


An interview with James A. McNamara Jr.

- Degree in Dentistry and Orthodontics, University of California, San Francisco.
- PhD in Anatomy from the University of Michigan.
- Professor of Thomas M. and Doris Graber Chair, Department of Orthodontics and Pediatric Dentistry - University of Michigan.
- Professor of Cell Biology and Development - University of Michigan.
- Research Professor at the Center for Human Growth and Development at the University of Michigan.
- Author of the book "Orthodontics and Dentofacial Orthopedics."
- Milo Hellman Research Award (AAO - 1973).
- Lecturer Sheldon E. Friel (European Society of Orthodontics -1979).
- Award Jacob A. Salzmann (AAO - 1994).
- Award James E. Brophy (AAO - 2001).
- Lecturer Valentine Mershon (AAO - 2002).
- Award Albert H. Ketcham (AAO - 2008).
- Graduate of the American Board of Orthodontics - ABO.
- Fellow of the American College of Dentists.
- Former President of Edward H. Angle Society of Orthodontists - Midwest.
- Editor of series "Craniofacial Growth Monograph" - published by University of Michigan.
- Over 250 published articles.
- Wrote, edited or contributed to more than 68 books.
- Taught courses and conferences in 37 countries.



I met James A. McNamara Jr. in the late 70's when we both became full members of the Edward H. Angle Society of Orthodontists - Midwest. Jim is one of the most active members, always looking on to break boundaries with new works. During over 30 years, I saw him being presented with all the existing awards and honors in the field of orthodontics. Knowing his ability and persistence, I'm sure that if in the future other awards are instituted, Jim will be there to, with all merits, conquer them. It is fortunate to have a family that supports and encourages: his wife Charlene, who accompanies him on every trip, and Laurie, his daughter and colleague, now a partner in his clinic. In addition to Orthodontics, he is passionate about golf and photography.

My sincere thanks to colleagues Bernardo Quiroga Souki, José Maurício Vieira de Barros, Roberto Mario Amaral Lima Filho, Weber Ursi, and Carlos Alexandre Câmara, who accepted the invitation to prepare questions that facilitated the development of the script of this interview. I hope that readers will experience the same pleasure and satisfaction I felt, when reading the answers. Jim was able to show growth and maturity of his clinical career, based on scientific evidence, with a clarity and simplicity that makes him, besides clinician and researcher emeritus, one of the best speakers of our time.

I thank the Dental Press for the opportunity to conduct this interview and wish you all a good reading.

Carlos Jorge Vogel

1) May I begin by asking you to tell us about your general educational background and your education in orthodontics?

I began my collegiate education at the University of California Berkeley, where I majored in Speech (today called Forensics), not science or biology. I then attended the School of Dentistry at the University of California San Francisco, where I received my dental degree and my specialty education in orthodontics. In 1968, I traveled 2000 miles east to Ann Arbor and began my doctoral studies in the Department of Anatomy at the University of Michigan. I also became affiliated with the Center for Human Growth and Development, an interdisciplinary research unit on the Ann Arbor campus that was headed by Dr. Robert Moyers. I had many wonderful mentors during my PhD years, including bone biologist Donald Enlow as well as orthodontists Frans van der Linden from the Netherlands, Kalevi Koski from Finland, Takayuki Kuroda from Japan and José Carlos Elgoyhen from Argentina. It was an exciting time for a young man like me to conduct research at the University of Michigan. My dissertation concerned the adaptation of the temporomandibular joints in rhesus monkeys, a study completed in 1972.^{1,2} I then was appointed to the University of Michigan faculty. I have been at Michigan ever since.

In addition to my current appointments in the School of Dentistry, the School of Medicine, and the Center for Human Growth and Development, I have maintained a part-time private practice in Ann Arbor, now sharing the practice with my daughter and partner Laurie McNamara McClatchey. Given my 40 years experience in private practice (with my partners and I sharing the same patients) as well as through my clinical supervision at the University of Michigan (and for eight years at the University of Detroit Mercy), I estimate that I have participated in the treatment of over 9,000 orthodontic patients. Thus, I have both academic and clinical perspec-

tives concerning orthodontics and dentofacial orthopedics. Maintaining a private practice while being on the Michigan faculty has had many advantages.

In addition, our research group, which includes Tiziano Baccetti and Lorenzo Franchi from the University of Florence, has addressed many orthodontic conditions from a clinical perspective, providing data on treatment outcomes. In this interview, I will be referring primarily to clinical investigations conducted by our group because the protocols used in our research efforts are consistent across studies.

2) You have been in private practice for a long time and have been an innovator of many orthodontic and dentofacial orthopedics treatments. How has your practice evolved over the years?

If anything, my practice philosophy has become simpler as the years have passed. I was well educated at UCSF in fixed appliance treatment and even used some preadjusted appliances during my residency in the mid 1960s. Beginning in the early 1970s, I began working with a variety of appliances aimed at modifying craniofacial growth, including functional jaw orthopedics (FJO), rapid maxillary expansion (RME) and facial mask therapy.

In 1980, I began formulating and testing protocols in the early mixed dentition for the correction of crossbites and of tooth-size/arch-size discrepancies, first with a bonded expander and later adding a removable lower Schwarz expansion appliance. As time passed, I began to realize how important it is for the orthodontist to have patience during treatment, letting normal growth and development of the patient take place after early intervention (for example, we will talk about creating an environment allowing “spontaneous improvement” in Class II malocclusion later in this discussion).

Today our treatment protocols are far less

complex that they were 20 years ago. Our regimens are clearly defined and standardized for the most part,³ as they had to become when I began sharing patient treatment with partners in my practice beginning in 1989. We also have placed significant emphasis on using those protocols that are not dependant on required high levels of patient compliance.

3) You thus have been an advocate of early orthodontic and orthopedic treatment for much of your professional career. Today, what are the most important issues related to early treatment?

In my opinion, perhaps the critical issue today is treatment timing.³ With the recent emphasis on “evidence-based” therapies in both medicine and dentistry, we now are gaining an appreciation concerning the nature of the treatment effects produced by specific protocols in patients of varying maturational levels. We are moving toward a better understanding concerning the optimal timing of orthodontic and orthopedic intervention, depending on the clinical condition.

In recent years, there has been considerable discussion among clinicians and researchers alike concerning the appropriate timing of intervention in patients who have Class II malocclusions, as has been evidenced by the ongoing discussions concerning the randomized clinical trials of Class II patients funded by the US National Institutes of Health (e.g., North Carolina, Florida). But the issue of “early treatment” is far broader than simply arguing about whether a Class II patient is better treated in one or two phases.

A variety of other malocclusions also must be considered within this topic, including the management of individuals with Class III malocclusions, those with open and deep bites, and the many patients with discrepancies between the size of the teeth and size of the bony bases (the latter comprise about 60% of the patients in our

private practice in Ann Arbor). The management of digital habits also falls within this discussion.

4) What are your views about the extent to which a clinician can alter the growth of the face?

In general, the easiest way for a clinician to alter the growth of the face is in the transverse dimension, orthopedically in the maxilla, orthodontically in the mandible.⁴ Rapid maxillary expansion (Fig 1) has been shown to be an extremely efficient and effective way of widening the maxillary bony base. In the lower arch, however, there is no mid-mandibular suture—so it is virtually impossible to produce orthopedic change in the mandible other than in combination with surgical distraction osteogenesis at the midline. The changes in the lower arch essentially are dentoalveolar in nature, such as those resulting from the use of a removable lower Schwarz appliance (Fig 2).

5) How about the correction of Class II and Class III problems?

As far as sagittal change is concerned, I think there is a substantial amount of experimental^{5,6} and clinical evidence⁷⁻¹⁰ that mandibular length can be increased over the short-term in comparison to untreated Class II controls, using a variety of functional orthopedic appliances. It should be noted, however, that not all investigators have come to this conclusion. The long-term effect of bringing the mandible forward functionally is much more uncertain at this time; most recent research has shown that the long-term mandibular skeletal effect may be limited to 1-2 mm over what would have occurred without treatment.^{11,12}

The best data that I have seen that considers the question of how much mandibular growth can be influenced over the long term has been derived from our recent study of Class II patients treated with the Fränkel appliance. In this

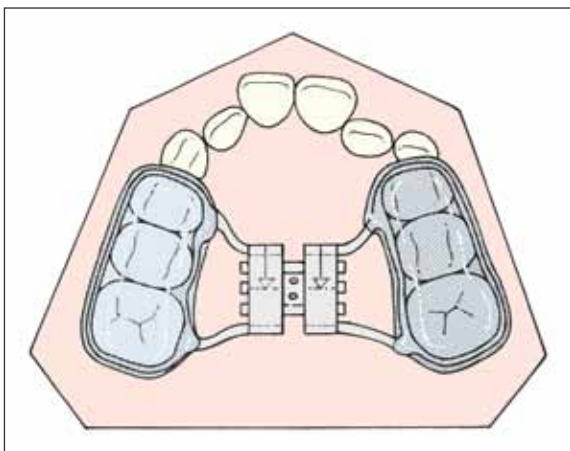


FIGURE 1 - The bonded acrylic splint type of rapid maxillary expander that is used primarily in patients in the mixed dentition is representative of the orthopedic expansion appliances used during treatment. The acrylic portion of the appliance is made from 3 mm thick splint Biocryl.³

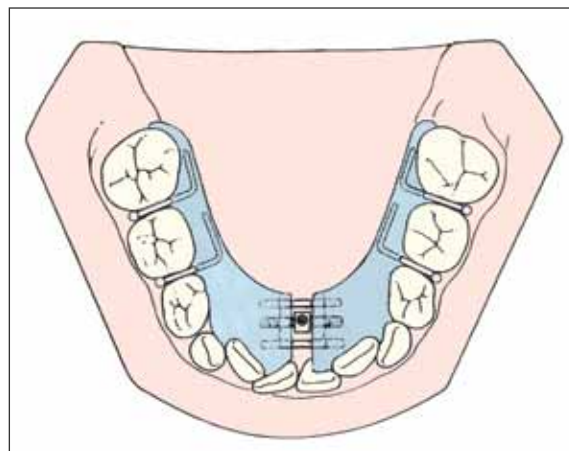


FIGURE 2 - The removable lower Schwarz appliance³ can be used prior to RME to upright the lower posterior teeth and gain a modest increase in arch perimeter anteriorly. It produces orthodontic tipping of the teeth only.

investigation by Freeman and co-workers,¹³ we evaluated patients treated with the FR-2 appliance by Rolf Fränkel of the former German Democratic Republic. Based on my experience with a variety of FJO appliances, I consider the function regulator (FR-2) the best of the functional appliances in that it addresses neuromuscular problems directly as well as skeletal and dental problems. A sample of 30 FR-2 patients was compared to a matched group of untreated Class II patients. Over the long-term, the increase in mandibular growth in the treated sample was 3 mm in comparison to controls.

6) If mandibular growth can be increased in length only by 1-2 mm with functional jaw orthopedics under most circumstances, why use it?

Hans Pancherz answered that question eloquently during a seminar at the University of Michigan when asked the same questions by our residents.¹⁴ He stated simply that “you get the growth when you need it.” Most studies of the Herbst appliance have shown that the

treatment effect produced by this tooth-borne type of FJO appliance is 50% dental and 50% skeletal.^{8,15} In comparison to untreated Class II controls, Herbst treatment produces about 2.5 to 3.0 mm increased mandibular length during the first phase of treatment; our investigation of Twin Block therapy has shown even larger short-term gains in mandibular length.^{9,16}

Normally Herbst or Twin Block wear results in the Class II patient having a Class I or super-Class I molar and canine relationship at the end of the first phase of treatment. Full fixed appliances then are used to align and detail the dentition. If the overall treatment outcome is evaluated, some of the gains in mandibular length observed during Phase I treatment may disappear by the end of fixed appliance therapy.^{11,12} Thus, FJO helps the clinician correct the underlying Class II malocclusion in a relatively short (9-12 months) and predictable manner. Some Class II patients with particularly favourable craniofacial features before treatment (a relatively closed gonial angle, for instance) may present an appreciable improvement in their

facial profile due to mandibular advancement following FJO. If a substantial change in the position of the chin is the primary focus of the treatment protocol, however, then corrective jaw surgery might be indicated, be it a mandibular advancement or a simple advancement by genioplasty.

Attempting to restrict the growth of the mandible presents a significant clinical challenge, particularly in the management of Class III malocclusion. One such appliance is the chin cup. I have not had extensive first-hand experience with the chin cup clinically, although at any given time we usually have one or two chin cup patients in our practice or in the university clinic, with the chin cup used primarily as a long-term retention device following facial mask therapy. The chin cup is indicated in patients who have mandibular prognathism and in whom an increase in lower anterior facial height is not desirable. A chin cup is not indicated in a patient who has maxillary retrusion.

There have been many studies, especially in Asian populations such as the Chinese, Korean and Japanese, that have shown over the short-term that there can be a restriction in mandibular projection in comparison to untreated Class III individuals.^{17,18} As of now, however, there is little evidence to support the premise that the growth of the mandible can be restricted over the long term (unless the patient wears the chin cup continuously from age 6 to age 18, a level of compliance that is difficult to attain).

7) You said earlier that the midface is responsive to treatment in the transverse dimension. How responsive is the maxilla to sagittal forces?

The growth of the midface seems to be influenced more readily by treatment than is the mandible. In the midface, restriction of the forward movement of the maxilla and maxillary dentition in Class II patients has been well-

documented for over 60 years, beginning with the work of Silas Kloehe,¹⁹ among others. Given good cooperation in a growing patient, there is no question that extraoral traction is effective in changing the occlusal relationship from Class II toward Class I. However our research on the components of Class II malocclusion has shown that true maxillary skeletal protrusion is relatively rare in a Caucasian population.^{20,21} In addition, good patient compliance is an essential component of this type of treatment.

Regarding protraction of the maxilla with an orthopedic facial mask (Fig 3) in Class III patients, most clinical studies have shown that the amount of true maxillary skeletal protraction is only 1-2 mm over what would occur during growth in untreated Class III subjects.^{22,23} Class III correction still can occur as a consequence of facial mask wear due mainly to mandibular modifications, especially because of favorable changes in the direction of condylar growth, also in relation to appropriate early treatment timing. Increased forward protraction amounts may be produced if the facial mask is attached to dental implants or if microimplants or bone anchors are used for skeletal anchorage.²⁴⁻²⁶

8) What changes can be produced in the vertical dimension of the face of a growing patient?

Most orthodontists have found that the vertical dimension is the dimension that is the most difficult to correct therapeutically, and that observation certainly has been substantiated by my clinical experience. In a growing patient, increasing a short lower facial height is accomplished most effectively with a FJO appliance such as the Twin Block^{9,27} or the FR-2 of Fränkel,⁷ less so with the Herbst appliance.

In the long-face patient, controlling the vertical dimension has been particularly challenging. For example, a study by our group evaluated modification in growth following the

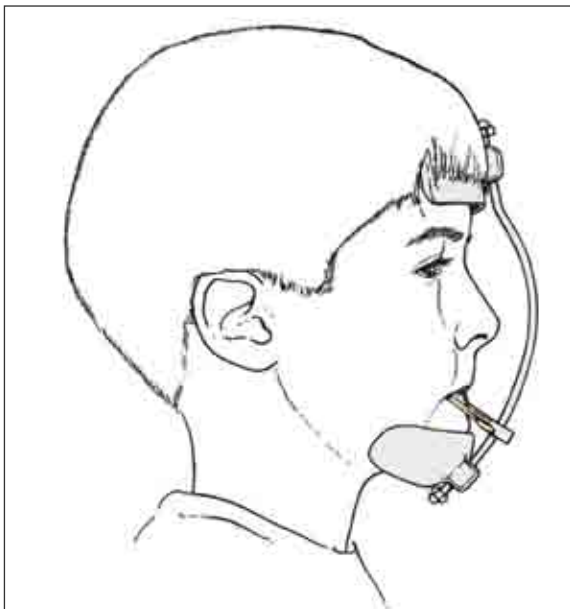


FIGURE 3 - The orthopedic facial mask of Petit.³

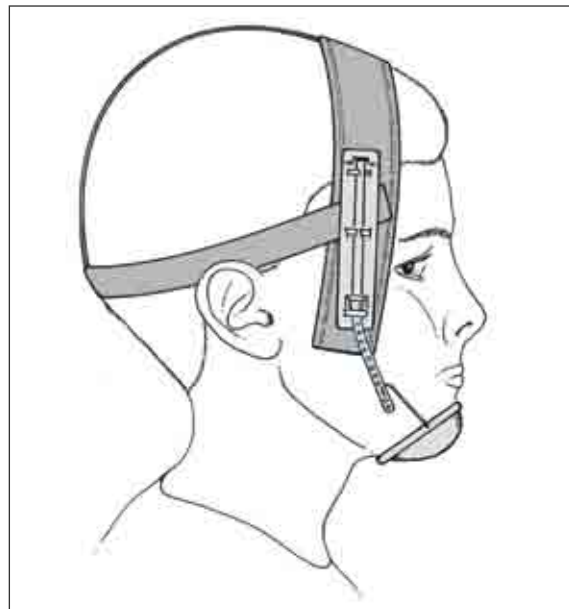

FIGURE 4 - The vertical-pull chin cup typically is used in combination with an acrylic splint expander.³

use of a bonded rapid maxillary expander and vertical-pull chin cup²⁸ (Fig 4). The effect of the vertical-pull chin cup was evident only in the mixed dentition, with little effect noted in the permanent dentition even though the appliance was worn at night for 5.5 years on average.

9) In Class III cases in the deciduous or early mixed dentition, what cephalometric parameters do you use to differentiate among a true Class III, true developing Class III, and a dentoalveolar Class III malocclusion?

I typically do not perform a detailed cephalometric analysis on a young patient with those questions in mind. Our approach to Class III treatment primarily is through the use of a bonded acrylic splint expander to which have been attached hooks for elastics (Fig 5) and an orthopedic facial mask (Fig 3). Typically, the first appliance that we use is the bonded expander.²⁹ In many patients (perhaps one-third of mixed dentition Class III patients), we observe

a spontaneous improvement of the Class III or Class III tendency toward Class I simply by expanding the maxilla. This favorable change occurs almost immediately after maxillary expansion. If further intervention is necessary, then we will incorporate an orthopedic facial mask into the treatment protocol.

Any time a patient has a Class III molar relationship and we use this protocol, first any CO-CR discrepancy is eliminated just by placing the facial mask; so we do not try to make the differentiation between those three conditions you asked about, in that all three conditions are managed by the same treatment regimen.

10) Do you still use the FR-3 Fränkel appliance? You previously have recommended the use of the FR-3, especially in maxillary retrognathic cases. What are your contemporary views on its use?

Currently, I actually use more FR-3 appliances³⁰ (Fig 6) than I do FR-2s. Today, the FR-3

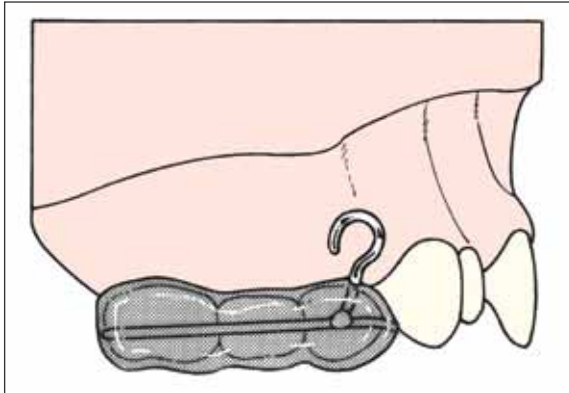


FIGURE 5 - The acrylic splint expander to which have been attached facial mask hooks.³

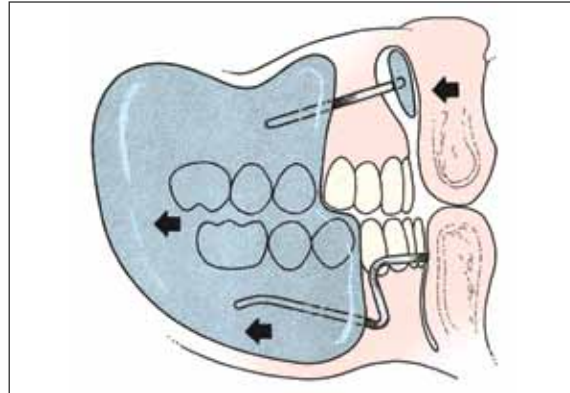


FIGURE 6 - The Fränkel FR-3 appliance.³ Fränkel⁶² states that the distracting forces of the upper lip are removed from the maxilla by the upper labial pads. The force of the upper lip is transmitted through the appliance to the mandible because of the close fit of the appliance to that arch.

usually serves as a retainer, rather than as a primary treatment appliance. The FR-3 is an appliance that has vestibular shields and also upper labial pads that free the maxilla from the forces of the associated musculature.³¹ The FR-3 produced similar treatment effects as does a facial mask-expander combination, but the effects take much longer to occur in FR-3 therapy.³

In the patient about whom we are suspicious of a strong tendency for relapse toward a Class III malocclusion after facial mask therapy, we will use the FR-3 as a retainer to be worn at night and around the house during the day. This approach of using the FR-3 as a retainer after successful facial mask therapy seems to be a reasonable way of incorporating this type of Fränkel appliance into our overall treatment scheme. We do not use the FR-3 often, but its use is essential in patients with difficult Class III problems.

11) Tell us more about the acrylic splint expander used in combination with the orthopedic facial mask. Can you elaborate on the use of this treatment protocol in dentoal-

veolar Class III or mandibular prognathism cases?

As stated before, we use the same basic protocol regardless of the etiology of the Class III problem. When I first heard Henri Petit (then of Baylor University in Dallas, Texas) speak about facial mask therapy in 1981, I was somewhat critical of his presentation because he did not differentiate among the various types of Class III malocclusions according to their etiology. I soon realized that the facial mask-expander combination is effective regardless of the underlying etiology of the Class III problem. I have used essentially the same protocol for the last 30 years, starting with the bonded expander. Typically we will deliver the expander and have the patient expand the appliance 28 times. If we need more turns, the patient is instructed to do so at the next appointment; then we will deliver the face mask if the underlying Class III malocclusion has not corrected spontaneously.

We usually recommend that the timing of facial mask therapy correspond to the eruption of the maxillary permanent central incisors.²⁹ I do not like to start much earlier than that because I

want to make sure that there is maximum vertical overlap of the permanent upper and lower central incisors at the end of facial mask treatment. The establishment of substantial vertical overlap of the incisors is critical in maintaining the corrected Class III malocclusion during the transition to the permanent dentition.

12) Do you use as a rule the maxillary expansion appliance with a facial mask, irrespective of the transverse width of the maxilla?

We use the bonded expander regardless of whether or not expansion is required. If the patient would benefit from widening of the maxilla, we have them expand the appropriate number of times. If there is no need to expand, we still have the patient expand 8-10 times to loosen the circummaxillary sutural system.²⁹ We and others have found that by mobilizing the sutures of the midface, we presumably affect the circummaxillary sutural system and facilitate the forward movement of the maxilla.^{3,32}

13) In the RME/FM appliance, where do you place the hooks for elastic attachment? Is it at the deciduous canines or deciduous first molars?

We typically use hooks that extend above the upper first deciduous molars. A downward and forward pull on the maxilla produced by the elastics counteracts the reverse autorotation of the maxilla that might occur because of the direction of pull on the teeth, resulting in a counterclockwise rotation of maxillary structures.

14) What are the force levels of the elastics that you prefer?

Three different elastics, the same elastics as originally recommended by Petit,³³ are used. The first elastic is 3/8" in length and is rated at 8 ounces (e.g., Tiger elastics from Ormco Corp.).

These elastics generate about 200 grams of force against the maxillary RME appliance. After a week or so, we switch to heavier elastics (1/2", 14 oz; Whale) that generate about 350 g of force. The final elastic is 5/16" and is rated at 14 oz (Walrus). These elastics generate about 600 g of force, so that by the time we use the third type of elastics, there is a considerable amount of force generated against the maxillary and mandibular structures.

15) Is there any particular method you recommend to remove the bonded expander?

The debonding procedure is relatively straightforward. First, one of my chairside assistants applies a topical anesthetic gel above the appliance in the region of the first and second deciduous molars bilaterally. We let the gel activate for a few minutes, and then I will use a pair of ETM 349 pliers to remove the bonded expander. The ETM 349 plier actually is an anterior bond remover that has a sharp edge on one side and a Teflon cap on the other. The Teflon cap is placed on the occlusal surface of the appliance, and the sharp edge is inserted under the gingival margin of the appliance between the first and second deciduous molars. I then use a single strong pulling motion that takes about half a second, debonding the left and then the right side of the appliance in one continuous motion. Very little or no discomfort is felt by the patient.

Obviously the ease of removal of the appliance is dependent on a number of technical factors. One of these factors is making sure that the proper material is used for the acrylic. I do not recommend the "salt and pepper" type of cold cure acrylic application for expander construction because the resulting type of acrylic is too rigid; rather, I strongly recommend the use of 3 mm thick splint Biocryl (Great Lakes Orthodontic Products) applied over the wire framework in a thermal pressure machine such

as a Biostar. By using the latter material, the expander is somewhat flexible; it then becomes very easy to break the seal of the adhesive to the teeth.

I also recommend that the chemical cure adhesive Excel™ (Reliance Orthodontics) is used for the bonding procedure. This adhesive is made specifically for the bonding of large acrylic appliances. In addition, a sealer should be placed on the teeth, and “plastic bracket primer” should be painted inside the expander prior to the bonding procedure. This primer actually is methyl methacrylate liquid; it softens the inside of the expander so that it can accept the bonding agent. So when we remove the appliance, all the bonding agent comes out in the appliance and none remains on the teeth, making clean-up easy.

16) Do you favor the use of slow expansion or rapid expansion?

I have not had much experience in dealing with protocols that deliver so-called “slow expansion.”³⁴ By that, I mean having the expander turned every other day or every third day (as might be used in some young adult patients). In our practice, we use a one turn-per-day protocol in growing patients, which is not as rapid as the original protocol of two turns-per-day advocated by Andrew Haas.³⁵

There are two distinct reasons why I have taken the one-turn-per-day approach, one practical and one based on long clinical experience. From a practice management standpoint, having a patient activate the expander twice per day simply means that I have to see the patient twice as frequently. We now have almost all patients activate the expander once a day for 28 days, which means that I only need to see the patient every four weeks, a more practical interval than once each week or once every two weeks.

The second reason has to do with the speed of expansion. Orthodontists across the United

States often contact me concerning problems they are experiencing that are associated with RME. One such problem is “saddle nose deformity,” a condition characterized by a loss of height of the nose because of the collapse of the bridge. This clinical problem can occur in young children undergoing rapid maxillary expansion (if the expander is removed immediately the unwanted deformity usually resolves without treatment). I have heard of 10 instances of this deformity over the years. In each instance, the orthodontist was using a protocol of twice-per-day expansion, a protocol that I do not recommend. It should be noted, of course, that this clinical recommendation is based purely on anecdotal information and clinical intuition, not hard science.

17) You have advocated expanding the maxilla using RME to alleviate moderate crowding. What is the basis of this approach?

This topic has been of great interest to me for over 3 decades. I received my orthodontic education during a time that the extraction of permanent teeth was a common occurrence in orthodontics, with a national extraction rate of 40% or greater observed during the 1960s and 1970s.³⁶ Since then, the rate of extraction gradually has decreased in the United States today to about 25% nationally. In our practice we extract about 12-15% of the time in Caucasian patients; however, the extraction rate is substantially higher in patients of Pacific Rim ancestry.

In 2003, our research group published a paper in the *Angle Orthodontist*³⁷ that dealt with an analysis of 112 individuals treated with a Haas-type expander (Fig 7) combined with fixed appliance therapy in the permanent dentition. We found that by using this treatment protocol, in comparison to a control sample from the University of Michigan Growth Study and University of Groningen Growth Study, a

residual increase of about 6 mm in maxillary arch perimeter and about 4.5 mm in mandibular arch perimeter was observed at age 21 years, value that are highly significant clinically. These data are the “best” data that I have seen with regard to increasing arch perimeter expansion in adolescent patients over the long term.

Subsequently, we have conducted many studies of patients treated initially in the early mixed dentition, two of which I will highlight: one that dealt with the bonded expander used alone³⁸ and one in which a mandibular Schwarz expansion appliance³⁹ that is intended to decompensate the lower arch and gain a modest amount of arch perimeter anteriorly was used prior to expansion. In general, the difference in arch perimeter in these two studies over the long term (patients were ~20 years of age) was slightly less than 4 mm in the maxilla and 2.5-3.7 mm in mandible in comparison to matched untreated control groups. Our investigations have shown that in a borderline case of crowding (i.e., 3-5 mm mandibular tooth-size/arch-size discrepancy) these early expansion protocols are reasonable approaches to treatment. On the other hand, if a patient has 7-10 mm or more of crowding in the mandible, an extraction approach (serial or otherwise) may be in order.

18) Tell me about serial extraction as used in your private practice? Do you advocate any particular sequence?

In our private practice my daughter and I currently have about 800 active patients, about 10 of whom are going through a protocol involving serial extraction. We use the size of the teeth as a guide to patient who requires serial extractions as the appropriate treatment. In a serial extraction protocol, extractions are indicated when there is at least 7 mm of arch length deficiency in the mandible; usually this protocol is undertaken in patients who have well balanced faces. If a patient has a severe man-

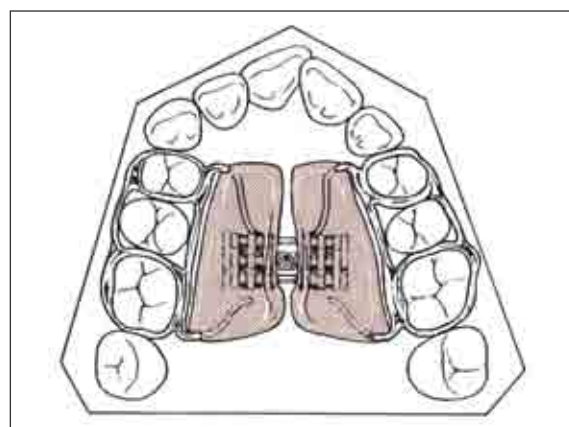


FIGURE 7 - The Haas-type rapid maxillary expander that has both metal and acrylic components.³

dibular skeletal retrusion or severe mandibular prognathism, it is not a good idea to use a serial extraction approach.

Our studies of the subjects in the University of Michigan Growth Study have shown that the size of the maxillary permanent central incisor in males of European ancestry is about 8.9 mm and in females about 8.7 mm, with a standard deviation of 0.6 mm for both sexes.⁴⁰ So, as a guideline, if we have a patient whose central incisor is 10 mm or greater in mesiodistal diameter, he or she would be a potential candidate for a serial extraction protocol. Obviously, the clinician has to take into account the size of all the teeth as well as the size of the bony bases. But generally a serial extraction protocol is performed in patients who have large tooth size (maxillary incisor ≥ 10 mm). In some instances, expansion of the maxilla followed by a serial extraction procedure ultimately is the treatment of choice.

Typically we order the extraction of all four deciduous canines, followed 6-12 months later by all deciduous first molars. This protocol hopefully encourages the first premolars to erupt before the canines, so that they can be

removed easily, later permitting the canines to erupt into the available arch space. In our serial extraction protocol, ultimately four first premolars almost always are removed.

19) Let's move on to the treatment of Class II malocclusion. If you have a choice as to the optimal timing of Class II intervention, at what stage is the best treatment outcome achieved?

Today, evidence seems to indicate that the most effective time in the maturation sequence of the “generic” Class II patient who does not have a severe skeletal problem is during the circumpubertal growth period. The maturational stage can be determined best by the level of cervical vertebra maturation⁴¹ (CVM) (Fig 8), as observed routinely in the lateral headfilm. This method originally was developed by Don Lamparski^{42,43} when he was an orthodontic resident at the University of Pittsburgh. This system was not used widely for the next 25 years. We discovered a copy of the Lamparski thesis serendipitously in the late 1990s and have been refining the CVM method ever since.^{41,44,45} Dentitional stage, meaning the late mixed or early permanent dentition, also can be used to determine the best time to initiate definitive Class II therapy. So in most such individuals, if it is reasonable we will defer any type of Class II correction until the circumpubertal growth period.

If a patient has a “socially debilitating” Class II malocclusion, however, then I would not hesitate to intervene in a 7-9 year old child, either with a functional appliance such as the Twin Block (Fig 9), the MARA appliance (Fig 10) or perhaps the cantilever version of the Herbst appliance. I would not expect, however, to have an abundant increase in mandibular growth during that early developmental stage. Rather, I would be attempting to make the patient socially acceptable from a psychological standpoint, hopefully leading to an improvement in his or her overall self image.

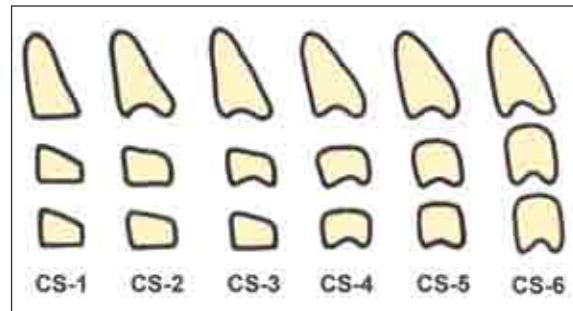


FIGURE 8 - CVM maturational stages. The six stages in cervical vertebrae maturation. Stage 1 (CS-1): The inferior borders of the bodies of all cervical vertebrae are flat. The superior borders are tapered from posterior to anterior. Stage 2 (CS-2): A concavity develops in the inferior border of the second vertebra. The anterior vertical height of the bodies increases. Stage 3 (CS-3): A concavity develops in the inferior border of the fourth vertebra. One vertebral body has a wedge or trapezoidal shape. Stage 4 (CS-4): A concavity develops in the inferior border of the fourth vertebra. Concavities in the lower borders of the fifth and sixth vertebrae are beginning to form. The bodies of all cervical vertebrae are rectangular in shape. Stage 5 (CS-5): Concavities are well defined in the lower borders of the bodies of all six cervical vertebrae. The bodies are nearly square and the spaces between the bodies are reduced. Stage 6 (CS-6): All concavities have deepened. The vertebral bodies are now higher than they are wide. The largest amount of mandibular lengthening normally occurs between CS-3 and CS-4.⁴¹

20) In your publications over the last 15 years, little emphasis has been assigned to the use of the Fränkel devices, in contrast to your earlier studies. What brought about this change to favor the use of Twin Block and Herbst appliances?

As I said earlier in the interview, I still consider the functional appliance system developed by Rolf Fränkel to be the most biologically based of any fixed or removable appliance. However, the technical manipulation of the appliance and the difficulties in having the function regulator FR-2 appliance (Fig 11) constructed properly still are daunting. In addition, appliance breakage and problems with patient compliance have caused the FR-2 to not be used often by most orthodontists in North America.

A few years ago, I polled six of the major orthodontic laboratories in the United States about FJO appliance fabrication. The results were startling—more Herbst appliances (Fig 12) are made today than all other functional

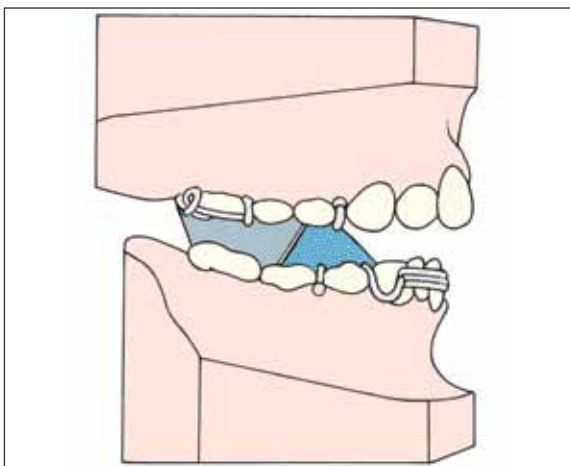


FIGURE 9 - The Twin Block appliance³ shown here is the modified version of the appliance that has a lower labial bow with acrylic to increase the stability of the appliance during the transition to the permanent dentition.

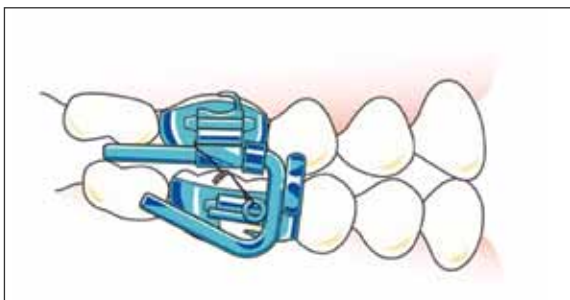


FIGURE 10 - The Mandibular Anterior Repositioning appliance (MARA).⁶³ This appliance has stainless steel crowns on the first permanent molars. The attachments cause the patient to bite in a forward position.

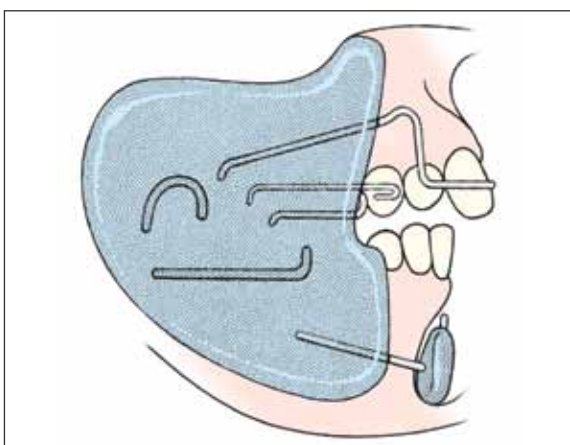


FIGURE 11 - The Fränkel Function Regulator FR-2.³ This appliance is characterized by buccal shields that are connected by a series of wires. The lower labial pads are used to retrain the mentalis muscle in patients with weak perioral musculature.

appliances combined. Most popular among the other FJO devices are the Twin Block (Fig 9) and the MARA (Fig 10) appliance and the bionator. About as many Fränkel appliances are made as bionators, but both are made less frequently than are the other appliances already mentioned.

21) For the last 20 or so years, you have talked about the “spontaneous improvement” in Class II malocclusion following maxillary expansion in the mixed dentition. A study from the University of Illinois by Tonya Volk et al,⁵⁴ published in 2010 in the AJO-DO, concluded that rapid maxillary expansion for spontaneous Class II correction does not support “the foot in the shoe theory”. According to this study, improvement in Class II malocclusions occur in about 50% of cases. What is your position today in respect of the concept that when the mandible is free to move forward, positive conditions are created for the mandible to grow to its full extent?

I have evaluated many treatments available for Class II malocclusion for over the last 40 years and have participated in the evolution of many types of functional appliances including the FR-2 of Fränkel as well as the Bionator, Herbst and Twin Block appliances. In addition, my education at the University of California San Francisco was strong concerning the use of extraoral traction. So I have substantial experience with different ways of correcting the sagittal position of the maxillary and mandibular bony bases. I certainly did not anticipate finding that Class II malocclusion improved spontaneously in many patients following expansion. A little personal history is in order.

We began using an acrylic splint expander in 1981 (actually our protocol today remains essentially unchanged from our early beginnings). We started by expanding the maxilla and placing four brackets on the maxillary incisors,

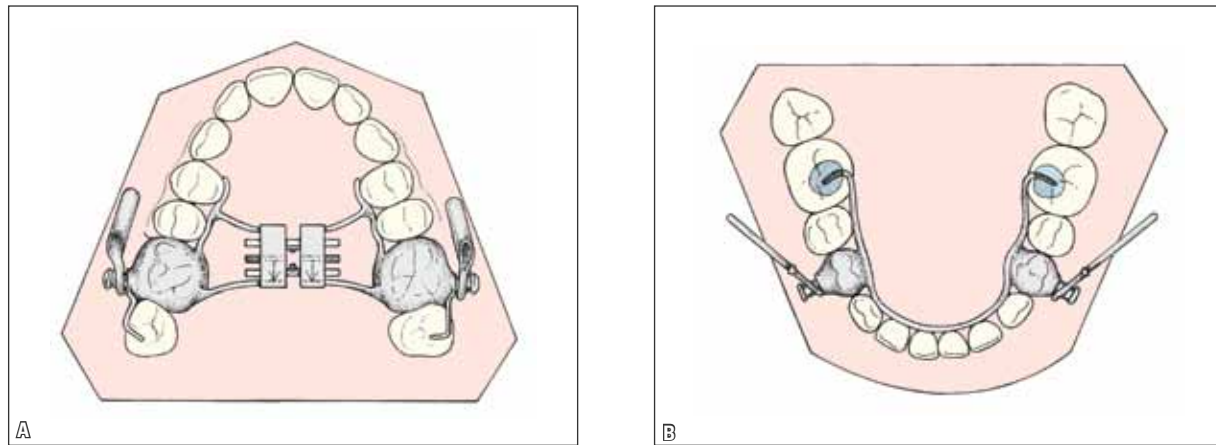


FIGURE 12 - The Stainless Steel Crown Herbst appliance.³ This design is used most commonly in our practice. A rapid maxillary expansion appliance always is added to the design not only to allow for expansion of the maxilla but also to stabilize the appliance. **A)** Maxillary view. **B)** Mandibular view.

if needed, to eliminate rotations and spacing. Treatment was completed and a removable maintenance plate (Fig 13) was delivered at the start of the retention period; some remarkable positive changes were noted post-treatment. Remember that at the end of active treatment, the maxillary dental arch intentionally had been overexpanded relative to the mandibular dental arch. This relationship encouraged the patient to posture his or her jaw forward in order to occlude in the most functionally efficient way. After 6-12 months when follow-up records were taken, many patients had substantial improvement in their sagittal occlusal relationship. It should be noted that discrepancies between centric occlusion and centric relation typically were not observed in the long-term.

Even though I thought that I had uncovered a previously unrecognized phenomenon, I later discovered that the spontaneous improvement in Class II relationship in fact had been noted in the German literature since the early 1900s by Körbitz,⁴⁶ who originally postulated the “foot-in-shoe” theory⁴⁷ mentioned in your question (Fig 14). Even Norman Kingsley, considered by many the “grandfather” of modern orthodontics,

alluded to the expansion of the maxilla as a way of correcting an excessive overjet as far back at 1880.⁴⁸ But until recently, no clinical studies had been carried out that addressed the “spontaneous improvement” issue.

In your question, you mentioned the work of Volk and co-workers on this topic, published in 2010.⁵⁴ Regardless of the findings of their study, the sample size was unacceptably small (N=13) and no control group was included. The question under consideration had to be addressed by a much larger prospective clinical study (as was stated in the last sentence of the Volk article), which we completed and just recently published.⁴⁹ We have gathered prospectively cephalometric and dental cast data on every patient in our practice who underwent an early expansion protocol, beginning in 1981. We stopped counting at 1,135 patients, a group that served as the original sample. We then applied several exclusionary rules to make sure that the patients were at the same stage of dental development and did not have any additional appliances used (e.g., FJO, lip bumper). The final sample size (by chance) was precisely 500 patients who had lateral cephalograms prior to treatment (about

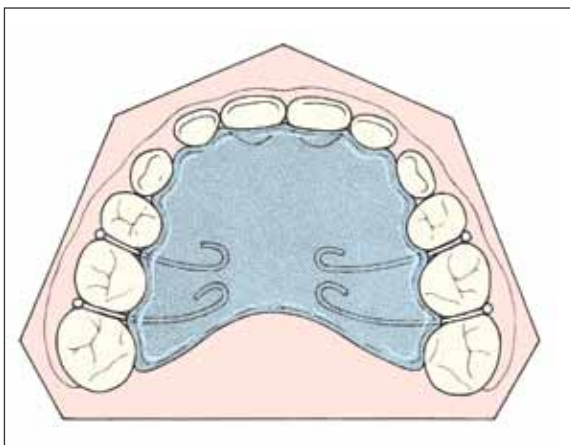


FIGURE 13 - A removable maintenance plate with ball clasps on either side of the second deciduous molars is used to stabilize the treated occlusion.³

8.5 years old) and prior to Phase II treatment (about 12.5 years of age). We then gathered data on 188 untreated subjects at the same two time intervals. Both the treated and untreated groups were separated into a Class II group, an end-to-end group, and a Class I group.

The results of our research are most easily understandable by looking at a more detailed analysis of a subset of individuals⁵⁰ that focused on 50 Class II and end-to-end patients who were matched to 50 untreated subjects. The findings of the latter study are presented in Figure 15. Positive skeletal and dentoalveolar treatment effects of RME were observed routinely; these effects are important in the serendipitous sagittal improvement of a Class II malocclusion after therapy. Forty-six of the 50 patients showed positive molar changes equal to or greater than 1 mm, compared to only 10 of 50 in the control group. On the other hand, 40 of the control subjects had neutral or unfavorable molar changes (less than +1 mm) between the mixed and permanent dentitions, compared to only 4 in the treated group. In other words, 92% of the treated group spontaneously improved their Class II molar relationship by one

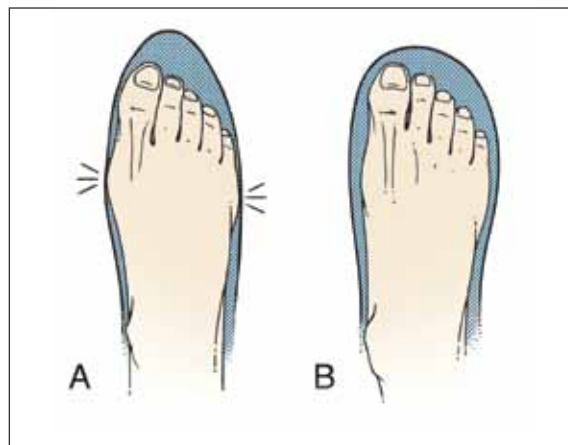


FIGURE 14 - Maxillomandibular relationship as indicated by the "foot and shoe" analogy of Körbitz.⁴⁶ **A**) The foot (mandible) is unable to be moved forward in the shoe (maxilla) due to transverse constriction. **B**) A wider shoe will allow the foot to assume its normal relationship. After Reichenbach et al.⁴⁷

millimeter or more, and almost 50% of treated patients presented with improvement in molar relationship of 2 mm or greater, without any definitive Class II mechanics incorporated into the protocol except for the transpalatal arch worn during the transition to the permanent dentition. There also were significant skeletal improvements from RME treatment including an increase in mandibular length, pogonion advancement, and a reduction in the ANB angle and the Wits appraisal value three and half years after active expansion therapy was completed.

Observations in the control group in this study confirm previously published data on longitudinal observations of untreated subjects with Class II malocclusions.⁵¹⁻⁵³ Arya and co-workers,⁵² for example, observed that all patients presenting with a distal-step relationship of the second deciduous molars ultimately demonstrated a Class II relationship of the permanent molars. In the current study, only 20% of the control subjects improved their molar relationship by 1 mm or 1.5 mm, which indicates that once a subject has a Class II malocclusion, without treatment they likely will remain with a Class II malocclusion in subsequent years.

The favorable effects of RME therapy on antero-posterior relationships occur both in full-cusp Class II and half-cusp Class II subjects. This expansion protocol originally was recommended from clinical anecdotal observations only in half-cusp Class II subjects;³ the results of the study by Guest and co-workers⁵⁰ indicate that spontaneous improvement of Class II malocclusion occurs equally in both half-cusp and full-cusp Class II relationships. Even Volk and co-workers⁵⁴ found improvement in Class II relationship in 7 of their 13 subjects.

The treatment protocol described above includes a Schwarz appliance (if needed), followed by an acrylic splint expander, and four brackets to align the maxillary incisors (if needed). The patient is given a simple maintenance plate (Fig 13) to maintain the achieved result. The lower arch is not maintained following the removal of the Schwarz appliance, but the patient is evaluated for a lower lingual arch (Fig 16) prior to the loss of the second deciduous molars if an arch length deficiency is anticipated. The last step in the protocol is the delivery of a transpalatal arch — TPA (Fig 17) — to maintain the leeway space during the transition to the permanent dentition.

22) Do you believe that the use of TPA in your sample had an important role for the positive outcome?

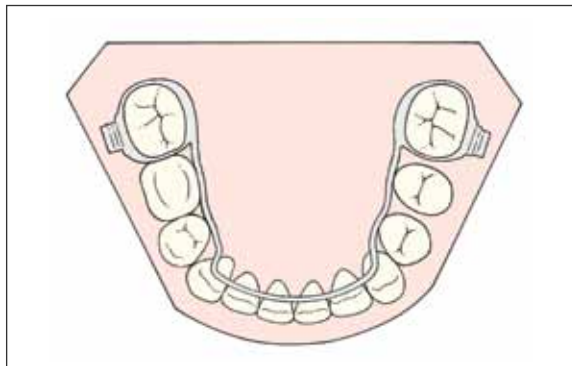


FIGURE 16 - The lower lingual arch is used during the late mixed dentition to maintain the “leeway” space in the region of the erupting second premolar.³ It also can be used during any stage of orthodontic treatment to help in transverse arch coordination, especially in patients who have undergone rapid maxillary expansion.

Each component of this protocol serves a significant role in improving the transverse and occlusal relationships during the transition to the permanent dentition. Obviously the rotation of the upper molars around the palatal root has a positive effect.

23) What happen in those patients in whom an early expansion protocol is undertaken and spontaneous correction of the underlying

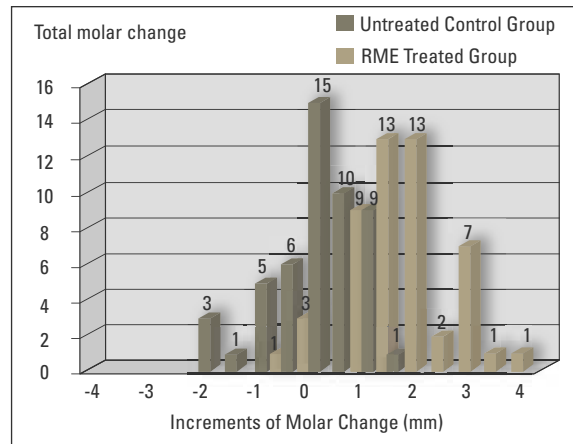


FIGURE 15 - Spontaneous improvement in Class II molar relationship following rapid maxillary expansion in the early mixed dentition. Comparison of amount of molar change from T2 - T1 for both groups. A score of “0” means that there was no change (i.e., 0 mm) in sagittal relationship of the maxillary and mandibular first permanent molars from the first to the second observation, a period of about 4 years. From Guest et al, 2010.⁵⁰

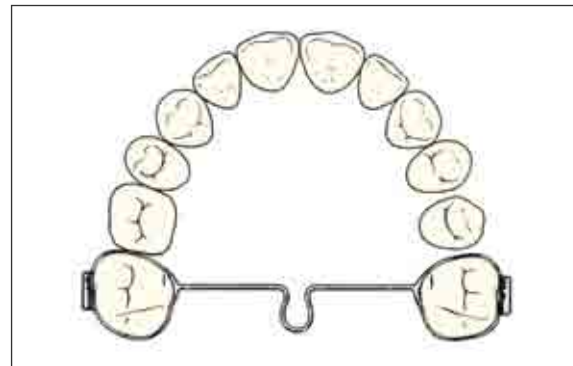


FIGURE 17 - The transpalatal arch is used not only to maintain leeway space, but also to rotate the maxillary first molars around their palatal roots and apply buccal root torque to these teeth.³

Class II molar relationship does not occur? Then what do you do?

All patients receive comprehensive edgewise treatment in the early permanent dentition. If a patient reaches the end of the mixed dentition or the early permanent dentition and still has a Class II malocclusion, a decision is made. If the patient has a reasonable growth potential and the canine relationships are within 1-3 mm of Class I, then routine fixed appliance treatment is undertaken including aggressive Class II elastic ($\frac{1}{4}$ ", 6 oz.) use. On the other hand, if the patient still has an end-to-end or worse Class II relationship, a stainless steel crown Herbst appliance (Fig 12) is used if mandibular skeletal retrusion is present. If the anteroposterior position of the mandible is within normal limits, then a Pendulum^{55,56} (Fig 18) or Pendex (Fig 19) appliance may be recommended. In a few instances, the extraction of 2 maxillary first premolars may be indicated. In any event, full fixed appliances are used to align the permanent dentition.

It seems that the use of a Herbst appliance to bring the mandible forward would be in sharp contrast to the approach taken by distalizing the maxillary dentition with a Pendex or Pendulum appliance; presumably these seemingly opposite treatment approaches would result in very dif-

ferent treatment outcomes. A study by our group that compared the Pendex appliance to 2 types of Herbst appliances¹⁰ showed that even though the expected differences in response in mandibular growth were noted during Phase I, the overall length of the mandible was not statistically different among groups at the end of treatment; a slightly greater increase in lower anterior facial height, however, did result after Pendex therapy combined with fixed appliances. Thus the presumed differences in treatment approach do not appear to be a great as assumed as before the results were made available, again showing the importance of evidence based treatment.

24) What are your views on the use of functional appliances in patients with vertical problems?

Functional appliance therapy in a high angle Class II patient is something I consider. My current treatment of choice is the stainless steel crown Herbst appliance (Fig 12), which I have used fairly routinely since the early 1990s.¹⁰ We also have had good success when using the acrylic splint variety of the Herbst appliance.³⁰ I see no significant contraindication to using either type of appliance in a high angle patient.

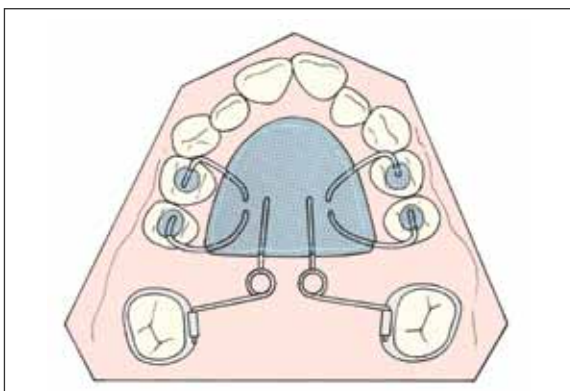


FIGURE 18 - The Pendulum appliance is used to distalize the maxillary first molars, typically one side at a time.³ This treatment is followed by the placement of a Nance holding arch that is left in place until the premolars and canines are distalized.

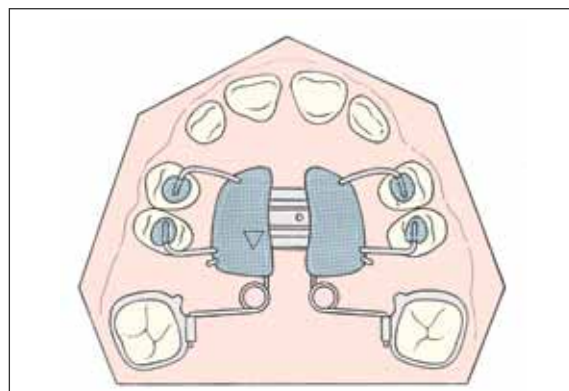


FIGURE 19 - The Pendex appliance incorporates an expansion screw into the palatal acrylic that is activated as necessary prior to molar distalization.³

25) Where do we stand when we are asked by parents whether this early treatment approach is going to result in better or more stable results? What is a safe answer to this question?

I started using the bonded expander protocol 30 years ago, and although we now have treated 1,500+ patients with this protocol, accumulating long-term data on patients who are 20 years of age or older is challenging, especially when conducting a non-federally-funded project such as ours. The data we have analyzed thus far indicate that the protocols we have been using are reasonably stable in comparison to untreated controls. I would tell patients and parents that existing research indicates that the treatment protocols seem to provide a stable result over the long-term as long as the patient wears the retainers at least on a part-time basis after active treatment. We recommend full-time wear of retainers for one year and then nighttime wear indefinitely, a protocol that is prudent to use in all patients treated orthodontically for any type of malocclusion.

26) How do you look at the changes orthodontics has gone through in the last 10 years, such as the use of TADs, self-ligating brackets, SureSmile archwires, lingual brackets and aligners (Invisalign and others)? In the next decade, what can we expect in terms of new technologies in orthodontics?

You certainly are correct with regard to the influence of technology on clinical practice, not only how we practice but also how patients use social and business media to determine which orthodontist to see. I am sure that this phenomenon is just as obvious in Brazil as it is in the United States.

You have asked about some specific technologies that have emerged during the last decade or so, the first being microimplants or TADs. My first exposure to TADs was in about ten years ago when we interacted with Drs. Kyung, Sung

and Park of Kyungpook National University in Daegu, Korea. In fact, I am the last author of a textbook on this subject published by the Daegu group.⁵⁷ Microimplants have been shown to offer new treatment options in orthodontics, particular in patients requiring maximum anchorage during tooth retraction and in managing problems in the vertical dimension. My own success rate with microimplants in our practice and at the university has been mixed, with the biggest problem being the loosening of the TADs during treatment for no apparent reason. With increased experience, I assume that our success rate will improve.

The second subject to be considered concerns self-ligating brackets. I entered this experience with great expectations, having learned the method directly from the developer of the particular system that I used. I then started 20 consecutive cases with the prescribed self-ligating brackets. Treatment progressed nicely at first with good initial leveling and aligning, but by the end I had switch 11 of the patients back to my original preadjusted bracket system. I could not finish the cases to my usual standards. I have tried other self-ligating bracket systems since then, but I still prefer a more traditional approach to straightening teeth.

I will group the next two topics together, SureSmile archwires and lingual brackets. I have not used either in our private practice, so I have no experience and thus no opinions on either. We now are conducting a clinical study comparing patients treated with the SureSmile approach to conventional treatment. In a year or two, we will have some good data as to the efficiency and effectiveness of the SureSmile approach.

One topic that I do know a lot about is invisible retainers. When I went into practice in Ann Arbor in 1971, I rented space for orthodontist John Mortell. He was a friend and colleague of Robert Ponitz, who practiced orthodontics three blocks away. Bob Ponitz published the first paper in the orthodontic literature⁵⁸ on

invisible retainers. I literally have used invisibles for 40 years. In 1985, we published a paper in the *Journal of Clinical Orthodontics* on how to use invisibles to move teeth.⁵⁹ I of course did not envision the CAD CAM revolution that would occur a decade later. We use invisible retainers for 97% of our patients as our primary retention method following the use of a tooth positioner in the vast majority of patients. I am not a fan of Hawley retainers in that Hawleys do not maintain the position of the anterior teeth very well, particularly the lateral incisors.

As far as Invisalign is concerned, this approach has been incorporated into our practice on a limited basis, so we have treated about 175 patients thus far. My daughter Laurie usually tells patients that Invisalign can achieve about 80% of what can be achieved with fixed appliances. We limit our Invisalign cases primarily to those that could be treated with fixed appliances in a year or so and have only minor skeletal discrepancies. For many adult patients, Invisalign is their only acceptable option and thus our treatment expectations must be limited by reality.

27) In that you have brought up the topic of retention, let's finish the interview with you giving us a description of your finishing and retention protocol.

One of the basic principles espoused by Stephen Covey in his popular book "The Seven Habits of Highly Effective People"⁶⁰ is to "start with the end in mind." Thus we place brackets and activate the transpalatal arch with the end of treatment in mind. After 6-12 months, a panoramic film is taken to evaluate bracket position; we reposition brackets as necessary. We typically move from an initial leveling wire (.014" or .016" NiTi or .016x.022" copper NiTi) to a .016x.022" Bioforce NiTi wire and finish in a .016x.022" TMA wire.

A few months before the end of treatment, we take what are called "debond evaluation models" to evaluate the occlusion in all three

dimensions. If additional treatment is indicated, this is completed and the same models are sent to a commercial laboratory for the fabrication of a positioner that is delivered as soon as the appliances are removed.

A week before debonding, all bands are removed including those that are part of the TPA (if still present). The archwires also are removed and the patient has .008" ligature wire placed in a serpentine configuration from second premolar to second premolar on the opposite side of the arch (Fig 20). The patient is instructed to chew gum for a week prior to appliance removal. On that day, all remaining appliances are removed and the patient is given the positioner (Fig 21), with instructions to wear it full-time for the next 24 hours, as much as possible during the next 3-4 days and then 4 hours a day plus sleeping hours for the next few weeks. At the next appointment, post-treatment records are taken as are impressions for invisible retainers (Fig 22). Up to one tooth per quadrant can be reset before the invisible retainers are fabricated.

I would like to make one final comment about our finishing and retention protocol. Most orthodontists finish treatment with fixed appliances and then give Hawley retainers to allow "settling" of the occlusion. We have found that our more complex protocol produces outstanding results, as has been substantiated by the findings of a prospective clinical trial conducted in our practice.⁶¹ The positioner improves the quality of the finished result substantially.

28) You have covered a wide range of topics in this interview. If our readers want additional information concerning the treatment protocols that you recommend, where can they find that information?

I suggest that they go online at www.needhampress.com and find our book "Orthodontics and Dentofacial Orthopedics"³ and well as the books from the Craniofacial Growth Series published by

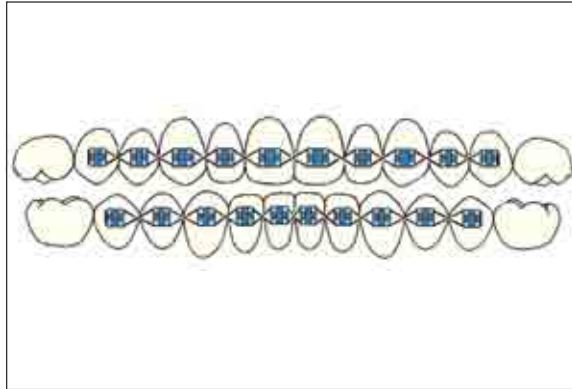


FIGURE 20 - Serpentine wires are placed from second premolar to second premolar in both arches after all bands have been removed.³ In extraction patients, bands adjacent to extraction sites are left in place.

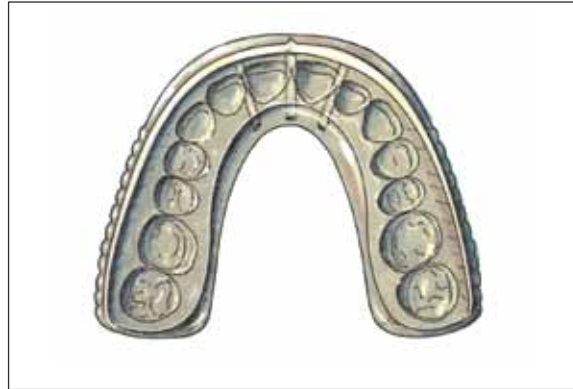

FIGURE 21 - A tooth positioner is fabricated from the debond evaluation models. The teeth are reset ideally after all the brackets and bands have been carved away. The occlusal set-up is ideal.³

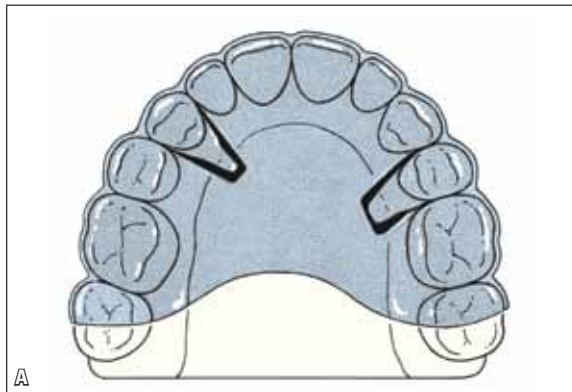
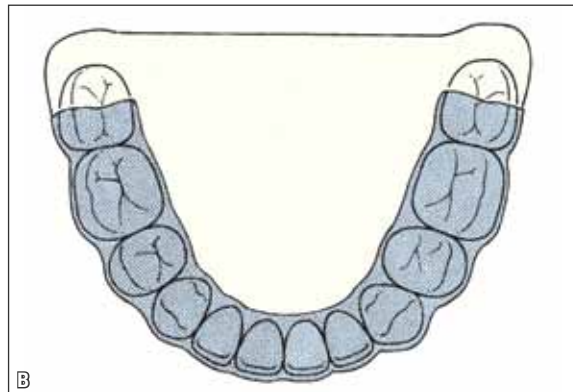


FIGURE 22 - Maxillary and mandibular invisible retainers³ 1 mm in thickness are used as the preferred method of long-term retention in most instances. Up to one tooth per quadrant can be reset in wax prior to the fabrication of the retainers.



the University of Michigan. The reader also can go to Google and search for “James McNamara Michigan.” That search will take them directly to my webpage on our dental school website. If the reader then looks under “Selected Publications,” PDF files of almost all of our publications can be downloaded without charge.

Also, I want to recognize again my two colleagues from the University of Florence, Italy, Lorenzo Franchi and Tiziano Baccetti, who have worked with me since 1994. Our collaboration together and with other researchers throughout the world has enabled all of us to gain unique perspective as to how the face grows and how the

craniofacial structures respond to treatment. Our research definitely has been a group effort.

Finally, I would like to thank you for the invitation to be interviewed. Over the years, I have had a close relationship with many Brazilian orthodontists and have lectured in Brazil many times, including a delightful experience sponsored by Dental Press in Maringá a few years ago (2007).

Just this past fall, we hosted a one-week intensive course for Brazilian orthodontists in Ann Arbor, the third time that we have done so over the years. We are planning another one-week orthodontic experience again through the University of Michigan in 2012.

REFERENCES

1. McNamara JA Jr. Neuromuscular and skeletal adaptations to altered orofacial function. Ann Arbor: Monograph 1, Craniofacial Growth Series, Center for Human Growth and Development, The University of Michigan; 1972.
2. McNamara JA Jr. Neuromuscular and skeletal adaptations to altered function in the orofacial region. *Am J Orthod.* 1973;64:578-606.
3. McNamara JA Jr, Brudon WL. Orthodontics and dentofacial orthopedics. Ann Arbor: Needham Press; 2001.
4. McNamara JA Jr. Maxillary transverse deficiency. *Am J Orthod Dentofacial Orthop.* 2000;117:567-70.
5. Petrovic A, Stutzmann J, Gasson N. The final length of the mandible: is it genetically determined? In: Carlson DS, editor. Craniofacial Biology. Ann Arbor: Monograph 10, Craniofacial Growth Series, Center for Human Growth and Development, The University of Michigan; 1981.
6. McNamara JA Jr, Bryan FA. Long-term mandibular adaptations to protrusive function: an experimental study in *Macaca mulatta*. *Am J Orthod Dentofacial Orthop.* 1987;92:98-108.
7. McNamara JA Jr, Bookstein FL, Shaughnessy TG. Skeletal and dental changes following functional regulator therapy on Class II patients. *Am J Orthod.* 1985;88:91-110.
8. McNamara JA Jr, Howe RP, Dischinger TG. A comparison of the Herbst and Fränkel appliances in the treatment of Class II malocclusion. *Am J Orthod Dentofacial Orthop.* 1990;98:134-44.
9. Toth LR, McNamara JA Jr. Treatment effects produced by the twin block appliance and the FR-2 appliance of Frankel compared to an untreated Class II sample. *Am J Orthod Dentofacial Orthop.* 1999;116:597-609.
10. Burkhardt DR, McNamara JA Jr, Baccetti T. Maxillary molar distalization or mandibular enhancement: a cephalometric comparison of the Pendulum and Herbst appliances. *Am J Orthod Dentofacial Orthop.* 2003;123:108-16.
11. Pancherz H. The Herbst appliance. Seville: Editorial Aguiram; 1995.
12. Lai M, McNamara JA Jr. An evaluation of two-phase treatment with the Herbst appliance and preadjusted edgewise therapy. *Semin Orthod.* 1998;4:46-58.
13. Freeman DC, McNamara JA Jr, Baccetti T, Franchi L. Long-term treatment effects of the FR-2 appliance of Fränkel. *Am J Orthod Dentofacial Orthop.* 2008;133:513-24.
14. Pancherz H. Personal communication; 2001.
15. Pancherz H. Treatment of Class II malocclusions by jumping the bite with the Herbst appliance. A cephalometric investigation. *Am J Orthod.* 1979;76:423-42.
16. Schaefer AT, McNamara JA Jr, Franchi L, Baccetti T. A cephalometric comparison of two-phase treatment with the Twin Block and stainless steel crown Herbst appliances followed by fixed appliance therapy. *Am J Orthod Dentofacial Orthop.* 2004;126:7-15.
17. Sugawara J, Asano T, Endo N, Mitani H. Long-term effects of chin-cap therapy on skeletal profile in mandibular prognathism. *Am J Orthod Dentofacial Orthop.* 1990;98:127-33.
18. Mitani H, Sato K, Sugawara J. Growth of mandibular prognathism after pubertal growth peak. *Am J Orthod Dentofacial Orthop.* 1993;104:330-6.
19. Kloehn SJ. Orthodontics: force or persuasion. *Angle Orthod.* 1953;23:56-65.
20. McNamara JA Jr. Components of Class II malocclusion in children 8-10 years of age. *Angle Orthod.* 1981;51:177-202.
21. Ellis E 3rd, McNamara JA Jr, Lawrence TM. Components of adult Class II open-bite malocclusion. *J Oral Maxillofac Surg.* 1985;43:92-105.
22. Turley PK. Orthopedic correction of Class III malocclusion with palatal expansion and custom protraction headgear. *J Clin Orthod.* 1988;22:314-25.
23. McGill JS, McNamara JA Jr. Treatment and post-treatment effects of rapid maxillary expansion and facial mask therapy. In: McNamara JA Jr, editor. Growth modification: what works, what doesn't and why. Ann Arbor: Monograph 36, Craniofacial Growth Series, Center for Human Growth and Development, University of Michigan; 1999.
24. McNamara JA Jr. Implants, microimplants, onplants and transplants: New answers to old questions in orthodontics. Ann Arbor: Monograph 44, Craniofacial Growth Series, Department of Orthodontics and Pediatric Dentistry and Center for Human Growth and Development, The University of Michigan; 2005.
25. De Clerck HJ, Cornelis MA, Cevidanes LH, Heymann GC, Tulloch CJ. Orthopedic traction of the maxilla with miniplates: a new perspective for treatment of midface deficiency. *J Oral Maxillofac Surg.* 2009;67:2123-9.
26. Cevidanes L, Baccetti T, Franchi L, McNamara JA Jr, De Clerck HJ. Comparison of 2 protocols for maxillary protraction: bone anchors and face mask with rapid maxillary expansion. *Angle Orthod.* in press 2010.
27. Clark WJ. Twin block functional therapy. London: Mosby-Wolfe; 1995.
28. Schulz SO, McNamara JA Jr, Baccetti T, Franchi L. Treatment effects of bonded RME and vertical pull chin cup followed by fixed appliances in patients with increased vertical dimension. *Am J Orthod Dentofacial Orthop.* 2005;128:326-36.
29. McNamara JA Jr. An orthopedic approach to the treatment of Class III malocclusion in young patients. *J Clin Orthod.* 1987;21:598-608.
30. Fränkel R, Fränkel C. Orofacial orthopedics with the function regulator. Munich: Karger; 1989.
31. McNamara JA Jr, Hulse SA. The functional regulator (FR-3) of Fränkel. *Am J Orthod.* 1985;88:409-24.
32. Baik HS. Clinical results of the maxillary protraction in Korean children. *Am J Orthod Dentofacial Orthop.* 1995;108:583-92.
33. Petit HP. Adaptation following accelerated facial mask therapy. In: McNamara JA Jr, Ribbens KA, Howe RP, editors. Clinical alterations of the growing face. Ann Arbor: Monograph 14, Craniofacial Growth Series, Center for Human Growth and Development, The University of Michigan; 1983.
34. Hicks EP. Slow maxillary expansion. A clinical study of the skeletal versus dental response to low-magnitude force. *Am J Orthod.* 1978;73:121-41.
35. Haas AJ. Rapid expansion of the maxillary dental arch and nasal cavity by opening the mid-palatal suture. *Angle Orthod.* 1961;31:73-90.
36. Proffit WR. Forty-year review of extraction frequencies at a university orthodontic clinic. *Angle Orthod.* 1994;64:407-14.
37. McNamara JA Jr, Baccetti T, Franchi L, Herberger TA. Rapid maxillary expansion followed by fixed appliances: a long-term evaluation of changes in arch dimensions. *Angle Orthod.* 2003;73:344-53.
38. Geran RG, McNamara JA Jr, Baccetti T, Franchi L, Shapiro LM. A prospective long-term study on the effects of rapid maxillary expansion in the early mixed dentition. *Am J Orthod Dentofacial Orthop.* 2006;129:631-40.
39. O'Grady PW, McNamara JA Jr, Baccetti T, Franchi L. A long-term evaluation of the mandibular Schwarz appliance and the acrylic splint expander in early mixed dentition patients. *Am J Orthod Dentofacial Orthop.* 2006;130:202-13.
40. Moyers RE, van der Linden FPGM, Riolo ML, McNamara JA Jr. Standards of human occlusal development. Ann Arbor: Monograph 5, Craniofacial Growth Series, Center for Human Growth and Development, The University of Michigan; 1976.

41. Baccetti T, Franchi L, McNamara JA Jr. The Cervical Vertebral Maturation (CVM) method for the assessment of optimal treatment timing in dentofacial orthopedics. *Semin Orthod.* 2005;11:119-29.
42. Lamparski DG. Skeletal age assessment utilizing cervical vertebrae. Pittsburgh: Unpublished Master's thesis, Department of Orthodontics, The University of Pittsburgh; 1972.
43. Lamparski DG, Nanda SK. Skeletal age assessment utilizing cervical vertebrae. In: McNamara JA Jr, Kelly KA, editors. *Treatment timing: Orthodontics in four dimensions.* Ann Arbor: Monograph 39, Craniofacial Growth Series, Department of Orthodontics and Pediatric Dentistry and Center for Human Growth and Development, The University of Michigan; 2002.
44. Franchi L, Baccetti T, McNamara JA Jr. Mandibular growth as related to cervical vertebral maturation and body height. *Am J Orthod Dentofacial Orthop.* 2000;118:335-40.
45. Baccetti T, Franchi L, McNamara JA Jr. An improved version of the cervical vertebral maturation (CVM) method for the assessment of mandibular growth. *Angle Orthod.* 2002;72:316-23.
46. Körbitz A. *Kursus der systematischen Orthodontik. Ein Leitfaden für Studium und Praxis.* 2nd ed. Leipzig: Hans Licht; 1914.
47. Reichenbach E, Brückl H, Taatz H. *Kieferorthopaedische Klinik und Therapie.* 6er aufl. Leipzig: Johan Ambrosius Barth; 1967.
48. Kingsley NW. *A treatise on oral deformities as a branch of mechanical surgery.* New York: D. Appleton; 1880.
49. McNamara JA Jr, Sigler LM, Franchi L, Guest SS, Baccetti T. Changes in occlusal relationship in mixed dentition patients treated with rapid maxillary expansion: a prospective clinical study. *Angle Orthod.* 2010;80:230-8.
50. Guest SS, McNamara JA Jr, Baccetti T, Franchi L. Improving Class II malocclusion as a side-effect of rapid maxillary expansion: a prospective clinical study. *Am J Orthod Dentofacial Orthop.* 2010;138(5):582-91.
51. Baccetti T, Franchi L, McNamara JA Jr, Tollaro I. Early dentofacial features of Class II malocclusion: a longitudinal study from the deciduous through the mixed dentition. *Am J Orthod Dentofacial Orthop.* 1997;111:502-9.
52. Arya BS, Savara BS, Thomas DR. Prediction of first molar occlusion. *Am J Orthod.* 1973;63:610-21.
53. Bishara SE, Hoppens BJ, Jakobsen JR, Kohout FJ. Changes in the molar relationship between the deciduous and permanent dentitions: a longitudinal study. *Am J Orthod Dentofacial Orthop.* 1988;93:19-28.
54. Volk T, Sadowsky C, BeGole EA, Boice P. Rapid palatal expansion for spontaneous Class II correction. *Am J Orthod Dentofacial Orthop.* 2010;137:310-5.
55. Hilgers JJ. The pendulum appliance for Class II non-compliance therapy. *J Clin Orthod.* 1992;26:706-14.
56. Hilgers JJ. The pendulum appliance: An update. *Clin Impressions.* 1993:15-17.
57. Sung JH, Kyung HM, Bae SM, Park HS, Kwon OW, McNamara JA Jr. *Microimplants in orthodontics.* Daegu: Dentos; 2006.
58. Ponitz RJ. Invisible retainers. *Am J Orthod.* 1971;59:266-72.
59. McNamara JA, Kramer KL, Jeunker JP. Invisible retainers. *J Clin Orthod.* 1985;19:570-8.
60. Covey SR. *The seven habits of highly effective people.* New York: Simon and Schuster; 1989.
61. Stock GM, McNamara JA Jr, Baccetti T. The efficacy of two finishing protocols in the quality of orthodontic treatment outcome. *Am J Orthod Dentofacial Orthop.* in press.
62. Fränkel R. Maxillary retrusion in Class III and treatment with the function corrector III. *Rep Congr Eur Orthod Soc.* 1970:249-59.
63. Berkman ME, Haerian A, McNamara JA Jr. Interarch maxillary molar distalization appliances for Class II correction: an overview. *J Clin Orthod.* 2008;42:35-42.

Bernardo Quiroga Souki

- Specialist in Pediatric Dentistry, School of Dentistry of Ribeirão Preto - USP.
- Specialist in Orthodontics, PUC Minas.
- MSc in Pediatric Dentistry, UFMG.
- PhD in Health Sciences (UFMG).
- Associate Professor III, Masters Course in Orthodontics at PUC Minas.

José Maurício de Barros Vieira

- Specialist and MSc in Orthodontics, PUC Minas.
- Associate Professor III, Masters Course in Orthodontics at PUC Minas.
- Graduate, Brazilian Board of Orthodontics and Dentofacial Orthopedics - BBO.
- Former President of ABOR-MG.

Carlos Alexandre Camara

- Specialist in Orthodontics, State University of Rio de Janeiro - UERJ.
- Graduate, Brazilian Board of Orthodontics and Dentofacial Orthopedics - BBO.
- Editorial reviewer of the Revista Dental Press de Estética.

Roberto Mario Amaral Lima Filho

- Post-graduate degree in Orthodontics, University of Illinois, Chicago, USA.
- MSc and PhD in Orthodontics, Federal University of Rio de Janeiro - UFRJ.
- Graduate, American Board of Orthodontics - ABO.
- Member of the Edward H. Angle Society of Orthodontists, Midwest.
- Former President of the Brazilian Board of Orthodontics and Facial - BBO.
- Editor of the book "Ortodontia: Arte e Ciência."

Carlos Jorge Vogel

- Postgraduate in Orthodontics, University of Illinois, Chicago, USA.
- PhD in Orthodontics, University of São Paulo - USP.
- Member of the Edward H. Angle Society of Orthodontists Midwest.
- Graduate, Brazilian Board of Orthodontics and Dentofacial Orthopedics - BBO.
- Former President of the Brazilian Board of Orthodontics and Dentofacial Orthopedics - BBO.

Weber Ursi

- MSc and PhD in Orthodontics, University of São Paulo - USP, Bauru.
- Professor at UNESP - São José dos Campos.
- Coordinator of the Specialization Course in Orthodontics - APCD - São José dos Campos.
- Interim Editor - Revista Clínica de Ortodontia Dental Press.

Contact address

James A. McNamara Jr.
mcnamara@umich.edu