

# Imaging from temporomandibular joint during orthodontic treatment: a systematic review

Eduardo Machado\*, Renésio Armindo Grehs\*\*, Paulo Afonso Cunali\*\*\*

## Abstract

**Introduction:** The evolution of imaging in dentistry has provided several advantages for the diagnosis and development of treatment plans in various dental specialties. Examinations as nuclear magnetic resonance, computed tomography and cone beam volumetric tomography, as well as 3D reconstruction methods, have enabled a precise analysis of orofacial structures. Allied to this fact, the effects of orthodontic treatment on temporomandibular joint (TMJ) could be evaluated with the accomplishment of clinical studies with appropriate designs and methodologies. **Objective:** This study, a systematic literature review, had the objective of analyzing the interrelation between orthodontic treatment and TMJ, verifying if orthodontic treatment causes changes in the internal structures of TMJ. **Methods:** Survey in research bases MEDLINE, Cochrane, EMBASE, Pubmed, Lilacs and BBO, between the years of 1966 and 2009, with focus in randomized clinical trials, longitudinal prospective nonrandomized studies, systematic reviews and meta-analysis. **Results:** After application of the inclusion criteria 14 articles were selected, 2 were randomized clinical trials and 12 longitudinal nonrandomized studies. **Conclusions:** According to the literature analysis, the data concludes that orthodontic treatment does not occur at the expense of unphysiological disc-condyle position. Some orthodontic mechanics may cause remodeling of articular bone components.

**Keywords:** Temporomandibular joint. Temporomandibular joint dysfunction syndrome. Temporomandibular joint disorders. Orthodontics. Magnetic resonance imaging. Tomography.

**How to cite this article:** Machado E, Grehs RA, Cunali PA. Imaging from temporomandibular joint during orthodontic treatment: a systematic review. Dental Press J Orthod. 2011 May-June;16(3):54.e1-7.

\* Specialist in TMD and Orofacial Pain, UFPR. Graduate in Dentistry, UFSM.

\*\* PhD in Orthodontics and Dentofacial Orthopedics, UNESP/Araraquara – SP. Professor of Graduate and Post-graduate Dentistry course, UFSM.

\*\*\* PhD in Sciences, UNIFESP. Professor of Graduate and Post-graduate Dentistry course, UFPR. Head of the Specialization Course in TMD and Orofacial Pain, UFPR.

## INTRODUCTION

The effects of orthodontic treatment on Temporomandibular Joint (TMJ) are still subject to doubts and discussions. The use of complementary exams has always been a constant in the evaluation of this interrelation and can be exemplified by conventional radiographic examinations that were widely used to assess the implications of orthodontic treatment on the TMJ. However, this modality of imaging examination has limitations, because the TMJ is one of the structures of the human body more difficult to be well visualized radiographically due to overlapping of several adjacent bony structures. Thus, the effects of orthodontics on TMJ structures are still controversial.

With the advent of imaging examinations with specificity, sensitivity and greater accuracy in the reproduction of articular anatomic structures, such as magnetic resonance imaging (MRI), computed tomography and cone-beam volumetric computed tomography as well as 3D reconstruction methods, this interrelationship can be evaluated with greater exactness. Added to this fact, there was accomplishment of clinical studies with designs and more rigorous methodological criteria, generating higher levels of evidence.

Thus, the general aim of this study, through a systematic literature review was to analyze within a context of a scientific evidence based dentistry, the implications of orthodontics to the TMJ and check specifically what changes in condylar and articular disc position and joint morphological changes that occur due to orthodontic treatment.

## MATERIAL AND METHODS

We performed a computerized search in MEDLINE, Cochrane, EMBASE, PubMed, Lilacs and BBO in the period from 1966 through February 2009. The research descriptors used were “orthodontics”, “orthodontic treatment”, “temporomandibular disorder”, “temporomandibular joint”, “cranio-mandibular disorder”, “TMD”, “TMJ”, “magnetic

resonance imaging” and “tomography”, which were crossed in search engines. The initial list of articles was submitted to review by two reviewers, who applied inclusion criteria to determine the final sample of articles, which were assessed by their title and abstract. If there was any disagreement between the results of the reviewers, a third reviewer would be consulted by reading the full version of the article.

Inclusion criteria for selecting articles were:

- » Studies based on magnetic resonance imaging (MRI), computed tomography (CT) and/or volumetric cone-beam tomography, which assessed the effects of orthodontic treatment in TMJ. Studies based only on electromyography, cephalometric radiographs and conventional radiographs were excluded, as well as studies involving orthognathic surgery.
- » Randomized clinical trials (RCT), non-randomized prospective longitudinal studies, systematic reviews and meta-analysis.
- » Studies in which orthodontic treatment is already completed in the assessed samples.
- » Studies written in English and Spanish, and published between 1966 and February 2009.

Thus, we excluded cross-sectional studies, clinical case reports, case series, simple reviews and opinions papers, as well as studies in which orthodontic treatment had not yet been completed.

## RESULTS

After applying the inclusion criteria 14 studies were selected and the Kappa index of agreement between reviewers was 1.00. Among these studies, two were randomized clinical trials and 12 were longitudinal studies without randomization criteria (Fig 1).

Among the selected studies, 11 were based on magnetic resonance imaging and 3 in computed tomography images, as shown in Figure 2. None of the selected studies used cone-beam computed tomography for evaluation of the TMJ.

The sample of articles selected by the methodological criteria of this systematic review is available in Table 1.

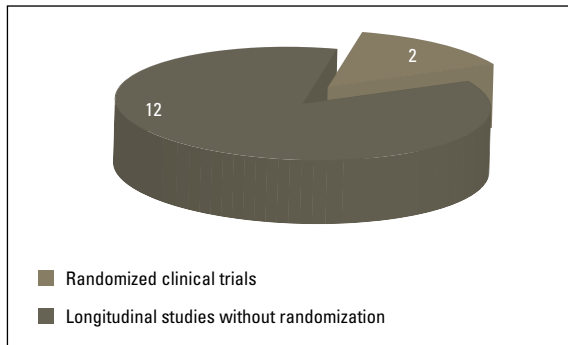


FIGURE 1 - Design of included studies.

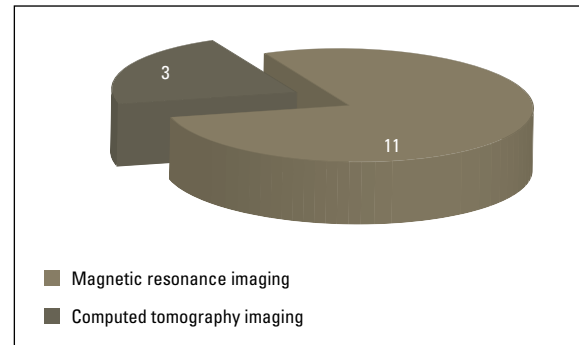


FIGURE 2 - Studies characteristics.

TABLE 1 - Studies based on imaging examination of magnetic resonance imaging, computed tomography and/or cone-beam computed tomography.

Authors	Year of publication	Design	Sample size	Imaging Examinations	Orthodontic Appliance Used	Changes in TMJ
Major et al. <sup>23</sup>	1997	P, L	35 tt	CT	F	Increase in An JS
Ruf, Pancherz <sup>26</sup>	1998	P, L	15 tt	MRI	Herbst	Remodeling of condylar and glenoid fossa
Ruf, Pancherz <sup>27</sup>	1999	P, L	39 tt	MRI	Herbst	Remodeling of condylar and glenoid fossa
Carlton, Nanda <sup>6</sup>	2002	P, L	106 tt	CT	F, FA	No adverse effects
Franco et al. <sup>9</sup>	2002	RCT	28 tt 28 no tt	MRI	FA	No adverse effects
Gokalp, Kurt <sup>12</sup>	2005	P, L	13 tt 7 no tt	MRI	CC	Condylar remodeling
Kinzinger et al. <sup>21</sup>	2006	P, L	20 tt	MRI	FA	No adverse effects
Kinzinger et al. <sup>22</sup>	2006	P, L	20 tt	MRI	FA	No adverse effects
Kinzinger et al. <sup>19</sup>	2006	P, L	15 tt	MRI	FA	No adverse effects
Kinzinger et al. <sup>20</sup>	2007	P, L	20 tt	MRI	FA	No adverse effects
Arici et al. <sup>3</sup>	2008	RCT	30 tt 30 no tt	CT	FA	Changes in An and Po joint spaces
Arat et al. <sup>1</sup>	2008	P, L	18 tt	MRI	F (RME)	No adverse effects
Arat et al. <sup>2</sup>	2008	P, L	18 tt	MRI	F (RME)	No adverse effects
Wadhawan et al. <sup>30</sup>	2008	P, L	12 tt	MRI	F, FA	No adverse effects

P= prospective; L= longitudinal; RCT= randomized clinical trial; tt= treatment; MRI= magnetic resonance imaging; CT= computed tomography; F= fixed appliances; FA= functional appliances; CC= chin cup; JS= joint space; An= anterior; Po= posterior; RME= rapid maxillary expansion.

## DISCUSSION

It becomes increasingly important to analyze the current literature in a critical and rigorous way to verify what level of scientific evidence that the information generates. The application of methodological considerations for research — such as sample size calculation, randomization, calibration, blinding and control of involved factors — are extremely important to qualify the level of evidence generated. And this information must be available for examination and discussion for the reader.<sup>28</sup>

Currently, the access to scientific evidences is available through many different ways. Because of this facility, the knowledge about the hierarchy of the scientific evidence levels is essential for assessing the quality of the study. Thus, meta-analysis, systematic reviews and randomized clinical trials receive the best concepts. Being aware of this fact is important, since the vast majority of articles published in Brazilian journals correspond to studies of low potential for direct clinical application.

Magnetic resonance imaging and computed tomography are methods with higher diagnostic accuracy compared with conventional radiology, because of greater anatomic resolution they provide. CT is the ideal method for assessment of bone structures, whereas MRI allows the study of soft tissues, including intra-articular disc. Both methods often complement the study of abnormalities of the temporomandibular joint (TMJ), thus becoming important tools in the differential diagnosis of various diseases in this region.<sup>11</sup>

Computed tomography is the examination of choice to evaluate TMJ bony structures, especially for the diagnosis of fractures, joint deformities, ankylosis and tumors. There is no overlapping of any other structure, enabling assessment of the quality and bone density.<sup>5</sup> Similarly, MRI is the gold standard for the representation of soft tissue and positioning of the TMJ articular disc,<sup>17</sup> allowing information about the position, function and form of the articular disc and conditions of muscle tissues

and ligaments, as well as assessment of severity of various disorders: trauma, arthritis, arthrosis and neoplastic degeneration.<sup>10</sup>

Also, the cone-beam computed tomography allows visualization of structures of reduced dimensions with minimal radiation exposure for patients and less operating time than conventional CT. This imaging modality has several applications, assisting in the diagnosis and in the treatment plan in different dental specialties.<sup>29</sup> The cone-beam tomography has a relevant importance in diagnosis, localization and reconstruction of tomographic images with excellent precision, aiding in therapeutic decisions.<sup>4</sup>

Clinically, the scientific evidences indicate for a tendency of no association between orthodontic treatment and temporomandibular disorders (TMD), in other words, orthodontics does not increase the prevalence of signs and symptoms of TMD, with longitudinal and experimental-interventionist studies,<sup>7,8,13-16,25</sup> systematic review<sup>24</sup> and meta-analysis<sup>18</sup> corroborating that. Also, with the analysis of imaging studies, according to the methodological criteria adopted by this systematic review, it appears that orthodontic movement does not cause adverse effects to the TMJ.<sup>6,9,19-22</sup>

The systematic literature review shows that the correct occlusal relationship between the teeth did not cause a change in the physiological position of the condyles and articular discs in TMJ when MRI and CT were examined,<sup>19,21,22</sup> whereas in some cases of TMD an improvement can be obtained as a result of orthodontic treatment.<sup>9,19,22</sup> Some studies found changes in condylar position<sup>3</sup> and in the volumes of the anterior and posterior joint spaces<sup>3,23</sup> due to applied orthodontic mechanics. Furthermore, the use of the chincup caused a morphological change in condylar growth, which may be associated with correction of skeletal malocclusion in conjunction with remodeling in the jaw,<sup>12</sup> as well as the Herbst appliance.<sup>26,27</sup>

The application of different orthodontic mechanics did not cause incorrect positioning on the articular disc-condyle relationship. Elastics mechanics,<sup>6,23</sup> headgear,<sup>6</sup> rapid maxillary expansion,<sup>1,2</sup> Frankel functional appliance,<sup>9</sup> Bionator,<sup>30</sup> fixed functional orthopedic appliances,<sup>20,21,22</sup> Twin Block<sup>30</sup> and functional mandibular advancement appliance<sup>19</sup> did not cause physiological changes in the positioning of the condyle and articular disc, whereas the implementation or not of extraction protocols did not change this situation.<sup>6,23</sup>

Great provider of scientific evidence, randomized clinical trials were found in low number in this systematic review: only two studies.<sup>3,9</sup> This fact is associated with difficulties in accomplishment of this type of study in patients undergoing orthodontic treatment due to ethical and practical questions.<sup>18</sup> Likewise, there

were no selected meta-analysis and systematic reviews after application of the inclusion criteria. It is important to be noted that all the selected studies presented longitudinal assessments, which is the ideal study design to check for risk factors, due to its temporal component.<sup>28</sup>

The use of imaging examinations — CT, cone-beam CT and MRI — in orthodontic practice, not only for evaluating the occlusal criteria, but also for adjacent structures, tends to become a useful tool. Through 3D reconstruction of the surfaces of condyle and their overlaps, detailed views of adaptive mechanisms and its non-invasive assessment may become possible in routine clinical orthodontics.<sup>20</sup> Through these examinations modalities, allied to scientific knowledge, diagnosis and therapeutic decision can be guided and based on scientific evidence, in order to provide most appropriate and safe treatment for patient.

## CONCLUSIONS

- » This systematic literature review finds that the correct occlusal relationship as a result of orthodontic treatment is not obtained at the expense of non-physiological positioning of both the condyle and the articular disc. Thus, when orthodontics is used correctly does not cause adverse effects in the TMJ.
- » The application of forces during certain orthodontic mechanics, especially orthopedic situations, can cause alterations in condylar growth and bone structures of the TMJ. Thus, the mechanics application should be performed properly and the professional

must have knowledge of these impacts.

- » In some studies by analysis of imaging examinations, it was observed that there were improvements in situations of pre-existing TMD at the beginning of orthodontic therapy. However, these data are only suggestive and more randomized clinical trials are necessary to obtain more precise conclusions.
- » Further randomized controlled clinical trials, with longitudinal and interventional nature are necessary, for the determination of more precise causal associations, within a context of a scientific evidence based dentistry.

## REFERENCES

1. Arat FE, Arat ZM, Tompson B, Tanju S, Erden I. Muscular and condylar response to rapid maxillary expansion. Part 2: magnetic resonance imaging study of the temporomandibular joint. *Am J Orthod Dentofacial Orthop.* 2008;133(6 Pt 2):823-9.
2. Arat FE, Arat ZM, Tompson B, Tanju S. Muscular and condylar response to rapid maxillary expansion. Part 3: magnetic resonance assessment of condyle-disc relationship. *Am J Orthod Dentofacial Orthop.* 2008;133(6 Pt 3):830-6.
3. Arici S, Akan H, Yakubov K, Arici N. Effects of fixed functional appliance treatment on the temporomandibular joint. *Am J Orthod Dentofacial Orthop.* 2008;133(6):809-14.
4. Bissoli CF, Ágre da CG, Takeshita WM, Castilho JCM, Medici Filho E, Moraes ML. Importancia y aplicaciones del sistema de tomografía computarizada cone-beam (cbct). *Acta Odontol Venez.* 2007;45(4):589-92.
5. Bumann A, Lotzmann U. Disfunção temporomandibular: diagnóstico funcional e princípios terapêuticos. Porto Alegre: Artmed; 2003.
6. Carlton KL, Nanda RS. Prospective study of posttreatment changes in the temporomandibular joint. *Am J Orthod Dentofacial Orthop.* 2002;122(5):486-90.
7. Egermark I, Carlsson GE, Magnusson T. A prospective long-term study of signs and symptoms of temporomandibular disorders in patients who received orthodontic treatment in childhood. *Angle Orthod.* 2005;75(4):645-50.
8. Egermark I, Magnusson T, Carlsson GE. A 20-year follow-up of signs and symptoms of temporomandibular disorders and malocclusions in subjects with and without orthodontic treatment in childhood. *Angle Orthod.* 2003;73(2):109-15.
9. Franco AA, Yamashita HK, Lederman HM, Cevidanes LH, Proffit WR, Vigorito JW. Fränkel appliance therapy and the temporomandibular disc: a prospective magnetic resonance imaging study. *Am J Orthod Dentofacial Orthop.* 2002;121(5):447-57.
10. Freitas A. Radiologia odontológica. 6ª ed. São Paulo: Artes Médicas; 2004.
11. Garcia MM, Machado KFS, Mascarenhas MH. Ressonância magnética e tomografia computadorizada da articulação temporomandibular: além da disfunção. *Radiol Bras.* 2008;41(5):337-42.
12. Gokalp H, Kurt G. Magnetic resonance imaging of the condylar growth pattern and disk position after chin cup therapy: a preliminary study. *Angle Orthod.* 2005;75(4):568-75.

13. Henrikson T, Nilner M. Temporomandibular disorders and need of stomatognathic treatment in orthodontically treated and untreated girls. *Eur J Orthod.* 2000;22(3):283-92.
14. Henrikson T, Nilner M. Temporomandibular disorders, occlusion and orthodontic treatment. *J Orthod.* 2003;30(2):129-37.
15. Henrikson T, Nilner M, Kurol J. Symptoms and signs of temporomandibular disorders before, during and after orthodontic treatment. *Swed Dent J.* 1999;23(5-6):193-207.
16. Imai T, Okamoto T, Kaneko T, Umeda K, Yamamoto T, Nakamura S. Long-term follow-up of clinical symptoms in TMD patients who underwent occlusal reconstruction by orthodontic treatment. *Eur J Orthod.* 2000;22(1):61-7.
17. Kamelchuk L, Nebbe B, Baker C, Major P. Adolescent TMJ tomography and magnetic resonance imaging: a comparative analysis. *J Orofac Pain.* 1997;11(4):321-7.
18. Kim MR, Graber TM, Viana MA. Orthodontics and temporomandibular disorder: a meta-analysis. *Am J Orthod Dentofacial Orthop.* 2002;121(5):438-46.
19. Kinzinger G, Gulden N, Roth A, Diedrich P. Disc-condyle relationships during Class II treatment with the Functional Mandibular Advancer (FMA). *J Orofac Orthop.* 2006;67(5):356-75.
20. Kinzinger G, Kober C, Diedrich P. Topography and morphology of the mandibular condyle during fixed functional orthopedic treatment: a magnetic resonance imaging study. *J Orofac Orthop.* 2007;68(2):124-47.
21. Kinzinger G, Roth A, Gulden N, Bucker A, Diedrich P. Effects of orthodontic treatment with fixed functional orthopaedic appliances on the condyle-fossa relationship in the temporomandibular joint: a magnetic resonance imaging study (Part I). *Dentomaxillofac Radiol.* 2006;35(5 Pt 1):339-46.
22. Kinzinger G, Roth A, Gulden N, Bucker A, Diedrich P. Effects of orthodontic treatment with fixed functional orthopaedic appliances on the disc-condyle relationship in the temporomandibular joint: a magnetic resonance imaging study (Part II). *Dentomaxillofac Radiol.* 2006;35(5 Pt 2):347-56.
23. Major P, Kamelchuk L, Nebbe B, Petrkowski G, Glover K. Condyle displacement associated with premolar extraction and nonextraction orthodontic treatment of Class I malocclusion. *Am J Orthod Dentofacial Orthop.* 1997;112(4):435-40.
24. Mohlin B, Axelsson S, Paulin G, Pietila T, Bondemark L, Brattstrom V, et al. TMD in relation to malocclusion and orthodontic treatment. *Angle Orthod.* 2007;77(3):542-8.
25. Mohlin BO, Derweduwen K, Pilley R, Kingdon A, Shaw WC, Kenealy P. Malocclusion and temporomandibular disorder: a comparison of adolescents with moderate to severe dysfunction with those without signs and symptoms of temporomandibular disorder and their further development to 30 years of age. *Angle Orthod.* 2004;74(3):319-27.
26. Ruf S, Pancherz H. Temporomandibular joint growth adaptation in Herbst treatment: a prospective magnetic resonance imaging and cephalometric roentgenographic study. *Eur J Orthod.* 1998;20(4):375-88.
27. Ruf S, Pancherz H. Temporomandibular joint remodeling in adolescents and young adults during Herbst treatment: a prospective longitudinal magnetic resonance imaging and cephalometric radiographic investigation. *Am J Orthod Dentofacial Orthop.* 1999;115(6):607-18.
28. Susin C, Rosing CK. *Praticando odontologia baseada em evidências.* 1ª ed. Canoas: ULBRA; 1999.
29. Xaves ACC, Sena LEC, Araújo LF, Nascimento Neto JBS. Aplicações da tomografia computadorizada de feixe cônico na odontologia. *Int J Dent.* 2005;4(3):80-124.
30. Wadhawan N, Kumar S, Kharbanda OP, Duggal R, Sharma R. Temporomandibular joint adaptations following two-phase therapy: an MRI study. *Orthod Craniofac Res.* 2008;11(4):235-50.

Submitted: February 2009  
 Revised and accepted: May 2010

#### Contact address

Eduardo Machado  
 Rua Francisco Trevisan 20, Nossa Sra. de Lourdes  
 CEP: 97.050-230 - Santa Maria / RS, Brazil  
 E-mail: machado.rs@bol.com.br