

Brazilian Board of Orthodontics and Facial Orthopedics: Certifying excellence

Roberto M. A. Lima Filho*, Carlos Jorge Vogel**, Estélio Zen***, Ana Maria Bolognese****, José Nelson Mucha*****, Telma Martins de Araújo*****

Abstract

The Brazilian Board of Orthodontics and Facial Orthopedics (BBO) is the institution that certifies the standards of clinical excellence in the practice of this specialty. This article describes the history of BBO's creation and the examination structure and phases to obtain the BBO Certification. It also presents a detailed report of the first exam applied in Brazil. Its purpose is to expand the knowledge, among professionals in the area, about the importance of BBO Certification as assurance of the highest level of quality in orthodontic treatments.

Keywords: Examination. Certification. Orthodontics.

The advances in medical sciences in the beginning of the 20th century positively affected the practice of specialties. Although such advances promoted improvements in service quality, there was no system to ensure, for the patient, that the professional that advertised as a specialist was actually qualified. Therefore, in 1908, Derrick T. Vail, then President of the American Academy of Ophthalmology and Otolaryngology, came up with the concept of a Board for specialties in health care.¹ Essentially, a Board evaluates the knowledge and clinical skills of professionals in a certain specialty. In May 1916, the pioneering American Board of Ophthalmic Examination was founded.

Since then, this new concept extended to other specialties. In dentistry, orthodontics was the first to establish its Board. In July 1929, during the 28th Conference of the American Society of Orthodontics in the USA, the American Board of Orthodontics (ABO) was founded.² In 1950, the Council on Dental Education of the American Dental Association (ADA) recognized the ABO as the official certifying agency for excellence in orthodontics.³

In Brazil, the idea of creating a Board was also born from the need to promote the achievement of clinical excellence standards in the practice of orthodontics. In 1998, the Brazilian Association of Orthodontics and Facial Orthopedics (ABOR),

How to cite this article: Lima Filho RMA, Vogel CJ, Zen E, Bolognese AM, Mucha JN, Araújo TM. Brazilian Board of Orthodontics and Facial Orthopedics: Certifying excellence. *Dental Press J Orthod.* 2011 July-Aug;16(4):148-57.

» The authors report no commercial, proprietary, or financial interest in the products or companies described in this article.

- * Post Graduate Degree in Orthodontics, University of Illinois at Chicago. MSc and PhD in Orthodontics, Federal University of Rio de Janeiro, Rio de Janeiro, Brazil (UFRJ). Diplomate of the American Board of Orthodontics. Former President of the Brazilian Board of Orthodontics and Facial Orthopedics (BBO).
- ** MSc, University of Illinois, Chicago, USA. PhD in Orthodontics, University of São Paulo (USP), São Paulo, Brazil. Member of the Angle Society of Orthodontics. Former President of the Brazilian Board of Orthodontics and Facial Orthopedics (BBO).
- *** Post Graduate Degree in Orthodontics, UFRJ. MSc in Orthodontics, UFRJ. Former President of the Brazilian Board of Orthodontics and Facial Orthopedics (BBO).
- **** MSc and PhD in Orthodontics, UFRJ. Specialist Degree in Radiology, UFRJ. Full Professor, Orthodontics, UFRJ. Former President of the Brazilian Board of Orthodontics and Facial Orthopedics (BBO).
- ***** MSc and PhD in Dentistry, UFRJ. Specialist Degree in Radiology, UFRJ. Full Professor, Orthodontics, Fluminense Federal University (UFF), Rio de Janeiro, Brazil. Former President of the Brazilian Board of Orthodontics and Facial Orthopedics (BBO).
- ***** MSc and PhD in Orthodontics, UFRJ. Full Professor and Head of the Orthodontic Center "Professor José Édimo Soares Martins", Federal University of Bahia, Salvador, Brazil. Specialist Degree in Radiology, UFRJ. Former President of the Brazilian Board of Orthodontics and Facial Orthopedics (BBO).

presided by Eros Petrelli, established a Special Committee, whose members were Kurt Faltin Jr., Roberto Mario Amaral Lima Filho and Airton O. Arruda. In 1999, during the 2nd ABOR Meeting, a project to create the Brazilian Board was discussed and evaluated during the ABOR Council Meeting, and its principles were approved by all council members.

In May 2000, members of the ABOR Special Committee participated in a meeting of the ABO in Chicago, USA, to learn about the operations of the American Board. The event was directed to countries interested in the implementation of a certification system. The essential resources to operate a Board were available and provided by the ABO Directors. The Brazilian Committee established contacts to learn about the mechanisms necessary to establish the Brazilian Board and received full support and promises of effective assistance. The material resulting from this meeting was presented in an extraordinary meeting of the ABOR during the Orto Rio Premium Conference in Rio de Janeiro in July 2000.

The professionals appointed to participate in the first Brazilian Board were: Roberto Mário Amaral Lima Filho, Carlos Jorge Vogel, Francisco Damico, Estélio Zen, Anna Letícia Lima, Ana Maria Bolognese, José Nelson Mucha and Telma Martins de Araújo. The legitimacy to hold those positions was obtained in examinations applied during the 101st Meeting of the American Association of Orthodontics (AAO) held in Toronto, Canada, on May 7, 2001. On that occasion, the members of the group were examined by Dr. Jack Dale and Dr. Eldon Bills, former ABO presidents.

The Brazilian Board of Orthodontics and Facial Orthopedics (BBO) was founded on September 2, 2002, in São Paulo. The founding members were Roberto Mário Amaral Lima Filho, Carlos Jorge Vogel, Estélio Zen, Ana Maria Bolognese, José Nelson Mucha and Telma Martins de Araújo, who also participated on the first Board of Directors.

Similarly to what occurred in the United States, the BBO had a pioneering role in health care in Brazil and acted as an exemplary model for other specialties in dentistry and medicine.

The BBO Board of Directors has eight members: President; President-elect; Secretary; Treasurer; 1st Director; 2nd Director; 3rd Director; and 4th Director. The Directors serve one-year terms. After that, the President leaves his position, becomes a member of the group of former presidents and retains membership. The President-elect then becomes President and, sequentially, the other members are appointed to the immediately higher position. The 4th Director position becomes vacant and, on the same date, a new member for that position is elected by the General Assembly. This model gives the members the chance to become familiar with all the institutional structures and prepares and motivates the Directors acting in the different positions.

The candidates to obtain the certification as "Diplomate of the Brazilian Board of Orthodontics and Facial Orthopedics" are evaluated in the areas of diagnosis, treatment planning and knowledge about different aspects of orthodontic treatments. The examinations provide a unique opportunity for candidates to review their practices, reflect about the importance of carefully maintaining quality records, of mechanical control in performing the treatment and of the attention to the final treatment phase.

To ensure the continuous professional qualification and recycle his or her clinical skills and scientific knowledge, the BBO diplomate must undergo periodic revalidation of the Certificate of Excellence.

Another relevant aspect of the certification is professional ethics. The professionals that decide to seek certification are moved by an ideal and dedication to their profession. Being granted is indicative of determination and merit. However, the certificate issued by the

Board does not grant any professional license or academic degree. It is a certificate of excellence and, therefore, does not confer any privileges in the practice of orthodontics. The best definition of the feelings of professionals that seek certifications came from the American orthodontist George Ewans: "The title conferred by the Board will not make you better than others, but it will definitely make you better than before."

Symbols

The BBO logo was developed using a classical lettering style, which conferred a traditional character to this symbol, compatible with the status of an agency that certifies professional excellence. The figure that accompanies the lettering suggests smoothness and stands for the concept of non-traumatic correction: a plant shoot being guided to grow up. As an analogy, this image refers to the aim of our profession (orthodontic correction), to the professional practice per se and the educational guidelines in the area. The colors are references to the Brazilian flag. The seal has the traditional shape of a stamp, and keeps the logo in an outstanding position. This logo is also printed on the lapel pin that all Diplomates receive when certification is granted (Fig 1).

Examination

The BBO certification examination has two phases. Phase 1 is the evaluation of the diagnosis and planning of cases presented by the BBO; phase 2, the presentation of ten cases treated by the candidate.⁴ The cases presented in phase 2 should meet the following criteria: 1) Angle Class II or III malocclusion treated without extractions and with growth control; 2) Angle Class I malocclusion treated with extractions of permanent teeth; 3) Angle Class II malocclusion treated with extractions of permanent teeth; 4) Malocclusion with marked anteroposterior discrepancy: Angle Class III relationship and ANB angle equal to or smaller than -2 degrees; Angle Class II relationship and ANB angle equal to or greater than 5 degrees; 5) Malocclusion with transverse discrepancy and at least one quadrant with crossbite; 6) Malocclusion and marked overbite; 7 to 10) free choice.

Orthodontic records

Good quality orthodontic records are essential for an accurate diagnosis, which is, in turn, key to the success of orthodontic treatment. Records should be identified using letters and colors: A – beginning of the treatment (black); A1, A2 – intermediate (blue); B – end of treatment (red); and C – post treatment (green). The records for



FIGURE 1 - BBO symbols: A) Logo; B) Seal and C) Lapel pin.

the end of treatment (B) may be obtained up to one year after the appliance is removed.

To ensure that evaluations are uniform and balanced, records should be standardized. The cases submitted should include dental casts, radiographs and photographs. The requisites for dental cast trimming and the cephalometric evaluation (tracing, angles, linear measures and superimpositions) follow international norms for case presentations and are available in the BBO website.

Dental casts

Casts should accurately reproduce dental arches and the buccal area to serve as accurate models of the malocclusion. The casts should be trimmed to maximum intercuspation, as shown in Figure 2.⁵

Adjustments or trimming in the anatomic portion (teeth and buccal area) of the casts should

be limited to removing bubbles and small flaws. Changes in tooth anatomy are considered adulterations, which will lead to the automatic rejection of the case. Dental casts must be polished so that all anatomic details are preserved (Fig 3). When preparing casts for cases in which it is not possible to use the recommended heights and angles, symmetry, proportion and esthetics should be taken into consideration.

Radiographs

Panoramic, periapical and supplemental radiographs should be of good quality. The films should be accurately oriented, and the right and left sides should be marked. Panoramic radiographs without a satisfactory definition in the incisor areas (maxillary and mandibular) should be accompanied by periapical radiographs of these areas (Fig 4).

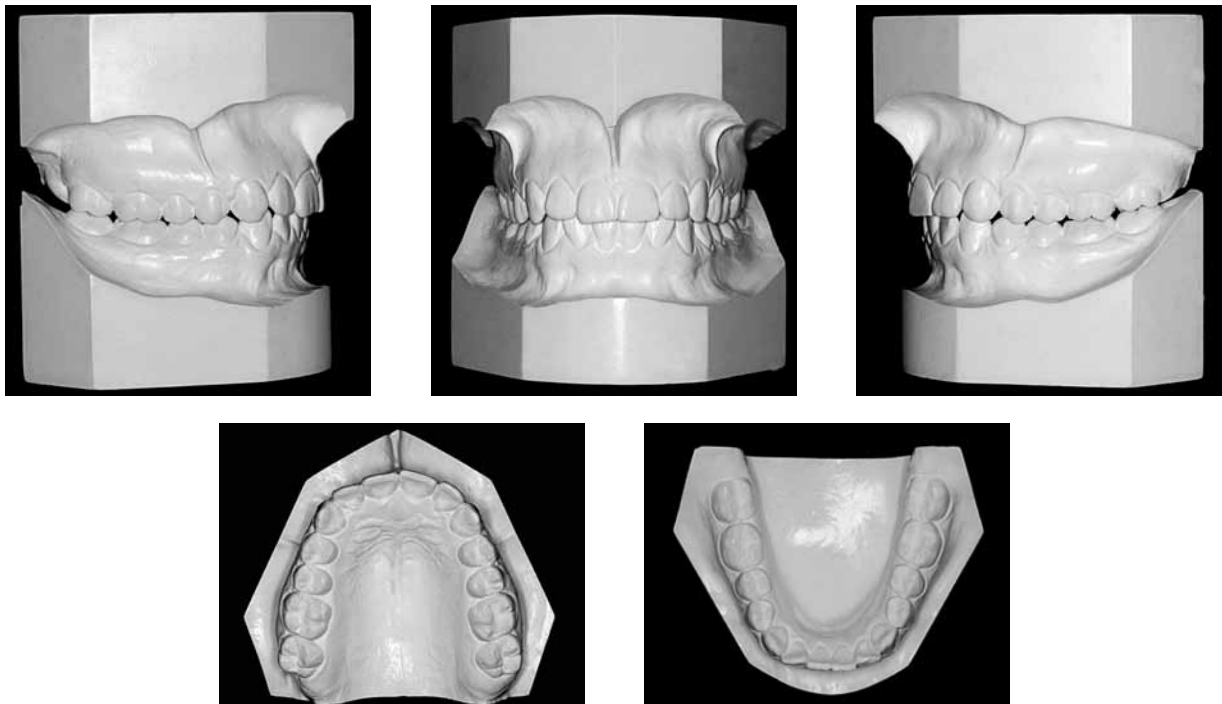


FIGURE 2 - Initial dental casts of Class II malocclusion case, accurately trimmed.⁵

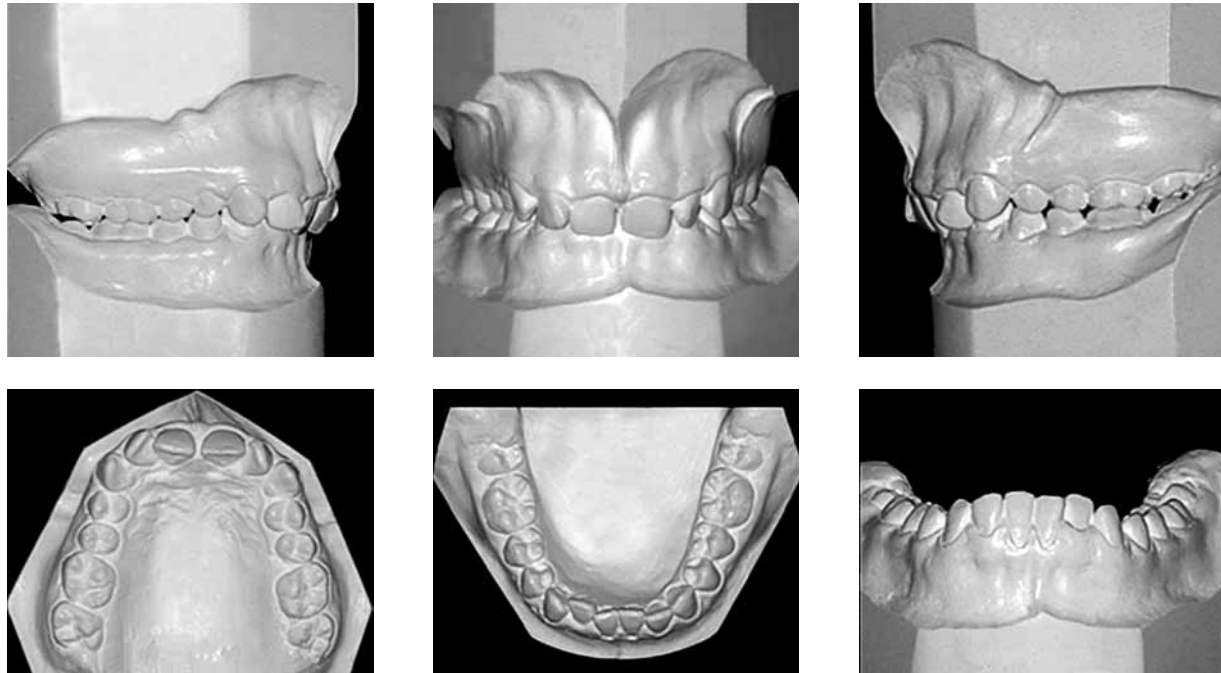


FIGURE 3 - Polished casts with preserved details and accurate reproduction of malocclusion.

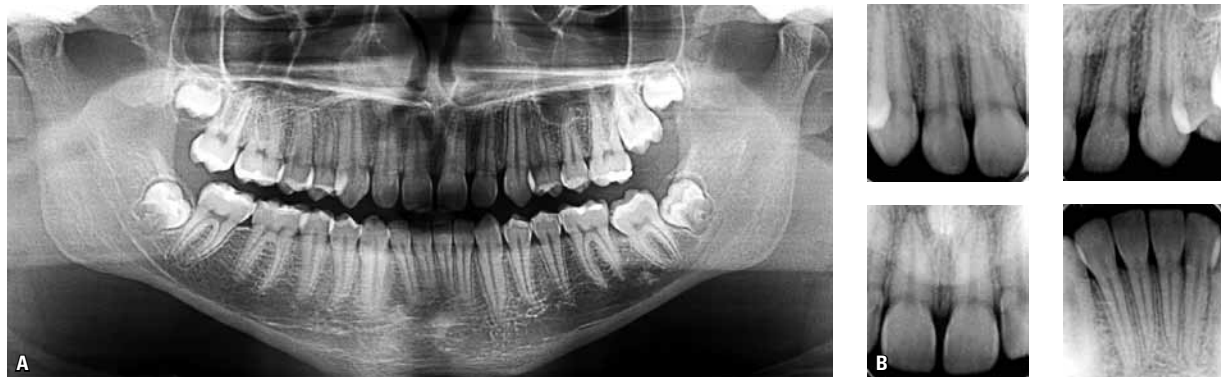

FIGURE 4 - Panoramic radiograph (A) and periapical radiograph of maxillary and mandibular incisors (B).

Lateral cephalometric radiographs should be properly standardized, and bone and soft tissue profiles should be clearly visible. In cases of evident facial asymmetry posteroanterior cephalograms should be properly examined and submitted in addition to profile cephalograms (Fig 5). To preserve anonymity, the names of the radiology service and of the dentist should be blacked out.

The patient's name and the radiograph date should be visible.

Cephalograms should be carefully hand-traced by the examinee on tracing acetate using a 0.5-mm diameter pen or pencil. They should contain only the anatomic details of interest for clinical analysis and cephalometric superimpositions (Fig 6). Computer-generated tracings are

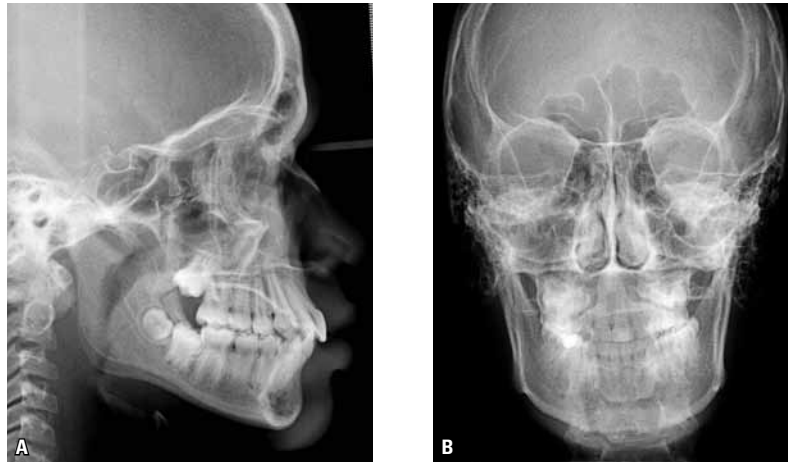


FIGURE 5 - Lateral (A) and posteroanterior (B) cephalometric radiographs.

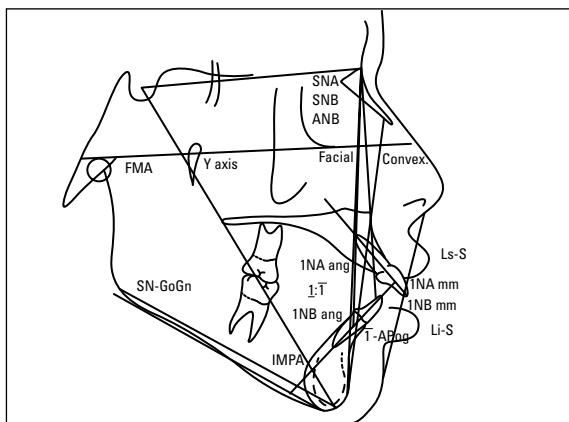


FIGURE 6 - Cephalometric tracing with reference lines and indication of places where measurements should be included.

not accepted. Templates may be used to trace tooth outlines. Cephalometric landmarks should be carefully identified to ensure reliability of the reference lines drawn.

The examinee should be familiar with all aspects of cephalograms, tracings and measurements, as well as their meanings. Tracings should be separated from the lateral radiographs and placed in the plastic envelopes found in the folders.

At least three tracing superimpositions are required: Total or craniofacial, to evaluate general changes during growth and/or treatment; and partial, maxillary and mandibular, to demonstrate dental changes in the maxilla and mandible and their

respective supporting bones. Total superimpositions may be prepared using one of two methods (Fig. 7): (a) Plane of the sphenoid bone and ethmoid cribriform plate, registered on the midpoint between the wings of the sphenoid bone; and (b) the sella-nasion plane, registered on sella. Partial superimpositions should be prepared as follows (Fig 8): Maxilla – best fit of the maxillary bony complex, registered on the palatal curve; mandible – best superimposition in the lower limit of the cortical bone of the mandibular body, registered on the internal cortical outline of the symphysis.

The three superimpositions should be hand-traced by the examinee using pen or pencil. In cases of treatments with intermediate tracings, superimpositions should be presented as follows: A-A1 (beginning–intermediate), A1-B (intermediate–final) and A-B (beginning–final). Cases with post-treatment records should include A-B-C (beginning–final–post-treatment). Superimpositions should be arranged on white paper, but not fixed to it, and placed into separate envelopes. In cases treated with orthognathic surgery, presurgical intermediate tracings should be included.

Photographs

Patient records should include the following face photographs: (a) Frontal; (b) Right lateral profile;

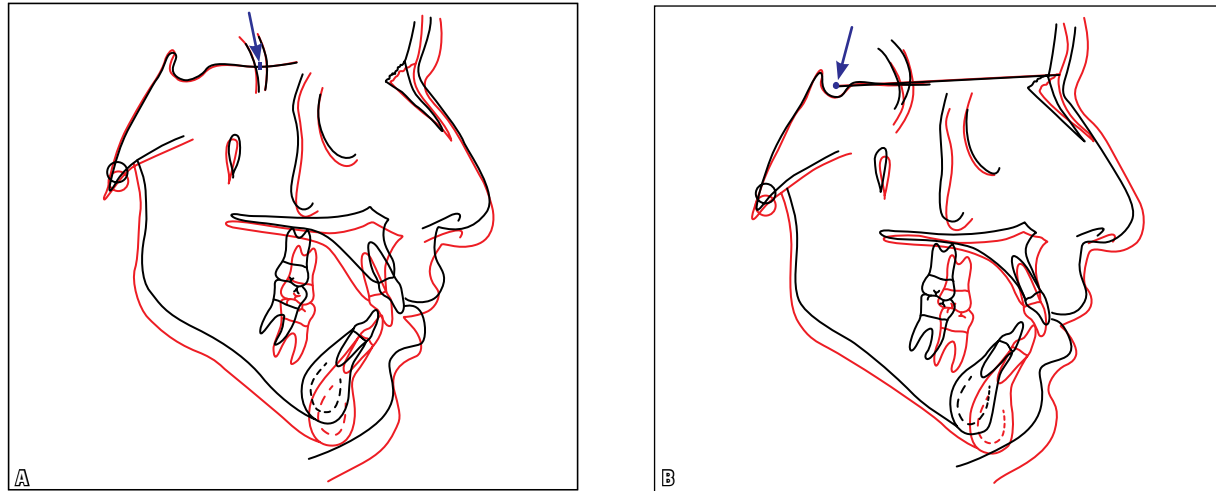


FIGURE 7 - Total superimpositions: **A)** Plane of the sphenoid bone and ethmoid cribriform plate, registered on the midpoint between the wings of the sphenoid bone; **B)** the Sella-Nasion line, registered on Sella.

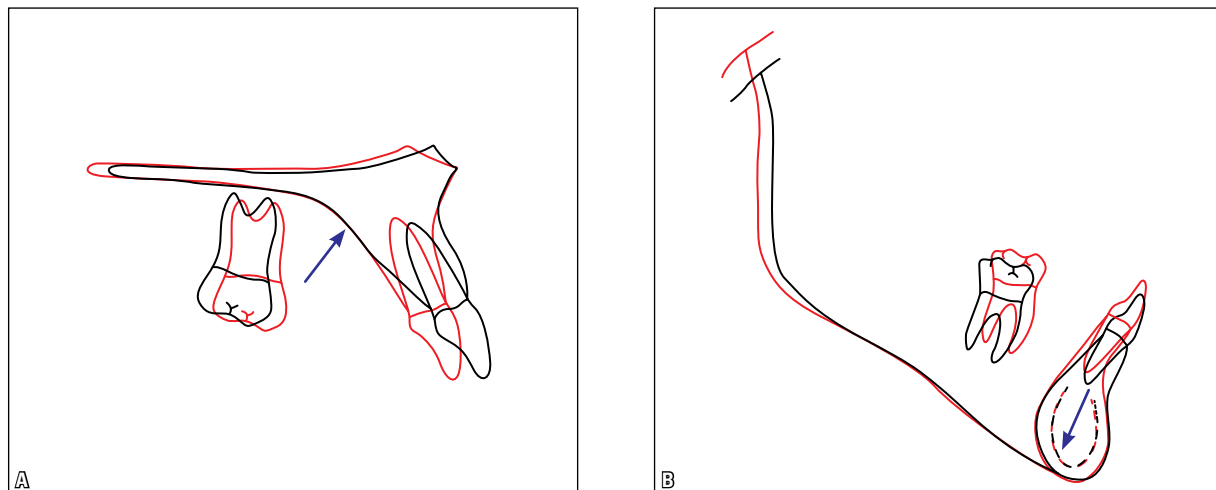


FIGURE 8 - Partial superimpositions: **A)** Maxilla – best fit of the maxillary bony complex, registered on the palatal curve; **B)** Mandible – best superimposition in the lower limit of the cortical bone of the mandibular body, registered on the internal cortical outline of the symphysis.

and (c) whenever possible, a frontal smile photograph. These photographs should be oriented to Frankfort horizontal, and the line between the pupils should be parallel to the ground. They should be taken with relaxed lips and depict the patient's actual labial relationship.

The background should be neutral, preferably white; good-quality lighting should reveal facial contours without shadows; the ears should be visible for

purposes of orientation; the eyes should be open and looking straight ahead; glasses and other accessories should be removed.

In addition to facial photographs, each case should include at least three intraoral records: a frontal view, a right lateral view, and a left lateral view, all with teeth in maximum intercuspation. These photographs should be oriented to the occlusal plane. Optional photographs may be included,

such as occlusal views of the maxillary and mandibular dental arches. Photographs should be as close as possible to a 1:1 ratio with the patient's teeth. If mirror images are used, they should be printed vertically flipped. Attention should be paid to a few other aspects: clean teeth, free of bacterial biofilm, bleeding or saliva; cheek retractors; adequate lighting to show anatomic contours, completely free of shadows; standardized colors; no visual distractions (cheek retractors, labels, fingers).

If the facial and intraoral images are computer generated, their resolution should be high, and

they should accurately demonstrate soft and hard tissues. Photographs may be printed in color to achieve the best possible framing, using the landscape layout and printing them on glossy photo paper. The examinees should keep in mind that records are legal documents and must not be altered. For malocclusions with marked skeletal discrepancies and indication of orthodontic treatment associated with orthognathic surgery, immediate preoperative records must be submitted. Below an example of a photo mount with three facial and five intraoral photographs (Fig 9).

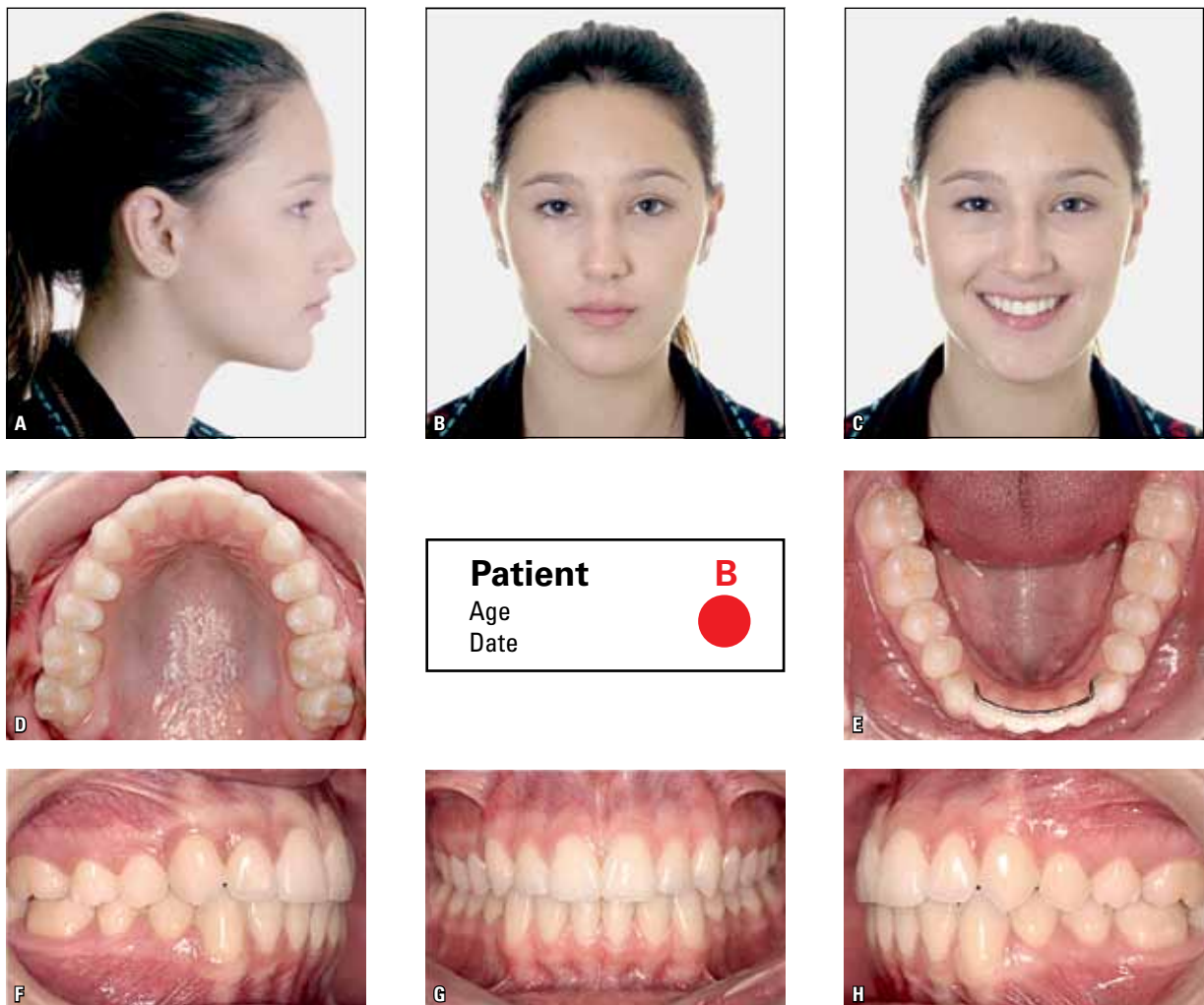


FIGURE 9 - Photograph layout: **A, B, C**) facial - right-side profile, frontal and frontal smiling photographs; **D, E, F, G, H**) intraoral - upper occlusal, lower occlusal, right lateral, frontal and left lateral photographs.

First examination

BBO conducted its first examination from March 19 to 21 in 2004, in the city of São Paulo, Brazil. Interestingly, in that same year, the American Board celebrated its 75th anniversary. The examination had the special participation of Jack Dale, renowned Canadian orthodontist, former ABO president and Professor Emeritus of the University of Toronto. In May of the same year, during the 104th AAO Annual Session in Orlando, Florida, Jack Dale was honored for his services to the American Board. At that time, he mentioned the work of the BBO Board of Directors and highlighted the effort and hard work that were landmarks of the beginning of the journey into BBO's mission.⁶ In special reference to it, he delivered a speech, freely reproduced below, which translated his view of the integrity of the Board efforts in Brazil:

The California redwoods, as magnificent as they are, do not grow alone; they need each other. They grow strong together by intertwining and entangling their roots, thus supporting one another. Without this mutual support they could not be nearly as robust and magnificent. With mutual support, we can remain strong and effective in our service to society. Maintaining our standard of care is a vital part of our strength... all over the world.

It was my honor and privilege to be invited as an external consultant for the first BBO examination. I found the treatment to be superb and the organization by the board of directors outstanding. There were problems, but that was expected. I am sure that these problems will be dealt with and solved in the future, because I am aware of the integrity, dedication, competence and concern of the BBO Directors. The American Board of Orthodontics has also had to solve problems along its 75 years of existence. In the future, these problems will certainly remain challenges.

In Brazil, records were standardized, uniform and beautifully done. You could examine any of the case reports on display and find that the

presentation was identical to the others. How I wish that this standard of excellence existed all over the world.

The exam was divided into two parts: (a) a written exam about case reports presented by the BBO; and (b) case report displays by each examinee.

a) Written examination: examinees from eight Brazilian states had four hours to examine two cases presented by BBO. For that, they were allowed to make cephalometric tracings and carry out any procedures that they used in their practices. I sat in the room for the four hours allotted for the examination, and observed men and women working hard at their tasks. The more I observed them, the more my admiration and respect grew.

B) Case report displays: the ten cases submitted by each examinee included six with specific malocclusions and four optional. The cases were on display in the room to be examined for two days. After that, there was a round table with the participation of all the examinees. The discussion was most valuable and constructive for the BBO.

The motto on the Brazilian flag means "Order and Progress". BBO exemplified this motto to perfection. They certainly achieved progress and did it step by step in an orderly way.

FINAL CONSIDERATIONS

The awareness of the relevance of professional qualification should be developed and expanded, as it occurs in the USA, where this movement has been constant in the different specialties. BBO is synonymous of qualification and adequate training to perform a successful treatment. Its credentials confirm professional competence and assure that the patient will receive a safe and efficacious treatment. Therefore, it should be used as motivation for other professionals to seek excellence in Orthodontics and Facial Orthopedics.

As Jack Dale said, the motto on the Brazilian flag was put into practice by BBO. According to that prominent professional, the level of excellence was achieved in the organization of the examination structure, which makes Brazil stand out as a model for the countries aspiring to become members of the World Board of Orthodontics (14 countries already have a Board of Orthodontics). Brazilian professionals should

believe in such effort so that the seed sown by the words of the Canadian professor germinates and bears good fruit as more specialists apply for excellence certification by the Brazilian Board of Orthodontics and Facial Orthopedics. The BBO certification system has been constantly updating. Therefore, orthodontists interested in taking the Certification Examination should regularly check the website www.bbo.org.br.

REFERENCES

1. Little DM. The founding of the specialty boards. *Anesthesiology*. 1981;55:317-21.
2. Cangialosi TJ, Riolo ML, Owens S Jr, Dykhouse VJ, Moffitt AH, Grubb JE, et al. The American Board of Orthodontics and specialty certification: the first 50 years. *Am J Orthod Dentofacial Orthop*. 2004;126(1):3-6.
3. The American Board of Orthodontics. [Cited 2010 Jan 11]. Available from: www.americanboardortho.com.
4. Board Brasileiro de Ortodontia e Ortopedia Facial. [Acesso 2010 Jan 11]. Available from: www.bbo.org.br.
5. Habib F, Fleischmann LA, Gama SLC, Araújo TM. Obtenção de modelos ortodônticos. *Rev Dental Press Ortod Orthop Facial*. 2007;12(3):146-56.
6. Dale J. Brazilian Board of Orthodontics and Dentofacial Orthopedics holds first examination. *Am J Orthod Dentofacial Orthop*. 2004;126:134.

Submitted: June 13, 2011
Revised and accepted: July 3, 2011

Contact address

Roberto M. A. Lima Filho
Avenida Alberto Andaló 4.025
CEP: 15.015-000 – São José do Rio Preto/SP, Brazil
E-mail: rlima@me.com