

# Orthodontic movement does not induce external cervical resorption (ECR)

or

*Orthodontic movement does not change gingival color and volume, and does not induce gingival inflammation*

Alberto Consolaro\*, Renata B. Consolaro\*\*

## Abstract

This study sought to explain, both anatomically and functionally, how the cervical region of human teeth is structured and organized in order to address the following questions: 1) Why does External Cervical Resorption (ECR) occur in human dentition? 2) Why is there no ECR in gingivitis and periodontitis? 3) Why ECR can occur after dental trauma and internal bleaching? 4) Why does orthodontic movement not change the gingival color and volume during treatment? 5) Why does orthodontic movement not induce ECR although it is common knowledge that the cervical region can undergo much stress? The existence of sequestered antigens in the dentin, the presence of dentin gaps in the cervical region of all teeth, the reaction of the junctional epithelium and the gingival distribution of blood vessels may explain why ECR does not occur, nor do gingival color and volume change when teeth are orthodontically moved.

**Keywords:** Tooth resorption. External cervical resorption. Orthodontic treatment. Gingiva.

## HOW THE CERVICAL REGION OF THE TOOTH IS STRUCTURED AND ORGANIZED

On the surface of cervical region of human teeth, in the area where the enamel borders the cementum, there is a line known as the cements-enamel junction (CEJ) (Fig 1). On the circumference of the neck of all human teeth the CEJ line alternates three types

of relationship between enamel and cementum.<sup>3,7</sup> In some areas of CEJ the cementum covers the enamel (Fig 4), in others the enamel and cementum meet edge to edge, but in other regions the enamel and cementum remain distant from each other, thereby exposing microscopic dentin gaps or “windows” facing the gingival connective tissue.

**How to cite this article:** Consolaro A, Consolaro RB. Orthodontic movement does not induce external cervical resorption (ECR). Dental Press J Orthod. 2011 Nov-Dec;16(6):22-7.

» The authors report no commercial, proprietary, or financial interest in the products or companies described in this article.

\* Head Professor of Pathology, FOB-USP, and postgraduation courses, FORP-USP.

\*\* Professor, FOA-Unesp and Faculdades Adamantinenses Integradas (FAI).

Having completed its key function of producing enamel, this organ — formed by the outer epithelium, stellate reticulum, stratum intermedium and ameloblasts — undergoes a sandwich-like re-stratification and gives rise to the reduced epithelium of the enamel organ. This epithelium is firmly attached to the enamel and receives nutrients from the peripheral connective tissue. Together, they form the dental follicle, which generates the image of the pericoronal space in unerupted teeth.

As a tooth gradually begins to appear in the mouth, the reduced epithelium of the enamel organ fuses with the oral mucosa and together form the junctional epithelium. Initially this epithelium has three to four layers, reaching as many 10 to 20 cells of thickness with age. Close to 30 years of age, the junctional epithelium lines the enamel in its cervical-most portion, but eventually progresses gradually towards the cementum. The length of the junctional epithelium<sup>4</sup> ranges from 0.25 to 1.35 mm.

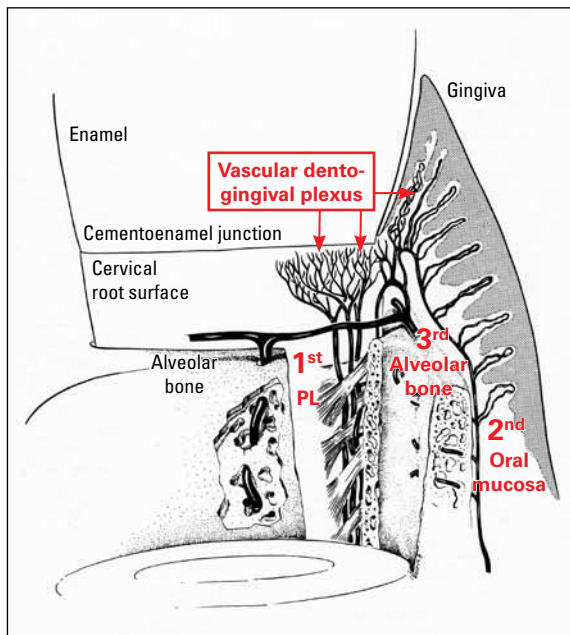


FIGURE 1 - The dentogingival plexus features anastomosis with vessels extending from the periodontal ligament (1<sup>st</sup>), oral mucosa (2<sup>nd</sup>) and alveolar bone (3<sup>rd</sup>) in the region of the connective attachment next to the cervical root surface (scheme modified from Glickman<sup>4</sup>).

In the cervical root region, next to the enamel, it is the connective tissue of the dental follicle, which gives rise to the connective attachment in the erupted tooth (Fig 4). Conceptually, the connective attachment in the erupted tooth comprises the space between the final portion of the enamel and the initial portion of the alveolar bone crest.

The cementum extends from the final edge of the cervical enamel and its junctional epithelium. On the cementum surface are the cementoblasts (Fig 4) nourished by the connective tissue of the dental follicle tissue and connective attachment. Progressing toward the apex, the connective tissue and cementoblasts on the root become part of the periodontal ligament. The average thickness of the cementum in the cervical third ranges from 16 to 60  $\mu\text{m}$ , which is equivalent to the thickness of a human hair. In the apical third, bifurcations and trifurcations range from 150 to 200  $\mu\text{m}$ . The average thickness of the cementum in a youth aged 20 is 95  $\mu\text{m}$  and at age 60, 215  $\mu\text{m}$ .<sup>9</sup>

Whatever the relationship between enamel and cementum in the cervical region, the CEJ and its components are in direct contact with the fibrous gingival connective tissue or, more specifically, with its collagen fibers and extracellular matrix gel interspersed with fibroblasts (Fig 4). In the CEJ segments, where the dentin gaps are located, it is "concealed" or protected from exposure to macrophages by the extracellular matrix gel, which plays this role with great competence.

### 1) WHY DOES EXTERNAL CERVICAL RESORPTION (ECR) OCCUR IN HUMAN DENTITION?

Some proteins in the dentin are recognized as antigenic by the immune system because they are deposited during odontogenesis without direct contact with the protein memory cells which develop during intrauterine life.<sup>1</sup> Thus, the dentin should be protected from this contact throughout its life, including in the dentin gaps of the CEJ present in all teeth.

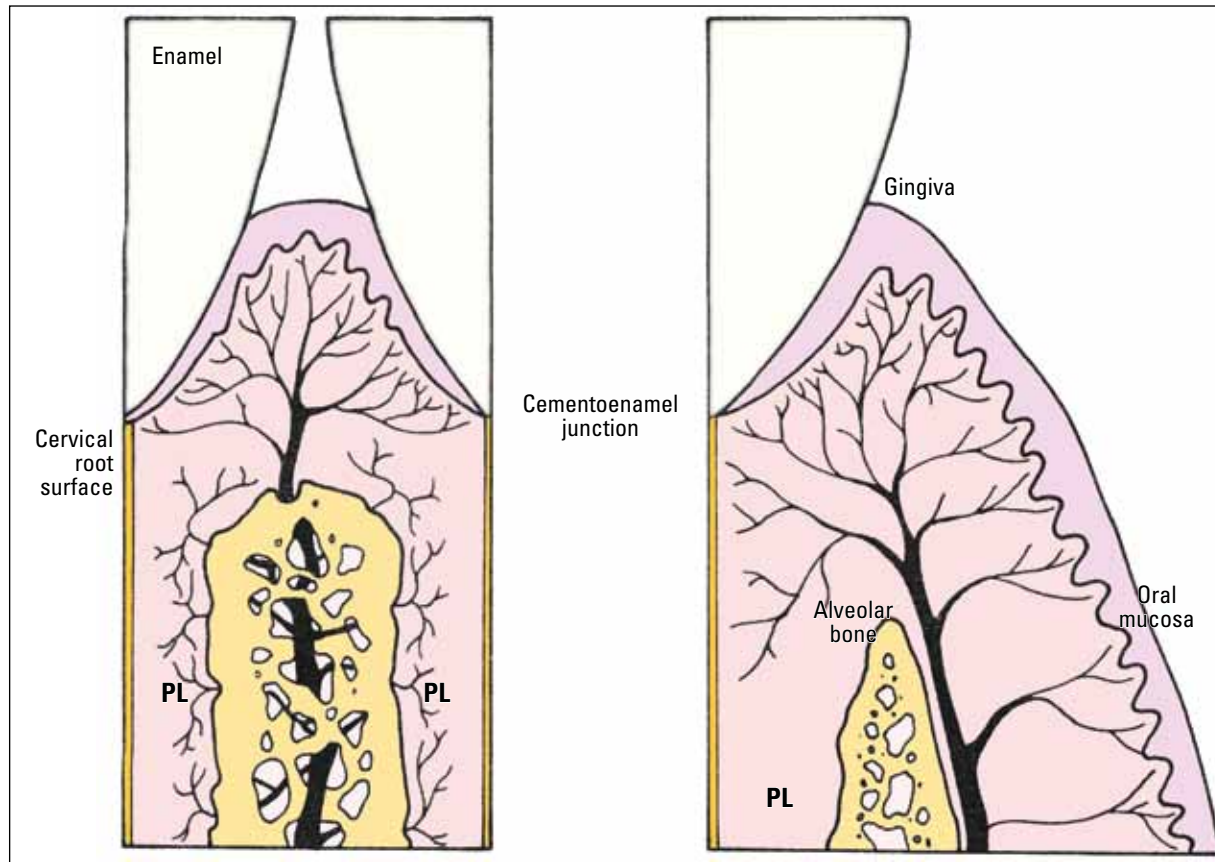


FIGURE 2 - During orthodontic movement blood supply to the periodontal ligament may be reduced or eliminated without compromising gingival blood supply, especially in the connective attachment region. Glickman's modified schemes<sup>4</sup> emphasize the osseous and gingival origin of blood vessels in the cervical region.

Before the dentin gaps are exposed to macrophages at the CEJ, with consequent immunological recognition, a direct exposure is required to occur as a result of the dissolution of the extracellular matrix of connective tissue where these cells circulate.

The destruction and/or dissolution of the extracellular matrix occur mainly in inflammation: A defense mechanism typical of connective tissues and dependent on vessels. The mediators and enzymes that make up the inflammatory exudate arising from vessels and leukocytes dissolve the extracellular matrix gel and, at the gingival connective attachment can provide the dentin with access to the macrophages.

Once the macrophages identify the dentin as

a foreign body, they initiate a process through which foreign proteins are eliminated and, when these macrophages are present in hard tissues, bone resorption is the mechanism of choice.<sup>1</sup>

## 2) WHY IS THERE NO ECR IN GINGIVITIS AND PERIODONTITIS?

When gingival inflammation is induced by dental bacterial plaque, it promotes epithelial hyperplasia while the junctional epithelium migrates toward the apical region, placing the CEJ and its gaps in the gingival sulcus and oral environment, thereby "protecting" the ECR region. In the oral environment, macrophages are not capable of recognizing foreign proteins in the dentin and therefore fail to trigger an immune response.

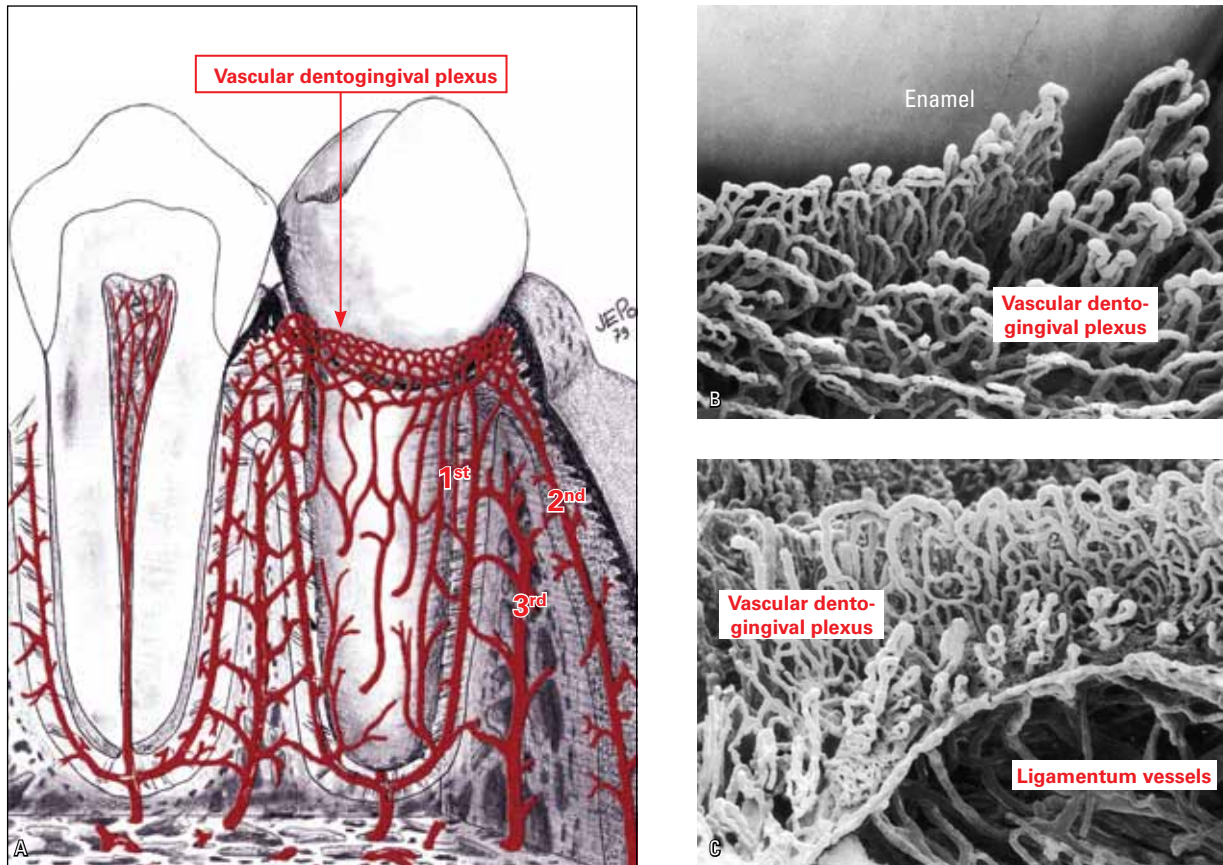


FIGURE 3 - **A)** The lace-shaped or net-shaped dentogingival plexus consists of vessels originating from the periodontium (1<sup>st</sup>), mucosa (2<sup>nd</sup>) and bone (3<sup>rd</sup>) (scheme introduced by Lascala and Moussalli<sup>5</sup>). **B** and **C** highlight the numerous loop-shaped capillaries of dentogingival plexus in rodents, revealed by scanning electron microscopy performed by Selliseth and Selvig (Source: Newman et al,<sup>8</sup> 2006).

### 3) WHY ECR CAN OCCUR AFTER DENTAL TRAUMA AND INTERNAL BLEACHING?

In dental trauma, inflammation of gingival connective tissue may occur, but without junctional epithelial hyperplasia. Such is the case in internal dental bleaching, where hydrogen peroxide leaks into the dentinal tubules that open out at the junction, causing a local gingival inflammation in the connective tissue, without epithelial hyperplasia. In these two situations, gingival inflammation dissolves the extracellular matrix, exposing the dentin in the CEJ gaps. However, hyperplasia of the junctional epithelium does not occur, allowing the occurrence of ECR.<sup>2</sup>

### 4) WHY DOES ORTHODONTIC MOVEMENT NOT CHANGE GINGIVAL COLOR AND VOLUME DURING TREATMENT?

One way to induce inflammation is by obstructing blood vessels, which results in local cell death. Proteins released by necrotic cells induce inflammation, as in the gingival connective tissue. Compression of the teeth against the periodontal ligament and alveolar bone often causes cells death and hyalinization of a ligament segment. Not only the arterioles and capillaries, but the veinlets would also be obstructed, along with areas of necrosis, followed by inflammation.



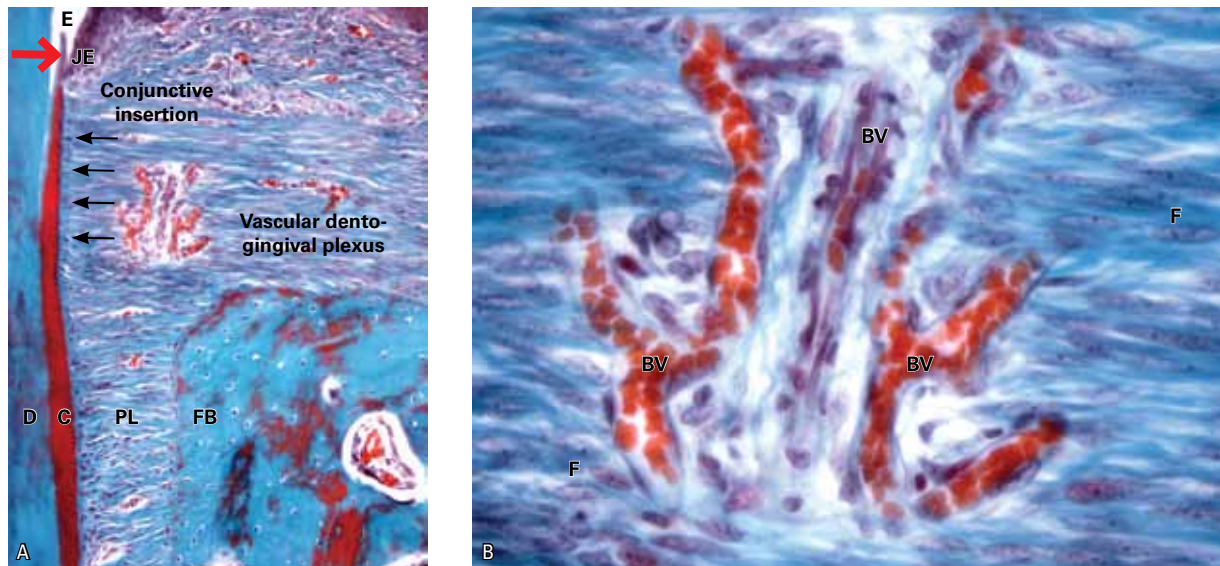


FIGURE 4 - Net-shaped dento-gingival plexus in the cervical dental region of monkeys, more specifically at the site of the cemento-enamel junction (larger arrow). On the root one can see the cementoblasts (small arrows) (E= enamel, JE= junctional epithelium, D= dentin, C= cementum, PL= periodontal ligament, FB= fasciculate bone, BV= blood vessel, F= fibroblast ).

In orthodontic movement, compression of the vessels occurs in the periodontal ligament and could potentially influence gingival blood flow, but this does not occur. It would be natural to expect ischemia would make the gingiva turn whitish, or passive hyperemia would make it violet-red due to veinlet compression.

In the gingival tissue, more specifically at the site of the gingival connective attachment, blood vessels form a lace-like dento-gingival vascular network or plexus with connections arising from periodontal vascular components. These connections also originate in the marrow spaces of the alveolar bone crest and its periosteum, as well as from the vessels of the alveolar mucous membrane via attached gingiva.<sup>5,6,8</sup> There are 50 capillaries within every square millimeter of gingiva<sup>5</sup> (Figs 1-4).

The effects of vascular compression of the cervical periodontal tissues and gingival tissues are offset by anastomosis or by connections from other sources (Fig 2). Blood supply to gingival tissues

and their venous and lymphatic drainage remain at normal levels. Gingival color and volume are not changed during orthodontic movement by this mechanism or anatomical feature. Neither an edema develops — due to venous obstruction — nor does any inflammatory process emerge.

#### 5) WHY DOES ORTHODONTIC MOVEMENT NOT INDUCE EXTERNAL CERVICAL RESORPTION?

In a similar compensatory manner, compression of the periodontal and gingival vessels does not promote focus areas of necrosis and/or gingival inflammation in the region of the connective attachment (Fig 2). In the absence of necrosis, characterized by cell rupture and protein spill, orthodontic movement does not induce inflammation and dissolution of extracellular matrix in the gingival connective tissue. The dentin gaps will not be exposed to macrophages, which in turn will not perform antigen recognition, nor present with foreign proteins that might trigger

external cervical immune and resorptive responses. This mechanism and anatomical feature does not induce ECR during orthodontic movement.

On the other hand, damage to the gingiva caused by dental trauma and internal dental bleaching cannot be offset by extensive anastomosis: Cellular injury occurs mechanically, directly and independently of blood supply. During trauma, cells and vessels are ruptured by sudden shifts while in tooth bleaching the toxic effect of hydrogen peroxide occurs independently of local blood supply.

### FINAL CONSIDERATIONS

1) Dentin comprises proteins, which are considered sequestered antigens and when it is exposed to connective tissues it tends to be resorbed as a form of elimination by the body.

2) At the cemento-enamel junction (CEJ), the dentin gaps found in all permanent teeth may expose the dentin whenever inflammation is induced at the connective attachment.

3) Before dentin is exposed at the CEJ, gingivitis and periodontitis reveal a hyperplasia of the junctional epithelium that covers the gaps, placing the dentin in the oral environment.

4) In dental trauma and internal bleaching, inflammation of connective gingival tissue does not promote junctional epithelial hyperplasia and direct exposure of the dentin allows antigen recognition by macrophages.

5) The gingiva receives vessels from the periodontium, bone, periosteum and mucous membrane so that its nutrition and drainage are not affected, even when the vessels of the periodontal ligament are compressed during orthodontic movement.

As a result, there is no inflammation at the connective attachment, nor there is cell death in the gingiva during orthodontic movement, with gingival color and volume remaining unchanged, even if the dentin is exposed at the CEJ gaps, which is necessary to initiate ECR.

### REFERENCES

1. Consolaro A. Reabsorções dentárias nas especialidades clínicas. Maringá: Dental Press; 2005.
2. Esberard R, Esberard RR, Esberard RM, Consolaro A, Pameijer CH. Effect of bleaching on the cemento-enamel junction. *Am J Dent.* 2007;20(4):245-9.
3. Francischone LA, Consolaro A. Morphology of the cemento-enamel junction of primary teeth. *J Dent Child (Chic).* 2008;75(3):252-9.
4. Glickman I. *Periodontia clínica de Glickman.* Rio de Janeiro: Interamericana; 1983.
5. Lascaia NT, Moussalli NH. *Periodontia clínica e especialidades afins.* São Paulo: Artes Médicas; 1980.
6. Lindhe J, Karring T, Lang NP. *Tratado de Periodontia clínica e Implantodontia oral.* 3ª ed. Rio de Janeiro: Guanabara Koogan; 1999.
7. Neuvald L, Consolaro A. Cemento-enamel junction: microscopic analysis and external cervical resorption. *J Endod.* 2000;26(9):503-8.
8. Newman MG, Takei HH, Klokkevold, PR, Carranza, FA. *Carranza's clinical periodontology.* 10ª ed. St. Louis: Saunders Elsevier; 2006.
9. Zander HA, Hurzeler B. Continuous cementum apposition *J Dent Res.* 1958;37(6):1035-44.

Submitted: October 7, 2011

Revised and accepted: October 11, 2011

#### Contact address

Alberto Consolaro

E-mail: consolaro@uol.com.br