

## Sigmoidoanal intussusception with exteriorization of sigmoid adenocarcinoma

PEDRO ROBERTO DE PAULA<sup>1</sup>, MARIA AUXILIADORA PROLUNGATTI CÉSAR<sup>2</sup>, EDUARDO FORTES DE ALBUQUERQUE<sup>3</sup>, FERNANDA PEREZ ADORNO DA SILVA<sup>4</sup>

<sup>1</sup>Assistant Professor and Doctor of the Medicine Department of Universidade de Taubaté; Head of the Coloproctology Service of the University Hospital of Taubaté – Taubaté (SP), Brazil. <sup>2</sup>Assistant Professor and Doctor of the Medicine Department of Universidade de Taubaté; Head of the Anal Physiology Service of the University Hospital of Taubaté – Taubaté (SP), Brazil. <sup>3</sup>Ex-Resident of general surgery at the University Hospital of Taubaté – Taubaté (SP), Brazil.

<sup>4</sup>Medical student at Universidade de Taubaté – Taubaté (SP), Brazil.

---

PAULA PR; CÉSAR MAP; ALBUQUERQUE EF; SILVA FPA. Intussuscepção sigmoideanal com exteriorização de adenocarcinoma de sigmoide. *Rev bras Coloproct*, 2011;31(3): 294-298.

**ABSTRACT:** The intestinal intussusception is a rare disease in adults, and is mostly caused by malignant neoplasm. Symptoms are usually nonspecific and chronic, and in most cases suggesting intestinal obstruction. Treatment consists of removing the malignant tumor. This article reports the case of a patient with hematochezia and apparent mass in the anus who underwent anterior rectosigmoidectomy and had the diagnosis of adenocarcinoma of the sigmoid confirmed.

**Keywords:** intestinal intussusception; colon adenocarcinoma; proctocolectomy.

---

### INTRODUCTION

Intestinal intussusception is rare among adults, corresponding to 5% of all cases and 1% of intestinal obstructions; it is more common among infants. It occurs when the proximal bowel segment (intussuscept) penetrates the distal segment lumen (intussuscepted)<sup>1,2</sup>. It was first described by Barbette de Amsterdam, in 1674, and Jonathan Hutchinson performed the first surgical reduction in 1871<sup>3</sup>.

The symptoms of intussusception in adults, unlike for children, are usually nonspecific and chronic, mostly suggesting intestinal obstruction<sup>4</sup>.

Among infants, it is mostly primary and benign, and the treatment consists of the reduction with ene-

ma in 80% of the cases. Among adults, the disease is frequently secondary to the organic cause, which makes the preoperative diagnosis difficult; it is usually confirmed during laparotomy. The diagnosis is based on surgical findings. However, imaging tests and minimally invasive procedures can be useful, such as the simple abdominal x-ray, contrast examinations, colonoscopy, ultrasonography and computed tomography (CT)<sup>5</sup>.

In 80 to 90% of the cases, neoplasm can be considered as the main organic cause for intussusceptions in adults, in which 68% of the large intestine is a result of the malignant disease, and, among these, 62% are adenocarcinomas. The opposite happens to the small intestine, since its main etiology consists of benign tumors<sup>1,4</sup>.

---

Financing source: none.

Conflict of interest: nothing to declare.

---

Submitted on: 01/02/2010

Approved on: 22/03/2010

The treatment of choice for malignant colon neoplasm is the removal of the tumor and all tissues involved in the angiolymphatic drainage, which are the main dissemination paths for these tumors<sup>6</sup>.

We reported a rare case in which the “head” of the invagination, which was formed by malignant sigmoid neoplasm, was exteriorized by the anus.

### CASE REPORT

We report the case of a 50-year-old black female patient that had been presenting with hematochezia for nine months, which was independent from evacuations; also, for six months she had been noticing the exteriorization of a mass in the anal region during the effort to evacuate, thus being necessary to digitally reduce it. She also presented with abdominal pain with moderate colic at the left flank and hypogastrium before evacuating. She had diarrhea intercalated with dry stool. She was regularly taking laxatives every three days. She lost 16 kg in the past eight months.

Proctocological examination showed: (a) inspection: absence of skin tags, tumors, fistulous orifice and prolapse; (b) rectal touch: normotonic/hypotonic sphincter, identifying the presence of a tumor mass in the anterior wall, approximately 9 cm to the anal margin; (c) rectosigmoidoscopy: presence of vegetating friable lesion in the anterior wall, with 6 cm in diameter, approximately 9 cm from the anal margin

(after biopsy); it moved upwards with the movement of the device.

An abdominal and pelvic CT scan showed a target image in the rectosigmoid region, which suggested a loop inside a loop (Figure 1). The colonoscopy confirmed the presence of a vegetating lesion of the sigmoid, hard with friable surface 20 cm from the anal border. The lesion was blocking 90% of the light and preventing the entrance of the device. A new biopsy was conducted and showed the presence of a tubular pattern adenocarcinoma with strong atypia.

The patient was admitted for surgery and underwent a radical anterior upper rectosigmoidectomy, with primary manual termino-terminal anastomosis. At intraoperative, a vegetating sigmoid tumor of about 7.0x5.0 cm was observed, which was invaginated within the sigmoid and the rectum, thus allowing its exteriorization through the anus (Figure 2). The presence of a main ganglion was identified, with 2 cm in diameter, hard and located at the emergency of the inferior mesenteric artery. The anatomopathological examination of the resected piece showed that the lesion was microscopically infiltrated to the serous and, out of the 17 dissected lymph nodes in the pericolic adipose tissue, only one was compromised. It was close to the inferior mesenteric artery (main ganglion) (Figures 3 and 4). The patient evolved without intercurrents, and was discharged from the hospital on the third postoperative day.

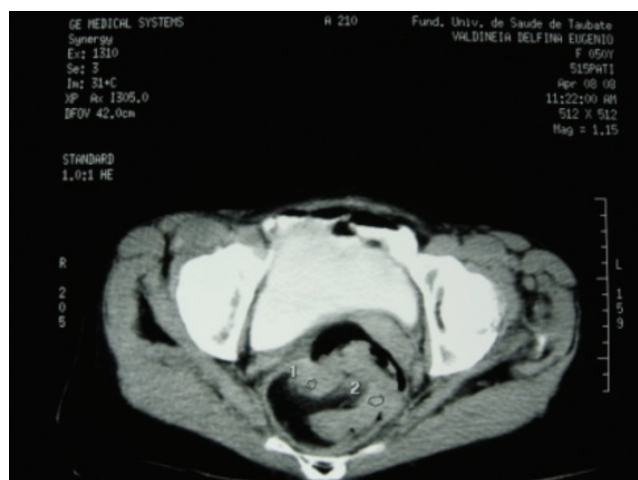


Figure 1. Pelvic computed tomography showing lesion in the rectal region (target image).

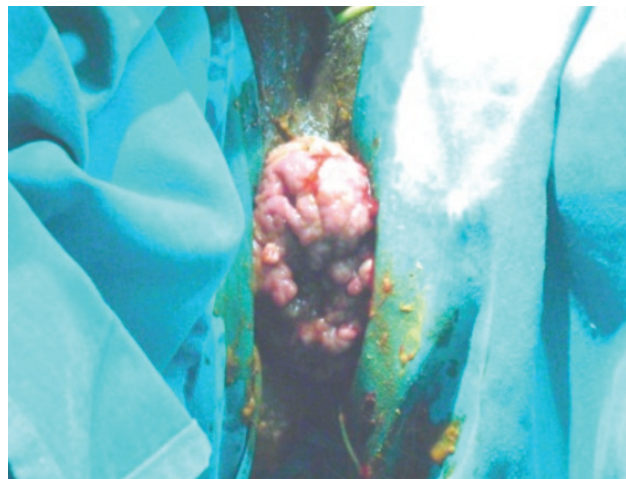
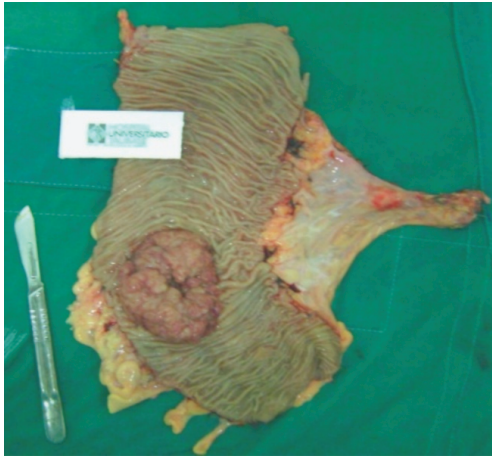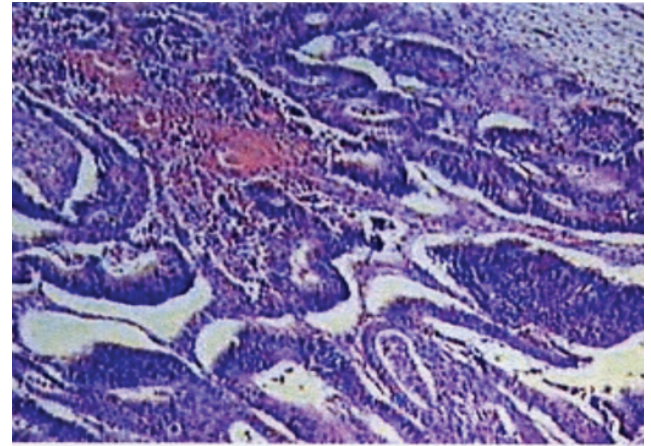


Figure 2. Vegetating tumor of the sigmoid exteriorized through the anus.



**Figure 3.** Surgical piece with tumor lesion and the main affected ganglion.



**Figure 4.** Histological bowel cut showing the invasion by neoplastic cells to the serous, affecting blood and lymphatic vessels.

## DISCUSSION

Intussusception can usually be classified according to the compromised intestinal segment; it can be called enteric (small intestine), ileocolic (penetration of the ileum in the ileocecal valve), ileocecal (when the ileocecal valve is the intussusception point), colocolic (colon) and colorectal<sup>4</sup>. In the studied case, the sigmoid was exteriorized through the anal orifice.

The general clinical picture is variable, but abdominal pain is the most common symptom, present in 100% of the studied cases<sup>2,5,7-9</sup>. Other symptoms are nausea, vomit, hematochezia, changes in intestinal habit, distension and palpable abdominal mass<sup>10,11</sup>. However, the abdominal mass is not a common finding related to intussusceptions among adults, occurring in 7 to 42% of the cases<sup>2,7</sup>. In the studied case, the patient presented with moderate abdominal pain before evacuating and at the moment of digital reduction of the mass that was exteriorized through the anus, hematochezia and changes in the intestinal habit.

The certain diagnosis is based on surgical findings. However, imaging tests and minimally invasive procedures can be useful in cases like this, in which the diagnosis can be established before surgery.

Simple contrast abdomen x-rays, ultrasonography, abdominal CT scan and colonoscopy can reveal the segment that is affected by the disease<sup>1</sup>.

Barium studies like intestinal transit and enema may help the diagnosis; however, in cases of com-

plications, such as ischemia or intestinal perforation, they are contraindicated.

Ultrasonography is the choice due to the accuracy to diagnose intussusceptions, both for adults and for children, showing the “target” image or the “onion skin” in the cross-sectional view, and the “pseudokidney sign” or “double kidney” in the longitudinal view, which may not be pathognomonic, but very suggestive<sup>5</sup>.

Abdominal and pelvic CT have also been important for the preoperative diagnosis of this condition<sup>1,5</sup>. The density of the mass generated by the compromised segment, which is associated to the edema of the intestinal wall and the mesenteric, creates a characteristic signal in the CT, which is also called the “target sign”<sup>1</sup>. However, the tomography is not reliable concerning the differentiation between neoplasm and the nonspecific thickening of the intestinal wall. Besides, this examination is still limited since it is not available in all the emergency services and due to the need of contrast administration<sup>5</sup>. Colonoscopy may help in cases of colonic obstruction.

The comparison between the different examinations in order to define the diagnosis, such as x-ray, ultrasound, barium studies, colonoscopy and CT, shows that CT is the test with the most diagnostic sensitivity, proving to be efficient and 88.6% more recommended to diagnose intussusceptions among adults<sup>12,13</sup>. Our patient was investigated with colonoscopy and tomography, which confirmed the intussusception and its

etiology. It was possible to perform the preoperative abdominal staging.

The treatment for the intussusceptions in adults demands an individual and systematic approach. Laparotomy is mandatory, once it can identify an organic lesion that could be neoplastic. The theoretical possibility to implant malignant cells indicates the resection of the lesion. The need and the extension of this resection are controversial, since there is the risk of an unnecessary intestinal resection<sup>2,7</sup>.

In cases of colocolonic intussusceptions, it is necessary to resect the segment with an oncologic purpose due to the high risk of malignancy<sup>2,7,14</sup>, which could be observed in this study; we had already diagnosed the sigmoid adenocarcinoma, and the patient presented a sigmoido-anal intussusception. She was submitted to a radical rectosigmoidectomy, which was essential, since the main lymphatic ganglion had metastatic compromise, in the root of the inferior mesenteric artery.

As to the surgical approach, laparoscopy performed by a trained team can be used with several advantages; however, the conventional path is still more common<sup>15</sup>. In this case, the conventional approach was used, and the patient did not present with any postoperative complication, being discharged early. Nowadays, the patient has finished the chemotherapy cycles, and is asymptomatic.

The incidence of colorectal malignant neoplasm, which is the main organic cause of intussusception, has been increasing in Brazil and represents the fifth most common cause of death by cancer<sup>16</sup>. It is more frequent among white males, especially those aged more than 40 years, with mean age of 60 and 70 years<sup>17,18</sup>.

In this case, the patient was female, black, at the fifth decade of life, and her age was within the prevalent age group.

The malignant lesions of the colon are adenocarcinomas in 95% of the cases, more commonly located in the rectosigmoid segment, which can be observed in the present case, in which the patient had a tumor affecting the sigmoid, which was the “head” of the invagination, that presented as a mass that was exteriorized by the anal canal<sup>17,18</sup>.

At the postoperative staging of the disease proposed by Dukes, which considers the tumor depth in the intestinal wall and the compromise of regional lymphatic ganglia, the case was classified as Dukes C for presenting a compromised regional lymphatic ganglion<sup>2,13</sup>. Imperfections in this classification system led to the creation of new classifications; TNM is the most appropriate and the most used one, even though its accuracy is around 65%, which leads to a flaw when estimating the evolution of patients<sup>11,13</sup>. The stage of our patient was T3 N1 M0, stage IIIa. The involvement of lymphatic nodules is considered to be the most important discriminating factor when related to the short survival of patients<sup>13,19,20</sup>.

## FINAL CONSIDERATIONS

Intussusception is a rare condition, and, in this case, the “head” of the invagination was formed by a malignant sigmoid neoplasm, which was exteriorized through the anus. It was diagnosed at the preoperative period by anamnesis, and confirmed by colonoscopy with biopsy and CT. The treatment was a radical surgery.

---

**RESUMO:** A intussuscepção intestinal é uma doença rara em adultos, sendo na maior parte dos casos causada por neoplasia maligna. Os sintomas são geralmente inespecíficos e crônicos, na maioria das vezes sugerindo obstrução intestinal. O tratamento consiste na remoção oncológica do tumor. Este artigo relata o caso de uma paciente com quadro de hematoquezia e exteriorização de massa através do ânus que foi submetido à retossigmoidectomia anterior alta em bloco e confirmado o diagnóstico de adenocarcinoma de sigmoide.

**Palavras-chave:** intussuscepção intestinal; adenocarcinoma de cólon; proctocolectomia.

---

## REFERENCES

1. Wang N, Cui XY, Liu Y, Long J, Xu YH, Guo RX, et al. Adult intussusception: a retrospective review of 41 cases. *World J Gastroenterol* 2009;15(26):3303-8.
2. Yakan S, Caliskan C, Makay O, Denecli AG, Korkut MA. Intussusception in adults: Clinical characteristics, diagnosis and operative strategies. *World J Gastroenterol* 2009;15(16):1985-9.
3. Butte BJM, Iniguez CA, Torres MJ. Intussuscepción de colon por lipoma. *Rev Chi Cir* 2006;58(2):151-4.

4. Marinis A, Yiallourou A, Samanides L, Dafnios N, Anastasopoulos G, Vassiliou I, et al. Intussusception of the bowel in adults: a review. *World J Gastroenterol* 2009;15(4):407-11
5. Korkmaz O, Yilmaz HG, Taçyıldız HH, Akgün Y. Intussusception in adults. *Ulus Travma Acil Cerrahi Derg* 2009;15(2):154-8.
6. Gordon PH, Nivatvongs S. Principles and practice of surgery for the colon, rectum, and anus. 2nd ed. Missouri: Quality Medical Publishing; 1999. p. 900-1097.
7. Dell'abate P, Del Rio P, Sommaruga L, Arcuri MF, Sianesi M. Laparoscopic treatment of sigmoid colon intussusception by large malignant tumor. Case report. *G Chir* 2009;30(8-9):374-6.
8. Zissin R, Gayer G, Konen O, Shapiro-Feinberg M. Transient colocolic intussusception. *J Clin Imaging* 2000;24(1):8-9.
9. Chen CF, Chuang CH, Lu CY, Hu C, Kuo TL, Hsieh JS. Adult intussusception secondary to lymphangioma of the cecum: a case report. *Kaohsiung J Med Sci* 2009;25(6):347-52.
10. Martin-Lorenzo JG, Torralba-Martinez A, Liron-Ruiz R. Intestinal invagination in adults. *Int J Colorectal Dis* 2004;19(1):68-72.
11. Warshauer DM, Lee JKT. Adult intussusception detected at CT or MR imaging: clinical-imaging correlation. *Radiology* 1999;212(3):853-60.
12. Pisano G, Manca A, Farris S, Tatti A, Atzeni J, Calò PG. Adult idiopathic intussusception: a case report and review of the literature. *Chir Ital* 2009;61(2):223-9.
13. Chang CC, Chen YY, Chen YF, Lin CN, Yen HH, Lou HY. Adult intussusception in Asians: clinical presentations, diagnosis and treatment. *J Gastroenterol Hepatol* 2006;22(11):1767-71.
14. Hanan B, Diniz TR, da Luz MM, da Conceição SA, da Silva RG, Lacerda-Filho A. Intussusception in adults. *Colorectal Dis* 2010;12(6):574-8.
15. Chuang CH, Hsieh CB, Lin CH, Yu JC. Laparoscopic management of sigmoid colon intussusception caused by a malignant tumor: case report. *Rev Esp Enferm Dig* 2007;99(10):615-6.
16. Priolli DG, Cardinali IA, Piovesan H, Margarido NF, Martinez CAR. Proposta para estadiamento do câncer colorretal baseada em critérios morfofuncionais. Correlação com níveis séricos do antígeno carcinoembrionário. *Rev Bras Coloproct* 2007;27(4):374-83.
17. Cruz GMG, Santana JL, Santana SKAA, Constantino JRM, Chamone BC, Ferreira RMRS, et al. Câncer colônico - epidemiologia, diagnóstico, estadiamento e gradação tumoral de 490 pacientes. *Rev Bras Coloproct* 2007;27(2):139-53.
18. Roediger WEW. Estadiamento TNM. Trad. Marcio Constantino Mimessi. 6a ed. São Paulo: Fundação Oncocentro de São Paulo; 2006. p. 347-59.
19. Mahmoud N, Rombeau J, Ross HM, Fry RD. Colon e reto. In: Sabiston DC. Tratado de Cirurgia: a base biológica da moderna prática cirúrgica. Rio de Janeiro: Elsevier; 2005. p. 1443-66
20. Araújo PHJ, Rangel MF, Batista TP. Intussuscepção íleo-cólica em adulto. *Rev Bras Coloproct* 2008;28(4):470-3.

**Correspondence to:**

Dr: Pedro Roberto de Paula.  
Rua Santo Antonio nº 45, Centro  
CEP: 12080-440 – Taubaté (SP), Brazil.  
E-mail: pedrordepaula@hotmail.com