

Transanal rectopexy – twelve case studies

Rubens Henrique Oleques Fernandes¹, Tito Armando Rossi²

¹Full Member, Brazilian Society of Coloproctology – Caxias do Sul (RS), Brazil; Residency Preceptor, General Surgery, Hospital Nossa Senhora de Pompeia – Caxias do Sul (RS), Brazil. ²Full Member, Brazilian Society of Coloproctology – Caxias do Sul (RS), Brazil; Head of Gastrocolon Clinic, Hospital Nossa Senhora de Pompeia – Caxias do Sul (RS), Brazil.

Fernandes RHO e Rossi TA. Transanal rectopexy – twelve case studies. *J Coloproctol*, 2012;32(2): 132-135.

ABSTRACT: Objectives: This study analyzed the results of transanal rectopexy and showed the benefits of this surgical technique. **Method:** Twelve patients were submitted to rectopexy between 1997 and 2011. The surgical technique used was transanal rectopexy, where the mesorectum was fixed to the sacrum with nonabsorbable suture. Three patients had been submitted to previous surgery, two by the Delorme technique and one by the Thiersch technique. **Results:** Postoperative hospital stay ranged from 1 to 4 days. One patient (8.3%) had intraoperative hematoma, which was treated with local compression and antibiotics. One patient (8.3%) had residual mucosal prolapse, which was resected. Prolapse recurrence was seen in one case (8.3%). Improved incontinence occurred in 75% of patients and one patient reported obstructed evacuation in the first month after surgery. No death occurred. **Conclusion:** Transanal rectopexy is a simple, low cost technique, which has shown good efficacy in rectal prolapse control.

Keywords: rectum; rectal prolapse; colorectal surgery.

RESUMO: Objetivo: O presente estudo analisou os resultados da retopexia pela via transanal e expôs os benefícios desta técnica cirúrgica. **Método:** Doze pacientes com prolapso foram operados no período de 1997 a 2011. A técnica cirúrgica usada foi a retopexia transanal, onde o mesorreto foi fixado ao sacro com fio inabsorvível. Três pacientes tinham cirurgia prévia, dois pela técnica de Delorme e um pela técnica de Thiersch. **Resultados:** A permanência hospitalar pós-operatória variou de 1–4 dias. Uma paciente (8,3%) apresentou hematoma transoperatório que foi tratado com compressão local e antibioticoterapia. Um paciente apresentou prolapso mucoso residual (8,3%), que foi ressecado. Houve recidiva da procidência em um caso (8,3%). A melhora da incontinência ocorreu em 75% dos pacientes e uma paciente apresentou bloqueio evacuatório no primeiro mês após a cirurgia. Não houve mortalidade entre os pacientes operados. **Conclusão:** A retopexia transanal é uma técnica simples, de baixo custo e apresentou boa eficácia no controle do prolapso retal.

Palavras-chave: reto; prolapso de reto; cirurgia colorretal.

INTRODUCTION

Rectal prolapse is the protrusion of all rectal walls through the anal canal. It affects women more often than men, at the ratio of 6:1¹. Several treatment methods have been proposed, either through abdominal or perineal approach. Few studies have been conducted to guide our practice, and good results have been achieved with both abdominal and perineal techniques². The re-

duced number of patients with this pathology at each service of Coloproctology is certainly a limitation to studies comparing these surgical techniques.

Perineal rectopexy, introduced in 1910³, uses gas in the retrorectal space for several days; with high recurrence, the technique has not become popular. Transperineal⁴, transsacral⁵ and postanal⁶ approaches have also been used, but without high acceptance. Transanal rectopexy has been used

Study carried out at the Service of Surgery, Hospital Nossa Senhora de Pompeia, Department of Coloproctology – Caxias do Sul (RS), Brazil.

Financing source: none.

Conflict of interest: nothing to declare.

Submitted on: 08/24/2011

Approved on: 11/23/2011

only in association with Altemeier⁷ e Delorme⁸ techniques, for reduced recurrence. No utilization of transanal rectopexy as an isolated technique has not been described.

The purpose of this study is to present the results of transanal rectopexy and the technical description of the procedure.

PATIENTS AND METHODS

Twelve patients, three males and nine females, aged 34 to 88, were submitted to rectopexy. Prolapse duration ranged from 1 to over 10 years. Three patients had been submitted to previous surgery for prolapse, two by the Delorme technique, with recurrence, and one, with external prolapse and mucosal ischemia, was submitted to urgent Thiersch surgery and subsequently to transanal rectopexy. Table 1 shows the clinical details of patients. The prolapse of patients submitted to rectopexy was 4–10 cm long.

Surgical technique

All patients were in the lithotomy position during the surgery, and received regional or local anesthesia with sedation (one patient only). After prolapse reduction and rectal retactor placement, the rectum returns to its original position. The following retractors were used: circular anal retactor, vaginal speculum 4 and composite anoscope (130 x 40 mm). With all these instruments, it is possible to perform the surgery. The mucosa is rinsed with physiological saline solution, and, after that, an incision is made in the posterior rectal wall, starting 6 cm and ending 10 cm from the anal margin. As the mesorectum was exposed, it was fixed to the pre-sacral fascia with nonabsorbable suture, using 40 mm atraumatic needles. The needle should be long enough to enable the passage through the pre-sacral fascia and expose the needle tip to end stitching. After 3-4 stitches are made, the threads are tied and the rectal wall is tensioned to test its fixation. It is rinsed again and the rectal wall is closed with absorbable suture #00 or #000. All patients received antibiotic prophylaxis. Figures 1 and 2 show the rectal wall incision and the final aspect after rectopexy and rectal wall suture.

RESULTS

The immediate postoperative period was asymptomatic and the patients did not require opioid analgesics. Hospital stay ranged from 1 to 4 days. The only patient hospitalized for 4 days presented retrorectal hematoma after stitching, which was treated with local compression during the surgery and antibiotics for 7 days.

The patients were supervised for periods that varied from 6 months to 14 years. Three patients died within one to three years after the surgery, without signs of recurrence. Two patients have not been found anymore, but they were supervised up to one year after the surgery and did not present prolapse recurrence. One patient presented prolapse recurrence 2 months after the surgery (8.3%) and was again submitted to the same surgical technique, with good results. One patient presented residual anterior mucosal prolapse and was treated with local resection 6 months after rectopexy.

The functional result showed partial or total incontinence improvement in 6 patients (75%), and 2 incontinent patients (25%) did not presented alteration to fecal loss. The levator-muscle surgery was recommended to these incontinent patients, but it was not performed, following the decision of patients and their relatives. Patients with incontinence before the surgery did not present any change in this clinical aspect after the transanal rectopexy. Constipation, present in 40% of patients before the surgery, had no change. One patient that had no constipation before rectopexy reported obstructed evacuation in the first preoperative month. She was treated with mini enemas and fiber and presented spontaneous improvement. No mortality was seen with the technique described in this study.

DISCUSSION

Abdominal procedures for prolapse treatment are related to lower recurrence¹. The current abdominal surgery is based on rectopexy, as other procedures that do not include it have been discarded². However, rectal dissection is associated with constipation and obstructed evacuation⁹⁻¹¹, and the lateral ligament division increases such incidence¹². The recurrence rate after rectopexy with or without associated sigmoidectomy is the same^{13,14}.

Tabela 1. Clinical information of patients.

Age	Gender	Previous surgery	Comorbidities	Constipation	Incontinence
34	M	No	No	No	No
76	M	Delorme	Yes	No	Yes
62	F	No	No	Yes	No
64	F	No	No	No	Yes
69	F	No	Yes	No	Yes
71	F	Delorme	Yes	Yes	Yes
73	F	No	Yes	Yes	Yes
77	F	No	Yes	Yes	Yes
59	F	No	No	No	No
44	M	Delorme	No	No	No
88	M	No	Yes	No	Yes
73	F	No	Yes	Yes	Yes

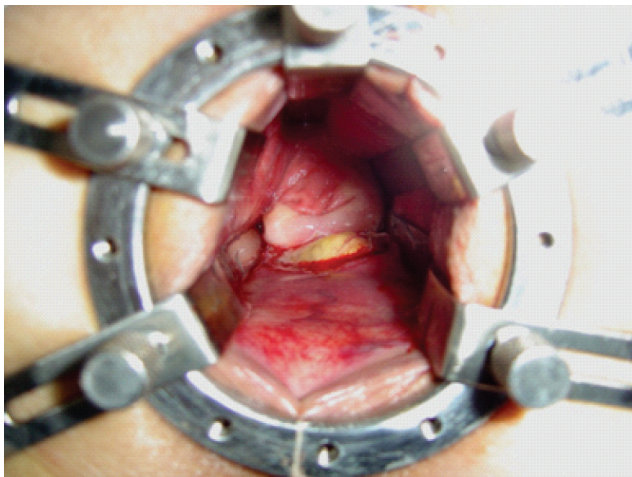


Figura 1. Incision on the rectal wall, exposing the mesorectum.

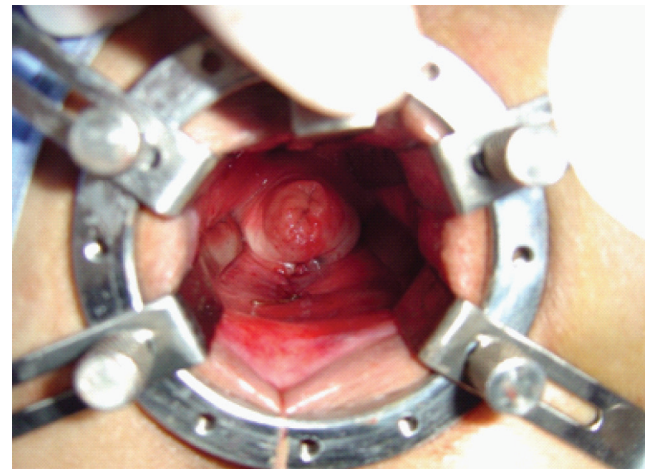


Figura 2. Rectal wall suture.

High morbidity rates of abdominal procedures used in pathologies associated with older age encouraged the development of perineal techniques. The prolapse treatment via perineal procedure has become the preferred choice in elderly and debilitated patients. These surgeries are safe, the anesthetic risk is low and the recovery is fast¹⁵, but they have presented higher recurrence rates than abdominal surgery.

Published studies present wide discrepancy in terms of recurrence after perineal rectosigmoidectomy, ranging from 0 to 60%¹. Functional results were also discouraging at first¹³, but they improved with

combined levator-muscle repair¹⁶⁻¹⁸. The combination of rectopexy with the Altemeier technique described by Prasad et al.⁷ shows the benefit of fixing the rectum to the sacrum, leading to lower recurrence. Despite the excellent functional results of this study, one death was reported among 25 patients. Anastomotic fistula occurred in another study series, in 16.6% of the patients¹⁹; then, resection and anastomosis are associated with high morbimortality²⁰.

Another study associated transanal rectopexy with Delorme surgery⁸, obtaining reduction in the recurrence rate, from 20 to 5%. Rectopexy was

performed only with the placement of absorbable mesh in the retrorectal space. Douglas pouch suture was also associated with this technique. This method also presented high morbidity rate, although not statistically significant.

The technical innovation presented in this study shows the benefits of rectopexy, a consolidated technique of lower recurrence rates, and the transanal approach advantages, which make the procedure fast and technically easy to be performed. The possibility of abscess occurrence seems to be discarded, as perirectal tissues are not dissected and synthetic meshes are not used. Hematomas may occur with the needle passing through the sacral fascia, but, in this study, the hematoma did not lead to complications and was

treated with local compression during the surgery. Levator-muscle repair was performed in the patient with persistent incontinence after the prolapse correction.

CONCLUSION

Transanal rectopexy uses the sphincter hypotonia, an anatomical aspect in patients with rectal prolapse, which makes it a relatively easy procedure. The recurrence rate was low, with minimum morbidity. Even treating patients at older ages, no mortality was seen with the technique described in this study. This is also a low cost technique. However, the comparison of this technique to other methods requires additional prospective studies.

REFERENCES

1. Henry MM, Swash M. Coloproctology and the pelvic floor. 2nd ed. Oxford: Butterworth – Heinemann Ltd.; 1996.
2. Nicholls RJ, Banerjee A. Rectal prolapse and solitary rectal ulcer syndrome. In: Nicholls RJ, Dozois RR (Eds). Surgery of the colon & rectum. New York: Churchill Livingstone; 1997. p. 709-37.
3. Lockhart Mummery JP. A new operation for prolapse of the rectum. Lancet 1910;1:641.
4. Wyatt AP. Perineal rectopexy for rectal prolapse. Br J Surg 1981;68:717-19.
5. Davidian VA, Thomas CG. Trans-sacral repair of rectal prolapse. Am J Surg 1972;123:231-5.
6. Rogers J, Jeffery PJ. Intersphincteric repair and Ivalon sponge rectopexy for the treatment of rectal prolapse. Br J Surg 1987;74:384-6.
7. Prasad ML, Pearl RK, Abcarian H, Orsay CP, Nelson RL. Perineal proctectomy, posterior rectopexy, and postanal levator repair for the treatment of rectal prolapse. Dis Colon Rectum 1986;29:547-52.
8. Lechaux JP, Lechaux D, Perez M. Results of Delorme's procedure for rectal prolapse. Dis Colon Rectum 1995;38:301-7.
9. Holmström B, Brodén G, Dolk A. Results of the Ripstein operation in the treatment of rectal prolapse and internal rectal procidentia. Dis Colon Rectum 1986;29:845-8.
10. Allen-Mersh TG, Turner MJ, Mann CV. Effect of abdominal Ivalon rectopexy on bowel habit and rectal wall. Dis Colon Rectum 1990;33:550-3.
11. Mann VC, Hofman C. Complete rectal prolapse: the anatomical and functional results of treatment by an extended abdominal rectopexy. Br J Surg 1988;75:34-7.
12. Speakman CT, Madden MV, Nicholls RJ, Kamm MA. Lateral ligament division during rectopexy causes constipation but prevents recurrence: results of a prospective randomized study. Br J Surg 1991;78:1431-3.
13. Watts JD, Rothenberger DA, Buls JG, Goldberg SM, Nivatvongs S. The management of procidentia: 30 years experience. Dis Colon Rectum 1985;28:96-102.
14. Mc Kee RF, Lauder JC, Poon FW, Aitchinson MA, Finlay IG. A prospective randomized study of abdominal rectopexy with and without sigmoidectomy in rectal prolapse. Surg Gynecol Obstet 1992;174:145-8.
15. Beck DE, Roberts PL, Rombeau JL, Stamos MJ, Wexner SD. The ASCRS Textbook of colon and rectal surgery. New York: Springer Science and Business Media; 2007.
16. Ramanujam PS, Venkatesh KS. Perineal excision of rectal prolapse with posterior levator ani repair in elderly high risk patients. Dis Colon Rectum 1988;31:704-6.
17. Bueno RN, Rocha JJR, Rodrigues RG, Feres O, Koga DY, Veneziano SG, et al. Proctossigmoidectomy via perineal no tratamento do prolapso retal. Acta Cir Bras 2001;16(Suppl 1):82-3.
18. Altemeier WA, Culbertson WR, Schowengerdt CJ, Hunt J. Nineteen years' experience with one stage perineal repair of rectal prolapse. Ann Surg 1971;173:993-1006.
19. Sobrado CW, Kiss DR, Nahas SC, Araujo SEA, Seid VE, Cotti G, et al. Surgical treatment of rectal prolapse: experience and late results with 51 patients. Rev Hosp Clin Fac Med S Paulo 2004;59:168-71.
20. Gordon PH. Rectal procidentia. In: Gordon PH, Nivatvongs S. Principles and practice of surgery for the colon, rectum and anus. St Louis, Missouri: Quality Medical Publisher; 1992. p. 449-81.

Correspondence to:

Rubens Henrique Oleques Fernandes
Rua Pinheiro Machado 2.321, sala 51
CEP: 95020-172 – Caxias do Sul (RS), Brazil
E-mail: olequesfernandes@terra.com.br