

## Proctocolectomy and ileal J-pouch anal anastomosis on the surgical treatment of familial adenomatous polyposis and ulcerative colitis: analysis of 49 cases

Bruno Amaral Medeiros<sup>1</sup>, Leonardo Estenio Iezzi<sup>1</sup>, Marley Ribeiro Feitosa<sup>1</sup>, Rogério Serafim Parra<sup>2</sup>, Ana Luiza Normanha Ribeiro de Almeida<sup>2</sup>, Raphael Gurgel de Carvalho<sup>1</sup>, Jose Joaquim Ribeiro da Rocha<sup>3</sup>, Omar Feres<sup>4</sup>

<sup>1</sup>MD; Resident of the Division of Coloproctology of the Department of Surgery and Anatomy of the Ribeirão Preto Medical School at Universidade de São Paulo (USP) – Ribeirão Preto (SP), Brazil. <sup>2</sup>MD; Research fellow of the Division of Coloproctology of the Department of Surgery and Anatomy of the Faculdade de Medicina de Ribeirão Preto da USP – Ribeirão Preto (SP), Brazil. <sup>3</sup>MD; PhD; Head of the Division of Coloproctology of the Department of Surgery and Anatomy of the Faculdade de Medicina de Ribeirão Preto da USP – Ribeirão Preto (SP), Brazil. <sup>4</sup>MD; PhD; Professor of Division of Coloproctology of the Department of Surgery and Anatomy of the Faculdade de Medicina de Ribeirão Preto da USP – Ribeirão Preto (SP), Brazil.

---

Medeiros BA, Iezzi LE, Feitosa MR, Parra RS, Almeida ALNR, Carvalho RG, Rocha JJR, Feres O. Proctocolectomy and ileal J-pouch anal anastomosis on the surgical treatment of familial adenomatous polyposis and ulcerative colitis: analysis of 49 cases. *J Coloproctol*, 2012;32(3): 260-264.

**ABSTRACT: Objective:** To evaluate the results of ileal J-pouch anal anastomosis in ulcerative colitis and familial adenomatous polyposis. **Method:** Retrospective analysis of medical records of 49 patients submitted to ileal J-pouch anal anastomosis. **Results:** Ulcerative colitis was diagnosed in 65% and familial adenomatous polyposis in 34%. Mean age was 39.5 years. 43% were male. Among familial adenomatous polyposis, 61% were diagnosed with colorectal cancer. Thirty-one percent of patients with ulcerative colitis was submitted to a previous surgical approach and 21% of these had toxic megacolon. Average hospital stay was 10 days. Post-operative complications occurred in 50% of patients with ulcerative colitis and 29.4% with familial adenomatous polyposis. Intestinal diversion was performed in 100% of ulcerative colitis and 88% of familial adenomatous polyposis. Pouchitis occurred in eight cases (seven ulcerative colitis and one FAP), requiring excision of the pouch in three ulcerative colitis. Mortality rate was 7.6%: two cases of carcinoma on the pouch and two post-operative complications. Late post-operative complications occurred in 22.4%: six familial adenomatous polyposis and five ulcerative colitis). Two patients had erectile dysfunction, and one retrograde ejaculation. One patient with severe perineal dermatitis was submitted to excision of the pouch. Incontinence occurred in four patients and two reported soil. Mean bowel movement was five times a day. **Conclusion:** Ileal J-pouch anal anastomosis is a safe surgery with acceptable morbidity and good functional results, if well indicated and performed in referral centers.

**Keywords:** adenomatous polyposis coli; colonic pouches; intestinal polyposis; proctocolitis.

**RESUMO: Objetivo:** Avaliar resultados da anastomose íleo-anal com bolsa ileal em J na colite ulcerativa e na polipose adenomatosa familiar. **Método:** Análise retrospectiva dos prontuários de 49 pacientes submetidos a anastomose íleo-anal com bolsa ileal em J. **Resultados:** 65% de colite ulcerativa e 34% de polipose adenomatosa familiar. Idade média de 39,5 anos. Gênero masculino perfaz 43% da amostra. Na polipose adenomatosa familiar, 61% tinham diagnóstico prévio de câncer colorretal. Na colite ulcerativa, 31% tiveram abordagem cirúrgica prévia (21% por megacólon tóxico). O tempo médio de internação foi de 10 dias. Complicações pós-operatórias ocorreram em 50% das colites ulcerativas e 29,4% de polipose adenomatosa familiar. Foi realizada ileostomia em 100% das colites ulcerativas e 88% das poliposes adenomatosas familiares. Bolsite ocorreu em oito casos: em sete colites ulcerativas e em uma polipose adenomatosa familiar, com ressecção da bolsa em três colites ulcerativas. Taxa de mortalidade de 7,6%: dois casos de câncer na bolsa e duas complicações pós-operatórias. Complicações tardias

---

*Study carried out at the Division of Coloproctology of the Department of Surgery and Anatomy of the Ribeirão Preto Medical School at Universidade de São Paulo (USP) – Ribeirão Preto (SP), Brazil.*

*Financing source: none.*

*Conflicts of interest: nothing to declare.*

---

*Submitted on: 04/04/2012*

*Approved on: 11/05/2012*

ocorreram em 22,4%: em seis poliposes adenomatosas familiares e cinco colites ulcerativas. Dois pacientes apresentaram disfunção erétil e uma ejaculação retrógrada. Um paciente teve dermatite perineal severa (realizada ressecção da bolsa). Foi observada incontinência em quatro pacientes e escape fecal em dois. Média de hábito intestinal: cinco vezes ao dia. **Conclusão:** Anastomose íleo-anal com bolsa ileal é uma cirurgia com aceitável morbidade e bons resultados funcionais, quando bem indicada e realizada em centros de referência.

**Palavras-chave:** polipose adenomatosa do colo; bolsas do colo; polipose intestinal, proctocolite.

## INTRODUCTION

Proctocolectomy and ileal pouch-anal anastomosis (IPAA) was first idealized by Nissen in 1933 to pediatric patients with familial adenomatous polyposis (FAP)<sup>1</sup>. Ravitch and Sabiston<sup>2</sup> and Ravitch<sup>3</sup> associated rectal mucosectomy and suturing of ileal mucosa to dentate line, with poor results.

Later technique modifications improved partially the results, but without large acceptance<sup>4-7</sup>. Only in 1980 Utsunomiya, a J ileal pouch was devised, with satisfactory post-operative results, including good quality of life<sup>8</sup>.

With these technical modifications, and confirmed relationship between capacity of “neorectum” and functional outcome<sup>9</sup>, proctocolectomy with IPAA became the ideal surgical treatment for most patients with refractory ulcerative colitis (UC) and selected cases of FAP.

The complications severity depends on the patient previous diagnoses, usually worst on UC. Nutritional status, previous surgery, size of pouch and even presence of intestinal diversion are involved on prognosis<sup>10-12</sup>.

Although stapler adoption, improved pre and post-operative cares and antibiotics, early and late postoperative complications (anastomotic leakage, fistula, pouchitis, dysplasia and even pouch carcinoma) may occur.

We decided to assess the results of IPAA in 49 patients with UC or FAP.

## METHODS

Medical records of 49 patients submitted to proctocolectomy with IPAA were analyzed including age at surgery, gender, diagnosis, previous surgeries, surgical time, hospital stay, functional results and postoperative complications (surgical material and technique shown in Figures 1 and 2).

## RESULTS

Thirty-two patients (65%) were diagnosed with UC and 17 (34%) with FAP. Average age was 39.5 years. Forty-three percent were male. Among FAP, 61% were diagnosed with colorectal carcinoma by colonoscopy.

Twenty-one percent of the patients with UC had toxic megacolon, 31% had undergone a surgical approach before the IPAA (usually subtotal colectomy) and half of the patients presented other complications (bleeding requiring transfusion or surgery, peritonitis or severe dysplasia on endoscopic examination).

Mean operative time was 4 hours and 30 minutes (4 hours and 36 minutes FAP *versus* 4 hours and 27 minutes UC). This time included patients from the beginning of the surgical experience on our hospital and some cases performed manual anastomosis (2 hours and 30 minutes, with mechanic anastomosis).

Average hospital stay was 10 days (5 to 57 days): 10.1 FAP and 10.7 UC. Fifty percent of patients with UC had surgical complications in the early postopera-

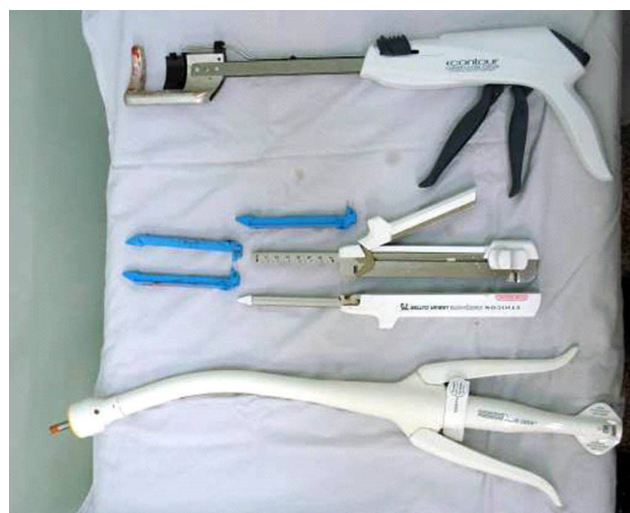

Figure 1. Linear, circular and curved cutter staplers.

tive period (we cite 18% had anastomotic stenosis and 15.6% pouch-anal anastomotic leakage).

Early surgical complications occurred in 29.4% of FAP: three cases of stenosis of the anastomosis, one pouch-anal anastomotic leakage and one anastomotic leak to incision fistula.

Intestinal diversion was performed in 100% of UC and 88% FAP. The closure of the ileostomy was performed in 87.5% UC and 76.4% FAP.

Pouchitis occurred in eight cases: 16.3% (seven UC and one FAP), requiring the excision of pouch in three UC.

Late post-operative complications (intestinal obstruction, erectile dysfunction, pelvic abscess and liver) occurred in 22.4% of cases, six cases in patients with PAF and five in patients with UC). Two patients had erectile dysfunction, and one retrograde ejacula-

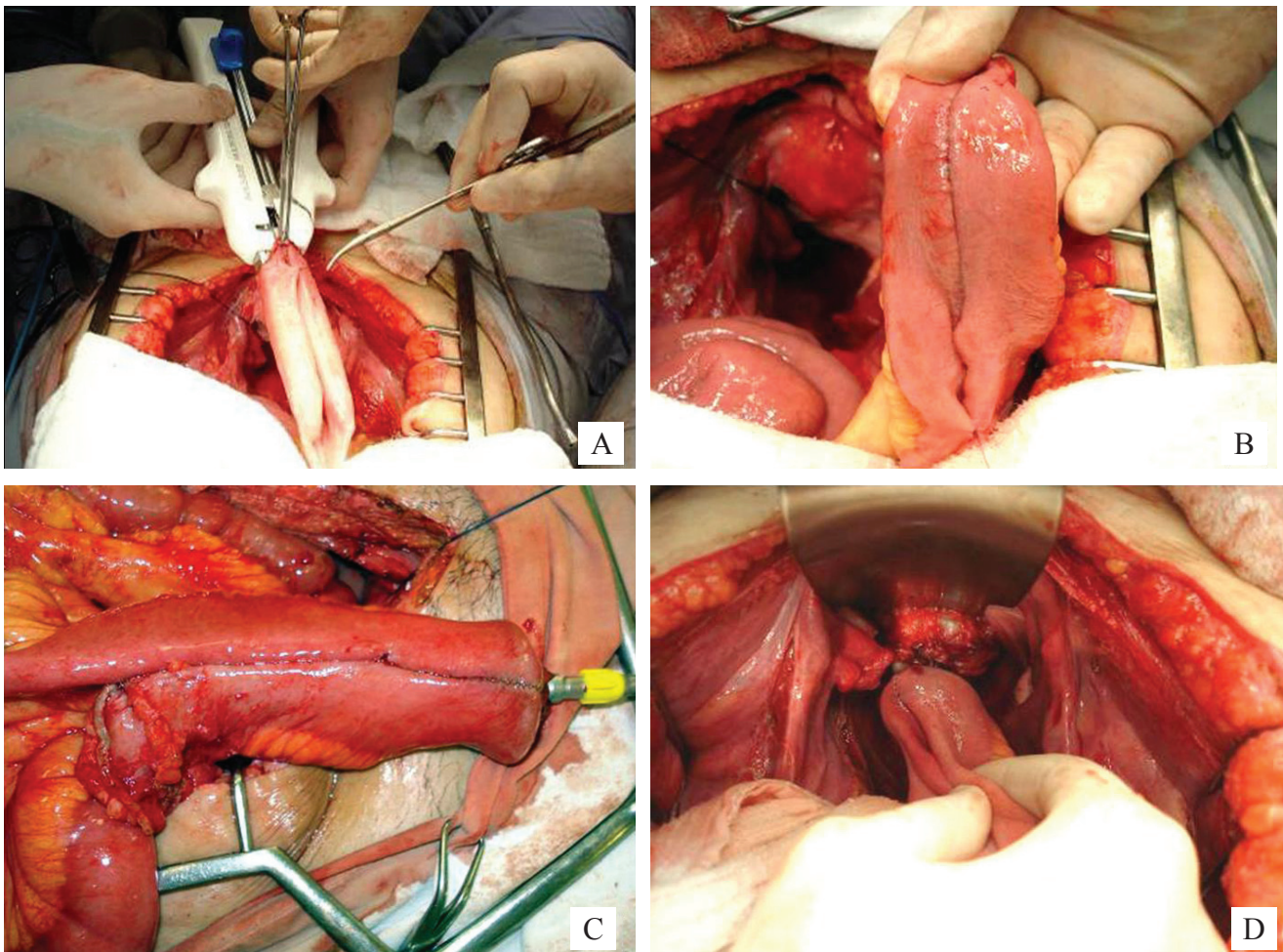
tion. Incontinence was observed in 6.1% of cases. One patient (1.9%) with a severe case associated to severe perineal dermatitis was submitted to performed excision of pouch. Two (3.8%) reported soil. Mean bowel movement was five times a day (3 to 20).

One patient was evaluated with urinary tract infection and mortality rate was 7.6%: two cases of carcinoma on J pouch and two postoperative complications.

## DISCUSSION

Most patients had UC (65%; 32 patients); 34% (17) had FAP.

The majority of patients with FAP (61%) were admitted with colorectal carcinoma (from *in situ* to 'T4' stage tumors). We attribute this data to delay since symptoms onset until search for medical treatment.



**Figure 2.** Creation of J-pouch. (A) First linear stapling. (B) Ileal J-pouch. (C) Preparing to anastomosis. (D) Ileal pouch-anal anastomosis.



Twenty-one percent of the patients with UC had previously toxic megacolon and 31% undergone a surgical approach before the IPAA (usually subtotal colectomy and terminal ileostomy or ileorectal anastomosis).

Half of the patients presented other complications (bleeding, peritonitis or severe dysplasia on endoscopic examination), similar to Langenbecks Fazio and Pemberton<sup>13-15</sup>.

Average operative time – 4 hours and 30 minutes – improved with stapler anastomosis (2 hours and 30 minutes) and the diagnoses do not affect average hospital stay (10.1 days for FAP *versus* 10.7 days for UC) or procedure length (4 hours and 36 minutes for FAP *versus* 4 hours and 27 minutes for UC).

Early postoperative complications were more common on UC (51%: 18% had anastomotic stenosis and 15.6%, pouch-anal anastomotic leakage) than FAP (29.4%: three cases of stenosis of the anastomosis, one pouch-anal anastomotic leakage and one IPAA fistula).

Our preference is to perform IPAA with a loop ileostomy (to prevent impact of an anastomotic leak, mainly on UC using steroids). 100% with UC and 88% with FAP) and closed in 87.5% with UC and 76.4% with FAP<sup>16,17</sup>.

Pouchitis occurred in eight cases (16.3%): seven of UC and one of FAP. The three excisions

of IPAA, converted to terminal ileostomy, occurred on UC. Two patients had severe pouchitis (biopsy posteriorly suggested Cröhn's disease) and one patient had severe perineal dermatitis and extensive cellulitis.

Mortality rate (7.6%), late post-operative complications like intestinal obstruction, erectile dysfunction and pelvic abscess (22.4%, six cases in patients with PAF and five in patients with UC) are similar to other authors<sup>18,19</sup>.

Two patients had erectile dysfunction, and one of these, retrograde ejaculation. Incontinence was observed on four patients (8.1%). Two patients (3.8%) reported nocturne soil. Mean bowel movement was five times a day (3 to 20).

## CONCLUSION

This study suggests IPAA is a safe surgery with acceptable morbidity, if well indicated and performed by a specialized team in referral centers. It provides satisfactory functional results and can avoid permanent ileostomy. The low postoperative morbidity and mortality and good functional results demonstrate the effectiveness of the IPAA surgery.

**Table 1.** Operative complications of ileal pouch-anal anastomosis on familial adenomatous polyposis and ulcerative colitis patients.

	Operative complications and adverse outcomes in each group				
	PAF (n=17)		UC (n=32)		Total
	n	%	n	%	
Anastomotic stenosis	3	17.65	7	41.18	10
Anastomotic leakage	1	5.88	4	23.53	5
Anastomotic fistula	1	5.88	1	5.88	2
Intestinal obstruction	3	17.65	1	5.88	4
Liver abscess	1	5.88	0	0.00	1
Erectil dysfunction	1	5.88	1	5.88	2
Incontinence	1	5.88	3	17.65	4
Pouchitis	1	5.88	7	41.18	8
Mortality	2	11.76	2	11.76	4
Deep-vein thrombosis	0	0.00	1	5.88	1
Excision of pouch	0	0.00	3	17.65	3
Post-operative Pneumonia	0	0.00	1	5.88	1
Urinary tract infection	1	5.88	2	11.76	3
<b>Total</b>	<b>15</b>	<b>100</b>	<b>33</b>	<b>100</b>	<b>48</b>

## REFERENCES

1. Nissen R. Demonstrationen aus der operativen chirurgie zunachst einige Beobachtungen aus der palstichen Chirurgie. *Zentralbl Chir* 1933;60:883.
2. Ravitch M, Sabiston DC. Anal ileostomy with preservation of the sphincter. *Surg Gynecol Obstet* 1947;84(6):1095-9.
3. Ravitch M. Anal ileostomy with sphincter preservation in patients requiring total colectomy for benign conditions. *Surgery* 1948;24(2):170-87.
4. Parks AG, Nicholls RJ. Proctocolectomy without ileostomy for ulcerative colitis. *Br Med J* 1978;2(6130):85-8.
5. Herbst F, Sielezneff I, Nicholls RJ. Salvage surgery for ileal pouch outlet obstruction. *Br J Surg* 1996;83(3):368-71.
6. Beart RW Jr, McIlrath DC, Kelly KA, Van Heerden JA, Mucha P Jr, Dozois RR, et al. Surgical management of inflammatory bowel disease. *Curr Probl Surg* 1980;17(10):533-84.
7. Martin LW, LeCoultre C, Schubert WK. Total colectomy and mucosal proctectomy with preservation of continence in ulcerative colitis. *Ann Surg* 1977;186(4):477-80.
8. Utsunomiya J, Iwama T, Imajo M, Matsuo S, Sawai S, Yaegashi K, et al. Total colectomy, mucosal proctectomy, and ileoanal anastomosis. *Dis Colon Rectum* 1980;23(7):459-66.
9. O'Connell PR, Pemberton JH, Kelly KA. Motor function of the ileal J pouch and its relation to clinical outcome after ileal pouch-anal anastomosis. *World J Surg* 1987;11(6):735-41.
10. Lovegrove RE, Tilney HS, Heriot AG, von Roon AC, Athanasiou T, Church J, et al. A comparison of adverse events and functional outcomes after restorative proctocolectomy for familial adenomatous polyposis and ulcerative colitis. *Dis Colon Rectum* 2006;49(9):1293-306.
11. Hurst RD, Molinari M, Chung TP, Rubin M, Michelassi F. Prospective study of the incidence, timing and treatment of pouchitis in 104 consecutive patients after restorative proctocolectomy. *Arch Surg* 1996;131(5):497-500; discussion 501-2.
12. Lovegrove RE, Symeonides P, Tekkis PP, Goodfellow PB, Shorthouse AJ. A selective approach to restorative proctocolectomy without ileostomy: A single centre experience. *Colorectal Dis* 2008;10(9):916-24.
13. Mennigen R, Senninger N, Bruewer M, Rijcken E. Pouch function and quality of life after successful management of pouch-related septic complications in patients with ulcerative colitis. *Langenbecks Arch Surg* 2012;397(1):37-44.
14. Fazio VW, Ziv Y, Church JM, Oakley JR, Lavery IC, Milsom JW, et al. Ileal pouch-anal anastomoses complications and function in 1005 patients. *Ann Surg* 1995;222(2):120-7.
15. Pemberton JH, Kelly KA, Beart RW Jr, Dozois RR, Wolff BG, Ilstrup DM. Ileal pouch-anal anastomosis for chronic ulcerative colitis. Long-term results. *Ann Surg* 1987;206(4):504-13.
16. Tjandra JJ, Fazio VW, Milsom JW, Lavery IC, Oakley JR, Fabre JM. Omission of temporary diversion in restorative proctocolectomy – is it safe? *Dis Colon Rectum* 1993;36(11):1007-14.
17. Cohen Z, McLeod RS, Stephen W, Stern HS, O'Connor B, Reznick R. Continuing evolution of the pelvic pouch procedure. *Ann Surg* 1992;216(4):506-11.
18. von Roon AC, Tekkis PP, Lovegrove RE, Neale KF, Phillips RK, Clark SK. Comparison of outcomes of ileal pouch-anal anastomosis for familial adenomatous polyposis with and without previous ileorectal anastomosis. *Br J Surg* 2008;95(4):494-8.
19. McGuire BB, Brannigan AE, O'Connell PR. Ileal pouch-anal anastomosis. *Br J Sg* 2007;94(7):812-23.

### Correspondence to:

Omar Feres  
Divisão de Coloproctologia do Departamento de Cirurgia e Anatomia da Faculdade de Medicina de Ribeirão Preto da Universidade de São Paulo  
Avenida Bandeirantes, 3.900 – Campus da USP  
14048-900 – Ribeirão Preto (SP), Brazil  
E-mails: omar.feres@hspaulo.com.br e brunoamedeiros@yahoo.com.br