

Intestinal obstruction caused by phytobezoar composed of jaboticaba seeds: case report and literature review

Rafael Luís Luporini¹, Lícia Deon Weirich², Marcelo Rodolfo Marciano³, Luiz Vagner Sipriani⁴, Francisco de Assis Gonçalves Filho⁵, Anwar Fausto Félix Sabbag⁶, Marcelo Maia Caixeta Melo⁷, Luís Sérgio Ronchi⁸, Geni Satomi Cunrath⁹, João Gomes Netinho¹⁰

¹Coloproctologist, School of Medicine at São José do Rio Preto (FAMERP) – São José do Rio Preto (SP), Brazil.

²Physician, FAMERP – São José do Rio Preto (SP), Brazil. ³Coloproctologist, FAMERP – São José do Rio Preto (SP), Brazil. ⁴Coloproctologist, FAMERP – São José do Rio Preto (SP), Brazil. ⁵Coloproctologist, FAMERP – São José do Rio Preto (SP), Brazil. ⁶General Surgeon, FAMERP – São José do Rio Preto (SP), Brazil. ⁷Coloproctologist; Master in Health Sciences, FAMERP – São José do Rio Preto (SP), Brazil. ⁸Coloproctologist, FAMERP – São José do Rio Preto (SP), Brazil. ⁹Coloproctologist; Master in Health Sciences, FAMERP – São José do Rio Preto (SP), Brazil. ¹⁰Coloproctologist; Master in Health Sciences, FAMERP – São José do Rio Preto (SP), Brazil; Doctor in Surgery, Universidade Estadual de Campinas (Unicamp) – Campinas (SP), Brazil.

Luporini RL, Weirich LD, Marciano MR, Sipriani LV, Filho FAG, Sabbag AFF, Melo MMC, Ronchi LS, Cunrath GS, Netinho JG. Intestinal obstruction caused by phytobezoar composed of jaboticaba seeds: case report and literature review. **J Coloproctol**, 2012;32(3): 308-311.

ABSTRACT: Bezoar is a cluster of swallowed and undigested material in the gastrointestinal tract which can cause intestinal obstruction. It has multiple subtypes and the phytobezoar (composed of vegetable fiber) is the most common. We report a patient admitted with intestinal obstruction caused by impaction of multiples seeds of jaboticaba in the rectum. The treatment included multiple enemas, laxatives and digital maneuvers and it was effective after four days. Only one similar report was found in the literature.

Keywords: intestinal obstruction; bezoars; rectum; seeds.

RESUMO: Bezoar trata-se de um aglomerado de material deglutido e não digerido no trato gastrointestinal que pode causar quadro de obstrução intestinal. Existem múltiplos subtipos, sendo o mais comum o fitobezoar (composto por fibras vegetais). Foi relatado o caso de uma paciente admitida com quadro de suboclusão intestinal causada por impactação de múltiplos caroços de jaboticaba em reto. O tratamento instituído foi conservador com múltiplos enteroclimas, laxativos e quebra digital, efetivos após quatro dias. Somente um caso semelhante foi encontrado na literatura.

Palavras-chave: obstrução intestinal; bezoares; reto; sementes.

Study carried out at the Hospital de Base de São José do Rio Preto, Discipline of Coloproctology, School of Medicine at São José do Rio Preto (FAMERP) – São José do Rio Preto (SP), Brazil.

Financing source: none.

Conflict of interest: nothing to declare.

Submitted on: 07/07/2011

Approved on: 07/19/2011

INTRODUCTION

Bezoar is a cluster of swallowed and undigested material in the gastrointestinal tract¹. Its most common subtype, phytobezoar, is composed of vegetable fiber^{1,2}. Bezoar may produce symptoms due to its potential to cause mechanical obstruction³. These symptoms are more frequently observed in the stomach, but they may be found in other portions of the digestive tract⁴. Intestinal obstruction caused by phytobezoar composed of seeds with impaction in the rectum is a rare event.

The purpose of this study was to report a rare case of intestinal obstruction caused by seeds of jaboticaba (*Myrciaria spp*) impacted in the rectum.

CASE REPORT

A 42-year-old female patient, living in the urban area, was admitted with complaint of intense abdominal pain, similar to colic, for 5 days. In addition, she reported reduced flatulence and no evacuation in this period. She denied any nausea, vomiting, fever, anorexia and any other complaint. She used laxatives without symptom improvement. After being questioned about any factor that could have contributed to those symptoms, she reported copious ingestion of jaboticabas two days before her condition started (Figure 1).

At the physical examination, she presented pain in deep palpation of the abdomen, especially in the hypogastrium, and abdominal distension. She had no signs of peritoneal irritation. Abdominal auscultation detected bowel sounds. Digital rectal exam was performed, showing moving hardened nodules in the rectum.

Abdominal radiography showed only stool in the colon (Figure 2). As the symptoms persisted, the patient was submitted to computed tomography of the abdomen, which showed solid nodules in the rectum and excluded the possibility of other expansive lesions that could have caused the intestinal obstruction (Figure 3).

After multiple enemas, laxatives and successive attempts of manual removal of nodules, the patient evacuated a large amount, eliminating the seeds and improving from her initial condition in four days. Today, the patient is normal, without recurrent obstruction.



Figura 1. Jaboticaba tree.

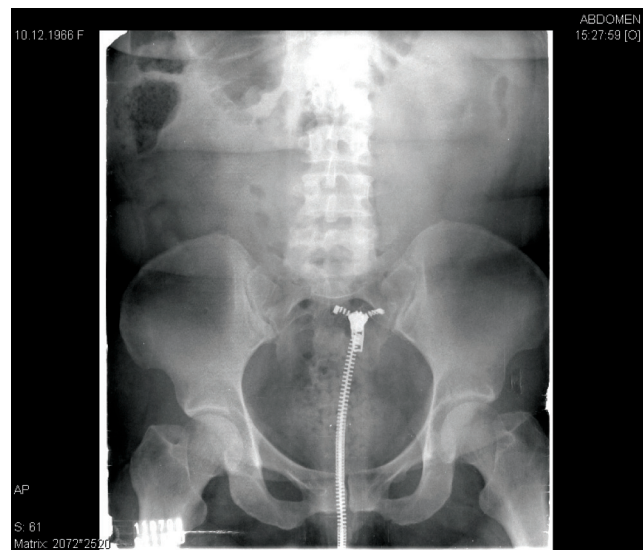

Figura 2. Abdominal radiography showing stool in rectal ampulla.

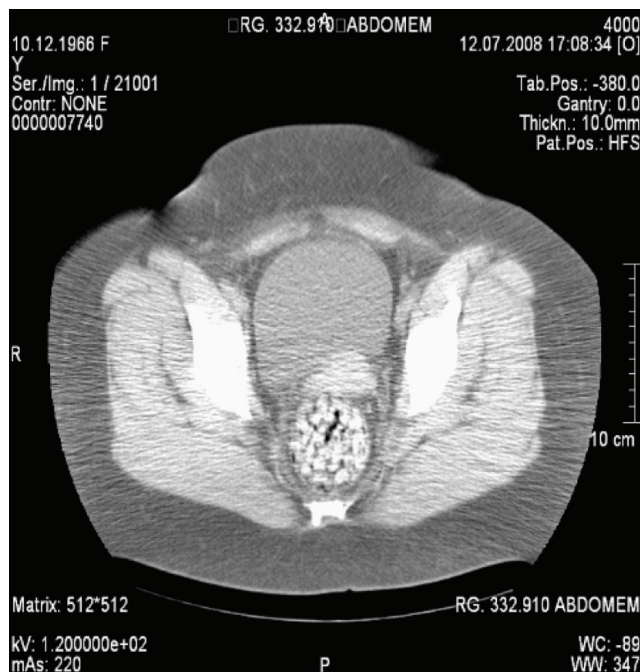


Figura 3. Computed tomography showing rectal nodules.

DISCUSSION

Bezoar is a cluster of swallowed and undigested material¹. It is classified according to its composition as phytobezoar (vegetable fiber), trichobezoar (hair), lactobezoar (milk), among others^{1,2}. Phytobezoar is the most common type. It is usually observed in elderly patients with deficient chewing due to lack of teeth or fast deglutition⁴ and in patients with prior gastric surgeries (especially after truncular vagotomy associated with partial gastrectomy or pyloro-

plasty for correction of peptic ulcer⁵). Other possible causes are: diet based on indigestible fibers⁵, diabetes⁶, hypothyroidism, muscular dystrophy⁷, gastric cancer⁸ or the chronic use of cimetidine⁹. The most common location of phytobezoars is the stomach, but they may be located also in other portions of the digestive tube⁴. Phytobezoars correspond to 40% of total bezoars¹, and prior gastric surgery is the main factor leading to such formation^{5,10}.

Phytobezoar is usually made of seeds, roots, peels, fibers, cellulose, tannin, lignin and products of fruits and vegetables, such as pineapple and kaki^{1,11,12}. The most common types of phytobezoar composed of seeds include sunflower seeds, cactus fruit and watermelon seeds¹³.

Although its most frequent site is the stomach and rarely in the colon¹⁰, this case report shows an intestinal obstruction due to phytobezoar composed of jaboticaba seeds impacted in the rectum, which is a very rare occurrence¹³. Only one case of intestinal obstruction caused by phytobezoar composed of seeds of jaboticaba (*Myrciaria spp*) had been reported so far in the literature¹⁴.

The symptoms of bezoars is unspecific, insidious and gradual or intermittent, and may vary greatly depending on the site. As they increase, bezoars may cause anorexia, weight loss and abdominal discomfort related to the meals. When obstruction occurs, the main symptoms are vomiting and abdominal colic³.

Benzoars should be preferably treated using conservative methods¹⁵. In the case reported in this study, the conservative method successfully eliminated the problem.

REFERENCES

1. Coelho JCU, Gonçalves CG, Madureira Filho D. Bezoar. In: Coelho JCU. Aparelho digestivo: clínica e cirurgia. 3a ed. São Paulo: Atheneu; 2004. p. 595-9.
2. Bandeira Ferraz AA, Tavares de Sá VC, Arruda PCL, Leão CS, Campos JM, Ferraz EM. Obstrução gastrointestinal por fitobezoar na cirurgia bariátrica. Rev Col Bras Cir 2006;33(1):35-8
3. Dasgupta HK, Chandra SS, Gupta M, Sanwal BL, Bhargava SC, Vaid RL. Trichobezoar: clinical diagnosis (a case report). J Postgrad Med 1979;25(3):181-2.
4. Madura MJ, Naughton BJ, Craig RM. Duodenal bezoar: a case report and review of the literature. Gastrointest Endosc 1982;28(1):26-8.
5. Escamilla C, Robles-Campos R, Parrilla-Paricio P, Lujan-Mompean J, Liron-Ruiz R, Torralba-Martinez JA. Intestinal obstruction and bezoars. J Am Coll Surg 1994;179(3):285-8.
6. Grimaldi A, Engels J, Brassier D, Maisani E. Phytobezoard secondaire à une gastropathie diabétique. Nouv Presse Med 1982;11(4):282.
7. Kuiper DH. Gastric bezoar in a patient with myotonic dystrophy. A review of the gastrointestinal complications of myotonic dystrophy. Dig Dis 1971;16(6):529-34.
8. Van Thiel DH, DeBelle RC, Painter TD, McMillan WB, Haradin AR. Phytobezoa occurring as a complication of

- gastric carcinoma. *Gastroenterology* 1975;68(5 Pt 1):1292-6.
9. Tolia V, Dubois RS. Lactobezoar in prematurity. A case with prolonged resolution. *Clin Pediatric* 1981;20(10):651-3.
 10. Andrus CH, Ponsky JL. Bezoars: classification, pathophysiology, and treatment. *Am J Gastroenterol* 1988;83(5):476-8.
 11. Erzurumlu K, Malazgirt Z, Bektas A, Dervisoglu A, Polat C, Senyurek G, et al. Gastrointestinal bezoars: a retrospective analysis of 34 cases. *World J Gastroenterol* 2005;11(12):1813-7.
 12. Hayes PG, Rotstein OD. Gastrointestinal phytobezoars: presentation and management. *Can J Surg* 1986;29(6):419-20.
 13. Eitan A, Bickel A, Katz IM. Fecal impaction in adults: report of 30 cases of seed bezoars in the rectum. *Dis Colon Rectum* 2006;49(11):1768-71.
 14. Martins CMG, Nascimento NB. Caroços de jaboticaba desencadeando quadro de suboclusão intestinal. *Rev Fac Cienc Med de Sorocaba* 2006;8(2):31.
 15. Spadella CT, Saad-Hossne R, Saad LHC. Tricobezoar gástrico: relato de caso e revisão da literatura. *Acta Cir Bras* 1998;13(2):110-5.

Correspondence to:

Rafael Luís Luporini
Rua 15 de Novembro, 3426
13569-220 – São Carlos (SP), Brasil
E-mail: rafaelluisluporini@yahoo.com.br