



# Journal of Coloproctology

www.jcol.org.br



## Original article

# APC protein immunoreexpression in colorectal adenoma and adenocarcinoma<sup>☆</sup>

Vivian Sati Oba Bourroul<sup>a,b,\*</sup>, Guilherme Muniz Bourroul<sup>c</sup>, Giovanna Canato Tolo<sup>d</sup>, Rogério Tadeu Palma<sup>a,e</sup>, Celina Tizuko Fujiyama Oshima<sup>f</sup>, Thiago Simão Gomes<sup>g</sup>, Sílvia Saiuli Miki Ihara<sup>g</sup>, Jaques Waisberg<sup>h</sup>

<sup>a</sup>Service of Digestive System Surgery of Hospital do Servidor Público Estadual (HSPE), São Paulo, SP, Brazil

<sup>b</sup>Service of Digestive System Surgery of Hospital Estadual Mário Covas, Santo André, SP, Brazil

<sup>c</sup>Service of Digestive System Surgery of Hospital Estadual Mário Covas, Santo André, SP, Brazil

<sup>d</sup>Faculdade de Medicina do ABC, São Paulo, SP, Brazil

<sup>e</sup>Discipline of Service of Digestive System Surgery of Faculdade de Medicina do ABC, São Paulo, SP, Brazil

<sup>f</sup>Laboratory of Molecular Pathology of Escola Paulista de Medicina da Universidade Federal de São Paulo (EPM-UNIFESP), São Paulo, SP, Brazil

<sup>g</sup>Laboratory of Molecular Pathology, Department of Pathology, EPM-UNIFESP, São Paulo, SP, Brazil

<sup>h</sup>General and Digestive System Surgery of Faculdade de Medicina do ABC, São Paulo, SP, Brazil

## ARTICLE INFO

### Article history:

Received 12 May 2013

Accepted 10 June 2013

### Keywords:

Colorectal neoplasms

Carcinoma

Adenoma

APC Gene

Immunohistochemistry

Biological tumor markers

## ABSTRACT

**Background:** activation of the Wnt pathway by mutated APC gene is considered the initial event in colorectal carcinogenesis. The identification of these mutations can improve the specific treatment of the adenocarcinoma.

**Objective:** detect and evaluate wild-type APC protein in tissue from colorectal adenoma, adenocarcinoma and adjacent mucosa.

**Methods:** 42 patients that underwent surgery for adenocarcinoma and 53 patients with resected adenomas were studied. Tissue samples from the adenocarcinoma were obtained from the tumor and from adjacent non-neoplastic mucosa located 10 cm from the proximal margin of the tumor. Adenoma tissue was obtained from representative areas. Blocks of tissue microarray (TMA) were submitted to immunohistochemistry with anti-APC, with readings of positivity and intensity of immunostaining and the score of immune expression of APC protein was obtained.

**Results:** the APC protein immune expression score showed a significantly lower expression of APC protein in the adenoma when compared with the adenocarcinoma ( $p < 0.0001$ ) and adjacent mucosa ( $p < 0.0001$ ). The APC protein immune expression score in the colorectal mucosa and adjacent to the adenocarcinoma showed no significant difference ( $p = 0.24$ ).

**Conclusions:** the finding of decreased expression of APC protein in adenoma tissue may indicate that the mutated APC gene may contribute to the changes in the adenoma-carcinoma process of carcinogenesis sequence. The strong expression of protein APC in tissues from

<sup>☆</sup> Support: Coordenação de Aperfeiçoamento de Pessoal de Nível Superior (CAPES) and Fundação de Amparo a Pesquisa do Estado de São Paulo (FAPESP) 2009/17420-7.

\* Corresponding author.

E-mail: viviansatioba@yahoo.com.br (V.S.O. Bourroul)

2237-9363/\$ - see front matter. © 2013 Elsevier Editora Ltda. All rights reserved.

<http://dx.doi.org/10.1016/j.jcol.2013.06.002>

the carcinoma and adjacent mucosa suggests that in most patients in this series, the mutation of the APC gene did not participate in the oncogenesis mechanism.

© 2013 Elsevier Editora Ltda. All rights reserved.

## Imunoexpressão da proteína APC nos tecidos de adenoma e de adenocarcinoma colorretais

### R E S U M O

#### Palavras-chave:

Neoplasias colorretais  
Carcinoma  
Adenoma  
Gene APC  
Imunoistoquímica  
Marcadores biológicos de tumor

**Racional:** a ativação da via Wnt pelo gene APC mutado é considerado evento inicial da carcinogênese colorretal. A identificação dessas mutações pode tornar o tratamento do adenocarcinoma mais específico.

**Objetivo:** detectar e avaliar a proteína APC não mutada em tecidos de adenoma, adenocarcinoma e mucosa adjacente.

**Método:** estudados 42 doentes operados de adenocarcinoma e 53 com adenomas ressecados. Tecidos de adenocarcinoma foram obtidas da neoplasia e da mucosa adjacente não neoplásica situadas a 10 cm da margem proximal do tumor. Tecidos do adenoma foram obtidas de área representativa. Blocos de tissue microarray (TMA) foram submetidos a imuno-histoquímica com anticorpo anti-APC. Avaliadas a positividade e intensidade da expressão e obtidos escores da imunoexpressão da proteína APC.

**Resultados:** o escore da imunoexpressão da proteína APC no adenoma foi significativamente menor do que no adenocarcinoma ( $p < 0,0001$ ) e na mucosa adjacente ( $p < 0,0001$ ). O escore da imunoexpressão da proteína APC na mucosa adjacente e no adenocarcinoma não mostraram diferença significativa ( $p = 0,24$ ).

**Conclusões:** a menor expressão da proteína APC no adenoma pode indicar que o gene APC mutado participa das alterações do processo adenoma-carcinoma. A forte expressão da proteína APC no CCR e na mucosa adjacente sugerem que a mutação do gene APC não participou da oncogênese.

© 2013 Elsevier Editora Ltda. Todos os direitos reservados.

## Introduction

Colorectal cancer (CRC) is the second most common malignancy in the West. Although 15-20% of CRC cases occur in the context of positive family history of the disease, specific genetic alterations in familial and sporadic adenocarcinomas are not yet completely known.<sup>1</sup>

In sporadic CRC, mutations in the APC and k-ras genes and p53 protein are evident, but mutations in all three genes are rarely found in the same tumor.<sup>2</sup>

APC gene comprises 108,352 bp at position 21q in chromosome 5 and has 21 exons encoding a protein with multiple functional domains that interact with proliferation and apoptosis regulators.<sup>3</sup>

The gene is mutated in 63% of sporadic adenomas<sup>4</sup> and in over 80% of sporadic CRC cases<sup>5</sup> being inherent as heterozygous mutation in all cases of familial adenomatous polyposis (FAP).<sup>3</sup>

The APC gene encodes a protein of 312 kDa with 2843 amino acids. The APC gene inhibits the members of Wnt signaling pathway that promotes  $\beta$ -catenin expression as a stimulator of cell division within the intestinal crypts.<sup>6</sup> A central region of APC protein is involved in  $\beta$ -catenin downregulation. This central region contains four segments with 15-amino acid repeats and seven segments with 20 amino-acid repeats.<sup>7</sup>

A characteristic of the Wnt pathway activation is the nuclear accumulation of its main effector, the  $\beta$ -catenin, an

activation component of the transcriptional complex that includes members of the TCF/LEF (T-cell transcription factor/Lymphoid enhancer-binding factor), and consequently activating target genes in carcinogenesis.<sup>4,8,9,10</sup>

In detail, the activation of the Wnt pathway occurs when Wnt proteins bind to frizzled receptors and act as paracrine proteins starting transduction of several signaling pathways. The canonical Wnt signaling pathway stabilizes  $\beta$ -catenin transcription.<sup>11</sup> The several domains of APC protein allow its interaction with numerous partner proteins, including  $\beta$ -catenin and axin, and is involved in several cellular processes.<sup>10</sup> The truncated APC protein disrupts the regulation of  $\beta$ -catenin-proteasome cellular concentration, blocking its degradation. The critical point is the  $\beta$ -catenin phosphorylation into Ser 33 and Ser 37 by phosphoglycerate dehydrogenase, which catalyzes the first step in the biosynthesis of glycine inside the APC/axin complex, known as the " $\beta$ -catenin destruction complex." The Phospho-Ser33/37- $\beta$ -catenin complex comprises the recognition sequence for the ubiquitin subtype called E3 ligase  $\beta$ TrCP ( $\beta$  transduction repeat containing protein), resulting in "ubiquitination" and subsequent degradation of  $\beta$ -catenin.<sup>9,10,11,12</sup>

A functioning APC protein is thus vital in maintaining low levels of cytosolic  $\beta$ -catenin in the absence of Wnt signaling pathway, thereby preventing excessive cell proliferation.<sup>13</sup> Although the role of APC in the regulation of Wnt signaling is more important in the prevention of tumor initiation, its in-

volvement in apoptosis and chromosomal stability also has an effect on adenoma growth progression.<sup>14</sup>

Although surgery and chemotherapy are useful methods for the treatment of patients with CRC, additional strategies for the treatment of such patients are needed. It has become apparent that the accumulation of gene mutations in a clonal cell results in the transition from a normal colon epithelial cell into carcinoma.<sup>15</sup> By defining the molecular alterations involved in the development of neoplasia, it is possible to expect the achievement of specific molecular targeting for the treatment of already established tumors, as well as for chemoprophylaxis interventions.<sup>16</sup>

## Method

### Ethics

The study was approved by the Research Ethics Committee of Instituto de Assistência Médica ao Servidor Público Estadual de São Paulo (IAMSPE) (protocol N. 043/09) (Annex 10), by the Research Ethics Committee of Faculdade de Medicina do ABC (protocol N. 291/2007) (Annex 11) and by the Research Ethics Committee of Universidade Federal de São Paulo (UNIFESP) (protocol N. 815/09) (Annex 12). Permission to obtain tissue samples was obtained from the Department of Pathological Anatomy of Hospital do Servidor Público Estadual (HSPE), Instituto de Assistência Médica ao Servidor Público Estadual de São Paulo (IAMSPE) (Annex 13) and permission to perform immunohistochemical tests at the Molecular Pathology Laboratory, Department of Pathology, EPM/UNIFESP (Annex 14). Permission to send the paraffin blocks to the Laboratory of Pathology, Faculdade de Medicina do ABC (Annex 15).

### Sample

A total of 64 patients with CRC and 53 patients with colorectal adenoma were analyzed retrospectively. Patients with CRC were submitted to curative or palliative surgery at the Surgical Gastroenterology Service of HSPE and patients with adenoma underwent lesion removal by colonoscopy at the Endoscopy Sector of Faculdade de Medicina do ABC (Santo André, São Paulo, Brazil).

Patients were divided into Group 1, comprising 64 patients submitted to surgery for CRC, whose tissue samples were obtained from the tumor and adjacent non-neoplastic colorectal mucosa anteriorly located 10 cm from the upper margin of the tumor, and Group 2, comprising 53 patients undergoing colonoscopic removal of 71 adenomas.

Inclusion criteria were adult patients with CRC confirmed by histological analysis of the resected tumor with curative intention or palliative removal of the lesion.

Exclusion criteria were patients younger than 18 years of age, patients with familial CRC or CRC associated with inflammatory bowel disease and patients submitted to emergency surgery and deficiency of the histological material used in the immunohistochemistry analysis. A total of 22 patients with CRC were excluded due to insufficient histological material for immunohistochemistry analysis, or due to detachment of the tissue. Thus, group 1 consisted of 42 patients with CRC

that provided material considered adequate for immunohistochemical analysis. In patients from group 2 that underwent resection of more than one adenoma, only the tumor with more marked histological alterations was considered for the analysis, totaling 53 adenomas.

In group 1, 24 (57.1%) patients were males and 18 (42.9%) females. Mean age was  $69.2 \pm 7.4$  years (51-90 years). The location of the CRC was the colon in 27 (64.3%) cases and the rectum in 15 (35.7%). The diameter of the tumors was  $\geq 5$  cm in 21 (50%) patients and  $< 5$  cm in 21 (50%). Of the 42 patients, 7 (16.7%) with distal rectal adenocarcinoma underwent neoadjuvant therapy. In group 2, regarding the adenomas obtained from 53 patients, 27 (50.9%) were males and 26 (49.1%) females. The mean age was  $60.7 \pm 3.4$  years (29-88 years).

Staging was performed by complete clinical and anorectal examination, serum measurement of CEA and CA19-9, colonoscopy with lesion biopsy and respective histopathological analysis, opaque enema when indicated, and total abdominal and chest CT. The clinicopathological staging classification used was the TNM (UICC, 2010).<sup>17</sup>

Resection with curative intent followed the pattern of oncologic surgeries. In palliative resections, the colorectal lesion was removed and oncologic procedures were not performed.

Clinical characteristics were obtained from the sample for all groups of individuals. In the group of patients with colorectal adenoma, the morphological characteristics of the lesion were recorded (location, histological type and degree of cell atypia). In patients with CRC, the following information was obtained: macroscopic characteristics of the lesion (location, size along the major axis), microscopic characteristics (level of invasion, inflammatory infiltrate, surgical margins, lymph node involvement, degree of tumor differentiation, lymphatic/vascular invasion and neural infiltration), TNM classification of UICC (2010),<sup>17</sup> presence of synchronous metastases and immunostaining (staining intensity scores and percentage of stained cells) of anti-APC antibody in colorectal tissue.

### Anatomopathological study

CRC tissues were fixed in formalin and routinely processed using the paraffin-embedding method for histological analysis. All pathological reports were analyzed to characterize macroscopic parameters. Histological sections with 3- $\mu$ m thickness were obtained from each block. All slides were stained with hematoxylin-eosin (HE), revised by the pathologist and the diagnosis was confirmed.

In the stained slides, the best preserved areas that were representative of the tumor to obtain the building block (cylinder) to be used in the preparation of tissue microarray (TMA) were identified. For the construction of TMA, areas with necrosis, hemorrhage, desmoplasia, and areas of low cellularity or even acellular areas were excluded.

### TMA preparation

The TMA block was prepared using a Beecher™ (Beecher Instruments, Silver Spring, MD, USA) equipment, followed by the following steps: identification of the selected area in the respective paraffin block; construction of the *casela* in the recipient block; extraction of 1 mm of tissue of the donor block from

the previously selected area of interest; obtaining cylinder tissue from the donor block and placing it in the previously created *casela* in the recipient block; progression into 1-mm fragments to the new positions in the recipient block, thus creating a set of tissue samples obtained from the array arrangement and quality assessment of the final block for storage.

For adhesion of the TMA block section onto the slides, an adhesive tape system was used (Instrumedics, Hackensack, N.J., USA). Samples were cut at a thickness of 4  $\mu$ m and a small cylinder was used to fix the tape. The histological section was subsequently joined, placed on a slide coated with resin and pressed with a cylinder to obtain better tissue section adhesion. Then the slides with the histological cuts adhered to the tape were placed under UV light for 20 min, followed by immersion in TPC solvent™ solution for another 20 min. After drying, the tapes were removed and the slides stored at -80 °C until completion of immunohistochemistry analysis.

The antibody receptor blocks were obtained from two blocks, in which the first (A-TMA) was added to the adenoma tissue. In the second block (TMA-B), CRC and adjacent mucosa cylinders were included. HE staining was performed in order to evaluate the quality of the sections and possible loss of sample representativeness.

### Immunohistochemical analysis

For the immunohistochemical study, 4- $\mu$ m histological fragments were obtained, placed on glass slides pretreated with 3-aminopropyltriethoxysilane adhesive (Sigma Chemical Co, St. Louis, MO, USA). Initially, histological slides were placed in an oven at 60 °C for 24 hours to obtain better tissue adhesion and deparaffinization. Deparaffinization was performed in three xylene baths at room temperature for 15 min and placed after each of the three baths, in absolute ethanol baths in for 1 min each. The slides were washed in running water for 5 min and submitted to heat induced antigen recovery by steam in a 10 mM citrate buffer solution with pH 6.0 for 30 min.

After cooling for 20 min at room temperature, the slides were washed in running water for 5 min and endogenous peroxidase blocking was performed using a hydrogen peroxide solution at 3%, in four baths of 5 min each. The slides were again washed in running water for 5 min and then washed with phosphate buffered saline (PBS), pH 7.2-7.6, also during 5 min.

Rabbit polyclonal anti-APC antibody C-20 (batch C1709) (Santa Cruz Biotechnology, Inc., CA, USA) was used, which detects the wild-type APC protein and is recommended for detection of the respective protein in human tissue. Incubation was carried out at a concentration of 1:100 in a humidified chamber at 4 °C for at least 16-18 hours (overnight).

Subsequently, after three washes in PBS at pH 7.2 to 7.6, the incubation was performed with the streptavidin-biotin peroxidase kit (LSAB, DakoCytomation, CA, USA) in a humidified chamber at room temperature for 30 min. This step was followed by washes with PBS at pH 7.2-7.6 and development with liquid DAB (DakoCytomation, CA, USA) at room temperature for 5 min.

After washing in running water for 3 min, counter-staining was performed with Harris hematoxylin for 1 min. The sections were dehydrated in three baths with absolute ethanol

and three baths of xylene and then mounted using cover slips with Entellan resin (Sigma Chemical Co., St. Louis, MO, USA) for analysis by optical microscopy.

As positive control, slides with histological sections previously demonstrated as being positive for these antibodies were used. A similar slide was used as a negative control, subtracting the primary antibody from the reaction.

Immunoexpression score was prepared using the method by Hao.<sup>18</sup> Slide positivity was considered zero score if there were less than 5% of epithelial cells in the lesion; score 1, with 5% to 25%, score 2, with 26% to 50%, score 3, 51% to 75% and score 4, more than 75% of epithelial cells in the lesion. Intensity was considered zero score when negative; score 1, when weak, score 2 when moderate and score 3, strong intensity.

The final score of the immunoexpression varied between zero and 12 and was obtained by multiplying the scores of intensity and positivity. The immunoexpression was considered reduced when the final score was between zero and 8, and strong if the final score was between 9 and 12.

Fig. 1 shows the adenoma tissue cells stained with anti-APC antibody. Positivity in these slides was greater than 50% and the intensity was moderate to strong.

Fig. 2 shows adenocarcinoma tissue cells stained with anti-APC antibody. Positivity in these slides was greater than 75% and the intensity was strong.

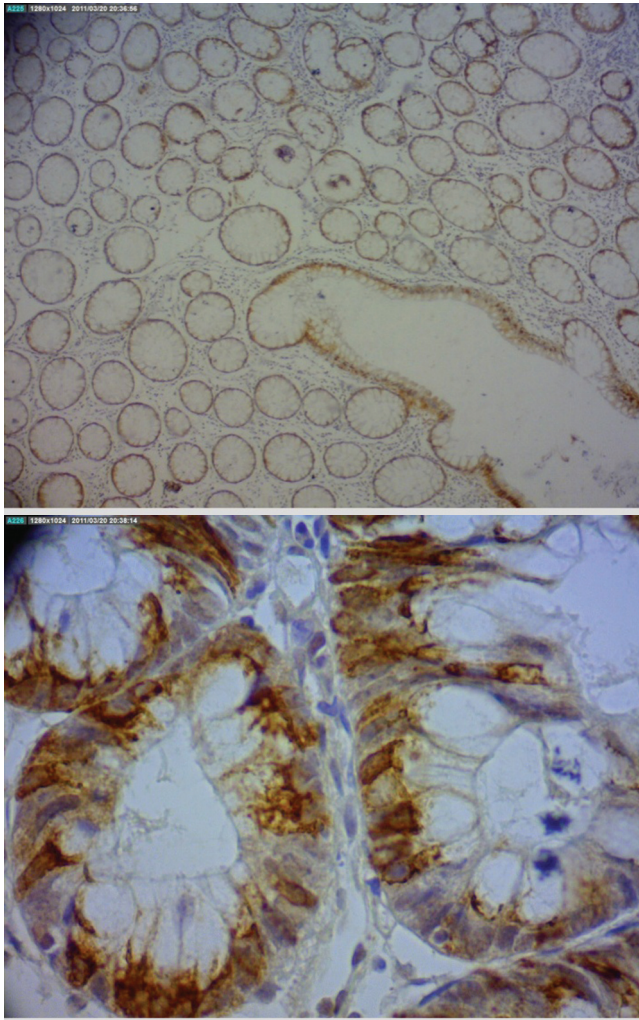
### Statistical analysis

The quantitative results were described as mean and standard deviation. Qualitative data was described as frequencies. The correlation between the scores of the immunohistochemical expression of the APC protein with clinicopathological parameters was assessed by Spearman's correlation coefficient. Student's *t* test, chi-square ( $\chi^2$ ), Mann-Whitney test and McNemar test for paired variables were used to test the significance of differences in clinicopathological parameters. Associations between positivity in protein labeling and clinicopathological features of interest were evaluated by chi-square or Fisher's exact test (very small tables with frequencies) or chi-square ( $\chi^2$ ) of likelihood ratio (tables of variables with more than two categories). The univariate logistic regression analysis (ANOVA) and multivariate analysis were used to identify the dependent and independent variables. Significance level was set at 5% ( $p \leq 0.05$ ). The statistical software SPSS, version 15.0 (The Predictive Analytics Company, Chicago, IL, USA) was used for statistical calculations.

## Results

Regarding the anatomopathological characteristics of CRC, 21 (50%) patients had lymph node metastases, 13 (31%) had venous invasion, 13 (31%) had lymphatic vessel invasion and 6 (14.3%) had neural and/or perineural infiltration. Thirty-four (81%) cases were classified as moderately differentiated, 7 (16.7%) were well differentiated and 1 (2.3%) was poorly differentiated. In relation to the depth of tumor invasion, 29 (69%) tumors were classified as T3, 12 (28.6%) as T2, and 1 (2.4%) as T4. Nine (21.4%) patients had metastases to the liver, peritoneum, or both locations.





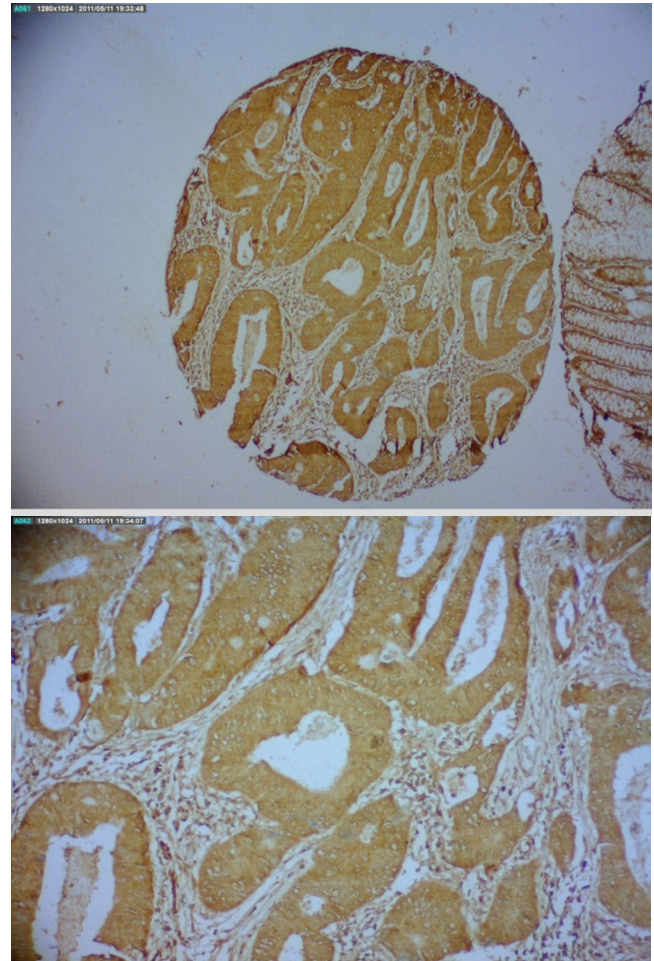
**Fig. 1 – Photomicrograph of positive immunohistochemical expression of anti-APC antibody represented by the brownish color in the cytoplasm of cells from colorectal adenoma (immunohistochemistry; (A) 40x and (B) 400x).**

Of the 42 CRC cases submitted to surgery, 39 (92.9%) underwent curative resection and the median survival of these patients was 18.5 months. Neoplastic recurrence occurred in 10 (23.8%) patients (2 colorectal adenocarcinomas and 8 colon adenocarcinomas) and five of them (11.9%) died due to neoplasia.

Of the 71 adenomas removed from 53 patients, 64 (90.1%) were located in the descending colon, sigmoid colon and rectum and in the ascending colon or transverse colon in 7 (9.9%). As for the histological type, the tumors were classified as tubular in 49 (69%) and tubulovillous lesions in 22 (31%). Mild atypia was found in 39 (55%) adenomas and 32 adenomas (45%) had no atypia. A total of 18 adenomas from patients with more than one adenoma were excluded at the immunohistochemical analysis.

The positivity and intensity of the immunohistochemical expression of APC protein observed in the cytoplasm of 53 colorectal adenomas studied are described in Tables 1 and 2.

The intensity of the immunohistochemical expression of the APC protein observed in the cytoplasm in cases of adjacent non-neoplastic colorectal mucosa is described in



**Fig. 2 – Photomicrograph of positive immunohistochemical expression of anti-APC antibody represented by the brownish color in the cytoplasm of neoplastic cells from colorectal adenocarcinoma (immunohistochemistry; (A) 40x and (B) 400x).**

Table 3. The intensity of the immunohistochemical expression of the APC protein found in the cytoplasm of the 42 CRC cases is described in Table 4.

The positivity of the immunohistochemical expression of the APC protein in CRC and adjacent non-neoplastic mucosa was strong in all patients.

The frequency of the APC protein in the colorectal adenoma tissues, of CRC and adjacent non-neoplastic colorectal mucosa is shown in Table 5. The frequency of strong expression was higher in tumor samples and adjacent non-neoplastic colorectal mucosa than in samples of colorectal adenoma. The comparison of wild-type APC protein immunohistochemical scores between adenoma and adenocarcinoma tissue showed that the immunoreactivity was significantly higher ( $p < 0.0001$ ) in adenocarcinoma tissue. The comparison of the scores of the wild-type APC protein immunohistochemical expression between adenoma tissue and adjacent non-neoplastic colorectal mucosa showed that the immunohistochemical expression was significantly higher ( $p < 0.0001$ ) in the adjacent non-neoplastic colorectal mucosa. The comparison of the scores of the wild-type APC protein immunohistochemical expression in adenocarcinoma tissue and adjacent

non-neoplastic colorectal mucosa showed that immunoe-expression was not significantly different ( $p = 0.24$ ).

In adenomas with strong expression ( $n = 24$ ), the mean age was  $62.3 \pm 2.7$  years, and in those with reduced expression, the mean age was  $58.8 \pm 1.94$  ( $p = 0.29$ ).

**Table 1 – Intensity of immunohistochemical expression of wild-type APC protein in colorectal adenomas.**

Intensity	n (%)
Low	0 (0%)
Moderate	22 (41.5%)
Strong	31 (58.5%)
n, number of cases.	

**Table 2 – Positivity of immunohistochemical expression of wild-type APC protein in 53 colorectal adenomas.**

Positivity	n (%)
< 5%	0 (0%)
5 to 25%	3 (5.7%)
26 to 50%	9 (17%)
51 to 75%	9 (17%)
> 75%	32 (60.3%)
n, number of cases.	

**Table 3 – Intensity of immunohistochemical expression of wild-type APC protein in non-neoplastic adjacent colorectal mucosa in 42 patients with colorectal adenocarcinoma.**

Intensity	n (%)
Low	0 (0%)
Moderate	1 (2.4%)
Strong	41 (97.6%)
n, number of cases.	

**Table 4 – Intensity of immunohistochemical expression of wild-type APC protein in the 42 cases of colorectal adenocarcinoma.**

Intensity	n (%)
Low	0 (0%)
Moderate	2 (4.8%)
Strong	40 (95.2%)
n, number of cases.	

**Table 5 – Frequency of scores of immunohistochemical expression of wild-type APC protein in adenoma tissue in adjacent non-neoplastic colorectal mucosa and colorectal adenocarcinoma.**

Scores	Adenoma	Adjacent Mucosa	Tumor
Strong expression	24 (45.2%)	41 (97.6%)	38 (90.4%)
Decreased expression	29 (54.7%)	1 (2.4%)	4 (9.5%)

Regarding gender, in cases of adenomas with strong expression there were 13 (24.5%) women and 11 (20.7%) men, whereas in cases of adenomas with reduced expression there were 13 (24.5%) women and 16 (31.3%) men ( $p = 0.58$ ).

Regarding the histological type, in adenomas with strong expression, 21 (39.6%) were tubular and 3 (5.6%) were tubulovillous, whereas in adenomas with reduced expression, 16 (30.3%) were tubular and 13 (24.5%) were tubulovillous ( $p = 0.01$ ).

In cases with adjacent non-neoplastic colorectal mucosa, there was one case with the reduced APC protein immunoe-expression, without the possibility of statistical analysis regarding age and sex.

In tumor tissue there were 38 (90.5%) patients with strong APC protein immunoe-expression and 4 (9.5%) patients with reduced immunoe-expression, and statistical analysis regarding age and sex was not possible. In cases with strong APC protein immunoe-expression, there were 22 (52.3%) women and 16 (38.1%) men, whereas in tissues with CRC, reduced immunoe-expression was found in 2 (4.8%) men and 2 (4.8%) women.

## Discussion

Luo et al.<sup>19</sup> studied the formation of aberrant crypt foci as precursor lesions of colorectal carcinogenesis in normal human tissue. These authors observed normal expression of APC and  $\beta$ -catenin proteins, suggesting that loss of heterozygosity of the APC tumor suppressor gene, commonly seen in CRC, may occur earlier and perhaps even before the APC mutation. The findings of this study showed that the strong expression of wild-type APC protein in CRC tissues and adjacent non-neoplastic colorectal mucosa were found in most samples (90.4% and 97.6%, respectively), a result that is in accordance with those by Luo et al.<sup>19</sup>

A study on the influence of the Wnt signaling pathway in adenomas was performed by Wang et al.,<sup>20</sup> who associated the presence of Wnt pathway activation to the process of carcinogenesis of laterally spreading tumors (LST). These authors studied 15 LST lesions and 54 adenomas and compared the expression of GSK3- $\beta$ , phospho-GSK3- $\beta$ , axin and  $\beta$ -catenin proteins of the Wnt pathway in LST lesions and colorectal adenomas.

There was an increase in the expression of phospho-GSK3- $\beta$  and  $\beta$ -catenin in LST lesions, but there was no difference in the expression of axin and GSK3- $\beta$  proteins. These findings suggested that activation of the Wnt /  $\beta$ -catenin pathway seems to be more intense in LST lesions, when compared to colorectal adenoma. Hashimoto et al.<sup>21</sup> studied 42 LST lesions, including seven colorectal adenomas, 25 intramucosal adenocarcinomas and 10 submucosal invasive colorectal adenocarcinomas. They found that the presence of the methylated APC protein was inversely proportional to the presence of submucosal invasion in LST lesions. APC protein hypermethylation is significantly associated with the presence of APC mutations.<sup>21,22</sup> There was no association between APC gene mutations and tendency to malignant LST lesions.<sup>21</sup> In the present study, the wild-type APC protein expression was reduced in colorectal adenoma tissue, which may indicate tendency to malignant adenomas.<sup>20</sup>

Wong et al.<sup>3</sup> studied 758 cases of colorectal adenomas located in the distal large intestine represented by adenomas



greater than 1 cm in diameter, with villous element or high-degree dysplasia, and other 767 cases of patients who underwent flexible rectosigmoidoscopy with more than 90% of the colorectal mucosa located 50 cm above the anal border visible to the device without macroscopic alterations. These authors hypothesized that the relatively frequent (> 2%) presence of single nucleotide polymorphisms of the APC gene would predispose individuals to the formation of adenomatous polyps and CRC and found no association between the presence of polymorphisms and advanced distal adenomas or development of sporadic adenomatous polyps in the colon. The authors did not exclude the possibility of rarer variants of the APC gene contributing to the increased risk of developing CRC.<sup>3</sup>

They concluded that malignant adenomas may not be related to the APC protein mutation alone, i.e., it is possible to develop colorectal carcinogenesis even in the absence of a truncated APC protein, which the results of the present study also suggested.

Yang et al.<sup>23</sup> in an experimental study in rats, found that colorectal carcinogenesis may occur even in the absence of the mutated APC protein. This process may be related to decreased production of mucin from goblet cells due to chronic inflammation process and stress of the colonic mucosa.<sup>23,24</sup>

Cleary et al.<sup>25</sup> compared the presence of missense mutations in the APC gene in 971 patients with CRC and 954 control cases. These authors observed that such a mutation occurred in only 16 cases of CRC. They concluded that APC gene missense mutations have limited participation in the risk of developing CRC.

Foley et al.<sup>15</sup> suggested that the suppression of  $\beta$ -catenin protein by target molecules such as oligodeoxynucleotide inhibits the formation of intestinal adenomas, even in the presence of truncated APC protein. This event could explain, in part, the finding of a few cases of wild-type APC protein weakly expressed in tissues of the adjacent non-neoplastic colorectal mucosa studied in the present series.

One of the most clinically relevant uses for anti-APC antibodies is immunohistochemical analysis of tissues. APC protein was detected in the nucleus and cytoplasm of human colonic tissue, with more prevalent cytoplasmic staining in colon tumors when compared to normal tissues. Most anti-APC antibodies currently available in the market have not shown to be specific for the identification of the APC protein and many commercially available clones of anti-APC recognize an unidentified protein located in the apical region of polarized epithelial cells.<sup>26,27</sup> This lack of specificity in some clones of anti-APC antibodies may have contributed to the results obtained in the present study.

An antibody against the C-terminal portion of the APC protein that detects only full-length or wild-type APC protein and not a truncated form that originates from a mutation in the APC gene was used in the present study. When the APC protein is mutated, it loses its binding site in the  $\beta$ -catenin destruction complex, which usually results in increased expression of  $\beta$ -catenin in the cytoplasm and nucleus, which eventually results in decreased membrane expression.<sup>19</sup>

Thus, the finding of decreased immunoreactivity of the wild-type APC protein in the majority of patients with colorectal adenomas suggests that the APC gene participates in altera-

tions in colorectal adenoma formation. On the other hand, the substantial presence of wild-type APC protein in colorectal tumor tissue and adjacent non-neoplastic colorectal mucosa in the significant majority of patients with CRC may indicate that the mutated APC protein did not participate in a significant way in the process of carcinogenesis in these patients.

## Conclusions

The finding of an increased expression of wild-type APC protein in colorectal adenoma tissue may indicate that the mutated APC gene participates in the process changes of the adenoma-carcinoma sequence in colorectal carcinogenesis.

The strong expression of wild-type APC protein in tissues with CRC and in the adjacent non-neoplastic colorectal mucosa suggests that, in the majority of patients in our series with colorectal carcinoma, the mutation in the APC gene did not participate in the mechanism of colorectal oncogenesis.

## Conflicts of interest

The authors declare no conflicts of interest.

## REFERENCES

1. Liberman E, Kraus S, Sagiv E, Dulcark O, Kazanov D, Arber N. The APC E1317Q and I1307K polymorphisms in non-colorectal cancers. *Biomed Pharmacother.* 2007;61:566-9.
2. Pino MS, Chung DC. The chromosomal instability pathway in colon cancer. *Gastroenterology.* 2010;138:2059-72.
3. Wong HL, Peters U, Hayes RB, Huang WY, Schatzkin A, Bresalier RS, Velie EM, Brody LC. Polymorphisms in the adenomatous polyposis coli (APC) gene and advanced colorectal adenoma risk. *Eur J Cancer.* 2010;46:2457-66.
4. Powell SM, Zilz N, Beazer-Barclay Y, Bryan TM, Hamilton SR, Thibodeau SN, Vogelstein B, Kinzler KW. APC mutations occur early during colorectal tumorigenesis. *Nature.* 1992;359:235-7.
5. Miyoshi Y, Nagase H, Ando H, Horii A, Ichii S, Nakatsuru S, Aoki T, Miki Y, Mori T, Nakamura Y. Somatic mutations of the APC gene in colorectal tumors: mutation cluster region in the APC gene. *Hum Mol Genet.* 1992;1:229-33.
6. Behrens J, Jerchow BA, Wurtele M, Grimm J, Asbrand C, Wirtz R, Kuhl M, Wedlich D, Birchmeier W. Functional interaction of an axin homolog, conductin, with  $\beta$ -catenin, APC, and GSK3 $\beta$ . *Science.* 1998 24(4):596-9.
7. Minde DP, Anvarian Z, Rudiger SGD, Maurice MM. Messing up disorder: how do missense mutations in the tumor suppressor protein APC lead to cancer? *Mol Cancer.* 2011;10:1-12.
8. Newton VA, Ramochi NM, Scull BP, Simmons JG, McNaughton K, Lund PK. Suppressor of cytokine signaling-2 gene disruption promotes APC<sup>Min/+</sup> tumorigenesis and activator protein-1 activation. *Am J.* 2010;176:2320-32.
9. Maandag ECR, Koelink PJ, Breukel C, Salvatori DCF, Changur ACJ, Bosch CA J, Verspaget HW, Deville P, Fodde R, Smits R. A new conditional Apc-mutant mouse model for colorectal cancer. *Carcinogenesis.* 2010;31:946-52.
10. Zilberberg A, Lahav L, Arbesfeld RR. Restoration of APC gene function in colorectal cancer cells by aminoglycoside and macrolide induced read through of premature termination codons. *Gut.* 2010;59:496-507.

11. Zhanke HH, Walker F, Kiflemaria S, Whitehead RH, Williams D, Phillips WA, Mikeska T, Dobrovic A, Burgess AW. Selective inhibition of proliferation in colorectal carcinoma cell lines expressing mutant APC or activated B-Raf. *Int J Cancer*. 2009;125:297-307.
12. Dhir M, Montgomery EA, Glöckner SC, Schuebel KE, Hooker CM, Herman JG, Baylin SB, Gearhart SL, Ahuja N. Epigenetic regulation of WNT signaling pathway genes in inflammatory bowel disease (IBD) associated neoplasia. *J Gastrointest Surg*. 2008;12:1745-53.
13. Dumas YR, He X. Wnt signaling: What the X@# is WTX! *EMBO J*. 2011;30:1415-7.
14. Vincan E, Barker N. The upstream components of the Wnt signalling pathway in the dynamic EMT and MET associated with colorectal cancer progression. *ClinExp Metastasis*. 2008;25:657-63.
15. Samowitz WS. Genetic and epigenetic changes in colon cancer. *Exp Mol Pathol*. 2008;85:64-7.
16. Foley PJ, Scheri RP, Smolock CJ, Pippin J, Green DW, Drebin JA. Targeted suppression of  $\beta$ -catenin blocks intestinal adenoma formation in APC Min mice. *J Gastrointest Surg*. 2008;12:1452-8.
17. TMN Classification of Malignant Tumours. International Union Against Cancer(UICC)/American Joint Committee on Cancer (AJCC). 7th ed. New York, NY: Springer, 2010, pp 143-164.
18. Hao XP, Pretlow TG, Rao JS, Pretlow TP.  $\beta$ -catenin expression is altered in human colon aberrant crypt foci. *Cancer Res*. 2002;61:8085-8.
19. Luo L, Shen GQ, Stiffler KA, Wang QK, Pretlow TG, Pretlow T. Loss of the heterozygosity in human aberrant crypt foci (ACF), a putative precursor of colon cancer. *Carcinogenesis*. 2006;27:1153-9.
20. Wang J, Wang X, Gong W, Mi B, Liu S, Jiang B. Increased expression of  $\beta$ -catenin, phosphorylated glycogen synthase kinase 3 $\beta$ , cyclin d1, and c-myc in laterally spreading colorectal tumors. *J HistochemCytochem*. 2009;57:363-71.
21. Hashimoto K, Shimizu Y, Suehiro Y, Okayama N, Hashimoto S, Okada T, Hiura M, Ueno K, Hazama S, Higaki S, Hamanaka Y, Oka M, Sakaida I, Hinoda Y. Hypermethylation status of APC inversely correlates with the presence of submucosal invasion in laterally spreading colorectal tumors. *Mol Carcinogenesis*. 2008;47:1-8.
22. Lee BB, Lee EJ, Jung H, Chun HK, Chang DK, Song SY, Park J, Kim DH. Aberrant methylation of APC, MGMT, RASSF2A, and Wif-1 genes in plasma as a biomarker for easy detection of colorectal cancer. *Clin Cancer Res*. 2009;15 :6185-91.
23. Yang K, Popova NV, Yang WC, Lozonchi I, Tadesse S, Kent S, Bancroft L, Matise I, Cormier RT, Scherer SJ, Edelmann W, Lipkin M, Augenlicht L, Velcich A. Interaction of Muc 2 and APC on Wnt signaling and in intestinal tumorigenesis: potential role of chronic inflammation. *Cancer Res*. 2008;68:7313-22.
24. Burgess AW, Faux MC, Layton MJ, Ramsay RG. Wnt signaling and colon tumorigenesis- a view from the periphery. *Exp Cell Res*. 2011; 317:2748-58.
25. Cleary SP, Lim H, Croitoru ME, Redston M, Knight JA, Gallinger S, Gryfe R. Missense polymorphisms in the adenomatous polyposis coli gene and colorectal cancer risk. *Dis Colon Rectum*. 2008;51:1467-74.
26. Weeraratna AT, Jiang Y, Hostetter G, Rosenblatt K, Duray P, Bittner M, Trent JM. Wnt5a signaling directly affects cell motility and invasion of metastatic melanoma. *Cancer Cell*. 2002;1:279-88.
27. Wang Y, Azuma Y, Friedman DB, Coffey RJ, Neufeld KL. Novel association of APC with intermediate filaments identified using a new versatile APC antibody. *BMC Cell Biology*. 2009;10:1-13.