



# Journal of Coloproctology

www.jcol.org.br



## Case report

### Primary epiploic appendagitis<sup>☆</sup>

Carlos Augusto Real Martinez<sup>a,\*</sup>, Rogério Tadeu Palma<sup>b</sup>, Paulo Pedroso Silveira Júnior<sup>c</sup>,  
Daniela Tiemi Sato<sup>c</sup>, Murilo Rocha Rodrigues<sup>c</sup>, Hermínio Cabral de Resende Júnior<sup>b</sup>,  
René Crepaldi Filho<sup>d,e</sup>

<sup>a</sup>Graduate Program in Health Sciences of Universidade São Francisco (USF), Bragança Paulista, SP, Brazil

<sup>b</sup>Discipline of Digestive System Surgery of Faculdade de Medicina da Fundação ABC (FUABC), Santo André, SP, Brazil

<sup>c</sup>School of Medicine, USF, Bragança Paulista, SP, Brazil

<sup>d</sup>Discipline of Digestive System Surgery of Faculdade de Medicina da Fundação ABC (FUABC), Santo André, SP, Brazil

<sup>e</sup>Discipline of Digestive System Surgery of Universidade Nove de Julho (UNIVOVE), São Paulo, SP, Brazil

#### ARTICLE INFO

##### Article history:

Received 2 February 2013

Accepted 15 March 2013

##### Keywords:

Appendicitis  
Cecal diseases  
Inflammation  
Colon  
Diagnosis  
Therapeutics

#### ABSTRACT

Primary epiploic appendagitis (PEA) is a seldom reported disease caused by spontaneous torsion of one or more epiploic appendices. The aim of this study is to describe two cases of PEA reviewing the main aspects of the diagnosis and treatment of disease. Case report: Case 1) Male patient, 55 years old, obese, with abdominal right iliac fossa (RIF) pain for two days. Abdominal examination showed pain on palpation in the RIF with rebound tenderness. Abdominal computed tomography identified lobulated lesion in the cecum, measuring 4.5 cm in diameter, which was suggestive of PEA or early neoplasm of the colon wall. The laparoscopic assessment confirmed the diagnosis of PEA and the appendix was removed. The patient had a satisfactory outcome, being discharged on the second postoperative day. Case 2) Female patient, obese, 47 years old, with abdominal pain for six days, with sudden RIF onset. She had pain at palpation with rebound tenderness. Acute diverticulitis was suspected and patient underwent abdominal CT that identified PEA in the sigmoid colon. After expectant management, the patient showed progressive improvement resuming her activities in seven days. PEA is a rarely recalled condition during the investigation of inflammatory acute abdomen which can be easily recognized by modern imaging methods of assessment.

© 2013 Elsevier Editora Ltda. All rights reserved.

#### Apêndagite epiplóica primária

#### R E S U M O

##### Palavras-chave:

Apêndicite  
Doenças do ceco  
Inflamação  
Colo  
Diagnóstico  
Terapêutica

Apêndagite epiplóica primária (AEP) é uma enfermidade raramente descrita, ocasionada pela torção espontânea de um ou mais apêndices epiplóicos. O objetivo deste estudo é descrever dois casos de AEP revisando os principais aspectos do diagnóstico e tratamento da doença. Relato dos Casos: 1º) Homem, 55 anos, obeso com dor abdominal em FID há dois dias. No exame do abdômen apresentava dor à palpação na FID e descompressão brusca presente. A tomografia computadorizada do abdômen identificou lesão expansiva no ceco, lobulada, medindo 4,5 cm de diâmetro, suspeitando-se de AEP ou neoplasia primitiva da

<sup>☆</sup> Study carried out at Programa de Pós-graduação em Ciências da Saúde da Universidade São Francisco (USF) – Bragança Paulista (SP), Brazil.

\* Corresponding author.

E-mail: carmartinez@uol.com.br (C.A.R. Martinez)

2237-9363/\$ - see front matter. © 2013 Elsevier Editora Ltda. All rights reserved.

<http://dx.doi.org/10.1016/j.jcol.2013.03.004>

parede cólica. Durante a videolaparoscopia confirmou-se o diagnóstico de AEP sendo removido o apêndice comprometido. O doente apresentou evolução satisfatória recebendo alta no segundo dia. 2º) Mulher, obesa, 47 anos, com dor abdominal há seis dias, de início súbito na fossa ilíaca esquerda. Apresentava dor à palpação local com descompressão brusca presente. Com suspeita de diverticulite aguda foi submetida à TC do abdômen que identificou AEP do cólon sigmóide. Após conduta expectante apresentou melhora progressiva retomando suas atividades em sete dias. A AEP é uma enfermidade raramente suspeitada durante a investigação do abdômen agudo inflamatório, que pode ser reconhecida com facilidade pelos modernos exames de imagem.

© 2013 Elsevier Editora Ltda. Todos os direitos reservados.

## Introduction

Epiploic appendices (EAs) are small, mobile pedunculated protuberances of fat, of varied sizes, found on the colon wall and comprising two rows (front and rear), parallel to the outer surface of the tenia coli.<sup>1-3</sup> It is estimated that there are approximately 50 to 100 EAs in the adult, extending from the cecum to the sigmoid colon, where they are more frequent and have larger dimensions.<sup>4-5</sup> As the EAs are pedunculated and have terminal arterial blood supply, they are susceptible to ischemic complications when they undergo torsion. Their function is not yet fully understood; it is believed that they may be linked to energy reserves of fat, immunological barrier, blood reserve or cushion pads during colon peristalsis.<sup>6</sup>

Primary epiploic appendagitis (PEA), also known as epiploic appendicitis, acute hemorrhagic epiploitis, fatty pericolitis or pericolonic infarction, is an inflammatory process that affects the EAs.<sup>6</sup> It usually appears after the spontaneous torsion of EA, which causes ischemic infarction of the structure, with consequent evolution to necrosis.<sup>3,7</sup> The disease is self-limiting with spontaneous resolution in most patients, with expectant treatment only. However, similar symptoms to other causes of acute abdominal inflammation (AAI), combined with the difficulties in establishing the correct etiological diagnosis can make many patients undergo surgery.<sup>8</sup>

The improvement in imaging technology – ultrasound (USG), computed tomography (CT) and abdominal magnetic resonance (MR) – increased the possibility of establishing the correct diagnosis of PEA before the surgical indication, allowing conservative treatment to be offered to most patients and limiting the indication for surgery to those with complications or in cases in which the differential diagnosis with other abdominal surgical conditions cannot be ruled out.

The objective of the present study is to present two cases of PEA and to perform a literature review considering the main aspects related to the diagnosis and treatment of the disease.

## Case reports

### Case 1

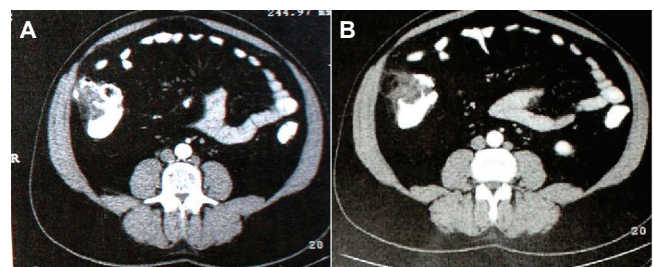
A 55-year-old obese male patient (BMI = 34) came to the ER complaining of abdominal pain of sudden onset lasting for two days, which appeared and remained localized in the RIF.

He complained of loss of appetite, denying nausea, vomiting, fever or being unable to pass gas or stool. He had been on a diet for the previous two months for control of obesity and had lost five kilograms. He had regularly used allopurinol to control hyperuricemia for 10 years, and had been submitted to an umbilical herniorrhaphy three years before and extracorporeal lithotripsy one year before.

On physical examination, the patient was in good general health, hydrated, had normal skin color, with BT = 36.8 °C, blood pressure of 140 × 90. Examination of the abdomen showed slight distention with pain on superficial palpation in the RIF that worsened with rebound tenderness. Abdominal sounds were present, although reduced. Laboratory tests were normal. Plain radiography of the abdomen showed the right psoas shadow was blurred, as well as the presence of sentinel loop in the RIF. With suspected acute appendicitis, the patient was submitted to an abdominal USG that identified a solid expansive lesion with intraluminal component located in the cecum, measuring 4.5 cm in diameter and a small amount of pericecal fluid.

As the vermiform appendix was not identified, a contrast-enhanced CT of the abdomen was performed, which identified an expansive lesion with soft tissue density and lobulated borders affecting part of the cecum and ascending colon, measuring 4.5 cm in its largest diameter, showing intraluminal component associated with significant blurring of the surrounding fat. Examination showed that the appendix was normal and the thickening of the colon wall was circumscribed by laminar collection, raising the possibility of complicated primary neoplasm of the colon wall (Fig. 1 A, B).

Considering the tomographic findings, it was decided to perform a colonoscopy, which even though did not identify

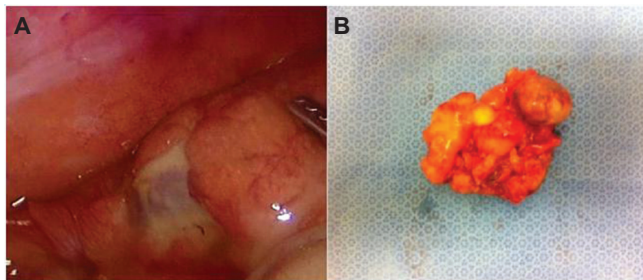


**Fig. 1 – A. Abdominal CT showing expansive lesion located in the anterolateral colon wall, in the cecal region, with locoregional inflammatory process and thickening of the abdominal wall near the lesion. B. Image suggestive of cecal lesion protrusion into the colon lumen (white arrow).**

mucosal lesions in all of the assessed colon, showed edema of the circular folds in the cecum, displaced by extrinsic compression of the anterolateral wall of the cecum. Two small sessile polyps were removed by polypectomy in the descending and sigmoid colon, measuring 2 mm and 3 mm, respectively, of which histopathological assessment confirmed were hyperplastic polyps. Because of the impossibility of ruling out a diagnosis of inflammatory acute abdomen due to complicated cecal neoplasm, it was decided to perform a laparoscopy. During the procedure it was verified that the compression of the colon, as well as the inflammatory process, were caused by PEA. Surgical resection of necrotic EA was performed (Fig. 2A, B). Histopathological analysis of the specimen showed EA measuring 5.0 × 4.9 cm, of which histological analysis showed areas of necrosis, steatohepatitis, fibrinous and leukocytic exudate, in addition to recent hemorrhagic foci. The patient had a satisfactory recovery and was discharged on the second postoperative day. At present he is well, two years after the procedure.

### Case 2

The patient was a 47-year-old woman complaining of sudden-onset localized abdominal pain for six days in the left inferior abdominal quadrant. She had self-medicated with analgesic and antispasmodic drugs to no avail, when she sought the specialized health care service. She denied fever, nausea, vomiting or being unable to pass gas or stool. She complained of lower abdominal discomfort after urination, although she had no dysuria, polyuria or hematuria. Her BMI was 30 and she denied recent weight loss or similar previous episodes. On physical examination she was in good general health, hydrated, had normal skin color, BP = 130 × 70, pulse of 88 bpm, with BT = 36.9 °C. The abdominal region showed slight distension and pain on superficial and deep palpation in the RIF. At the site, it was possible to palpate a resistant mass in the right iliac fossa with ill-defined borders and approximately 8 cm long, painful when compressed, which worsened with rebound tenderness. With clinical suspicion of acute diverticulitis of the sigmoid colon, laboratory tests were requested, as well as an abdominal USG. Laboratory tests showed: Hb: 12.6; Htc: 31%, leukocyte count = 11,800 (without left shift). Urinalysis was normal and the abdominal USG identified a heterogeneous mass located in the anterior wall of the sigmoid colon,



**Fig. 2 – A. Laparoscopic appearance of epiploic appendix over the cecum, with local inflammatory process and signs of steatonecrosis. B. Surgical specimen consisting of epiploic appendix with PEA, removed by laparoscopic approach.**

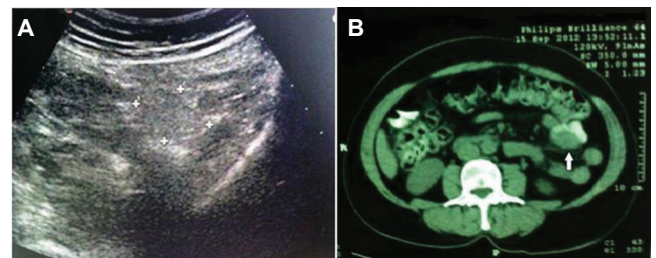
ill-defined, hyperechoic, with attenuation in the center of the lesion and hypoechoic halo in part of its perimeter (Fig. 3). With clinical suspicion of PEA, the patient underwent an abdominal CT, which confirmed the presence of a regular mass, 8 × 6 cm in diameter, in close contact with the anterior wall of the sigmoid colon that showed mild local thickening (Fig. 3B). With the diagnosis of PEA, expectant management was chosen and she was discharged. Rest, warm compresses and nonsteroidal anti-inflammatory drugs and analgesics were advised. Daily monitoring showed that the painful symptoms had decreased and a new CT scan was performed 10 days after the initial picture showed regression of the inflammatory process. After 20 days the patient was asymptomatic, having resumed her daily activities. At present, she has been asymptomatic for 14 months.

### Discussion

EA are protuberances of fat recovered by peritoneum that extend throughout the colon, of which size varies between 0.5 to 5 cm, although they can occasionally have up to 15 cm in diameter.<sup>9</sup> The first woodcuts describing EA can be found in the famous treatise of anatomy, *De Humani Corporis Fabrica*, by Andreas Vesalius in 1453.

The EA are distributed throughout the colon in two parallel lines between the tenia coli, being firmly adhered to the serous intestinal surface. It is estimated adults have between 50 and 150 EAs; however, this figure, as well their dimensions, may vary depending on the ethnic background and characteristics of the individual, represented by obesity and metabolic diseases. Although they are found in the entire colon, they are more often found in the sigmoid (57%), cecum (26%) ascending (9%), transverse (6%) and descending colon (2%).

Similarly to what happened to the patients described here, the most frequent distribution in the sigmoid and cecum explains the higher incidence of PEA in these sites.<sup>10,11</sup> EAs receive their blood supply from one or two terminal arterial branches formed from the vasa recta, being drained by a single vein. As the pedunculated appendices are fixed only at the implantation base, they move freely, making them susceptible to torsions along the axis and which may lead to in-



**Fig. 3 – A. Abdominal USG showing hyperechoic mass with irregular and ill-defined borders and peripheral acoustic enhancement (crosses) on the sigmoid colon wall and small central hypoechoic area (white arrow). B. Abdominal CT with hypotransparent image on the sigmoid colon wall, exerting extrinsic compression on the intestinal lumen (white arrow).**

terruption of blood supply and hence ischemic infarction and necrosis of the structure.<sup>11,12</sup>

Epiplonic appendagitis is a rarely described condition in which the EA becomes inflamed as a primary (primary torsion) and secondary condition caused by torsions associated with surgical adhesions caused by previous surgeries, inflammatory diseases such as sigmoid colon diverticulitis and Crohn's ileitis, appendicitis, pelvic inflammatory disease, venous thrombosis, intense abdominal exercises and in individuals on severe dietary regimens with marked weight loss within a short period of time.<sup>3,10,13</sup> It is believed that the first case of PEA was described in 1904, but the first publication only occurred in 1956.<sup>1</sup> The main tomographic characteristics were described only three decades later.<sup>4,14</sup> PEA is an uncommon cause of AAI, with unknown prevalence. It is estimated to represent 2-8% of all suspected cases of acute diverticulitis of the sigmoid colon and a smaller proportion of those diagnosed as acute appendicitis.<sup>1,4,5</sup>

PEA affects mainly men (70-85% of cases) between the fourth and fifth decades of life.<sup>1,4,6,12,13</sup> Literature reviews have shown that men are affected nearly five times more frequently than women (82% × 18%).<sup>3,13</sup> The disease has a higher incidence around 40 years, a younger age range when compared to patients with acute diverticulitis of the sigmoid colon.<sup>3</sup> The patients followed in this report were 47 and 55 years old, which is exactly the age range with the highest incidence of the disease. Most patients with PEA are obese or have experienced marked weight reduction in a short period of time. The first patient described was obese and had experienced weight loss in a short period of time, while the latter was overweight. Study showed that on average, patients with PEA have a body mass index  $> 25.9 \pm 3.5$  kg/m<sup>2</sup>, significantly higher compared to patients with abdominal pain due to acute diverticulitis.<sup>3</sup> Both patients reported in this study had BMI  $> 28$  kg/m<sup>2</sup>.

The main clinical symptom mentioned in PEA is the presence of acute abdominal, localized pain, of sudden onset (usually lasting less than a week), continuous and intense, commonly felt in the left lower quadrant of the abdomen, of non-migratory character, which affects a patient who is in good overall condition.<sup>15</sup> As in the two cases described, the patient can easily identify the most painful site. A retrospective study showed that the pain has a non-migratory character, affecting the lower quadrants of the abdomen (41.9%) and the upper and lower hypogastrium at lower percentages (9.7% and 6.5%, respectively).<sup>5,15</sup>

Pain is more common in the lower left quadrant of the abdomen (73%-93%) when compared to the right (7%-21%) or in the epigastrium (2% to 5%), probably due to the greater presence of EA in the sigmoid colon.<sup>1,4,5</sup> Symptoms such as change in stool frequency (19.4%), fever (15%), nausea (12.9%), anorexia (9.7%) and vomiting (3.2%) are less common.<sup>3</sup>

On physical examination, there is pain on superficial and deep palpation of the abdomen, which is more intense where there is an affected EA, as in the described patients. Rebound pain is verified in 25% of cases and an inflammatory resistant mass is identified in 10% to 30% of patients.<sup>3,16</sup> Typically, only 15% of patients may experience low-grade fever ( $<37.8$  °C) and infectious alterations in leukocyte counts are uncommon, occurring in only 4-12% of patients.<sup>1,3,4,6,12</sup> Both patients described here had no fever on physical examination and had

leukocyte counts within normal limits. As the first patient was obese, it was not possible to palpate the inflammatory resistant mass in the right iliac fossa, which was easily observed in the second patient.

The differential diagnosis of PEA includes a number of clinical or surgical conditions that can potentially develop as AAI. Among them, acute appendicitis, diverticulitis of the sigmoid colon, acute cholecystitis, hemorrhagic ovarian cyst, ovarian torsion, ectopic pregnancy, cancer, mesenteric lymphadenitis and complicated colorectal cancer are some of the most important ones. Thus, as it was suspected in the described patients, acute appendicitis and acute diverticulitis of the sigmoid colon, depending on the pain location, are the main hypotheses proposed prior to the imaging assessment.

A study evaluating 31 patients observed that it was not possible to establish the diagnosis of PEA only through patient history and physical examination, before the imaging assessment was performed.<sup>3</sup> Authors mention that from the strictly tomographic point of view, PEA mimicked other diseases, including omental infarction, mesenteric panniculitis, colon wall tumors and primary or secondary acute inflammatory processes (appendicitis or diverticulitis).<sup>5</sup> In the first patient described, the tomographic image could not rule out a cecum neoplasm complicated by the suspicion of inflammatory mass projection into the cecal lumen and wall thickening of the cecum, which required a colonoscopy and indication of laparoscopic diagnosis and therapy.

Before the advent of ultrasonography, computed tomography (CT) and magnetic resonance imaging (MRI) of the abdomen, the diagnosis of PEA was difficult to establish preoperatively. In most cases the clinical suspicion was AAI caused by diverticulitis, appendicitis, pelvic inflammatory disease, mesenteric adenitis and acute cholecystitis, which made the definitive diagnosis of PEA to be confirmed only during surgical exploration.<sup>1,4,13</sup> It is possible that the difficulty of having access to imaging methods with good diagnostic sensitivity and specificity can be blamed for the increasing need for surgical indications. Currently, the diagnosis of PEA can be achieved by using the cross-sectional tomography, which provides greater diagnostic accuracy.

However, the abdominal USG, despite its lower sensitivity, is the first imaging examination requested in most centers in Brazil, probably due to the higher availability. MRI of the abdomen, despite the higher sensitivity for the diagnosis of PEA when compared to USG and CT, is used only in larger centers due to its higher costs and lower availability.<sup>19</sup> With the increased diagnostic accuracy afforded by imaging methods, the diagnosis of PEA became possible before the surgical indication, allowing the adoption of a conservative approach, as it occurred with the second patient described.<sup>2,14,17</sup>

In cases of PEA, abdominal USG usually identifies a lobulated oval, hyperechoic, non-compressible mass located between the colon and the anterior or anterolateral wall of the abdomen.<sup>2</sup> The lesion may exert a mass effect on the adjacent colon or the parietal peritoneum, which makes it difficult to confirm whether there is invasion of the intestinal wall. Usually the lesion is in close contact with the colon wall and can be surrounded, in approximately 60% of cases, by a peripheral hypoechoic halo with increased echogenicity of the adjacent fat located under the colon wall, the echographic demonstra-

tion of the presence of local inflammatory process with edema, as identified in the second case described. Concomitant use of Doppler ultrasound can be very helpful in the differential diagnosis of acute diverticulitis by not identifying signs of blood flow in the central region of the lesion, reflecting the absence of perfusion within the necrotic epiploic appendix.<sup>18</sup>

The abdominal USG allowed the correct diagnosis of PEA in the second patient described; however, the same was not true in the first patient. It is noteworthy the fact that the USG performed in the first case was done by a professional that had less experience with the method when compared to the second case. From our viewpoint, this fact confirms the literature, by showing that the major limitation of ultrasonography in the diagnosis of PEA is that few radiologists are familiar with the disease, in addition to the fact that it is an examiner-dependent imaging method.<sup>3</sup>

After the introduction of CT in 1986, studies have shown that abdominal CT has greater accuracy in the diagnosis of PEA, having become the preferred imaging method for diagnosis in most series.<sup>2,9,11,12,14,16,17,20</sup> In normal individuals, EAs are not usually visible at the abdominal CT, except when they are surrounded by free fluid in the abdominal cavity (ascites, blood collections) or when they are inflamed.<sup>3</sup>

As they are made of fat, they have tomographic characteristics similar to other structures of the abdominal cavity also formed by adipose tissue (omentum, mesentery). In PEA cases, the CT usually identifies an oval, lobulated mass, in most cases with less than 5 cm in diameter, adjacent to the colon wall with the formation of a thick hyperdense halo that reflects the inflammatory process in the serous layer surrounding the affected EA region.<sup>21</sup> In the central region of the inflamed EA, it is possible to find an area of liquefaction that represents ischemic necrosis, which usually occurs in the central region of the EA. The combination of these two alterations gives the image the tomographic aspect known as target signal.<sup>11,21</sup>

Although these features are useful in the diagnosis, their absence does not allow the exclusion of PEA diagnosis.<sup>2,5,16,17,21</sup> In some opportunities, as described in the first case herein, the CT cannot accurately define whether the mass originates from the colon wall, making the differential diagnosis of colon tumors difficult, particularly those of nonepithelial origin (GIST, neuroendocrine tumors) that underwent an inflammatory process. In this situation, diagnosis by colonoscopy or laparoscopy may be necessary.

When the disease regresses, the center of the inflamed EA may undergo central fibrosis and calcification, resulting in an image similar to an eggshell. The calcified EA can detach from the colon wall and form an oval and calcified loose structure inside the peritoneal cavity, often found during laparotomy for the treatment of other abdominal conditions.<sup>1,21</sup> One of the most characteristic features of PEA found during follow-up is the progressive improvement of the alterations found in the CT as regression of clinical symptoms occurs, and in most cases, they completely regress after six months of symptom onset.<sup>3,4,16</sup>

When using MRI, the affected EA shows a hyperintense signal on T1-weighted image without contrast, slightly less intense than those from normal peritoneal fat. The inflamed EAs are enhanced on T2-weighted images with fat suppression, confirming the fatty nature of the lesion.<sup>19</sup>

In PEA, the thin peripheral halo detected on CT appears in the MRI as hypointense alterations on T1 and hyperintense on T2, with marked enhancement in T1-weighted images and fat suppression in the periphery, while in the central region, a place of venous drainage, there is reduced signal in both T1- and T2-weighted images.<sup>19,21</sup> As mentioned above, despite the high image resolution, MRI has limited use due to its higher cost and lower availability.<sup>13</sup>

Up to the routine introduction of the new imaging methods in urgency and emergency Medicine, the treatment of PEA was mainly surgical, as most of the patients were diagnosed with AAI due to diseases requiring surgical treatment.<sup>3,22,23</sup> Currently, surgery is indicated only in cases where there are complications, such as abscess formation, intracavitary purulent peritonitis, intussusception, intestinal obstruction or in cases where it is not possible to rule out a neoplasm.<sup>22,24</sup>

A study demonstrated that recurrence can occur in up to 40% of cases, requiring removal of the EA to decrease these rates.<sup>3</sup> The laparoscopic access is currently the most used approach as, in addition to having the same advantages when used in other abdominal procedures, it reduces adhesion formation, being associated with reduced rates of recurrence.<sup>3</sup> Conservative treatment for PEA proposed in 1968, considering it is a self-limiting disease that has spontaneous resolution, is currently indicated in most cases.<sup>25</sup> Recovery occurs in up to four weeks with the administration of NSAIDs, as it was carried out with the second patient described.<sup>3,25</sup> Although there have been few series confirming the effectiveness of nonsurgical treatment, it is estimated that this type of treatment is successful in 97% to 100% of cases and it can be performed on an outpatient basis.<sup>2</sup> Two studies, one that evaluated 50 patients and another that assessed 55 cases, confirmed the favorable evolution of the disease with clinical treatment, with complete response in 100% and 98% of patients, respectively.<sup>16,26</sup>

The first one showed that 64% of patients were treated on an outpatient basis and the 36% that required hospitalization were discharged within 24 hours.<sup>5</sup>

Even though antibiotic therapy is used in up to 36% of patients, antibiotic prescription is indicated only when there is clinical and laboratory suspicion of infection.<sup>13</sup> A study that used the conservative approach showed that all assessed patients showed complete remission of clinical symptoms after one week of regular use of NSAID, showing no recurrence after the four-month follow-up period.<sup>3</sup> When imaging methods cannot explain the nature of the lesion, the indication of diagnostic laparoscopy becomes the most sensible strategy.<sup>1,27</sup> When inflamed EA is identified during the laparoscopy, it is removed, in most series, through simple ligation at the base, taking care not to injure the colon wall, as there are inflammatory adhesions that hinder the correct identification of the cleavage plan.<sup>1,11</sup>

PEA is a little known condition, seldom suspected as cause of acute abdominal pain, which is probably underdiagnosed. Due to the lack of a specific clinical picture, the diagnosis is established by imaging methods in most cases. Even though it has a self-limited clinical course, its diagnosis must be properly established to avoid surgical indication for a condition that can be resolved with clinical treatment. In cases where the diagnosis cannot be established, the performance of laparoscopic assessment should be considered.<sup>1,11</sup>

## Conflicts of interest

The authors declare no conflicts of interest.

## REFERENCES

- Sand M, Gelos M, Bechara FG, Sand D, Wiese TH, Steinstraesser L, et al. Epiploic appendagitis-clinical characteristics of an uncommon surgical diagnosis. *BMC Surgery*.2007;7:11.
- Rioux M, Langis P. Primary epiploic appendagitis: clinical, US, and CT findings in 14cases. *Radiology*.1994;191:523-6.
- 3 Choi YU, Choi PW, Park YH, Kim JI, et al. Clinical characteristics of primary epiploic appendagitis. *J Korean Soc Coloproctol*. 2011;27:114-21.
- DeCastro FJ, Santos JA, Garcia P, Diez JC. Epiploic appendicitis. *Rev Esp Enferm Dig*.2006;98:140-2.
- Singh AK, Gervais DA, Hahn PF, Sagar P, Mueller PR, Novelline RA. Acute epiploic appendagitis and its mimics. *Radiographics*.2005;25:1521-34.
- González ZM, Barrasa AG, Vilaseca RM, Alsina EF, Renau AR. Epiploic appendagitis. *Cir Esp*. 2009;86:379-89.
- Carmichael DH, Organ CH Jr. Epiploic disorders. Conditions of the epiploic appendages. *Arch Surg*.1985;120:1167-72.
- Legome EL, Belton AL, Murray RE, Rao PM, Novelline RA. Epiploic appendagitis: the emergency department presentation. *J Emerg Med*.2002;22:9-13.
- Melo AS, Moreira LB, Pinheiro RA, Noro F, Alves JR, Machado BB. Apendicite epiplóica: aspectos na ultra-sonografia e na tomografia computadorizada. *Radiol Bras*. 2002;35:171-4.
- Thomas JH, Rosato FE, Patterson LT: Epiploic appendagitis. *Surg Gynecol Obstet*.1974;138:23-5.
- Dubb S, Arnold A, Banavalli S, Arnold A. Acute appendagitis presenting with features of appendicitis: value of abdominal CT evaluation. *Case Rep Gastroenterol*. 2008;2:191-5.
- Rao PM, Wittenberg J, Lawrason JN. Primary epiploic appendagitis: evolutionary changes in CT appearance. *Radiology*.1997;204:713-7.
- Freitas GP, Borges AA, Mendonça R, Ribeiro C, Chindamo MC. Apendagite epiplóica: aspectos clínicos e radiológicos. *Arq Gastroenterol*. 2008;45:163-5.
- Danielson K, Chernin MM, Amberg JR, Goff S, Durham JR. Epiploic appendicitis: CT characteristics. *J Comput Assist Tomogr*.1986;10:142-3.
- Pignaton G, Borges AA, Mendonça R, Ribeiro C, Chindamo MC. Apendagite epiplóica: tratamento conservador. *Rev bras Coloproct*. 2008;28:350-2.
- Singh AK, Gervais DA, Hahn PF, Rhea J, Mueller PR. CT appearance of acute appendagitis. *AJR*.2004;183:1303-7.
- Molla E, Ripolles T, Martinez MJ, Morote V, Rosello-Sastre E. Primary epiploic appendagitis: US and CT findings. *Eur Radiol*.1998; 8:435-8.
- Danse EM, Van Beers BE, Baudrez V, et al. Epiploic appendagitis: color Doppler-sonographic findings. *Eur Radiol*. 2001;11:183-6.
- Sirvanci M, Balci NC, Karaman K, Duran C, Karakas E. Primary epiploic appendagitis: MRI findings. *Magn Reson Imaging*.2002; 20:137-9.
- Hiller N, Berelowitz D, Hadas-Halpern I. Primary epiploic appendagitis: clinical and radiological manifestations. *Isr Med Assoc J*. 2000;2:896-8.
- Almeida AT, Melão L, Viamonte B, Cunha R, Pereira JM. Epiploic appendagitis: an entity frequently unknown to clinicians - diagnostic imaging, pitfalls, and look-alikes. *AJR*.2009;193:1243-51.
- Carmichael DH, Organ CH Jr. Epiploic disorders. Conditions of the epiploic appendages. *Arch Surg*. 1985;120:1167-72.
- Ghahremani GG, White EM, Hoff FL, Gore RM, Miller JW, Christ ML. Appendices epiploicae of the colon: radiologic and pathologic features. *Radiographics*. 1992;12:59-77.
- Romaniuk CS, Simpkins KC. Case report: pericolic abscess secondary to torsion of an appendix epiploic. *Clin Radiol*. 1993;47: 216-7.
- Epstein LI, Lempke RE. Primary idiopathic segmental infarction of the greater omentum: case report and collective review of the literature. *Ann Surg*. 1968;167:437-43.
- Legome EL, Belton AL, Murray RE, Rao PM, Novelline RA. Epiploic appendagitis: the emergency department presentation. *J Emerg Med*. 2002;22:9-13.
- Horvath E, Majlis S, Seguel S, Whittle C, Mac Kinnon J, Pablo J, et al. Apendicitis epiplóica primaria: diagnóstico clínico y radiológico. *Rev Méd Chile*. 2000;128:601-7.
- Kiriakopoulos A, Tsakayannis D, Linos D. Laparoscopic management of complicated appendicitis. *JLSLS*. 2006;10:453-6.