



Journal of Coloproctology

www.jcol.org.br



Original article

Neoadjuvant therapy and surgery in rectal adenocarcinoma: analysis of patients with complete tumor remission[◇]

Vitor Augusto de Andrade^a, Raquel Franco Leal^b, João José Fagundes^b,
Cláudio Saddy Rodrigues Coy^b, Maria de Lourdes Setsuko Ayrizono^{b,*}

^aSchool of Medical Sciences, Universidade Estadual de Campinas (UNICAMP), Campinas, SP, Brazil

^bService of Coloproctology, Departament of Surgery, Universidade Estadual de Campinas (UNICAMP), Campinas, SP, Brazil

ARTICLE INFO

Article history:

Received 15 July 2013

Accepted 19 August 2013

Keywords:

Rectal cancer

Neoadjuvant therapy

Surgery

ABSTRACT

Introduction: the standard treatment for locally advanced extra-peritoneal rectal adenocarcinoma, consists of neoadjuvant treatment with radiotherapy and chemotherapy followed by total mesorectal excision.

Objective: evaluate, retrospectively, the patients submitted to neoadjuvant therapy and surgery that presents with total remission of the lesion in the anatomopathological examination.

Methods: between 2000 and 2010, 212 patients underwent surgery at the Coloproctology Unit at DMAD at FCM-UNICAMP. They were grouped as: rectosigmoidectomy and colorectal anastomosis (n = 54), rectosigmoidectomy with coloanal anastomosis (n = 41), 114 abdominoperineal resection of the rectum (n = 114) and other (n = 3).

Results: thirty (14.2%) patients (mean age 57.6 years; 60% males) showed complete remission of the rectal lesion. 4 (13.3%) had compromised lymph nodes and/or lymphatic invasion

At follow-up (mean 51.9 months), 4 (13.3%) presented with local recurrence (one patient) or distant metastases (two patients had liver metastasis, one had liver and lung, and one had bone metastasis). The mean survival was 86.7%.

Conclusion: patients with a complete tumor response showed an increased survival rate, however, the same patients without evidence of residual tumors could develop local recurrence or distant metastases on a later follow-up.

© 2013 Elsevier Editora Ltda. All rights reserved.

[◇]Study carried out at the Service of Coloproctology of the Discipline of Digestive System Diseases (DMAD) of the Department of Surgery of the School of Medical Sciences (FCM) of Universidade Estadual de Campinas (UNICAMP), Campinas, SP, Brazil.

* Corresponding author.

E-mail: luayrizono@terra.com.br (M.L.S. Ayrizono)

2237-9363/\$ - see front matter. © 2013 Elsevier Editora Ltda. All rights reserved.

<http://dx.doi.org/10.1016/j.jcol.2013.08.008>

Terapia neoadjuvante e cirurgia no adenocarcinoma retal: análise dos pacientes com remissão tumoral completa no reto

R E S U M O

Palavras-chave:

Câncer retal
Terapia neoadjuvante
Cirurgia

Introdução: o tratamento padrão do adenocarcinoma de reto extra-peritoneal localmente avançado consiste de neoadjuvância com radio e quimioterapia, seguida de cirurgia com excisão total do mesorreto.

Objetivo: avaliar, retrospectivamente, os pacientes submetidos à neoadjuvância e cirurgia, que apresentaram remissão completa da lesão no reto no exame anatomopatológico.

Métodos: foram avaliados 212 doentes, operados no Serviço de Coloproctologia da DMAD da FCM-Unicamp, entre 2000 e 2010. As cirurgias realizadas foram: retossigmoidectomia e anastomose colorretal (n = 54), retossigmoidectomia com anastomose coloanal (n = 41), amputação abdominoperineal do reto (n = 114) e outras (n = 3).

Resultados: trinta (14,2%) pacientes (média de idade de 57,6 anos; 60% do sexo masculino) apresentaram remissão tumoral completa no reto; destes, 4 (13,3%) tinham acometimento linfonodal e/ou invasão linfática. No seguimento pós-operatório (médio de 51,9 meses), 4 (13,3%) apresentaram recidiva local (um doente) ou metástases à distância (dois doentes com metástases hepáticas, uma hepática e pulmonar, e um outro metástase óssea). A sobrevida média do grupo foi de 86,7%.

Conclusão: os pacientes com resposta tumoral completa no reto apresentaram elevada taxa de sobrevida, mas mesmo doentes sem evidência de tumor residual, podem apresentar recidiva local ou metástases à distância no seguimento tardio.

© 2013 Elsevier Editora Ltda. Todos os direitos reservados.

Introduction

Colorectal cancer is the third most common malignant neoplasia worldwide and the third main cause of cancer mortality in the United States, with rectal carcinoma comprising approximately 30% of these cases.¹ While the occurrence of colon cancer is similar between genders, rectal cancer is 20% to 50% more frequent in men, afflicting especially the age group between 50 and 70 years. The mean survival, in five years, is estimated at 40% to 50%.²

Traditionally, the multimodal therapy is recommended in the treatment of rectal cancer, including radiotherapy associated with neoadjuvant chemotherapy and subsequent surgical approach with total mesorectal excision. The main objective is the improvement in survival and local control of the disease, in addition to maintenance of urinary and sexual function, and preservation of the anal sphincter, thereby avoiding the definitive colostomy.³

The use of neoadjuvant therapy has proven to be effective in reducing tumor size, facilitating surgical resection and allowing sphincter preservation. Some studies also show fewer affected lymph nodes and absence of residual neoplastic disease. In these cases, the neoadjuvant treatment was enough to lead to a complete pathological response, or lack of tumor cells in the surgical specimen.⁴

With the improvement of radiotherapy techniques and the development of new chemotherapeutic agents, there has been progressive improvement in the results of neoadjuvant therapy with complete tumor response rates ranging from 20% to 35%.⁵ The favorable results of preoperative therapy have raised questions about the need for a surgical

approach. Thus, some authors have posited the validity of the non-surgical treatment in cases of complete response to neoadjuvant therapy.^{4,6-10}

Patients and methods

A retrospective analysis of a consecutive series of 212 patients with a diagnosis of extra-peritoneal rectal adenocarcinoma, submitted to neoadjuvant therapy followed by surgical resection with curative intention. Procedures were carried out at the Coloproctology Service of the Discipline of Digestive System Diseases (DMAD) of Universidade Estadual de Campinas (Unicamp) between 2000 and 2010.

The variables analyzed were: age, gender, ethnicity, tumor differentiation, TNM staging and type of surgery performed. Complete tumor regression was considered in the absence of viable neoplastic cells in the surgical specimen from the rectum. The neoadjuvant radiotherapy consisted of a dose of 4.500-5040 cGy and 5-fluorouracil (5-FU) for chemotherapy.

The following data was obtained from the group of patients with complete tumor response: time of symptom evolution until surgery, distance between the tumor and the anal verge, preoperative colonoscopy, staging tests (chest radiography/tomography computed, total abdominal ultrasound/tomographic computed, carcinoembryonic antigen [CEA] levels), time between neoadjuvant therapy and surgery, type of surgery, intraoperative findings, and anatomopathological analysis of the surgical specimen and follow-up, including survival and recurrence.

Results

From 212 patients, 124 (58.5%) were males, 179 (88.4%) were Caucasian and the mean age was 59.9 years, ranging from 29 to 88 years. The surgeries performed were: 54 (25.5%) rectosigmoidectomies with colorectal anastomosis, 41 (19.3%) resectosigmoidectomies with coloanal anastomosis, 114 (53.8%) abdominoperineal resection of the rectum and three (1.4%), other surgeries.

The anatomopathological study showed 30 (14.2%) patients with no residual tumor in the rectum (Fig. 1). Of the remaining 182 (85.8%), 5 (2.4%) were Tis tumors, 9 (4.2%) T1; 62 (29.2%) T2; 81 (38.2%) T3 and 25 (11.8%) were T4. (Eighteen 9.9%) were well-differentiated tumors, 152 (83.5%) moderately differentiated, and 12 (6.6%), poorly differentiated.

In the study group (patients with complete remission, the surgeries performed were: rectosigmoidectomy with colorectal anastomosis in 6 (20%), rectosigmoidectomy with coloanal anastomosis in 9 (30%) and abdominoperineal resection of the rectum in 15 (50%). When performing the intraoperative assessment, there were lesions suggestive of liver metastases in 3 (10%) and invasion of adjacent organs in other 2 patients (6.7%). The data of the 30 patients who had complete tumor response are shown in Table 1.

Two patients underwent surgery for intestinal obstruction with defunctioning sigmoidostomy, before the completion of neoadjuvant therapy. At the colonoscopy, 6 (20.0%) patients had benign synchronous lesions and in 2 (6.7%) it was not possible to evaluate the proximal colon due to tumor stenosis. In the preoperative examinations, no patient had lung metastases and 1 (3.3%) patient had liver metastasis. The level of CEA was higher than 5 µg / L in 10 (33.3%) patients.

The interval between neoadjuvant therapy and surgery was less than four weeks in 8 (26.7%) patients, four to eight weeks in 12 (40%) and more than eight weeks in 7 (23.3%) patients; this information was undetermined for 3 (10%) patients.

The anatomopathological analysis of the surgical specimen showed that 2 (6.7%) patients had lymphatic invasion, and 1 (3.4%) of them also had 5 affected lymph nodes. Other 2 patients also had lymph node involvement, respectively, with

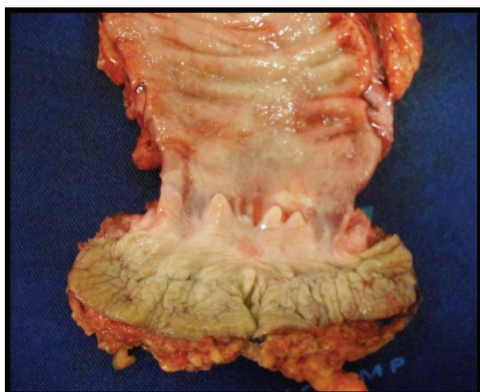

Fig. 1 - Sample of rectal amputation after neoadjuvant therapy with no residual malignancy.

Table 1 – General and specific data.

Data	n = 30
Gender (M / F)	18 / 12 (60% / 40%)
Mean age (years)	57.6 (33 – 79)
Ethnicity (C / NC)	27 / 3 (90% / 10%)
Time of evolution (months)	16.1 (2 – 41)
Location of lesion	
< 5 cm from the AV	16 (53.3%)
> 5 cm from the AV	14 (46.7%)
Metastases (pre-op.)	
liver	1 (3.33%)
lung	0 (0%)
Colonoscopy (pre-op)	
synchronous lesions	6 (20%)
stenosing tumor	2 (6.7%)
CEA (pre-op)	
< 5 µg/L	20 (66.7%)
> 5 µg/L	10 (33.3%)
Interval between neoadjuvant therapy and surgery	
< 4 weeks	8 (26.7%)
4 - 8 weeks	12 (40%)
> 8 weeks	7 (23.3%)
no information	3 (10%)
Intraoperative finding	
Liver metastasis	3 (10%)
Invasion of adjacent organs	2 (6.7%)

AV, anal verge; CEA, carcinoembryonic antigen.

1 and 10 affected lymph nodes. No patient had perineural invasion.

The mean postoperative follow-up was 51.9 months; 4 (13.3%) patients showed distant metastases (two in the liver, one in the lung and liver and one had bone metastasis) and one of these also developed pelvic recurrence and was reoperated 59 months after the first intervention. Of the patients with liver metastases, one had synchronous liver metastasis in the preoperative period of the rectal surgery and the second one had lymph node involvement and lymphatic invasion revealed in the anatomopathological assessment.

Twenty-six (86.6%) patients remain alive. The mean survival of the group with complete remission was 86.7%, with 3 (10%) patients lost at follow-up. The survival curve is shown in Fig. 2.

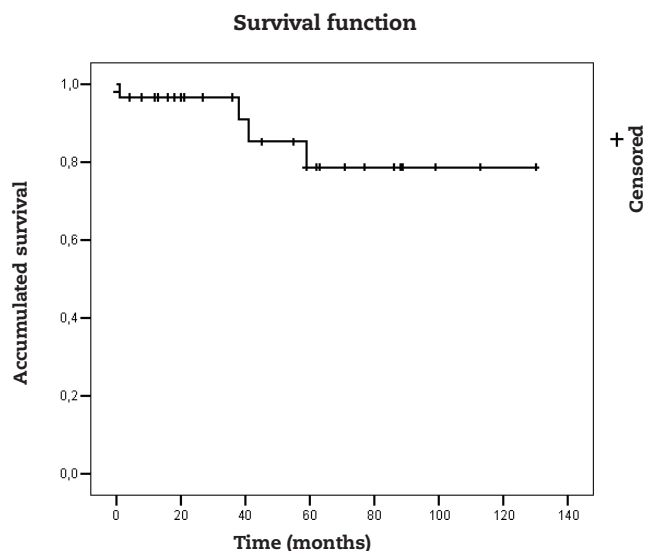


Fig. 2 – Survival curve.

Discussion

The treatment of distal rectal cancer remains a challenge for surgeons worldwide. A multimodal approach has been preferred for the management of these patients. This includes neoadjuvant chemotherapy and radiotherapy combined with surgery with total mesorectal excision and adjuvant chemotherapy in cases of lymph node involvement or distant metastases.

Neoadjuvant treatment can result in downstaging, with reduction in tumor size, degree of rectal wall penetration and even lymph node sterilization. This response, in addition to allowing better surgical outcomes with anal sphincter preservation and reduction in permanent colostomies, is related to better rates in local recurrence and overall survival.^{3,11} In some cases, the complete regression is evident, defined as the absence of neoplastic cells, determined by anatomopathological analysis after rectal resection. This particular scenario is found in 5% to 30% of patients treated with neoadjuvant therapy and surgery.^{3,12,13}

In the present study, we found complete tumor response in 30 patients, representing 14.2% of the sample. Despite being within the range reported in the literature, the value found is a little below the best results, possibly suggesting differences in the neoadjuvant treatment and in the time interval between neoadjuvant therapy and surgery. In this study, the time between neoadjuvant treatment and surgical resection was predominantly 4 to 8 weeks, the same verified by Nyasvajjala et al., who observed tumor remission rates of 10%.¹⁵

Recent literature has demonstrated that longer periods between neoadjuvant therapy and surgery may result in higher rates of complete response.^{3,14-16} Sloothaak et al., assessing 1593 patients, found that the higher rate of complete remission of the tumor was observed when the surgery was delayed until the 15th or 16th week after the beginning of the neoadjuvant therapy, which corresponds to 10-11 weeks after its completion.¹⁸

The results indicating the absence of tumor lesion in the surgical specimen have raised questions about the need for the surgical treatment, considering the current diagnostic methods. However, to date there is no test available capable to confirm with certainty the tumor disappearance from the rectum and/or lymph nodes.

Current diagnostic tests for evaluation include imaging methods such as endorectal ultrasound and magnetic nuclear resonance. As for the detection of lymph node involvement, endorectal ultrasonography has a sensitivity and specificity of 55% and 78%, respectively.¹⁹ Rectal examination by colonoscopy or digital rectal examination (DRE) are not sufficient to guarantee the absence of neoplasia, as well as the magnetic resonance to demonstrate the disappearance of tumor cells both in the primary tumor and lymph nodes. Furthermore, the distinction between residual tumor, intramural fibrosis or actinic ulcers can be difficult.^{3,17}

Perez et al., evaluating the effectiveness of Positron Emission Tomography (PET)/CT, assessed 99 patients with rectal cancer after 12 weeks of neoadjuvant treatment using the imaging method and obtained 5 false negative and 10 false positive results. Aiming to detect residual tumor, the sensitivity was 93% and the specificity was 53%. Clinical evaluation resulted in accuracy of 91% and the information disclosed by the PET-CT improved the accuracy up to 96%.²⁰

Studies have shown that patients with apparent total remission submitted to neoadjuvant therapy and local resection (mostly because of comorbidities or patient refusal) have an overall satisfactory and disease-free survival, with no difference compared to those who underwent radical surgery.^{21,22}

Pelvic recurrence is a major concern in the treatment of rectal cancer and could be associated with the level of tumor penetration in the bowel wall, presence of affected lymph nodes, resection margins and surgical techniques. The target of a large number of studies, local recurrence rate has shown to be extremely variable, from 3% to 30%.³ In the present study, only one (3.4%) patient had local recurrence, but this sample involves only patients who had complete remission of rectal lesions. Habr-Gama et al., following 67 patients with complete remission and non-operated, found recurrence in 15 (21%) patients, with 8 rectal, and 7 distant metastases and no pelvic recurrence.⁸

Campos-Lobatto et al. assessed 58 patients with complete remission, found no local recurrence and this group also had fewer distant metastases. Overall survival was also statistically significantly better than in the group with residual disease.²³

Three meta-analyses, with a significant number of patients, showed that patients with complete tumor remission after neoadjuvant therapy had high survival rates and low recurrence of cancer.²⁴⁻²⁶ Of the 3,105 patients in the study, Maas et al. found that 484 had complete remission, ranging between 8% and 24% in the different studies. They observed 61 recurrences and this group had a 5-year survival rate of 83.3%, compared with 65.6% among those with residual tumor.²⁴ Of the 3,363 patients (1263 with complete remission and 2100 with residual tumor) of the study, Martin et al. observed 0.7% of local recurrence, 8.7% of distant metastases, 90.2% of overall survival and disease-free survival of 87% in patients with complete remission, with the difference being statistically

significant when compared to the group that showed residual tumor after the neoadjuvant therapy²⁵

Zorcolo et al. observed complete tumor response in 300 (15.6%) patients. They found that patients with complete remission after neoadjuvant therapy had better local and distance control, as well as better overall and disease-free survival.²⁶

Smith et al. found that most patients with complete pathological response did not have complete clinical improvement. T1/T2 tumors showed small mucosal abnormalities and had low risk of lymph node involvement, potentially facilitating local resection. The risk of lymph node metastasis was associated significantly with poorer tumor differentiation and presence of lymphovascular invasion.²⁷ Tranchart et al. also found in their sample that patients with T3 tumors had more affected lymph nodes than patients with T1-T2 tumors, 46% and 7% respectively.²⁸ The rate of lymph node involvement in patients with complete tumor response ranged from 0% to 10%,^{29,30} whereas in our study, 13.3% of patients had lymph node metastases and one of them developed pelvic lymph node recurrence.

Habr-Gama and collaborators have carried out studies to find evidence for not performing surgery in these patients. It has been documented that a proportion of these patients might develop metastases during treatment after neoadjuvant therapy or even after complete tumor response, representing the presence of non-detectable tumor cells.^{3,17} Therefore, even patients with complete tumor remission need follow-up with periodic clinical and imaging method assessment, which together will provide confidence to the professional.

In conclusion, the neoadjuvant therapy resulted in a significant number of patients with no residual primary tumor. Although the percentage of patients with complete tumor regression was a little lower than some values reported in the literature, this group had a high survival rate. However, in the late follow-up, even patients with complete remission of rectal cancer with neoadjuvant therapy may show distant disease recurrence or even local recurrence.

Funding

Sources of financial support: PIBIC/CNPq and School of Medical Sciences (FCM) of Universidade Estadual de Campinas (UNICAMP).

Conflicts of interest

The authors declare no conflicts of interest.

REFERENCES

- Castaldo ET, Parikh AA, Pinson W, Feurer ID, Merchant NB. Improvement of survival with response to neoadjuvant radiation therapy for rectal cancer. *Arch Surg* 2009; 144: 129-134.
- Instituto Nacional de Câncer (INCA). <http://www2.inca.gov.br/wps/wcm/connect/tiposdecancer/site/home/colorretal/definicao>.
- Habr-Gama A, Perez RO, Nadalin W, Sabbaga J, Ribeiro U Jr, Silva e Sousa AH Jr et al. Operative versus nonoperative treatment for stage 0 distal rectal cancer following chemoradiation therapy: long-term results. *Ann Surg* 2004; 240(4): 711-7.
- Habr-Gama A. Assessment and management of the complete clinical response of rectal cancer to chemoradiotherapy. *Colorectal Dis* 2006; 8 Suppl 3: 21-4.
- Altenburg FL, Biondo-Simões MLP, Bahten LC. A pesquisa de sangue oculto nas fezes associada a um questionário de sinais e sintomas na prevenção do câncer colorretal. *Rev bras Coloproct* 2009; 29(1): 57-64.
- Bipat S, Glas AS, Slors FJM, Zwinderman AH, Bossuyt PMM, Stoker J. Rectal cancer: local staging and assessment of lymph node involvement with endoluminal US, CT, and MR imaging - a meta-analysis. *Radiology* 2004; 232(3): 773-83.
- Habr-Gama A, Perez RO, Julião GPS, Proscurshim I, Gama-Rodrigues J. Nonoperative approaches to rectal cancer: A critical evaluation. *Semin Radiat Oncol* 2011; 21(3): 234-9.
- Habr-Gama A, Perez RO, Julião GPS, Proscurshim I, Gama-Rodrigues J. Complete clinical response after neoadjuvant chemoradiation for distal rectal cancer. *Surg Oncol Clin N Am* 2010; 19: 829-845.
- Maas M, Beets-Tan RG, Lambregts DM, Lammmering G, Nelemans PJ, Engelen SM et al. Wait-and-see policy for clinical complete responders after chemoradiation for rectal cancer. *J Clin Oncol* 2011; 29(35): 4633-40.
- Smith JD, Ruby JA, Goodman KA, Saltz LB, Guillem JG, Weiser MR et al. Nonoperative management of rectal cancer with complete clinical response after neoadjuvant therapy. *Ann Surg* 2012; 256(6): 965-72.
- Wichmann MW, Muller C, Meyer G, Straus T, Hornung HM, Lau-Werner U et al. Effect of preoperative radiochemotherapy on lymph node retrieval after resection of rectal cancer. *Arch Surg* 2002; 137: 206-210.
- Medich D, McGinty J, Parda D, Karlovits S, Davies C, Caushaj P et al. Preoperative chemoradiotherapy and radical surgery for locally advanced distal rectal adenocarcinoma: pathologic findings and clinical implications. *Dis Colon Rectum*. 2001; 44:1123-1128.
- Dulk M, Velde CJH. Considerations and restrictions for non-operative treatment of rectal cancer in selected patients. *The Lancet Oncol* 2007;8(7): 570-571.
- Hiotis SP, Weber SM, Cohen AM, Minsky BD, Paty PB, Guillem JG et al. Assessing the predictive value of clinical complete response to neoadjuvant therapy for rectal cancer: An analysis of 488 patients. *J Am Coll Surg* 2002; 194: 131-135.
- Moore HG, Gittleman AE, Minsky BD, Wong D, Paty PB, Weiser M et al. Rate of pathologic complete response with increased interval between preoperative combined modality therapy and rectal cancer resection. *Dis Colon Rectum* 2004; 47: 279-286.
- Habr-Gama A, Perez RO, Proscurshim I, Santos RMN, Kiss D, Gama-Rodrigues J et al. Interval between surgery and neoadjuvant chemoradiation therapy for distal rectal cancer: Does delayed surgery have an impact on outcome? *Int J Radiat Oncol Biol Phys* 2008; 71(4): 1181-1188.
- Nyasavajjala SM, Shaw AG, Khan AQ, Brown SR, Lund JN. Neoadjuvant chemo-radiotherapy and rectal cancer: can the UK watch and wait with Brazil? *Colorectal Dis* 2009; 12:33-36.
- Sloothaak DA, Geijsen DE, van Leersum NJ, Punt CJ, Buskens CJ, Bemelman WA et al. Optimal time interval between neoadjuvant chemoradiotherapy and surgery for rectal cancer. *Br J Surg* 2013; 100(7): 933-9.

19. Pinho M. Resposta completa à terapia neoadjuvante no câncer de reto: Apenas sorte ou um resultado previsível? *Rev Bras Coloproct* 2007; 27(4): 474-478.
20. Perez RO, Habr-Gama A, Gama-Rodrigues J, Proscurshim I, Julião GPS, Lynn P et al. Accuracy of positron emission tomography/computed tomography and clinical assesment in the detection of complete rectal tumor regression after neoadjuvant chemoradiation. *Cancer* 2012; 15: 3501-11.
21. Issa N, Murninkas A, Powsner E, Dreznick Z. Long-term outcome of local excision after complete pathological response to neoadjuvant chemoradiation therapy for rectal cancer. *World J Surg* 2012; 36(10): 2481-7.
22. Belluco C, De Paoli A, Canzonieri V, Sigon R, Fornasari M, Buonadonna A et al. Long-term outcome of patients with complete pathologic response after neoadjuvant chemoradiation for cT3 rectal cancer: implications for local excision surgical strategies. *Ann Surg Oncol* 2011; 18(13): 3686-93.
23. Campos-Lobato LF, Stocchi L, Luz Moreira A, Geisler D, Dietz DW, Lavery IC et al. Pathologic complete response after neoadjuvant treatment for rectal cancer decreases distant recurrence and could eradicate local recurrence. *Ann Surg Oncol* 2011; 18(6): 1590-8.
24. Maas M, Nelemans PJ, Valentini V, Das P, Rödel C, Kuo LJ et al. Long-term outcome in patients with a pathological complete response after chemoradiation for rectal cancer: a pooled analysis of individual patient data. *Lancet Oncol* 2010; 11(9): 835-44.
25. Martin ST, Heneghan HM, Winter DC. Systematic review and meta-analysis of outcomes following pathological complete response to neoadjuvant chemoradiotherapy for rectal cancer. *Br J Surg* 2012; 99(7): 918-28.
26. Zorcolo L, Rosman AS, Restivo A, Pisano M, Nigri GR, Fancellu A et al. Complete pathologic response after combined modality treatment for rectal cancer and long-term survival: a meta-analysis. *Ann Surg Oncol* 2012; 19(9): 2822-32.
27. Smith FM, Chang KH, Sheahan K, Hyland J, O'Connell PR, Winter DC. The surgical significance of residual mucosal abnormalities in rectal cancer following neoadjuvant chemoradiotherapy. *Br J Surg* 2012; 99(7): 993-1001.
28. Tranchart H, Lefèvre JH, Svrcek M, Flejou JF, Tiret E, Parc Y. What is the incidence of metastatic lymph node involvement after significant pathologic response of primary tumor following neoadjuvant treatment for locally advanced rectal cancer. *Ann Surg Oncol* 2012 nov 28 [Epub ahead of print]
29. Habr-Gama A, Perez RO, Proscurshim I, Campos FG, Nadalin W, Kiss DR et al. Patterns of failure and survival for nonoperative treatment of stage c0 distal rectal cancer following neoadjuvant chemoradiation therapy. *J Gastrointest Surg* 2006; 10: 1319-1329.
30. Stipa F, Zerneck A, Moore HG, Minsky BD, Wong WD, Weiser M et al. Residual mesorectal lymph node involvement following neoadjuvant combined-modality therapy: Rationale for radical resection? *Ann Surg Oncol* 2004;11: 187-191.