



Case Report

Hyperplastic polyposis: a case report



Thiago Almeida Flauzino^{a,*}, Gabriela N.S. Fardin^a, Adriana F. Sena^a,
Leonardo R.F. Gama^b, Flávia L.M. Ribeiro^a, Giovanni J.Z. Loureiro^a,
Luciano P.N. Gama^a, Rossini C. Gama^a

^a Vitória Apart Hospital, Serra, ES, Brazil

^b Gastroenterologist, Brazil

ARTICLE INFO

Article history:

Received 20 January 2014

Accepted 11 August 2014

Available online 28 January 2015

Keywords:

Hyperplastic polyposis syndrome

Videolaparoscopic colectomy

Polyposis

ABSTRACT

Objective: The authors present a case report of hyperplastic polyposis syndrome from the Coloproctology Service, Vitória Apart Hospital, Vitória-ES.

Case study: Our case is a 24-year-old man who suffered from fatigue, malaise and microcytic and hypochromic anemia, whose upper digestive endoscopy presented several hyperplastic polyps in the stomach and whose colonoscopy revealed colonic polyposis mainly in the right colon; the histopathology showed tubular adenoma with moderate atypia in the ascending colon. Thus, a videolaparoscopic right colectomy was performed; the analysis of the surgical fragment showed multiple (more than 30) polyps distributed through the cecum and ascending colon.

Conclusion: The histopathological diagnosis of hyperplastic polyposis is a challenging task. In general, most polyps are hyperplastic, but serrated and classic adenomas also occur. These associated adenomatous injuries can be the cause of malignant transformation. So far, there is no consensus about the appropriate treatment; however, a colectomy procedure may be beneficial in a scenario of a large number of hyperplastic polyps, concurrent serrated adenomas, or multiple high-risk adenomatous lesions.

© 2015 Sociedade Brasileira de Coloproctologia. Published by Elsevier Editora Ltda. All rights reserved.

Polipose hiperplásica: relato de caso

RESUMO

A Síndrome Polipose Hiperplásica (HPS), descrita em 1980, é considerada como a presença de pólipos hiperplásicos múltiplos, grandes e/ou proximais e, ocasionalmente, um número menor de adenomas serrados, adenomas clássicos e pólipos mistos. A grande maioria dos pacientes são assintomáticos, sendo o diagnóstico um achado incidental da colonoscopia. No tocante ao prognóstico, a maioria dos autores considera HPS um achado incidental sem

Palavras-chave:

Síndrome polipose hiperplásica

Colectomia videolaparoscópica

Polipose

* Corresponding author.

E-mail: tflauzino@gmail.com (T.A. Flauzino).

<http://dx.doi.org/10.1016/j.jcol.2014.08.013>

2237-9363/© 2015 Sociedade Brasileira de Coloproctologia. Published by Elsevier Editora Ltda. All rights reserved.

potencial de malignização, porém, estudos recentes têm descrito lesões genéticas sincrônicas à HPS e ao câncer colorretal.

Objetivo: Os autores apresentam um relato de caso de Síndrome Polipose Hiperplásica do serviço de coloproctologia do Vitória Apart Hospital, Vitória-ES.

Caso Clínico: Trata-se de um paciente de 24 anos, masculino, que apresentava fadiga, adinamia e anemia microcítica e hipocrômica que apresentou na Endoscopia Digestiva Alta: diversos pólipos hiperplásicos no estômago e na Colonoscopia: polipose colônica principalmente em cólon direito cujo histopatológico demonstrou adenoma tubular com atipia moderada no ascendente. Para tal foi realizado colectomia direita videolaparoscópica em que a análise da peça mostrou múltiplos pólipos hiperplásicos distribuídos pelo ceco e cólon ascendente, superior a 30.

Conclusão: O diagnóstico histopatológico de HPS é desafiador. Em geral, a maioria dos pólipos são hiperplásicos, mas também ocorrem adenomas serrados e adenomas clássicos. Tais lesões adenomatosas associadas podem ser a causa de transformações malignas. Ainda não há consenso do tratamento adequado, porém, a colectomia pode ser benéfica quando há grande número de pólipos hiperplásicos, adenomas serrados concomitantes ou múltiplas lesões adenomatosas de alto risco.

© 2015 Sociedade Brasileira de Coloproctologia. Publicado por Elsevier Editora Ltda.

Todos os direitos reservados.

Introduction

Hyperplastic polyposis was described in 1980. This disease is regarded as the presence of multiple large and/or proximal hyperplastic polyps, and sometimes fewer serrated adenomas, classical polyps and mixed adenomas. They differ from isolated hyperplastic polyps, as can reach up to 3 cm.¹ Usually these hyperplastic polyps are found in the proximal colon, occur equally among men and women and exhibit familial character. While it is accepted that small hyperplastic polyps have no malignant potential, there are cases of adenocarcinoma associated with hyperplastic polyposis (HPS).

The guidelines recommend some criteria for a definition of the diagnosis of HPS; these criteria are also used by the World Health Organization (WHO) and were introduced in 2000. The criteria are¹: at least five hyperplastic polyps histopathologically diagnosed proximally to the sigmoid colon, with two of them measuring more than 10 mm in diameter; or² any number of hyperplastic polyps occurring proximally to the sigmoid colon in a patient with a first-degree relative with HPS; or³ more than 30 hyperplastic polyps of any size, but spread throughout the colon.³

Although a hyperplastic polyp is a non-neoplastic polyp, it may present genetic changes, including chromosomal rearrangements, such as: Kras and BRAF proto-oncogenes' mutation and low levels of DNA's unstable microsatellites (MSI-H). TP53 mutations and increased p53 immunosuppression are limited to areas of intraepithelial neoplasia and serrated adenomas. High levels of MSI-H are associated with loss of DNA capacity for error repair, and this is the likely cause of colorectal injuries in HPS patients. The HPS also exhibits histopathologic features that differ from normal mucosa, for instance, an increase in the crypt proliferation zone (although confined to the base of the crypt), serrated architectural organization in basilar areas of the crypt, basilar expansion of the crypt, inverted crypts and prevalence of crypts with reduced

maturation. A small portion of cases presents some degree of dysplasia, and even an association with tubular, tubulovillous, villous and serrated adenomata.⁴

The vast majority of patients are asymptomatic, and the diagnosis is an incidental finding from colonoscopy; a portion of patients may suffer rectal bleeding. Therefore, a high-definition colonoscopy and multiple biopsies are essential for obtaining this diagnosis.

With regard to prognosis, most authors consider HPS as an incidental finding, with no potential for colorectal adenocarcinoma; however, recent studies have described genetic lesions occurring synchronously to HPS and to colorectal cancer, supporting the concept of the sequence: hyperplastic polyp – adenoma – colorectal carcinoma.⁵⁻¹³

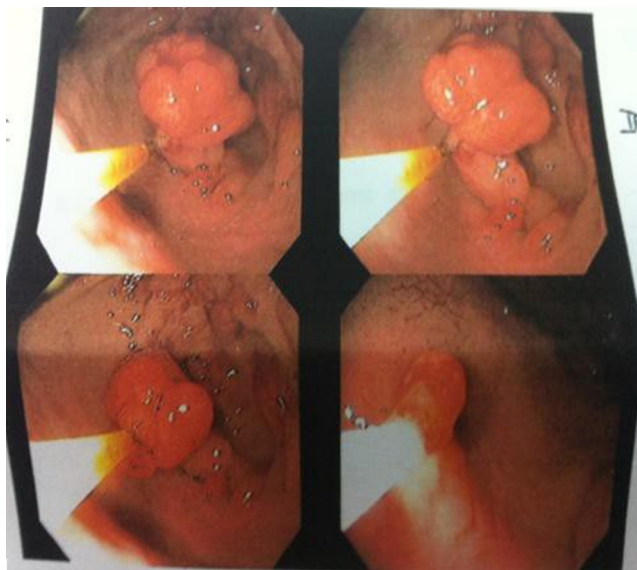
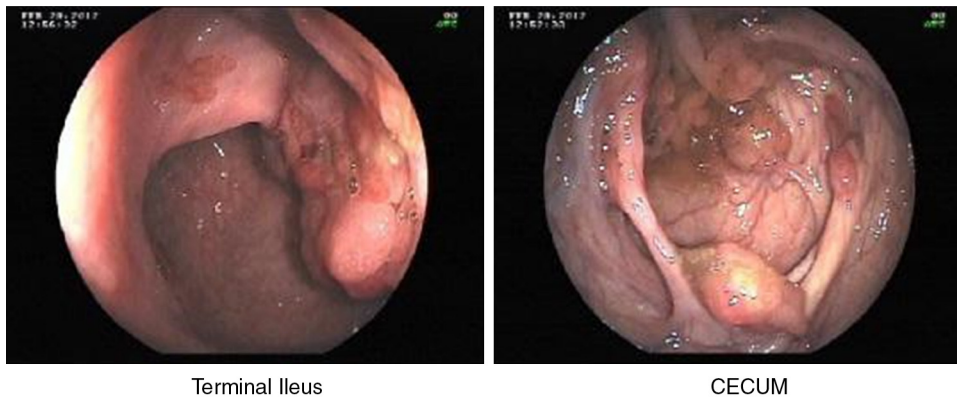
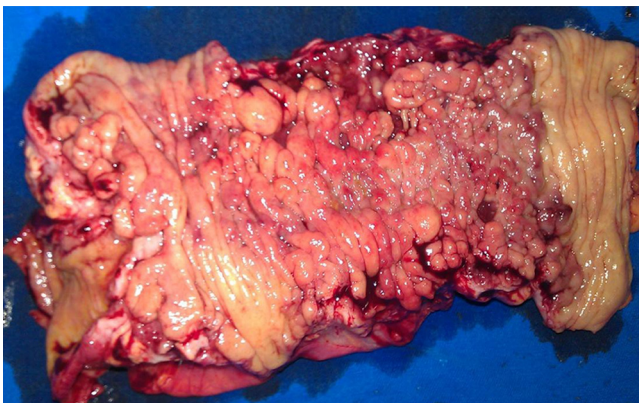

Fig. 1 – UDE: gastric polyposis.



Terminal Ileus

CECUM

Fig. 2 – Colonoscopy: colon polyposis.**Fig. 3 – Surgical fragment from right colectomy, with intestinal polyposis.**

Objective

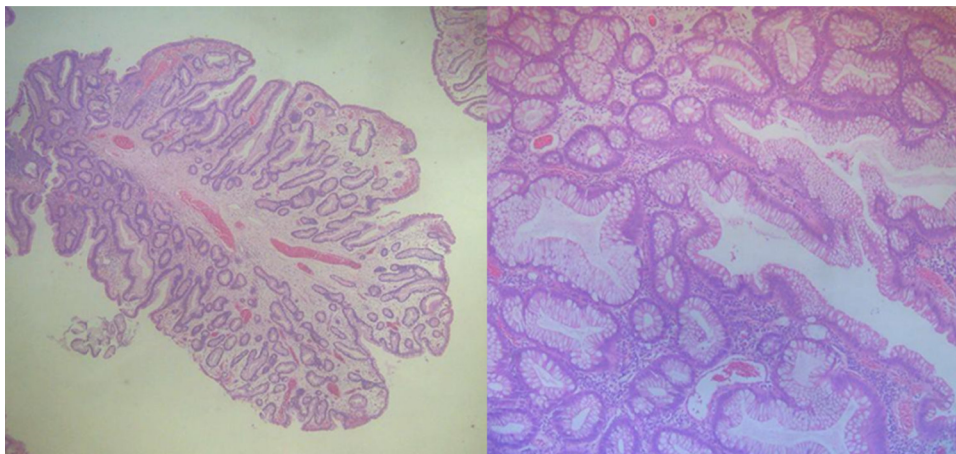
The authors present a case report of HPS syndrome from Coloproctology Service, Vitória Apart Hospital, Vitória-ES.

Case report

Our case is a 24-year-old man who suffered from fatigue, malaise and microcytic and hypochromic anemia. No family history of colorectal cancer or familial polyposis. In the diagnosis, Upper Digestive Endoscopy (UDE) revealed several polyps in the stomach, the largest of them measuring 3 cm, with a histopathologic study compatible with hyperplastic polyps; colonoscopy: colonic polyposis (cecum and ascending and transverse colon), measuring 1–5 cm, with a 1.5-cm polyp in the sigmoid colon and two 1-cm sessile polyps in the rectum. In the face of such findings, polypectomy was performed in the distal colonic segments and, by sampling, in the right colon. Histopathological study (HPTL): retention polyp associated with lymphoid hyperplasia in the rectum and sigmoid colon; tubular adenoma with moderate atypia in the ascending colon (Figs. 1–5).

Results

The patient underwent a partial right colectomy by videolaparoscopy; the surgical fragment measured

**Fig. 4 – Optic microscopy view, hematoxylin and eosin. Fragment of the specimen with polypoid lesion.**

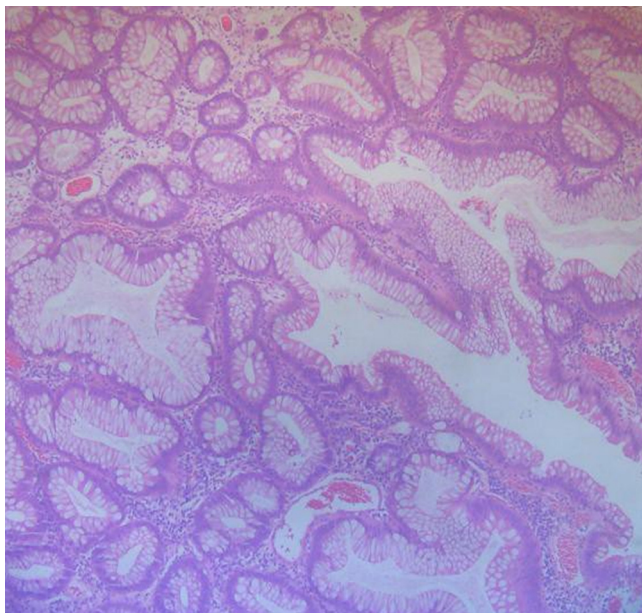


Fig. 5 – Colonoscopy from normal control.

162 mm, containing 50 sessile and pedunculated polypoid lesions.

The histopathological study of the surgical specimen revealed multiple (more than 30) hyperplastic polyps distributed throughout the cecum and ascending colon; this finding fulfills the criteria for HPS syndrome. The research for BRAF gene mutation was inconclusive.

A polypoid lesion with a central fibrovascular bundle and disorganization of crypt architecture was also noted; the crypts showed at their base a proliferative zone, with high number of cells, but without dysplasia, characterizing a hyperplastic polyp.

The patient's recovery was uneventful, and he was discharged on the 4th postoperative day. Currently the patient is under rigorous clinical and endoscopic follow-up.

Conclusion

The histopathological diagnosis of HPS is a challenging task. In general, most of the polyps are hyperplastic, but serrated and classic adenomas can also occur. These associated adenomatous lesions can be the cause of malignant transformation. There is no consensus about the appropriate treatment;

however, colectomy may be beneficial in cases of a large number of hyperplastic polyps, concurrent serrated adenomas, or multiple high-risk adenomatous lesions.

Conflicts of interest

The authors declare no conflicts of interest.

REFERENCES

1. Poswar FO, Carneiro JA, Monteiro VA, Freitas MOS. Hyperplastic polyposis: case report. *Rev Bras Coloproctol*. 2010, July/September;30 [Rio de Janeiro].
2. Rashid A, Houlihan PS, Booker S, Petersen GM, Giardiello FM, Hamilton SR. Phenotypic and molecular characteristics of hyperplastic polyposis. *Gastroenterology*. 2000;119:323-32.
3. Surgical Pathology of the GI TRACT Liver, Biliary Tract and Pancreas.
4. Hamilton SR, Aaltonen LA (eds.). *Pathology and genetics of tumours of the digestive system*.
5. Hyung Su Ahn, Su Jin Hong, Hee Kyung Kim, Hee Yong Yoo, Hwa Jong Kim, Bong Min Ko. Hyperplastic Poliposis Syndrome Identified with a RAF Mutation. *Gut and Liver*. 2012:280-3.
6. Williams GT, Arthur JF, Bussey HJR, Morson BC. Metaplastic polyps and polyposis of the colorectum. *Histopathology*. 1980;4:155-70.
7. Lage P, Sousa R, Albuquerque C, Chaves P, Salazar M, Cravo M, et al. Polipose Hiperplásica: Caracterização Fenotípica e Molecular de uma entidade rara com risco aumentado de cancro do cólon e recto. *J Port Gastro*. 2004;11:76-83.
8. Goldstein NS, Bhanot P, Odish E, Hunter S. Hyperplastic-like Colon Polyps That Preceded Microsatellite-Unstable Adenocarcinomas. *Am J Clin Pathol*. 2003;119:778-96.
9. Burt RW, Jass JR. Hyperplastic polyposis. In: Hamilton SR, Aaltonen LA editor. *World Health Organization classification of tumours. Pathology & genetics. Tumours of the digestive system*. Lyon: IARC Press; 2000.
10. Hawkins NJ, Gorman P, Tomlinson IP, Bullpitt P, Ward RL. Colorectal carcinomas arising in the hyperplastic polyposis syndrome progress through the chromosomal instability pathway. *Am J Pathol*. 2000;157:385-92.
11. Place RJ, Simmang CL. Hyperplastic-adenomatous polyposis syndrome. *J Am Coll Surg*. 1999;188:503-7.
12. Riccio AAL, Godwin AK, Loukola A, Percesepe A, Salovaara R, Masciullo V, et al. The DNA repair gene MBD4 (MED1) is mutated in human carcinomas with microsatellite instability. *Nat Genet*. 1999;23:266-8.
13. Sieber OM, Lipton L, Crabtree M, Heinimann K, Fidalgo P, Phillips RK, et al. Multiple colorectal adenomas, classic adenomatous polyposis, and germ-line mutations in MYH. *N Engl J Med*. 2003;348:791-9.