



## Case Report

# A case of rectal stricture associated with the use of a fecal management system



Kshitij Chatterjee<sup>a,\*</sup>, Jagpal Singh Klair<sup>a</sup>, Abhishek Agarwal<sup>a,b</sup>, Farshad Aduli<sup>a,b</sup>

<sup>a</sup> Department of Internal Medicine, University of Arkansas for Medical Sciences, Little Rock, United States

<sup>b</sup> Division of Gastroenterology and Hepatology, Department of Medicine, University of Arkansas for Medical Sciences, Little Rock, United States

## ARTICLE INFO

## Article history:

Received 5 March 2015

Accepted 8 June 2015

Available online 21 September 2015

## Keywords:

Bowel management system

Rectal stricture

Bowel obstruction

## ABSTRACT

Fecal management systems are widely used to prevent complications of fecal incontinence such as skin breakdown and pressure ulcers. However they are occasionally associated with complications such as bleeding and pressure necrosis of rectal mucosa. We present a patient with *Clostridium difficile* colitis with a prolonged hospital stay requiring the use of Flexi-Seal Fecal Management System who developed abdominal pain and distention with obstipation. Computed tomography of abdomen showed dilatation of small and large bowel loops with a transition point at rectosigmoid junction. Flexible sigmoidoscopy revealed the presence of a severe stricture at the rectosigmoid junction that was not amenable to endoscopic dilation. Surgical resection with an end-colostomy was performed to relieve the obstruction. To the best of our knowledge, this is the first reported case of a high-grade stricture due to use of bowel management system that needed bowel resection surgery.

© 2015 Sociedade Brasileira de Coloproctologia. Published by Elsevier Editora Ltda. All rights reserved.

## Caso de constrição retal associada ao uso de um Sistema de manejo fecal

## RESUMO

Sistemas de manejo fecal são amplamente utilizados com o objetivo de evitar as complicações da incontinência fecal, além de avarias à pele e úlceras de decúbito. No entanto, ocasionalmente esses sistemas estão associados a complicações, como sangramento e necrose por pressão da mucosa retal. Apresentamos um paciente com colite por *Clostridium difficile* com prolongada permanência no hospital e que necessitou do uso do Flexi-Seal Fecal Management System; esse paciente veio a sofrer dores e distensão abdominal, juntamente com obstipação. A tomografia computadorizada do abdome revelou dilatação de alças de intestino delgado e grosso, com um ponto de transição na junção retossigmóidea.

## Palavras-chave:

Sistema de manejo intestinal

Constrição retal

Obstrução intestinal

\* Corresponding author.

E-mail: [kchatterjee@uams.edu](mailto:kchatterjee@uams.edu) (K. Chatterjee).

<http://dx.doi.org/10.1016/j.jcol.2015.06.005>

2237-9363/© 2015 Sociedade Brasileira de Coloproctologia. Published by Elsevier Editora Ltda. All rights reserved.

A sigmoidoscopia flexível revelou presença de grande constrição na junção retossigmóidea, que não permitia dilatação endoscópica. Realizamos ressecção cirúrgica com colostomia terminal, com o objetivo de aliviar a obstrução. Até onde vai nosso conhecimento, este é o primeiro caso relatado de constrição de alto grau causada pelo uso de um sistema de manejo intestinal necessitando de cirurgia de ressecção intestinal.

© 2015 Sociedade Brasileira de Coloproctologia. Publicado por Elsevier Editora Ltda.  
Todos os direitos reservados.

## Introduction

Diarrhea leading to fecal incontinence is a challenging problem in the acute and critical care setting.<sup>1</sup> The presence of fecal incontinence complicates the clinical course of patients by facilitating the development of skin breakdown, pressure ulcers, and also promotes the transmission of nosocomial infections like *Clostridium difficile* colitis.<sup>2,3</sup> Over the recent years, fecal management systems have evolved as an efficient way to divert stool and reduce these complications. However, the devices are associated with an increased risk of rectal trauma. We present a case of rectal stricture associated with the use of flexi-seal fecal management system (FMS) resulting in intestinal obstruction. The purpose of this case report is to familiarize the clinician about the benefits and possible complications of using an intra-rectal FMS in hospitalized patients with fecal incontinence.

## Case presentation

A 47-year-old Caucasian male presented with progressive abdominal pain and distention over 4 weeks and obstipation for 2 days. He also had nausea and vomiting with obstipation for 2 days. He had a 30-lb weight loss over the preceding 2 months. He had no history of abdominal surgeries other than a gastrostomy tube placement 3 months ago. His medical history was significant for hypertension and coronary artery disease. Also, 3 months ago, he had a recent prolonged hospitalization following orthopedic trauma due to a tornado. During this time, he developed *clostridium difficile* diarrhea and was treated with courses of metronidazole followed by vancomycin. The high volume diarrhea necessitated the placement of the Flexi-Seal Fecal Management System that remained in place for a week.

Upon presentation, his vital signs were stable, but he appeared very malnourished. His abdomen appeared distended and tympanic. Plain X-rays showed dilated small bowel loops with multiple air fluid levels and paucity of air in the colon (Fig. 1). A computed tomography (CT) of the abdomen showed narrowing at the rectosigmoid region with dilatation of proximal small and large bowel loops. Patient was started on conservative management with nil per mouth, intravenous fluids, and nasogastric tube decompression.

A flexible sigmoidoscopy showed a severe stricture from a concentric ulcer at 15 cm from the anal verge (Fig. 2). Even the smallest diameter (4.8 mm) endoscope could not be traversed past the stricture. The biopsy revealed inflammatory stricture with ulceration. With failure of conservative management,

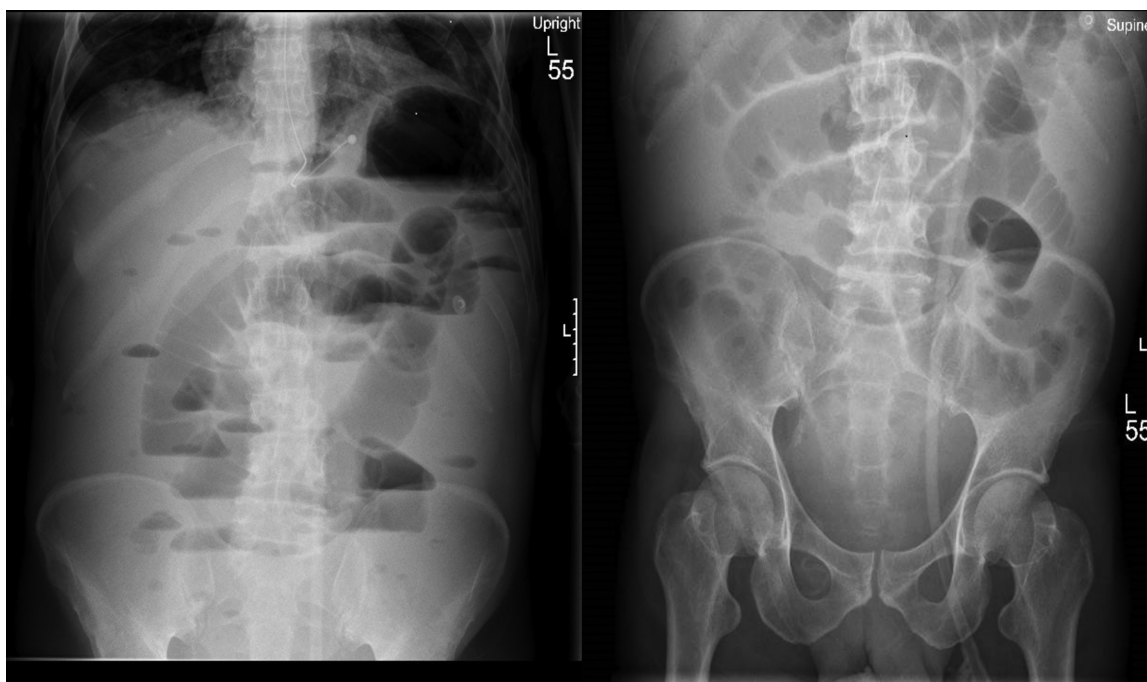
patient underwent a laparoscopic converted to open rectosigmoid resection with end-colostomy. During surgery, the colon was noted to be massively dilated and the upper rectum was noted to be scarred down to a fibrotic band with no obvious lumen. Pathology of the strictured area showed mucosal ulceration with underlying mural and serosal fibrosis consistent with stricture. There was no evidence of viral inclusions or malignancy.

## Discussion

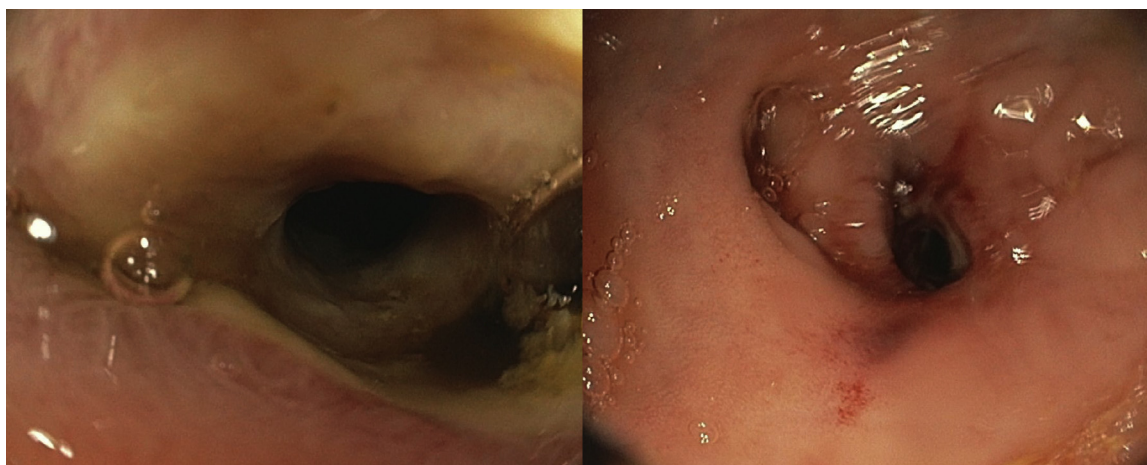
Fecal incontinence secondary to diarrhea is a commonly encountered entity in patients in the inpatient setting with the rates being significantly higher in the patients in the intensive care units.<sup>1,4</sup> Fecal incontinence has been clearly associated with an increased risk for the development of pressure ulcers, wound infection and transmission of hospital acquired infections.<sup>2,3,5</sup> Traditionally absorbent pads and rectal pouches have been used for reducing soiling and contamination but they have significant limitations of their own. Absorbent pads allow perianal soiling and changing pads frequently in a patient with diarrhea is not time efficient for the nursing staff. Rectal pouches often have significant leakage around them and fail to prevent infection transmission.

Flexi-seal fecal management system (FMS) was introduced in 2006 with the aim to effectively manage fecal incontinence. The device consists of a 1 m long silicone cannula with a flexible annular balloon at the rectal end to hold it in place. The balloon is typically inflated with around 45 mL of water and the signal indicator gives an estimate of pressure in the balloon. The flexi-seal FMS was evaluated in a prospective, single arm study of 42 patients and was found to be effective in terms of maintained skin-integrity during the course of the treatment and was also reported to be time-efficient.<sup>6</sup> One patient among these 42 had a rectal ulceration and a lower GI bleed probably associated with the use of the device. Few case reports have been published describing rectal trauma in the form of mucosal tear, laceration, and ulceration with bleeding with the use of flexi-seal FMS.<sup>7,8</sup> These findings were reported as likely related to sudden movement of the device like traumatic removal or related to insertion. Patients receiving therapeutic doses of anticoagulation and antiplatelet drugs are particularly at risk for complications.

To the best of our knowledge, this paper describes the first reported case of a stricture associated with the use of the flexi-seal fecal management system. As the ulcer seen on sigmoidoscopy was concentric in nature leading to stricture without causing previous bleeding, it seems more likely that the inciting factor was pressure necrosis than sudden trauma.



**Fig. 1 – Plain X-ray abdomen showing dilated loops of small intestine, paucity of gas in distended colon loops and multiple air-fluid levels.**



**Fig. 2 – Flexible Sigmoidoscopy showing a severely narrowed stricture near upper rectum.**

Even though the annular balloon is a low-pressure system, there is a concern for pressure necrosis, as it remains inflated throughout the period the device is in situ. The duration of usage of the device was recommended as  $\leq 29$  days in the study evaluating its safety; however, the mean duration was 5.6 (1 to 14) days.<sup>6</sup> Sparks et al. reported a case of ulceration in anal canal resulting in bright red blood per rectum on day 22 of insertion of the fecal management system.<sup>8</sup> They reported the ulceration to be consistent with the plastic tubing of the FMS. Further evaluation is necessitated on the safe maximum time the device can be used. Intermittently deflating the balloon might also be studied to assess the impact on device efficacy and complications. The contraindications for using the device include previous anorectal surgeries or anorectal conditions such as stricture or stenosis, severe rectal hemorrhoids, rectal

tumors, or severe proctitis.<sup>9</sup> Studying the safety of the device in a variety of clinical scenarios, usage concomitant with anti-coagulants, and its use in frail patients more prone to trauma are other areas that need further attention.

#### Conflicts of interest

The authors declare no conflicts of interest.

#### REFERENCES

1. Bliss DZ, Johnson S, Savik K, Clabots CR, Gerding DN. Fecal incontinence in hospitalized patients who are acutely ill. *Nurs Res.* 2000;49:101-8.

2. Gray M, Ratliff C, Donovan A. Protecting perineal skin integrity. Incontinent patients present unique challenges to successful skin care management. *Nurs Manage*. 2002;33:61–3.
3. Donskey CJ. The role of the intestinal tract as a reservoir and source for transmission of nosocomial pathogens. *Clin Infect Dis*. 2004;39:219–26.
4. Nelson RL. Epidemiology of fecal incontinence. *Gastroenterology*. 2004;126:S3–7.
5. Theaker C, Mannan M, Ives N, Soni N. Risk factors for pressure sores in the critically ill. *Anaesthesia*. 2000;55:221–4.
6. Padmanabhan A, Stern M, Wishin J, Mangino M, Richey K, DeSane M, Flexi-Seal Clinical Trial Investigators G. Clinical evaluation of a flexible fecal incontinence management system. *Am J Crit Care*. 2007;16:384–93.
7. Page BP, Boyce SA, Deans C, Camilleri-Brennan J. Significant rectal bleeding as a complication of a fecal collecting device: report of a case. *Dis Colon Rectum*. 2008;51:1427–9.
8. Sparks D, Chase D, Heaton B, Coughlin L, Metha J. Rectal trauma and associated hemorrhage with the use of the convatec flexi-seal fecal management system: report of 3 cases. *Dis Colon Rectum*. 2010;53:346–9.
9. Flexi-seal Fecal Management System [package-insert]. F-SFMSp, Princeton NC, a Division of E. R. Squibb & Sons, LLC; 2006.