



Original Article

Retrospective analysis of the elective tests of rigid proctosigmoidoscopy performed in the service of medical residency in Coloproctology of Hospital Santa Marcelina[☆]



Isaac José Felipe Corrêa Neto^{a,b,*}, Janaína Wercka^a, Angelo Rossi Silva Cecchini^a,
Eduardo Augusto Lopes^{a,b}, Hugo Henriques Watté^{a,b}, Rogério Freitas Lino Souza^a,
Alexander Sá Rolim^{a,b}, Laercio Robles^{a,c}

^a Service of Coloproctology, Department of General Surgery, Hospital Santa Marcelina, São Paulo, SP, Brazil

^b Sociedade Brasileira de Coloproctologia, Brazil

^c Colégio Brasileiro de Cirurgia, Brazil

ARTICLE INFO

Article history:

Received 30 September 2015

Accepted 25 March 2016

Available online 13 April 2016

Keywords:

Proctological examination
Rigid proctosigmoidoscopy
Diagnosis

ABSTRACT

Introduction: Proctologic examination is a deeply intimate procedure which deals with a body area in which prejudices, taboos and constraints prevail, and may also relate to previous trauma; yet this procedure is of paramount importance for the investigation of patients with symptoms that foretell pathologies associated with distal colon, rectum and anus.

Objectives: This study aimed to analyze all cases scheduled of rigid proctosigmoidoscopy performed by the Coloproctology Service, Hospital Santa Marcelina, in 8 of its 10 years of residency in the specialty.

Materials and methods: We analyzed mean age, gender distribution, device's height of reach in relation to the anal verge, the percentage of abnormal tests stratified to perform, or not perform, anoscopy and proctosigmoidoscopy, and major diseases detected.

Results: 844 rigid proctosigmoidoscopy procedures scheduled and performed by the Coloproctology Service, Hospital Santa Marcelina, between September 2006 and August 2014, were analyzed. The distribution was similar between genders and the mean age was 51.2 years. With respect to the device's height of reach from the anal verge, these values were stratified as follows: distance reached >15 cm, 10-15 cm, and <10 cm from the anal verge. Distances >15 cm from the anal verge were attained in 692 (82% of RR) tests, between 10 and 15 cm in 94 (11.1%) tests, and <10 cm in 58 (6.9%) tests.

Conclusion: In this study, it was found that proctology examination and rigid proctosigmoidoscopy are mandatory procedures in cases of symptoms depending on these practices.

© 2016 Sociedade Brasileira de Coloproctologia. Published by Elsevier Editora Ltda. This is an open access article under the CC BY-NC-ND license (<http://creativecommons.org/licenses/by-nc-nd/4.0/>).

[☆] This study was conducted by the Program of Medical Residency in Coloproctology, Department of General Surgery, Hospital Santa Marcelina, São Paulo, SP, Brazil.

* Corresponding author.

E-mail: isaacneto@hotmail.com (I.J.F.C. Neto).

<http://dx.doi.org/10.1016/j.jcol.2016.03.007>

2237-9363/© 2016 Sociedade Brasileira de Coloproctologia. Published by Elsevier Editora Ltda. This is an open access article under the CC BY-NC-ND license (<http://creativecommons.org/licenses/by-nc-nd/4.0/>).

Análise retrospectiva de exames eletivos de retossigmoidoscopia rígida realizadas no serviço de residência médica de Coloproctologia no Hospital Santa Marcelina

R E S U M O

Palavras-chave:

Exame proctológico
Retossigmoidoscopia rígida
Diagnóstico

Introdução: O exame proctológico, apesar de profundamente íntimo e de lidar com área do corpo na qual imperam preconceitos, tabus e constrangimento, podendo inclusive relacionar-se a traumas prévios, é de suma importância para a investigação de pacientes com sintomas que predizem patologias associadas ao cólon distal, reto e ânus.

Objetivos: Analisar todos os casos de retossigmoidoscopias rígidas realizadas de forma agendada pelo serviço de Coloproctologia do Hospital Santa Marcelina em 8 de seus 10 anos de residência médica na especialidade.

Materiais e métodos: Analisou-se a média de idade, distribuição por sexo, altura de alcance do aparelho em relação à borda anal, percentagem de exames anormais com estratificação quando realizado ou não a anuscopia e retossigmoidoscopia e as principais doenças detectadas.

Resultados: Foram avaliadas 844 retossigmoidoscopias rígidas realizadas pelo serviço de Coloproctologia do Hospital Santa Marcelina, de forma agendada, entre setembro de 2006 e agosto de 2014. A distribuição foi semelhante entre os sexos e a média de idade foi de 51,2 anos.

Com relação à altura em relação à borda anal, estratificou-se esses valores em maior que 15 cm, entre 10 e 15 cm da borda anal e alcance inferior a 10 cm da borda anal. Em 692 exames foi possível alcance superior a 15 cm da borda anal (82% das RR), em 94 (11,1%) entre 10 e 15 cm, e em 58 (6,9%) exames, abaixo de 10 cm.

Conclusão: Verificou-se em nosso estudo que o exame proctológico e a retossigmoidoscopia rígida são mandatório em casos de sintomatologia que assim o necessitem.

© 2016 Sociedade Brasileira de Coloproctologia. Publicado por Elsevier Editora Ltda. Este é um artigo Open Access sob a licença de CC BY-NC-ND (<http://creativecommons.org/licenses/by-nc-nd/4.0/>).

Introduction

Proctologic examination is a deeply intimate procedure, which deals with a body area in which prejudices, taboos and constraints prevail, and may also relate to previous trauma and abuse issues; yet this procedure is of paramount importance for the investigation of patients with symptoms that foretell pathologies associated with distal colon, rectum and anus, such as bleeding, change in bowel habits, abdominal or perineal pain, mucorrhea, tenesmus, rectal pull, anal incontinence, anal prolapse or tumor, anemia, and others.

Therefore, it is emphasized that this approach should be done (where appropriate, depending on patient's complaints) by all medical assistants, not only by general surgeons, digestive tract surgeons and, more specifically, by coloproctologists. However, a more detailed assessment of the anal area, rectum and distal colon with the help of anoscopy and rigid proctosigmoidoscopy should be performed, preferably by more jaded professionals. Rigid proctosigmoidoscopy (RR) is that part of a proctologic physical examination that depends on greater expertise and knowledge of the region. This examination consists of direct visualization of the mucosal surface of the rectum and distal sigmoid colon in a variable length, depending on the equipment, the physician's expertise, and the patient's anatomical configuration, notably at the

rectosigmoid transition. In order to achieve an effective RR, some principles should be followed¹:

- speed: the examination should be performed in the shortest possible time and with due effectiveness;
- minimum air-blowing: excess air during the procedure causes discomfort and pain to the patient;
- the doctor should talk to the patient during the examination: the objective is to explain, reassure and, if possible, to distract the patient;
- one does not cause iatrogenic problems, mainly bleeding, mucosal laceration, and the most dreaded of all complications: rectal perforation during the examination.

The main contraindications to this examination are represented by an acute diverticulitis, suspected peritonitis, hemorrhoidal thrombosis, anal fissure, perianal abscess, anal stenosis and an early postoperative period of a colorectal or orificial surgery.

Objective

Our aim is to analyze all cases of RR scheduled and performed by the Coloproctology Service of Hospital Santa Marcelina in 8 of its 10 years of residency in the specialty.

Materials and methods

This is a retrospective analysis of all RR examinations performed electively by the Service of Coloproctology, Hospital Santa Marcelina, in 8 of its 10 years of medical residency in the specialty.

Previously to the examination, all patients underwent retrograde bowel preparation with a glycerin solution 12%. For the examination, patients have adopted the knee-chest position, except when there were contraindications or any age-related limitation.

Mean age, gender distribution, the origin of the patient (i.e., whether from internal or external service), the device's height of reach from the anal verge, percentage of abnormal tests with stratification (with or without anoscopy and proctosigmoidoscopy), and major diseases detected. RR procedures performed during outpatient visits were excluded.

Results

We evaluated 844 RR procedures scheduled and conducted by the Service of Coloproctology, Hospital Santa Marcelina, between September 2006 and August 2014. The mean age was 51.2 years (13-92 years) (Fig. 1) and 414 (49.05%) patients were male; most of the tests came from internal hospital services, i.e., 622 tests (73.7%). Regarding the device's height of reach from the anal verge, the values were stratified in distances >15 cm, 10-15 cm and <10 cm from the anal verge. In 692 examinations, a distance >15 cm from the anal verge (82% of RRs) was reached; in 94 (11.1%), between 10 and 15 cm; and in 58 (6.9%) patients the device's progression only was up to 10 cm from the anal verge (Fig. 2). In all in which the height of reach <10 cm, the cause was an inadequate preparation, pain or a stenotic tumor. Moreover, in 14 of 94 tests (14.9%) with progression from 10 to 15 cm, an excessive angulation was observed. The proctosigmoidoscopy had normal results in 677 patients (80.2%); but with respect to these cases, in only 270 (39.9%) the whole proctological examination was normal; in the other 407 tests (60.1%), some change was found, either at the inspection, during palpation or at anoscopy.

On the other hand, when the proctological analysis was taken as a whole (i.e., inspection, digital rectal examination and palpation, anoscopy and rigid proctosigmoidoscopy), it was found that the test had abnormal results in 574 patients

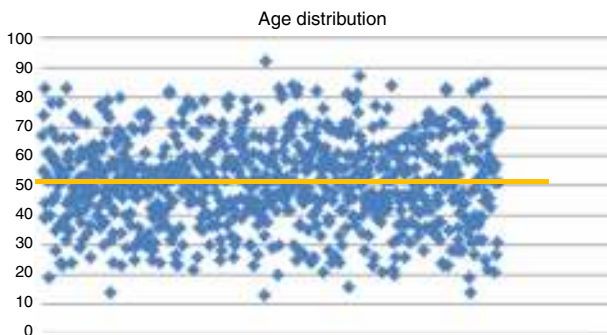


Fig. 1 – Age distribution.

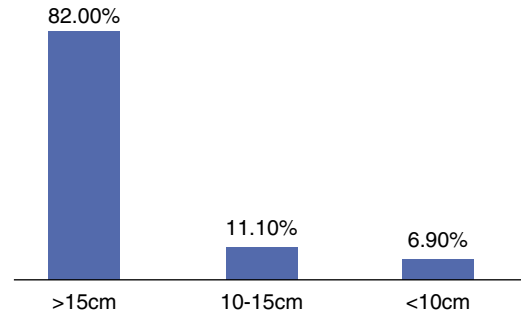


Fig. 2 – Height of rigid rectosigmoidoscopy reach in relation to the anal verge.

(68%), and in only 28.6% of these patients more training and expertise were needed to achieve a diagnosis by anoscopy and RR. Thus, in general, the diagnosis of orificial pathology was only possible with the use of anoscopy and RR in 144 patients (17.06%); and only with the use of RR in 20 patients (2.4%) (Fig. 3).

Cancer was diagnosed in 63 procedures (7.4%); in 44 of these (69.8%), the digital rectal examination was sufficient for obtaining the diagnosis of neoplasia. Thus, it was observed that from 844 RRs performed, in 44 (5.2%) of them the digital rectal examination was sufficient for the diagnosis of a tumor (Fig. 4).

Discussion

According to data from INCA,² between 2012 and 2013 518,510 new cases of cancer were diagnosed in Brazil, and specifically with respect to colorectal malignancy, 30,140 subjects were affected, with an equivalent distribution between genders. This neoplasia is the fourth most common cancer in men and the third in women. Between 55 and 67%^{3,4} of cases, colorectal cancer is found in the distal segment of the intestinal tract, i.e. in the sigmoid colon and rectum, and about 35% of these tumors are specifically located in the rectum.⁵

In this regard, when reaching 25 cm from the anal verge, RR allows the establishment of a diagnosis in about 65% of all colorectal cancers.⁶ However, in only 50% of the procedures, the device will progress up to 20 cm from the anal verge.⁶ Moreover, being a rigid tube, the proctosigmoidoscopy is still quite sensitive and specific in order to measure the height of the tumor from the anal verge or rectum valves.

Despite being an invasive and uncomfortable procedure to the patient, Elias et al.⁷ conducted a study to verify the patient's impression with respect to the proctology examination by the resident physician. In this study, these authors

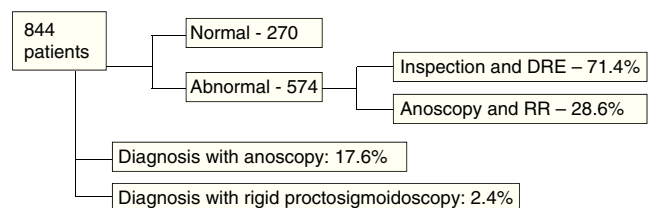


Fig. 3 – Results of examinations of rigid sigmoidoscopy.

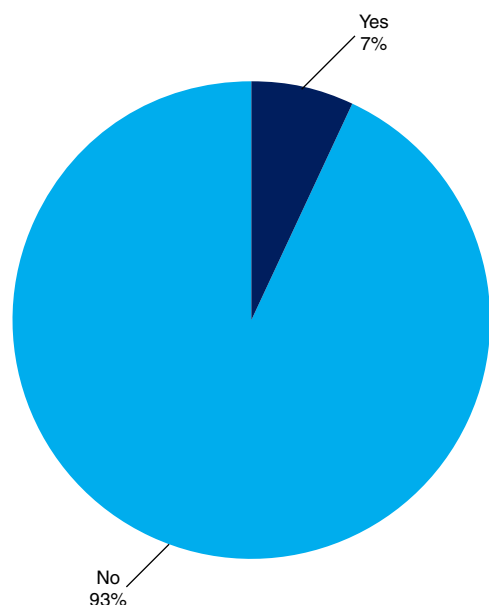


Fig. 4 – Percentage of neoplasm diagnoses in anorectal examinations by inspection, digital rectal examination, anoscopy and rigid proctosigmoidoscopy.

analyzed 100 patients undergoing consultation and a full proctological test through ectoscopy, digital rectal examination, anoscopy and rigid proctosigmoidoscopy. Elias et al. showed that 87% of patients accepted well the presence of residents, 11% remained indifferent, 1% found their presence unpleasant, and 1% did not answer. Regarding the residents' gender, no statistically significant correlation was found between this variable and the refusal or acceptance of their presence by patients.

Similarly, Simpson et al.⁸ conducted an interview with colorectal surgeons from Australia and New Zealand. Of the 35 professionals who answered the questionnaire, 30 (85%) routinely perform RR in their offices.

In this context, Diogenes et al.⁹ intended to evaluate the proctosigmoidoscopy findings in a colorectal cancer screening in asymptomatic patients over 50 years. With that in mind, these authors studied 208 patients in the period of approximately one year, achieving 94.73% of normal results; in the remaining 5.26%, the presence of hyperplastic or adenomatous polyps was diagnosed, and not one case of malignancy in the sample studied was found.

Between 1989 and 1996, Balkan et al.¹⁰ evaluated 119 RR procedures in 100 patients aged 8 months to 14 years with complaints of anal bleeding. These authors used as exclusion criteria the presence of anal fissure, hemorrhoids and anal infection. The procedure had abnormal results in 60 patients and the primary diagnosis was a rectal polyp in 53.3% of cases, followed by proctitis in 26.7%. Of those patients with a rectal polyp, the authors established the diagnosis by digital rectal examination in 66% of cases, with a false-positive rate of 25% and a false-negative rate of 12%.

Studies on the applicability of RR are relatively rare and dated, mainly with reference to the acquisition and progressive development of modern methods for the rectal work-up.

Selby et al.⁶ showed that patients undergoing rigid proctosigmoidoscopy in colorectal cancer screenings in the 10-year period prior to the study had only 30% of fatal cancer risk versus subjects not screened for malignancy in the group of patients already known to be carriers of rectal, rectosigmoid transition, or distal sigmoid cancer.

In addition, and highlighting the usefulness of RR – even when the most advanced propaedeutics are available – Schoellhammer et al.¹¹ set out to determine the degree to which rectal and rectosigmoid tumors showed a change in their treatment, based on the height of measured injury obtained with RR and colonoscopy. With that in mind, these authors subdivided their 53 patients examined by colonoscopy into carriers of injury in the lower rectum (0–7 cm from the anal verge), middle rectum (8–11 cm from the anal verge), high rectum (12–15 cm from the anal verge) and rectosigmoid region (>15 cm from the anal verge); this done, these authors compared their findings with these distances obtained with RR.

Also in this study, when low, medium and high rectal and rectosigmoid tumors were analyzed, its authors observed differences in the measured distance from the anal verge to the injury by colonoscopy versus RR: 0.8 cm, 1.8 cm, 3.1 cm and 5 cm respectively. Thus, an intermediate Kappa index between the differences of height measurements of the lesion in the high rectum and the sigmoid region was obtained, showing that the most proximal the neoplasia was located relative to the anal verge, the greater the discrepancy between the measurements obtained by colonoscopy and RR. Moreover, these authors reported that the addition of RR previously to the therapeutic decision making changed the treatment plan in 25% of patients.¹¹

Although this is a test usually applied during coloproctological consultation, the presence of fecal residue in the rectum may compromise its effectiveness in such a way that, with respect to the need to prepare the area for a rigid proctosigmoidoscopy, it is known that about 50% of the tests have limitations due to the presence of fecal residue.¹²

With that in mind, Bulmer et al.¹³ conducted a randomized study involving 131 patients in order to compare subjects with retrograde distal mechanical preparation versus those who did not make any preparation. It was found that among those patients undergoing bowel preparation, it was possible to inspect more than 75% of the rectal mucosa circumference in 79% of patients. On the other hand, among those subjects who did not undergo preparation, this was only possible in 26.2% ($p < 0.05$). Moreover, among those subjects undergoing bowel preparation, it was possible to introduce the device in 83.3% of patients; as to those subjects without preparation, this was only possible in 46.2% of the examined patients ($p < 0.05$).

Conclusion

In the present study, it was found that the proctological examination is mandatory in cases of symptoms implying this examination. In this analysis, we emphasize that in 71.4% of abnormal anorectal examinations, the inspection and digital rectal examination were enough to establish a diagnosis of

official pathology. Thus, thanks to its simplicity and the ability to be carried out by any practicing doctor, this test should never be overlooked.

Conflicts of interest

The authors declare no conflicts of interest.

REFERENCES

- Sobrado CW, Corrêa Neto IJF. In: Sobrado CW, Nadal SR, Souza AHS Jr, editors. *Manual de doenças anorretais: aspectos práticos. Exame proctológico: quando e como realizar*. Office Editora; 2013. p. 403-15.
- INCA: Available at: <http://www.inca.gov.br/estimativa/2014/> [Accessed on 30 September 2015].
- Vikram R, Iyer RB. PET/CT imaging in the diagnosis, staging, and follow-up of colorectal cancer. *Cancer Imaging*. 2008;S46-51.
- Hayne D, Brown RS, McCormack M, Quinn MJ, Payne HA, Babb P. Current trends in colorectal cancer: site, incidence, mortality and survival in England and Wales. *Clin Oncol*. 2001;13:448-52.
- Rajput A, Dunn KB. Surgical management of rectal cancer. *Semin Oncol*. 2007;34:241-9.
- Selby JV, Friedman GD, Quesenberry CP, Weiss NS. A case-control study of screening sigmoidoscopy and mortality from colorectal cancer. *New Engl J Med*. 1992;326:653-7.
- Elias IP, Lacerda Filho A, Mansur ES, Camara FG, Sena KA. Visão do paciente quanto à participação do residente no exame proctológico em ambulatório. *Rev Bras Coloproct*. 2006;26:389-93.
- Simpson PJB, McMurrick PJ, Polglase AL, Koh CE. Comparison of equipment management and cleaning protocols for rigid sigmoidoscopy. *ANZ J Surg*. 2010;80:728-31.
- Diogenes CVVN, Marianelli R, Soares RPS, Abud RM, Falleiros V, Vilariño TC. Achados de retossigmoidoscopia no rastreamento de câncer colorretal em pacientes assintomáticos acima de 50 anos. *Rev Bras Coloproct*. 2007;27:403-7.
- Balkan E, Kırıştıoğlu I, Gürpınar A, Özel I, Sınmaz K, Doğruyol H. *Arch Dis Child*. 1998;78:267-8.
- Schoellhammer HF, Gregorian AC, Sarkisyan GG, Petrie BA. How important is rigid proctosigmoidoscopy in localizing rectal cancer. *Am J Surg*. 2008;196:904-8.
- Lee M. Comparison of three bowel preparations for sigmoidoscopy. *West Indies Med J*. 1993;42:118-20.
- Bulmer M, Hartley J, Lee PWR, Duthie GS, Monson JRT. Improving the view in the rectal clinic: a randomized control trial. *Ann R Coll Surg Engl*. 2000;82:210-2.