



Original Article

Inflammatory bowel and oxidative stress changes in an experimental model of portal hypertension: action of N-acetylcysteine



Francielli Licks^{a,*}, Renata Minuzzo Hartmann^b, Elizângela Schemitt^b, Josieli Raskopf Colares^d, Lúcio Sarubbi Fillmann^c, Henrique Fillmann^c, Norma Possa Marroni^{a,b,d}

^a Universidade Federal do Rio Grande do Sul (UFRGS), Programa de Pós Graduação em Ciências Biológicas, Porto Alegre, RS, Brazil

^b Universidade Federal do Rio Grande do Sul (UFRGS), Programa de Pós Graduação em Medicina, Porto Alegre, RS, Brazil

^c Pontifícia Universidade Católica do Rio Grande do Sul (PUCRS), Porto Alegre, RS, Brazil

^d Universidade Luterana do Brasil (ULBRA), Programa de Pós Graduação em BioSaúde, Canoas, RS, Brazil

ARTICLE INFO

Article history:

Received 28 April 2016

Accepted 7 May 2016

Available online 6 July 2016

Keywords:

N-acetylcysteine

Portal hypertension

Intestine

Oxidative stress

Inflammation

ABSTRACT

Introduction: Portal hypertension (PH) is characterized by vasodilatation in the portal system and the bowel is one of the severely affected organs. N-acetylcysteine (NAC) is a molecule with important properties and widely used in clinical practice.

Objective: To evaluate NAC action in the bowel of animals submitted to the animal model of partial portal vein ligation (PPVL).

Methods: 18 male Wistar rats were divided into three experimental groups (n=6): sham-operated (SO), PPVL, and PPVL+NAC. On the 8th day after surgery, N-acetylcysteine (10 mg/kg, ip) was administered daily for 7 days. On the 15th day the animals' bowel was collected for oxidative stress analysis, immunohistochemistry and Western blot. We evaluated the expression of NF-KB and TNF- α by immunohistochemistry and of iNOS by Western blot. Lipid peroxidation was assessed by TBARS technique, and the activities of antioxidant enzymes superoxide dismutase (SOD) and glutation peroxidase (GPx) were checked.

Results: We observed an increased expression of NF-KB and TNF- α in PPVL group, and an increased iNOS expression assessed by Western blot. NAC reduced the expression of all proteins evaluated. We also observed an increase in oxidative stress in the bowel of mice PPVL group compared to controls (SO), and NAC was effective in reducing these values in PPVL + NAC group. Also, a reduction in the activity of SOD and GPx enzymes was observed in the diseased group, and NAC was able to restore the activity of the enzymes assessed.

Conclusion: We suggest the anti-inflammatory and antioxidant action of NAC in the bowel of animals submitted to PPVL model.

© 2016 Sociedade Brasileira de Coloproctologia. Published by Elsevier Editora Ltda. This is an open access article under the CC BY-NC-ND license (<http://creativecommons.org/licenses/by-nc-nd/4.0/>).

* Corresponding author.

E-mail: francielli.licks@gmail.com.br (F. Licks).

<http://dx.doi.org/10.1016/j.jcol.2016.05.005>

2237-9363/© 2016 Sociedade Brasileira de Coloproctologia. Published by Elsevier Editora Ltda. This is an open access article under the CC BY-NC-ND license (<http://creativecommons.org/licenses/by-nc-nd/4.0/>).

Alterações intestinais inflamatórias e de estresse oxidativo em modelo experimental de hipertensão portal: ação da N-acetilcisteína

R E S U M O

Palavras-chave:
N-Acetilcisteína
Hipertensão Portal
Intestino
Estresse Oxidativo
Inflamação

Introdução: A Hipertensão Portal (HP) é caracterizada por uma vasodilatação no sistema portal, e o intestino é um dos órgãos gravemente acometidos. A N-acetilcisteína (NAC) é uma molécula com importantes propriedades, amplamente utilizada na clínica.

Objetivo: Avaliar a ação da NAC no intestino de animais submetidos ao modelo animal de ligadura parcial da veia porta (LPVP).

Métodos: Foram utilizados 18 ratos machos Wistar divididos em três grupos experimentais (n=6): Sham-operated (SO), LPVP, LPVP+NAC. No 8º dia após a cirurgia, a N-acetilcisteína (10 mg/kg,ip) foi administrada diariamente durante 7 dias. No 15º dia foi coletado o intestino dos animais para análises de estresse oxidativo, imunohistoquímica e Western blot. Nós avaliamos a expressão do NF-kb e TNF- α por imunohistoquímica e da iNOS por Western blot. A lipoperoxidação foi avaliada pela técnica de TBARS, e as atividades das enzimas antioxidantes Superóxido Dismutase (SOD) e Glutathione Peroxidase (GPx) foram verificadas.

Resultados: Observamos um aumento da expressão do NF-kb e TNF- α no grupo LPVP, e aumento na expressão da iNOS avaliada por Western blot. A NAC reduziu a expressão de todas as proteínas avaliadas. Observamos um aumento do estresse oxidativo no intestino dos ratos do grupo LPVP com relação aos controles (SO), sendo a NAC eficaz na redução desses valores no grupo LPVP+NAC. Ainda, uma redução na atividade das enzimas SOD e GPx no grupo doente, sendo a NAC capaz de restaurar a atividade das enzimas avaliadas.

Conclusão: Sugerimos a ação anti-inflamatória e antioxidante da NAC no intestino de animais submetidos ao modelo LPVP.

© 2016 Sociedade Brasileira de Coloproctologia. Publicado por Elsevier Editora Ltda. Este é um artigo Open Access sob uma licença CC BY-NC-ND (<http://creativecommons.org/licenses/by-nc-nd/4.0/>).

Introduction

Portal hypertension (PH) is a syndrome whose clinical picture is established by the emergence of an anatomical obstacle in the portal system. This obstacle, which blocks the blood flow, causes blood damming at the site of obstruction. The compensatory mechanism of decompression in the portal system is the development of an important vasodilation in the splanchnic territory; in turn, this event is responsible for the main complications of the portal hypertension syndrome.¹

We can correlate the development of a hyperdynamic collateral circulation with one of the major complications from PH: the bleeding from gastrointestinal varices, an event that is triggered when the portal pressure gradient rises above 12 mmHg.² The progressive vasodilation in the splanchnic territory is responsible for the appearance of these varicose veins, the most important being those located in the stomach and bowel. These conditions are known as Portal Hypertension Gastropathy (PHG) and Portal Hypertensive Colopathy (PHC), respectively, and the first of these conditions is already well established in the literature.³

Intestinal changes present in PH are still being elucidated and were gradually identified over the last decade as being mainly one of the causes of fatal gastrointestinal bleeding in patients with PH.⁴ The pattern of lesions in cases of PH can be found in other parts of the gastrointestinal tract, including the intestine,⁵ due to mucosal edema, inflammatory diseases, and ectopic and anorectal varices.⁶

The experimental model of Partial Portal Vein Ligation (PPVL) has been used by many authors to study the molecular changes in pre-hepatic portal hypertension.⁷⁻⁹ In rats, the hemodynamic changes present in PH show up around the day 14 after surgery, and hyperdynamic circulation and splanchnic vasodilation are prevailing conditions in animals subjected to a PPVL model.¹⁰ In addition, PHC and encephalopathy are among the most important manifestations resulting from this experimental model, and inflammatory mechanisms are aggravating factors in both manifestations.¹¹

Inflammation is an event often associated with injuries of different origins. In the case of PH, systemic and splanchnic vascular responses appear to play an important role in the pathogenesis of hyperdynamic circulation and are very similar to those produced in the post-traumatic inflammatory response. The mechanical stress caused by the increased blood flow in the splanchnic territory stimulates the endothelium to secrete vasoactive substances, cytokines and growth factors, and this is a triggering factor for local or generalized inflammation.¹²

With respect to local inflammation, it is important to mention that the mucosa of the gastrointestinal tract is a major reservoir of macrophages and mast cells, and these cells located in the intestine are considered as effector cells that participate in the first line of defense of our body.¹³ In the case of inflammation, the intestinal mucosa acquires a phenotypic pro-inflammatory profile, secreting cytokines that can amplify the systemic inflammatory vascular response.¹²

Among the cytokines secreted by the intestine after the initial stimulation, one must mention the tumor necrosis factor (TNF- α), released by mast cells of the intestine and mesenteric lymph nodes. This proinflammatory cytokine is probably related not only to the inflammatory process present in PH but also to the development of hyperdynamic circulation, since it stimulates the primary route of splanchnic vasodilation, nitric oxide.¹⁴ In addition, TNF- α is an extracellular stimulus for release of another pro-inflammatory cytokine, NF- κ B. This factor induces phosphorylation in I κ B, the cytoplasmic inhibitory protein that prevents the nuclear translocation of NF- κ B.¹⁵

The activation of nitric oxide (NO) is the main event proposed as a triggering factor for the development of collateral circulation in cases of PH. NO is synthesized by nitric oxide synthase (NOS), including, among its major isoforms, endothelial nitric oxide synthase (eNOS), neuronal nitric oxide synthase (nNOS), and inducible nitric oxide synthase (iNOS). This latter isoform is associated with increased levels of NO production.¹⁶ iNOS is mainly expressed in macrophages and smooth muscle cells, especially after the stimulation by lipopolysaccharides, or inflammatory cytokines.¹⁷ This enzyme is modulated by transcription factors, among which NF- κ B is considered the primary mediator of its activation, which, in turn, can be activated by the oxidative stress.¹⁸

Inflammatory cells are important sources for the generation of reactive oxygen species; thus the oxidative and inflammatory damage acts synergistically in the development and worsening of conditions in which these events are present.¹⁹

With HP, the role of oxidative stress is associated with the overproduction of nitric oxide, which determines the production of highly reactive species, for example, peroxy-nitrite (ONOO⁻).²⁰ Using the PPVL model, previous studies published by our study group have already shown this significant involvement in the pathogenesis of pre-hepatic portal hypertension^{9,21,22} as well as the participation of inflammation in gastric injury in this experimental model.²³

This study aimed to evaluate the involvement of oxidative and inflammatory stress in the intestinal mucosa of rats with pre-hepatic portal hypertension. In addition, we aimed to evaluate the antioxidant and anti-inflammatory action of N-acetylcysteine in intestinal injuries present in PPVL model.

Material and methods

Ethics

The experimental procedures with animals were carried out in accordance with the current Brazilian legislation in the practice of scientific research (Law 11,794, Official Gazette – October 8, 2008), Euthanasia Practice Guidelines of CONCEA (2013) and Brazilian Guidelines for the Care and Use of Animals for Scientific and Didactic Purposes – DBCA (2013).

Animals

The animals were acquired in the vivarium of HCPA according to the specifications of the Animal Experimentation Unit (UEA) and were maintained throughout the experiment in plastic

cages measuring 47 cm \times 34 cm \times 18 cm, lined with wood shavings, in a 12-h light/dark cycle and at a temperature of $22 \pm 4^\circ\text{C}$. All animals were fed a commercially available animal food (Purina® – Nutripal, Porto Alegre, RS, Brazil) and had access to water *ad libitum*.

Groups and experimental protocols

For this study, we used 18 male Wistar rats (± 250 g) which were divided randomly into three groups ($n=6$): sham-operated (SO), PPVL, and PPVL + NAC.

On the first day of the experiment, the animals were weighed and anesthetized with ketamine (100 mg/kg) and xylazine (10 mg/kg) intraperitoneally (IP). We performed local asepsis and then made a mid-ventral laparotomy with a careful exposure of bowel loops with a gauze pad soaked in saline. All animals underwent the same surgical procedure; however, the animals in group SO were submitted only to the manipulation of the portal vein. The animals of PPVL and PPVL + NAC groups were submitted to an experimental model of Partial Portal Vein Ligation, described by Sikuler et al. 1985.⁷

We used a 20G needle to promote a partial obstruction of the portal vein; for this purpose, both the vessel and the needle were tied with silk 3-0. The immediate vasodilation of the splanchnic territory was observed and then the needle was gently withdrawn, leaving only the portal vein partially occluded. Next, intestinal loops were replaced into the abdominal cavity of the animals, and an infusion of 10 mL of saline was administered, and the peritoneum was sutured with continuous points. The epithelial layer was closed with individual sutures. The above-described model features a pre-hepatic portal hypertension.⁷

After completion of the surgical procedures, the animals were placed in individual cages for their recovery under analgesia with dipyrone (200 mg/kg); the first administration was performed by intramuscular route and the remaining was orally administered with a frequency of 8/8 h during the subsequent 72 h.

Seven days after surgery, the treatment was initiated in the respective groups. The animals in OS and PPVL groups received only the vehicle (0.9% NaCl, 0.6 mL IP). On the other hand, the animals in PPVL + NAC group received N-acetylcysteine (Sigma Chemical Co., St. Louis, MO, USA; CAS registry number 616-91-1) at a dose of 10 mg/kg dissolved in 0.6 mL of 0.9% NaCl. The treatment was carried out beginning on the 8th day, for seven days.

Euthanasia and tissue collection

At the end of treatment on day 15, the animals were again weighed and anesthetized using the same protocol described above. After an inspection of the animal's state of anesthesia, a new laparotomy was made for removal of the intestines for subsequent analysis. A portion of the collected material was stored in a freezer at -80°C , and the remainder was fixed in 10% buffered formalin for 24 h. After this period, 3-mm sections of the paraffin block were obtained using a rotary microtome.

Immunohistochemistry

The histological technique of immunohistochemistry was used to evaluate the expression of the nuclear factor kappa B (NF- κ B) and tumor necrosis factor (TNF- α) in the animal's intestine. The reacquisition of the antigen was carried out using a buffer at 100 °C; subsequently, the activity of endogenous peroxidase was blocked by incubation with absolute methanol. The slides were incubated with rabbit polyclonal antibody (NF- [sc-9072], 1: 200, Santa Cruz Biotechnology, Santa Cruz, CA, USA) and goat monoclonal antibody (TNF- α [sc-1351], 1: 200, Santa Cruz Biotechnology, Santa Cruz, CA, USA) overnight at 4 °C. Next, the material was washed and incubated with the secondary antibody goat anti-rabbit IgG-HRP (sc-2004) for 30 min at room temperature. The slides were analyzed using a microscope equipped with a digital camera, and the images were captured using the Image-Plus software (Media Cybernetics, Bethesda, MD, USA). Quantification of the marking of both analytes was carried out by digital analysis with Adobe Photoshop® CS3 extended 10.0, using the counting of brown color stained pixels. The expression level was determined by multiplying the average density of the image by the percentage of the stained areas.²⁴

Western blot

The cytosolic extracts prepared on the basis of intestinal homogenates were used in Western blot, and protein values were determined by the Bradford method.²⁵ Then, protein lysates were fractionated by polyacrylamide gel electrophoresis at 9–12% in an electrophoresis buffer (25 mM Tris, 0.2 M glycine, 3.5 mM SDS, pH 8.8) and then transferred to membranes of polyvinylidene fluoride (PVDF). Blocking of the membranes was done using a 5% solution of skimmed milk powder in PBS-Tween. Then, the PVDF membrane was incubated overnight at 4 °C with the specific monoclonal primary antibody, mouse polyclonal antibody (NOS2 [sc-7271], Santa Cruz Biotechnology, Santa Cruz, CA, USA). After the overnight incubation, the membranes were washed with TTBS and incubated for 1 h at room temperature with the secondary antibody IgG-HRP sc-2005, anti-goat donkey (sc-2020, Santa Cruz Biotechnology, Santa Cruz, CA, USA, 1:4000). After revealed, the bands were quantified using the Scion Image program, v. 4.02 for Windows (Scion Corporation, Frederick, USA). The results were expressed in arbitrary units.²⁶

Biochemical analyses

Homogenate

The intestines of the animals were homogenized for 1 min with Ultra-Turrax (IKA-WERK) in the presence of potassium chloride (KCl) 1.15% (5 mL/g of tissue) and phenylmethylsulfonyl fluoride (PMSF) at a concentration of 100 mM in isopropanol (10 μ L/mL KCl added). Then, the homogenates were centrifuged for 10 min at 3000 rpm (1110 \times g) in a refrigerated centrifuge (SORVALL RC-5B Refrigerated Superspeed Centrifuge) and the supernatant was removed and frozen in a freezer at –80 °C for subsequent measurements.²⁷

Protein content

The protein concentration in the homogenates was determined by the Bradford method, with bovine albumin (SIGMA) used as a standard. The samples were measured spectrophotometrically at 595 nm, and the values were expressed in mg/mL. These values were used to calculate subsequently TBA-RS and the values of antioxidant enzymes SOD and GPx.²⁵

Determination of oxidative stress

For the determination of lipid peroxidation, we used the method of reactive substances to thiobarbituric acid (TBA-RS). The technique consists in heating the homogenate in the presence of thiobarbituric acid, with consequent formation of a pink color product, measured in a spectrophotometer at 535 nm. The appearance of color occurs due to the presence of malondialdehyde and other substances from lipid peroxidation in biological material. 0.5 mL of thiobarbituric acid (TBA) 0.67%, 0.25 mL of distilled water, 0.75 mL of trichloroacetic acid (TCA) 10%, and 0.25 mL of the homogenate were placed in a test tube, in this order. TBA reacts with lipid peroxidation products forming a Schiff base, and TCA exerts the function of denaturation of the proteins present and also acidifies the reaction medium. Then, each tube was stirred and heated to 100 °C for 15 min. After that, the tubes were cooled and 1.5 mL of n-butyl alcohol was added to extract the pigment formed. The tubes were placed on a shaker (Biomatic) for 45 s and centrifuged for 10 min at 3000 rpm (1110 \times g). Finally, the stained product was taken away and the reading was taken using a spectrophotometer (CARY 3E – UV – Visible Varian Spectrophotometer) at a wavelength of 535 nm. The concentration of TBA-RS is expressed as nmol/mg protein.²⁸

The activity of superoxide dismutase (SOD) is defined by its ability to inhibit a detection system which reacts with $O_2^{\bullet-}$. For this purpose, adrenaline is used, which, in an alkaline medium, turns to adrenochrome, producing $O_2^{\bullet-}$, which is the substrate of the enzyme. Before performing the determination with the homogenate, measurement of the reaction medium (50 mM glycine-NaOH, pH 9.6) was carried out with 50 μ L of adrenaline (60 mM, pH 2.0), corresponding to 100% of the reaction. This mixture was stirred and read at 480 nm. Subsequently, different volumes of the homogenate (50 μ L, 25 μ L, and 10 μ L) were added, and the inhibition of the reaction was measured. The enzymatic activity was expressed as SOD units/g of tissue (quantity of SOD able to inhibit in 50% the adrenaline reduction rate).²⁹

The determination of glutathione peroxidase (GPx) using the Flohé–Guntzler method³⁰ consists in measuring the NADPH consumption rate in a system containing GSH; the oxidation is recorded spectrophotometrically at a wavelength of 340 nm. To this end, 2.7 mL of a regulating solution of Na⁺ and K⁺ phosphates (100 mM, pH 7.0) with 50 μ L of NADPH (10 mM), 150 μ L of BOOH (10 mM) and 50 μ L of glutathione reductase (12 U/mL) were placed in a quartz cuvette. The mixture was read for 1 min; at this point, a baseline was established, and then 50 μ L of GSH (100 mM) and 50 μ L of the homogenate were added. The samples were incubated at 25 °C for 5 min and read

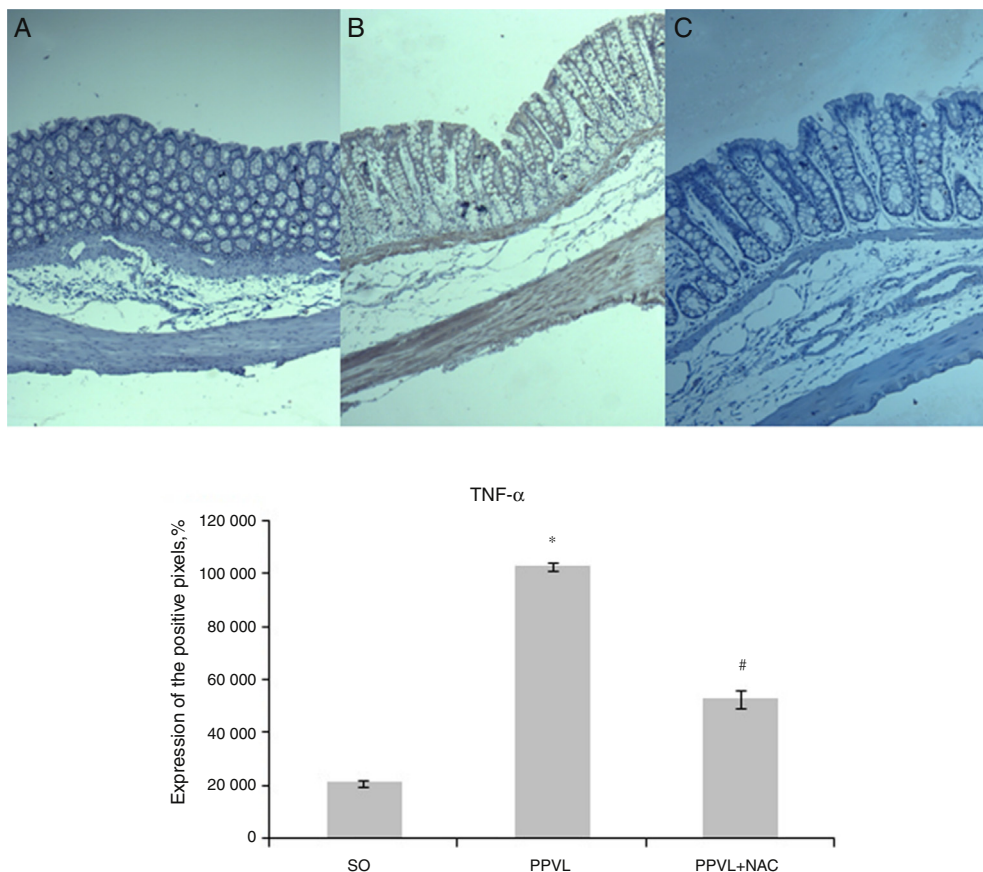


Fig. 1 - Immunohistochemistry of TNF- α . Effects of partial portal vein ligation (PPVL) and N-acetylcysteine (NAC) administration on TNF- α expression. SO, Sham-operated group; PPVL, partial portal vein ligation; PPVL + NAC, partial portal vein ligation treated with NAC. * $p < 0.001$, # $p < 0.001$ ($n = 6$).

at an absorbance of 340 nm. The activity was expressed in nmol/min/mg protein.

Statistical analysis

All data were presented as a mean \pm standard error. Statistical analyses were calculated using Graphpad InStat software, version 3.0 for Windows. Analysis of variance (ANOVA) and the Student–Newman–Keuls test was used for multiple analyses, and the significance level was set at $p < 0.05$ (5%).

Results

Immunohistochemistry

In assessing the expression of the protein TNF- α in the different experimental groups, we observed a significant increase in its markings in PPVL *versus* SO group ($p < 0.001$). The administration of N-acetylcysteine in the proposed dose in this study was able to reduce the expression of TNF- α in PPVL + NAC group ($p < 0.001$) (Fig. 1).

The expression of NF- κ B was increased in animals subjected to the experimental model of PPVL *versus* controls ($p < 0.001$), and the values of PPVL + NAC group were

significantly reduced *versus* values for animals of the diseased group ($p < 0.001$) (Fig. 2).

Western blot

Using Western blot, we observed a significant increase in iNOS expression in the intestine of animals of the diseased group ($p < 0.01$). The animals treated with NAC had their values reduced, as observed in PPVL + NAC group ($p < 0.01$) (Fig. 3).

Biochemical analyses

An increase was observed in lipid peroxidation, evaluated by TBA-RS in animals from PPVL *versus* OS group ($p < 0.05$), and NAC was able to reduce these levels when administered to PPVL + NAC group ($p < 0.01$) (Fig. 4).

SOD activity was also evaluated in the intestine of animals of different experimental groups; the activity was reduced in diseased *versus* control animals ($p < 0.01$), and the treatment has proven effective in increasing the activity of this enzyme ($p < 0.05$) (Fig. 5).

Another antioxidant enzyme, GPx, was also evaluated in this study; We observed a similar behavior in PPVL ($p < 0.05$), and in PPVL + NAC groups *versus* OS group ($p < 0.01$) (Fig. 6).

Discussion

The portal hypertension syndrome shows as characteristics the occurrence of ascites, hepatic encephalopathy, and a hyperdynamic collateral circulation³¹; this latter occurrence is considered the main cause of worsening of the general condition.

The collateral circulation develops in order to divert the blood flow from the obstructed territory; and the obstruction may be situated before (pre-hepatic), into (hepatic) or after (post-hepatic) the liver.³² Regardless of the place of this obstruction, the unblocking compensatory mechanism will eventually result in the formation of varicose veins distributed along the digestive tract of the patient.

In general, varicose veins located in the colon are prevalent in the cecum and rectosigmoid region³³ and characterize portal hypertension colopathy (PHC). In this scenario, the risk of bleeding through colonic varices is 1-8%³⁴; on the other hand, for rectal varicose veins, the risk is from 44 to 89% in cirrhotic patients.⁶ In addition, vascular ectasia and microcirculatory changes along the intestinal mucosa damage its integrity and promote the development of a local inflammatory process.³⁵

The intestinal inflammatory condition present in cases of portal hypertension is considered an aggravating factor in the pathogenesis of the disease. Among the pro-inflammatory cytokines involved in the process, TNF- α is considered as an important mediator, being produced by intestinal mast

cells.³⁶ In this study, we observed a significant increase of this cytokine in the intestine of animals of PPVL group (Fig. 1). The same behavior was observed in the evaluation of NF-kB, which was increased in relation to the animals of SO group (Fig. 2). These data are consistent with studies published, that report leukocyte infiltration and an inflammatory process in this same experimental model.³⁷

N-acetylcysteine was able to reduce the expression of both cytokines evaluated in the intestine of animals of PPVL + NAC group. The anti-inflammatory properties of NAC have been previously described in inflammatory bowel diseases with encouraging results,³⁸ and these results may be related to its thiol group, which is important to combat oxidative stress and inflammation.³⁹ In addition, the treatment with NAC suppresses the activation of NF-kB and the subsequent production of its cytokines and also blocks TNF- α activation, causing structural changes in its receptor.⁴⁰

The involvement of nitric oxide in this experimental model is well established in the literature. With the progression of the disease, the immune system is activated and the inducible form of NOS (iNOS) undergoes up-regulation.⁴⁰ In this study, the animals of PPVL group demonstrated a significant increase in the expression of iNOS versus animals of OS group in the evaluation by Western blot (Fig. 3). A previous study, published by our research group, observed the same behavior of this enzyme in the stomach of animals subjected to the same experimental model of partial portal vein ligation.²³

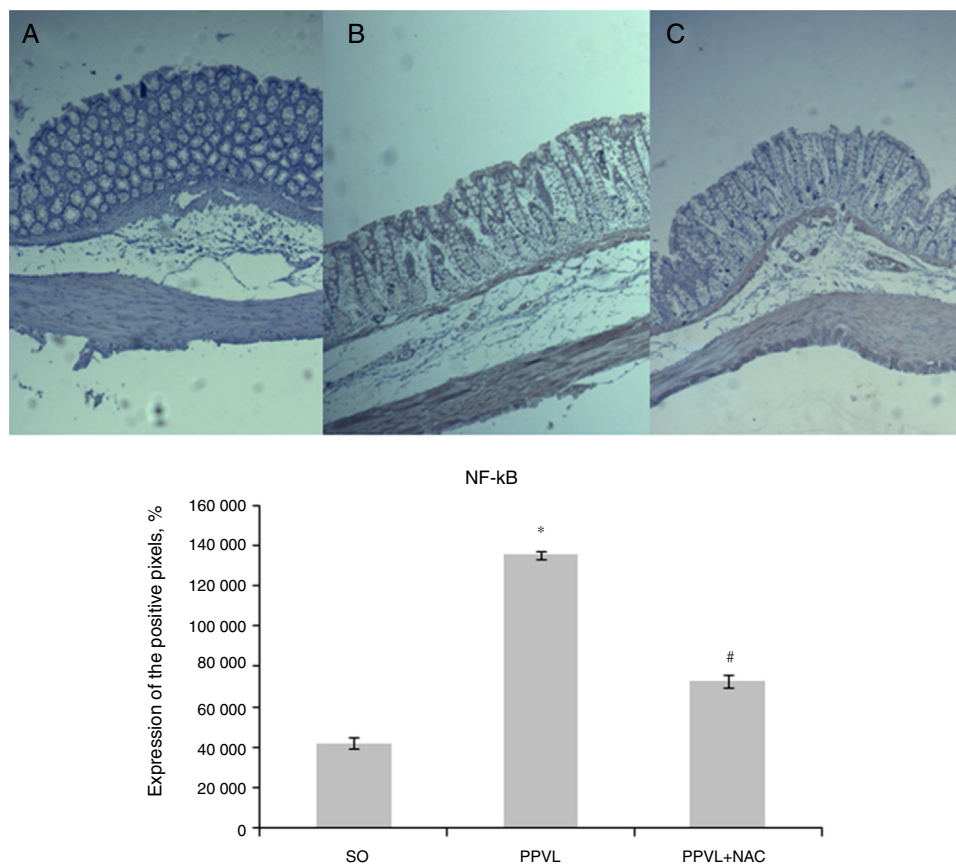


Fig. 2 – Immunohistochemistry of NF-kB. Effects of partial portal vein ligation (PPVL) and N-acetylcysteine (NAC) administration on NF-kB. SO, Sham-operated group; PPVL, partial portal vein ligation; PPVL + NAC, partial portal vein ligation treated with NAC. * $p < 0.001$, # $p < 0.001$ (n = 6).

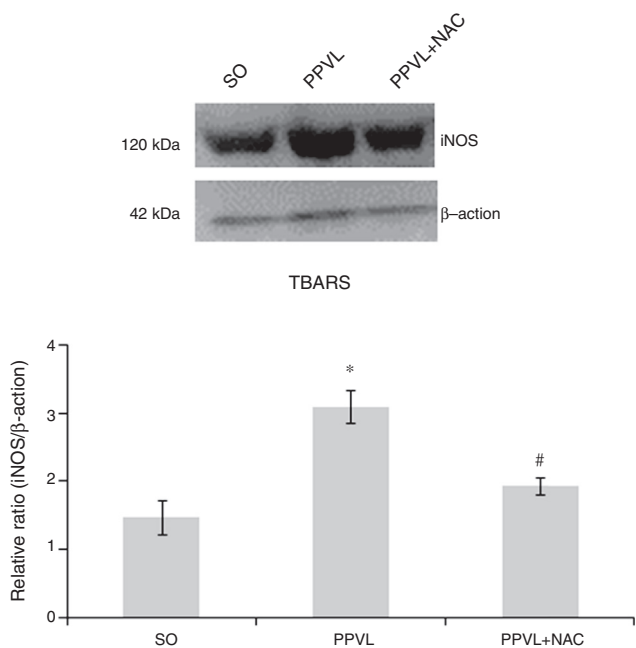


Fig. 3 – Western blot of iNOS. Effects of partial portal vein ligation (PPVL) and N-acetylcysteine (NAC) on iNOS expression. SO, Sham-operated group; PPVL, partial portal vein ligation; PPVL + NAC, partial portal vein ligation treated with NAC. * $p < 0.01$, # $p < 0.01$ (n = 6).

In this study, N-acetylcysteine was able to reduce the levels of iNOS into the intestine of animals of PPVL + NAC group. This finding is in agreement with a previously published study, in which it was reported that NAC inhibits nitric oxide production by cells of the immune system and by the inducible isoform of NOS (iNOS).⁴¹

The involvement of oxidative stress in the development of hyperdynamic circulation was initially proposed by Fernand et al. 1998.⁴² Since then, several studies have demonstrated a positive correlation of the experimental model of partial portal vein ligation with the same oxidative impairments.^{8,9,21-23}

In the present study, we observed increased levels of thiobarbituric acid reactive substances (TBA-RS) in animals subjected to this experimental model (Fig. 4). Furthermore, the increase of lipid peroxidation was accomplished by reducing

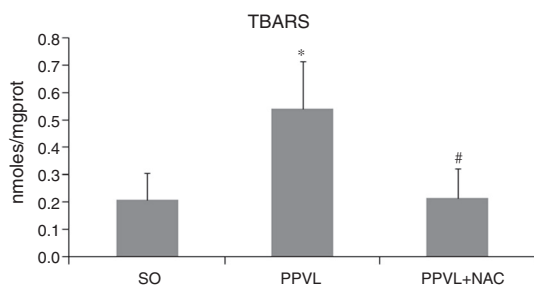


Fig. 4 – TBA-RS. Effects of partial portal vein ligation (PPVL) and N-acetylcysteine (NAC) on TBA-RS values. SO, Sham-operated group; PPVL, partial portal vein ligation; PPVL + NAC, partial portal vein ligation treated with NAC. * $p < 0.05$, # $p < 0.01$ (n = 6).

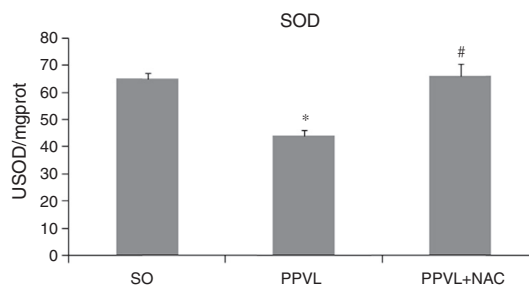


Fig. 5 – SOD. Effects of partial portal vein ligation (PPVL) and N-acetylcysteine (NAC) on SOD activity. SO, Sham-operated group; PPVL, partial portal vein ligation; PPVL + NAC, partial portal vein ligation treated with NAC. * $p < 0.01$, # $p < 0.05$ (n = 6).

the activity of antioxidant enzymes superoxide dismutase (SOD) (Fig. 5) and glutathione peroxidase (GPx). This finding demonstrates a potential condition of oxidative stress in the bowel of experimental animals. This is in agreement with previous studies in which PPVL triggered a condition of oxidative stress in other body organs studied: stomach⁹ and liver.⁸ The antioxidant action of N-acetylcysteine revolves around the fact that this molecule is a cysteine precursor for the synthesis of GSH, and also by acting directly as a free radical scavenger. Thanks to its antioxidant and anti-inflammatory properties, NAC has been widely studied in the treatment of liver diseases.⁴⁰

The authors of this study have already used NAC in the treatment of experimental pre-hepatic portal hypertension, with very promising results.^{9,21} This study demonstrated the role of this molecule in the bowel of animals subjected to the same model, which points to a systemic potential of this drug. NAC was able to reduce lipid peroxidation levels, as measured by TBA-RS, and to restore the activity of both antioxidant enzymes studied (SOD and GPx) in the animals' bowel. Thus, one can say that N-acetylcysteine acted as an antioxidant, reducing oxidative stress in the intestinal mucosa in animals with PPVL.

In conclusion, we point out an anti-inflammatory and antioxidant synergistic effect of N-acetylcysteine in the bowel of animals with portal hypertension. Judging by the results, NAC was able to reduce the intestinal damage in animals by

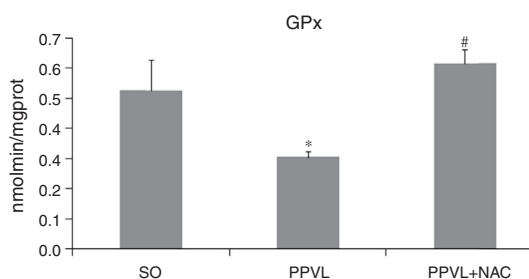


Fig. 6 – GPx. Effects of partial portal vein ligation (PPVL) and N-acetylcysteine (NAC) on GPx activity. SO, Sham-operated group; PPVL, partial portal vein ligation; PPVL + NAC, partial portal vein ligation treated with NAC. * $p < 0.05$, # $p < 0.01$ (n = 6).

reducing oxidative stress and inflammation - both being conditions extremely harmful and determinant in the evolution of the disease here studied.

Conflicts of interest

The authors declare no conflicts of interest.

Acknowledgements

This study received financial support from the Fundo de Incentivo à Pesquisa e Eventos (FIPE Project No. 11-0293) of Hospital de Clínicas de Porto Alegre (HCPA), Coordenação de Aperfeiçoamento de Pessoal de Nível Superior (CAPES) and Conselho Nacional de Desenvolvimento Científico e Tecnológico (CNPq). We want also to thank the contribution of the Experimental Hepatology and Gastroenterology Laboratory (HCPA/UFRGS) and the Oxidative Stress and Antioxidants Laboratory (ULBRA), places of support and development of this study.

REFERENCES

- Dmitry Victorovich Garbuzenko. Contemporary concepts of the medical therapy of portal hypertension under liver cirrhosis. *World J Gastroenterol.* 2015;21:6117-26.
- Bosch J, Groszmann RJ, Shah VH. Evolution in the understanding of the pathophysiological basis of portal hypertension: how changes in paradigm are leading to successful new treatments. *J Hepatol.* 2015;62:S121-30.
- Gjeorgjievski M, Cappell MS. Portal hypertensive gastropathy: a systematic review of the pathophysiology, clinical presentation, natural history and therapy. *World J Hepatol.* 2016;8:231-62.
- Mekaroonkamol P, Cohen R, Chawla S. Portal hypertensive enteropathy. *World J Hepatol.* 2015;7:127-38.
- Misra V, Misra SP, Dwivedi M, Gupta SC. Histomorphometric study of portal hypertensive enteropathy. *Am J Clin Pathol.* 1997;108:652-7.
- Hosking SW, Smart HL, Johnson AG, Triger DR. Anorectal varices, haemorrhoids, and portal hypertension. *Lancet.* 1989;1:349-52.
- Sikuler E, Kravetz D, Groszmann RJ. Evolution of portal hypertension and mechanisms involved in its maintenance in a rat model. *Am J Physiol.* 1985;248:G618-25.
- Gonzales S, Perez MJ, Perazzo JC, Tomaro ML. Antioxidant role of heme oxygenase-1 in prehepatic portal hypertensive rats. *World J Gastroenterol.* 2006;12:4149-55.
- Licks F, Hartmann RM, Marques C, Schemit E, Colares JR, Soares M do C, et al. N-acetylcysteine modulates angiogenesis and vasodilation in stomachs such as DNA damage in blood of portal hypertensive rats. *World J Gastroenterol.* 2015;21:12351-60.
- Geerts AM, Vanheule E, Praet M, Van Vlierberghe H, De Vos M, Colle I. Comparison of three research models of portal hypertension in mice: macroscopic, histological and portal pressure evaluation. *Int J Exp Path.* 2008;89:251-63.
- Aller MA, Arias JL, Cruz A, Arias J. Portal hypertension and inflammation: lessons from the past. *Hepatology, Research Media, in press.*
- Aller MA, Arias JL, Cruz A, Arias J. Inflammation: a way to understanding the evolution of portal hypertension. *Theor Biol Med Model.* 2007;4:44.
- Prieto I, Aller MA, Santamaría L, Nava MP, Madero R, Perez-Robledo JP, et al. Prehepatic portal hypertension produces increased mast cell density in the small bowel and in mesenteric lymph nodes in the rat. *J Gastroenterol Hepatol.* 2005;20:1025-31.
- Gordon JR, Galli SJ. Mast cell as a source of both preformed and immunologically inducible TNF-alpha/cachectin. *Nature.* 1990;346:274-6.
- Glezer I, Marcourakis T, Avellar MCW, Gorenstein C, Scavone C. The role of the transcription factor NF-kB in the molecular mechanisms of action of psychoactive drugs. *Rev Bras Psiquiatr.* 2000;22:26-30.
- Hu LS, George J, Wang JH. Current concepts on the role of nitric oxide in portal hypertension. *World J Gastroenterol.* 2013;19:1707-17.
- Pautz A, Art J, Hahn S, Nowag S, Voss C, Kleinert H. Regulation of the expression of inducible nitric oxide synthase. *Nitric Oxide.* 2010;23:75-93.
- Mankan AK, Lawless MW, Gray SG, Kelleher D, McManus R. NF-kappaB regulation: the nuclear response. *J Cell Mol Med.* 2009;13:631-43.
- Crowley SD. The cooperative roles of inflammation and oxidative stress in the pathogenesis of hypertension. *Antioxid Redox Signal.* 2014;20:102-20.
- Vercelino R, Tieppo J, Dias AS, Marroni CA, Garcia E, Meurer L, et al. N-acetylcysteine effects on genotoxic and oxidative stress parameters in cirrhotic rats with hepatopulmonary syndrome. *Basic Clin Pharmacol Toxicol.* 2008;102:370-6.
- Licks F, Marques C, Zetler C, Martins MI, Marroni CA, Marroni NP. Antioxidant effect of N-acetylcysteine on prehepatic portal hypertensive gastropathy in rats. *Ann Hepatol.* 2014;13:370-7.
- Marques C, Licks F, Zattoni I, Borges B, de Souza LE, Marroni CA, et al. Antioxidant properties of glutamine and its role in VEGF-Akt pathways in portal hypertension gastropathy. *World J Gastroenterol.* 2013;19:4464-74.
- Moreira AJ, Fraga C, Alonso M, Collado PS, Zetler C, Marroni C, et al. Quercetin prevents oxidative stress and NF-kB activation in gastric mucosa of portal hypertensive rats. *Biochem Pharmacol.* 2004;68:1939-46.
- Gaffey MJ, Mills SE, Swanson PE, Zarbo RJ, Shah AR, Wick MR. Immunoreactivity for BER-EP4 in adenocarcinomas, adenomatoid tumors, and malignant mesotheliomas. *Am J Surg Pathol.* 1992;16:593-9.
- Bradford MM. A rapid and sensitive method for the quantitation of microgram quantities of protein utilizing the principle of protein-dye binding. *Anal Biochem.* 1976;72:248-54.
- Towbin H, Staehelin T, Gordon J. Electrophoretic transfer of proteins from polyacrylamide gels to nitrocellulose sheets: procedure and some applications. *Proc Natl Acad Sci.* 1979;76:4350-4.
- Llesuy SF, Milei J, Molina H, Boveris A, Milei S. Comparison of lipid peroxidation and myocardial damage induced by adriamycin and 4'-epiadriamycin in mice. *Tumori.* 1985;71:241-9.
- Buege JA, Aust SD. Microsomal lipid peroxidation. *Methods Enzymol.* 1978;52:302-10.
- Misra HP, Fridovich I. The role of superoxide anion in the autoxidation of epinephrine and a simple assay for superoxide dismutase. *J Biol Chem.* 1972;247:3170-5.
- Flohe L, Gunzler WA, Schock HH. Glutathione peroxidase: a selenoenzyme. *FEBS Lett.* 1973;32:132-4.

31. Sauerbruch T, Trebicka J. Future therapy of portal hypertension in liver cirrhosis – a guess. *F1000Prime Rep*. 2014;6:95.
32. Martinelli ALC. Hipertensão portal. *Medicina*. 2004;37:253–61.
33. Sharma M, Rameshbabu CS. Collateral pathways in portal hypertension. *J Clin Exp Hepatol*. 2012;2:338–52.
34. Ganguly S, Sarin SK, Bhatia V, Lahoti D. The prevalence and spectrum of colonic lesions in patients with cirrhotic and noncirrhotic portal hypertension. *Hepatology*. 1995;21:1226–31.
35. Luigiano C, Iabichino G, Judica A, Virgilio C, Peta V, Abenavoli L. Role of endoscopy in management of gastrointestinal complications of portal hypertension. *World J Gastrointest Endosc*. 2015;7:1–12.
36. Coulon S, Heindryckx F, Geerts A, Van Steenkiste C, Colle I, Van Vlierberghe H. Angiogenesis in chronic liver disease and its complications. *Liver Int*. 2011;31:146–62.
37. Aller MA, de las Heras N, Nava MP, Regadera J, Arias J, Lahera V. Splanchnic-aortic inflammatory axis in experimental portal hypertension. *World J Gastroenterol*. 2013;19:7992–9.
38. Moura FA, de Andrade KQ, Dos Santos JC, Araujo OR, Goulart MO. Antioxidant therapy for treatment of inflammatory bowel disease: does it work. *Redox Biol*. 2015;6:617–39.
39. Kerksick C, Willoughby D. The antioxidant role of glutathione and N-acetylcysteine supplements and exercise-induced oxidative stress. *J Int Soc Sports Nutr*. 2005;9:38–44.
40. de Andrade KQ, Moura FA, dos Santos JM, de Araújo OR, de Farias Santos JC, Goulart MO. Oxidative stress and inflammation in hepatic diseases: therapeutic possibilities of N-acetylcysteine. *Int J Mol Sci*. 2015;16:30269–308.
41. Hou Y, Wang L, Yi D, Ding B, Yang Z, Li J, et al. N-acetylcysteine reduces inflammation in the small intestine by regulating redox, EGF and TLR4 signaling. *Amino Acids*. 2013;45:513–22.
42. Fernando B, Marley R, Holt S, Anand R, Harry D, Sanderson P, et al. N-acetylcysteine prevents development of the hyperdynamic circulation in the portal hypertensive rat. *Hepatology*. 1998;28:689–94.