



## Case Report

# Appendico-cutaneous fistula following hysterectomy: first case report<sup>☆,☆☆</sup>



Antonio Sérgio Brenner<sup>a,\*</sup>, Antonio Baldin<sup>a</sup>, Rafaela Molteni<sup>a</sup>,  
Renata Frões Ramos de Lima<sup>b</sup>, Lígia Heinrichs Freitas<sup>b</sup>, Maria Cristina Sartor<sup>a</sup>,  
Emerson Luís Neves<sup>a</sup>

<sup>a</sup> Universidade Federal do Paraná (UFPR), Hospital de Clínicas, Curitiba, PR, Brazil

<sup>b</sup> Universidade Federal do Amazonas (UFAM), Manaus, AM, Brazil

### ARTICLE INFO

#### Article history:

Received 16 January 2017

Accepted 25 January 2017

Available online 17 March 2017

#### Keywords:

Fistula

Colorectal surgery

Appendix

### ABSTRACT

Appendico-cutaneous fistulas not related to acute appendicitis or cancer are rare and show spontaneous resolution after conservative treatment, mainly when they show low output, absence of obstruction or sepsis and in patients with good nutritional status. We found no report in the literature on appendico-cutaneous fistula after hysterectomy. The evolution of this case shows that this type of fistula can have low, but persistent output, requiring definitive surgery.

© 2017 Published by Elsevier Editora Ltda. on behalf of Sociedade Brasileira de Coloproctologia. This is an open access article under the CC BY-NC-ND license (<http://creativecommons.org/licenses/by-nc-nd/4.0/>).

### Fístula apêndico-cutânea pós histerectomia: primeiro relato de caso

### RESUMO

Fístulas apêndico-cutâneas não relacionadas à apendicite aguda ou neoplasias são raras e de resolução espontânea após tratamento conservador, sobretudo quando se apresentam com baixo débito, ausência de obstrução ou sepse e em pacientes em bom estado nutricional. Não encontramos relato na literatura de fístula apêndico-cutânea após histerectomia. A evolução desse caso demonstra que a esse tipo de fístula pode apresentar débito baixo, mas persistente, demandando cirurgia definitiva.

© 2017 Publicado por Elsevier Editora Ltda. em nome de Sociedade Brasileira de Coloproctologia. Este é um artigo Open Access sob uma licença CC BY-NC-ND (<http://creativecommons.org/licenses/by-nc-nd/4.0/>).

#### Palavras-chave:

Fístula

Cirurgia colorretal

Apêndice

<sup>☆</sup> Study carried out at Universidade Federal do Paraná (UFPR), Hospital de Clínicas, Departamento de Cirurgia, Serviço de Coloproctologia, Curitiba, PR, Brazil.

<sup>☆☆</sup> Study submitted for presentation at II Congresso Setorial do CBC, Capítulo do Amazonas. October, 2016.

\* Corresponding author.

E-mail: [drbrenner@iadc Curitiba.com.br](mailto:drbrenner@iadc Curitiba.com.br) (A.S. Brenner).

<http://dx.doi.org/10.1016/j.jcol.2017.01.002>

2237-9363/© 2017 Published by Elsevier Editora Ltda. on behalf of Sociedade Brasileira de Coloproctologia. This is an open access article under the CC BY-NC-ND license (<http://creativecommons.org/licenses/by-nc-nd/4.0/>).

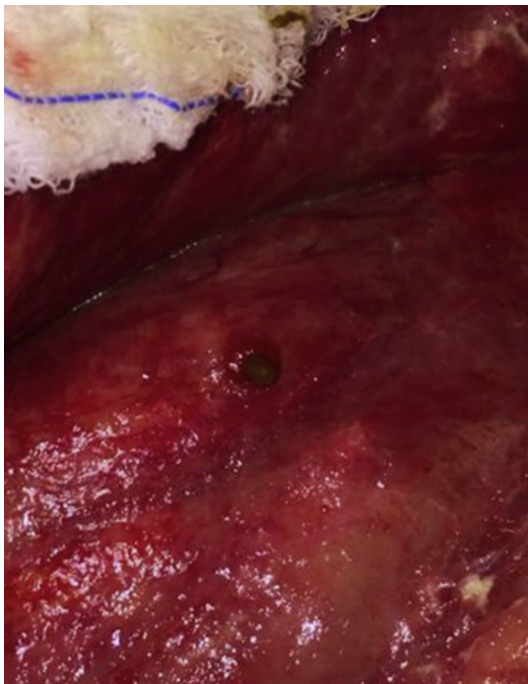
## Introduction

Digestive fistulas are abnormal communications between two epithelial surfaces. They are classified as internal (between the digestive tract and intra-abdominal organs) and external (between the digestive tract and the skin). They can be congenital or acquired. Digestive fistulas occur postoperatively in 85% of cases, mostly due to failure to heal digestive sutures. They can also be spontaneous and appear as a complication during the evolution of Crohn's disease (39%), ulcerative colitis (13%), malignancy (9%), radiation (6%), diverticular disease (5%), among others.<sup>1</sup> The appendix is rarely involved, predominantly due to complicated acute appendicitis or neoplasms. We did not identify reports in the literature on appendico-cutaneous fistula literature after total abdominal hysterectomy (TAH).

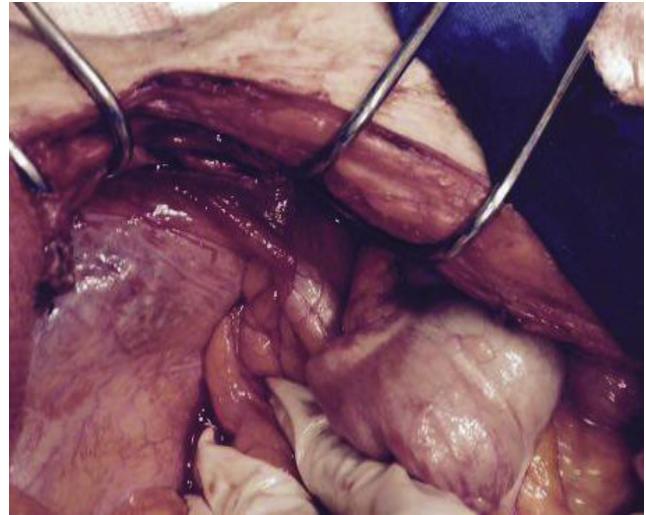
## Case report

A 40-year-old female patient with type 2 diabetes, systemic arterial hypertension, grade III obesity with a previous history of gastropasty through median laparotomy in 2006 (prior BMI: 57.40 kg/m<sup>2</sup> and current: 46.2 kg/m<sup>2</sup>) developed a moderate-sized incisional hernia.

She was submitted to total abdominal hysterectomy (TAH) (Pfannenstiel incision) due to uterine myomatosis and refractory dysmenorrhea. She was discharged from the hospital on the 2nd postoperative (PO) day, being readmitted on the 8th PO day due to surgical wound infection and skin dehiscence with points of necrosis. She developed necrotizing fasciitis requiring debridement and antibiotic therapy. On the 30th PO day, the patient showed enteric secretion drainage (100 mL/day) through the labiate ostium in the granulation area of the



**Fig. 1 – Appendicular fistula orifice in granulation tissue.**



**Fig. 2 – Vermiform appendix fistulizing in the granulation area.**

surgical wound (Fig. 1). No extravasation was observed after methylene blue was swallowed. The abdominal tomography was normal and a fistulography showed a short fistula pathway contrasting the right colon. Initially we chose a conservative treatment with fasting and total parenteral nutrition (TPN). The output remained stable, and surgical treatment was decided.

The patient was submitted to mid-incision exploratory laparotomy approaching the supra-umbilical incisional hernia up to the infra-umbilical granulation tissue, where the labiate fistula was located. During the laparotomy, the presence of adhered and fistulizing cecal appendix was observed in the granulation area of the abdominal wall (Fig. 2). The pathway was catheterized, confirming the appendicular fistula. An appendectomy was performed associated with hernioplasty, using a polypropylene mesh and dermolipectomy.

The patient evolved with surgical wound infection and border necrosis, requiring antibiotic therapy with Metronidazole and Vancomycin, associated with surgical debridement and subsequent closure of the abdominal wall by free grafting through plastic surgery.

## Discussion

Appendico-cutaneous fistula unrelated to acute appendicitis are rare. There are reports in the literature on fistulas caused by appendicular mucinous cystadenocarcinoma<sup>2-6</sup> and/or congenital ones.<sup>7</sup> In this review, we found no reports of appendico-cutaneous fistulas due to iatrogenic or surgical complications, unrelated to appendix diseases or appendectomies.

With the advances in intensive care and total parenteral nutrition (TPN), antibiotic therapy and operative techniques, the mortality of patients with digestive fistulas decreased from 40% to 65% from the 1980s to 10% to 15% in recent literature reports.<sup>1</sup> The main causes of mortality continue to be malnutrition, hydroelectrolytic disorders and sepsis.

The expected outcome of an appendico-cutaneous fistula would be its spontaneous resolution after conservative treatment, mainly considering its characteristics of low output, postoperative etiology, absence of obstruction or sepsis, patient with good nutritional status and primary surgery performed at the same institution.<sup>8</sup> The evolution of this case shows that the appendico-cutaneous fistula can show specific characteristics of low and persistent flow even after the use of TPN, demanding definitive surgical correction.

---

### Conflicts of interest

The authors declare no conflicts of interest.

### REFERENCES

---

1. Campos ACL, Borges A, Haida VM. Terapia nutricional nas fistulas digestivas. In: Campos ACL, editor. Tratado de nutrição e metabolismo em cirurgia. 1 ed Rio de Janeiro: Rubio; 2013. p. 399-412.
2. Mishin I, Ghidirim G, Vozian M. Appendiceal mucinous cystadenocarcinoma with implantation metastasis to the incision scar and cutaneous fistula. *J Gastrointest Cancer*. 2012;43:349-53.
3. Hadj-Taieb I, Masmoudi A, Ayadi L, Meziou TJ, Khabir A, Charfeddine A, et al. Appendicular cystadenocarcinoma with cutaneous fistula. *Ann Dermatol Venereol*. 2010;137:198-202.
4. Ghidirim G, Gagauz I, Mişin I, Canariov M, Ionesii P, Zastavnitchi G. Mucinous cystadenocarcinoma of the appendix complicated with spontaneous cutaneous fistula. *Chirurgia (Bucur)*. 2007;102:231-5.
5. Nakao A, Sato S, Nakashima A, Nabeyama A, Tanaka N. Appendiceal mucocele of mucinous cystadenocarcinoma with a cutaneous fistula. *J Int Med Res*. 2002;30:452-6.
6. Shija JK. Congenital appendiceal-cutaneous fistula with appendiceal intussusception and herniation through an umbilical defect. *J R Coll Surg Edinb*. 1986;31:184-5.
7. Jagdish S, Ninan S, Pai D, Ratnakar C. Spontaneous appendicocutaneous fistula. *Indian J Gastroenterol*. 1996;15:31.
8. Berry SM, Fischer JE. Classification and pathophysiology of enterocutaneous fistulas. *Surg Clin North Am*. 1996;76: 1009-18.