



Case Report

Hemipelvectomy with laparoscopic abdominoperineal excision for epithelioid sarcoma treatment[☆]



Daniel Paulino Santana^a, Matheus Matta Machado Mafra Duque Estrada Meyer^{a,*}, Edmilson Celso Santos^a, Camila Gomes de Souza Andrade^b, Paulo Vilela Neto^b, Aline Alves Matoso^c, Bruna Sílvia Torres Santos^c, Bruno José Guedes Silva^c, Danielle Bossi Grassi Ferreira^c, Larissa Vasconcelos Horta^c, Marcos Campos Wanderley Reis^d

^a Hospital da Baleia, Belo Horizonte, MG, Brazil

^b Hospital da Baleia, Programa de Residência Médica de Cirurgia Geral, Belo Horizonte, MG, Brazil

^c Faculdade de Medicina de Barbacena, Barbacena, MG, Brazil

^d Hospital da Baleia, Serviço de Cirurgia Geral, Belo Horizonte, MG, Brazil

ARTICLE INFO

Article history:

Received 28 August 2016

Accepted 27 March 2017

Available online 12 May 2017

Keywords:

Sarcoma

Epithelioid sarcoma

Soft tissue sarcoma

Neoplasm

ABSTRACT

The epithelioid sarcoma (ES) is an unusual variant of the sarcoma, not reaching 1% of all soft tissue sarcomas. Initially reported in 1970, it has a more aggressive variant, which was classified as the “proximal-type” in 1997. These are aggressive tumors with high rates of distant metastasis and local relapses. Isolated radio and chemotherapy responses are poor and free-margin surgical resection is the treatment of choice.

This is the case report of a 25-year-old male patient diagnosed with “proximal-type” ES in the perineal region. He underwent surgical resection in another institution and was later admitted to our institution with local recurrence with rectal and left thigh muscle invasion. Neoadjuvant radio-chemotherapy was performed, followed by laparoscopic abdominoperineal rectal resection and partial left hemipelvectomy associated with left lower-limb amputation. The patient had no postoperative complications and is currently undergoing outpatient follow-up. The anatomopathological analysis showed tumor-free margins.

The “proximal-type” ES is a rare soft-tissue sarcoma subtype. High local recurrence, as well as the metastasis rates, makes its treatment a challenging task.

© 2017 Sociedade Brasileira de Coloproctologia. Published by Elsevier Editora Ltda. This is an open access article under the CC BY-NC-ND license (<http://creativecommons.org/licenses/by-nc-nd/4.0/>).

[☆] Study conducted at Fundação Benjamin Guimarães, Hospital da Baleia, Departamento de Cirurgia Geral, Belo Horizonte, MG, Brazil.

* Corresponding author.

E-mail: matheusww@gmail.com (M.M. Meyer).

<http://dx.doi.org/10.1016/j.jcol.2017.03.005>

2237-9363/© 2017 Sociedade Brasileira de Coloproctologia. Published by Elsevier Editora Ltda. This is an open access article under the CC BY-NC-ND license (<http://creativecommons.org/licenses/by-nc-nd/4.0/>).

Hemipelvectomia com amputação laparoscópica do reto para tratamento de sarcoma epitelióide

R E S U M O

Palavras chave:

Sarcoma
Sarcoma epitelióide
Sarcoma de tecidos moles
Neoplasia

O sarcoma epitelióide (SE) é um subtipo incomum de sarcoma, não chegando a 1% dos sarcomas de partes moles. Foi inicialmente descrito em 1970, sendo que em 1997 uma variante mais agressiva foi classificada como “tipo proximal”. São tumores agressivos, com altas taxas de metástases e recidiva local, com resposta pobre à quimioterapia e radioterapia isoladas. A ressecção cirúrgica com margens livres é o tratamento padrão.

Apresentamos o caso de um paciente de 25 anos com SE tipo proximal avançado em região perineal, submetido a ressecção em outro serviço, evoluindo com recidiva local com invasão do canal anal e musculatura da coxa esquerda. Foi realizado tratamento radioquimioterápico neoadjuvante seguido de ressecção cirúrgica com amputação abdominoperineal do reto por videolaparoscopia associada a hemipelvectomia parcial esquerda incluindo o membro inferior esquerdo (MIE). O paciente apresentou boa evolução pós operatória e encontra-se em segmento ambulatorial. O anatomopatológico evidenciou margens cirúrgicas livres.

O SE proximal é um tipo raro de sarcoma de partes moles, cujo tratamento curativo é desafiador, em virtude dos altos índices de recidiva local e metástases à distância.

© 2017 Sociedade Brasileira de Coloproctologia. Publicado por Elsevier Editora Ltda. Este é um artigo Open Access sob uma licença CC BY-NC-ND (<http://creativecommons.org/licenses/by-nc-nd/4.0/>).

Introduction

Soft tissue sarcomas are rare neoplasms, accounting for approximately 1% of malignant tumors in adults. These tumors originate from the mesenchyme, which can result in several histological subtypes. The epithelioid sarcoma (ES) consists in a rare subtype, corresponding to less than 1% of soft-tissue sarcomas. It was first described by Ezinger in 1970,¹ with a typical histology of granulomatous tissue, characterized by the presence of multiple nodules, spindle cells and central necrosis. They occur more often in the distal topography of young adult limbs, especially in the hands. A more aggressive variant was described by Guillou in 1997,² being called “proximal type”, with greater occurrence in the pelvis, perineum, and genital tract, also in young individuals. The typical granuloma-like histology of the conventional ES was shown to be less frequent, added to the presence of polygonal cells with epithelioid and rhabdoid traits, similar to the findings of undifferentiated carcinomas.

The “proximal type” ES is a tumor with a worse prognosis when compared to conventional ES, with high rates of local recurrence, as well as hematogenous metastases that can vary between 30 and 50% of the cases.³ Lymph node metastasis is unusual in sarcomas, being more common in cases of proximal ES. These are tumors that show little response to chemotherapy and radiotherapy alone, with the standard treatment being surgical resection with free margins. Tumor size seems to be the only well-defined prognostic factor.

Overall survival for patients with conventional ES varies from 50 to 70% in 5 years,³⁻⁶ whereas the cases of “proximal type” SE have lower survival, with 65% of cases recurring and 75% having metastases, especially in the lymph nodes.⁷

Approximately 65% of patients die of the disease, most of them due to metastatic disease.⁷

The aim of this study was to report a case of advanced proximal epithelioid sarcoma in the perineal region in a 25-year-old patient undergoing multidisciplinary treatment in our institution.

Case report

A 25-year-old male patient, with a hard and ulcerated palpable mass in the left perianal region, with an initial diagnosis of perianal abscess, admitted to another service where an unsuccessful drainage attempt was performed, followed by surgical resection. Anatomopathological examination revealed a 3.5 × 3.2 cm lesion with epithelioid sarcoma microscopy result with free surgical margins.

He was admitted to our institution by the Oncology service, with negative staging for metastases through computed tomography (CT) of the thorax, abdomen, and pelvis, which disclosed only fibrosis area in soft tissue of the perineum, compatible with postoperative status. Adjunctive chemotherapy with ifosfamide and doxorubicin was proposed together with the initial resection, but the patient showed severe neutropenia, requiring treatment discontinuation. There was early recurrence of the lesion and rapid local progression, with infiltration of the left thigh root. Magnetic resonance imaging (MRI) was performed, showing heterogeneous expansive formation, located in the left thigh root, affecting the adductor musculature, extending to the ischioanal fossa, with no cleavage planes with the anal canal. The surgical reapproach was chosen, but neoadjuvant radiochemotherapy was started.

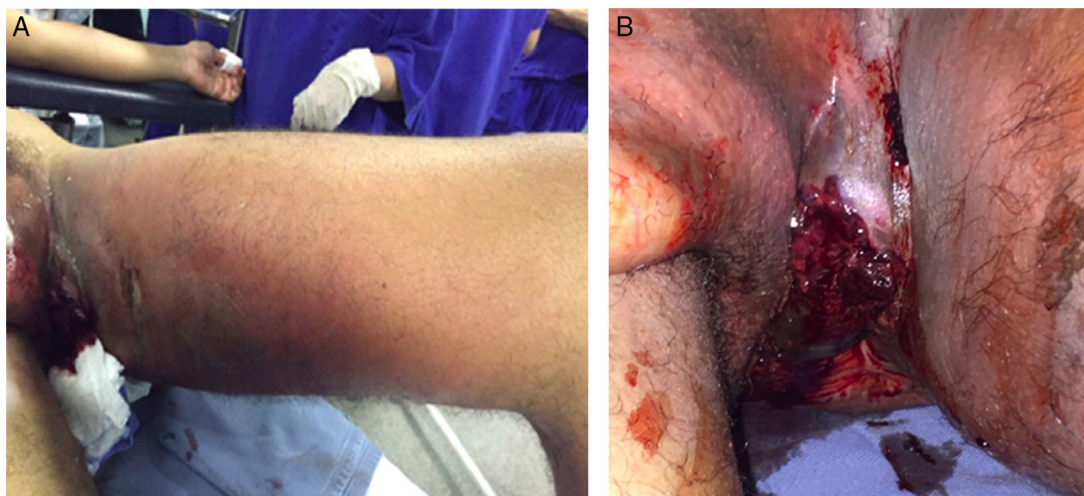


Fig. 1 – In (A) ulcerated tumor lesion in the perineal region extending to the left thigh; (B) in the detail, ulcerated lesion, and perineal bleeding.

The patient showed clinical progression of the lesion, with incapacitating pain in the left lower limb, permanent semi-flexed position, and skin ulceration in the left perianal region with continuous small bleeding. The re-staging with MRI showed massive heterogeneous expansive formation in the left perineal region, solid, with areas of necrosis in its interior, involving the deep muscular planes, with no cleavage planes with the anal canal on the left, and no signs of invasion of the genitourinary tract. It extended through the musculature of the medial aspect of the left thigh to its distal third, measuring about $22.0 \times 9.5 \times 6.0$ cm. Inguinal lymphadenomegalies were identified on the left. The patient was then admitted for pain control and prepared for surgery by a multidisciplinary team (Oncologic Surgery, Coloproctology, Urology, Orthopedics, and Plastic Surgery) with a proposal of abdomino-perineal amputation of the rectus through videolaparoscopy, associated with left hemipelvectomy including the LLL (Fig. 1).

Initially, a minimally invasive videolaparoscopic approach was used to dissect the entire rectosigmoid, with complete excision of the mesorectum near the pelvic floor, ligation of the inferior mesenteric vessels, and ligation of the left internal iliac artery, aiming to reduce bleeding in the perineal approach. A terminal colostomy was created on the left flank. In the perineal area, the rectum was amputated together with soft parts of the perineum on the left, with free macroscopic margins, preserving the genitourinary tract, which did not show any invasion. Left inguinal dissection was performed, associated with left partial hemipelvectomy together with the LLL (Fig. 2). The reconstruction was carried out using a biological mesh of porcine acellular dermal tissue (Permacol®) for correction of the pelvic defect, as well as coverage using a lateral musculocutaneous flap of the thigh, as there was no evidence of tumor involvement (Fig. 3). The surgical procedure was uneventful, with a total duration of 7 h, with 600 mL of packed red blood cell being transfused due to the previously low levels of hemoglobin. The patient was referred to the ICU, hemodynamically stable. He showed a favorable postoperative evolution, being discharged from the hospital after 9 days.

Anatomopathological examination disclosed a poorly differentiated proximal epithelioid sarcoma measuring $38 \times 11 \times 6$ cm, with 60% necrosis, affecting soft tissues in the deep planes of the perineal region and the medial thigh area, reaching the popliteal fossa. The rectosigmoid segment showed multifocal infiltration. Angiolymphatic and perineural invasion were present, with free proximal, distal, and radial margins. Eleven inguinal and 8 peri-rectal lymph nodes were dissected without neoplastic involvement.

The patient is being followed up in an outpatient setting, with no signs of tumor recurrence.

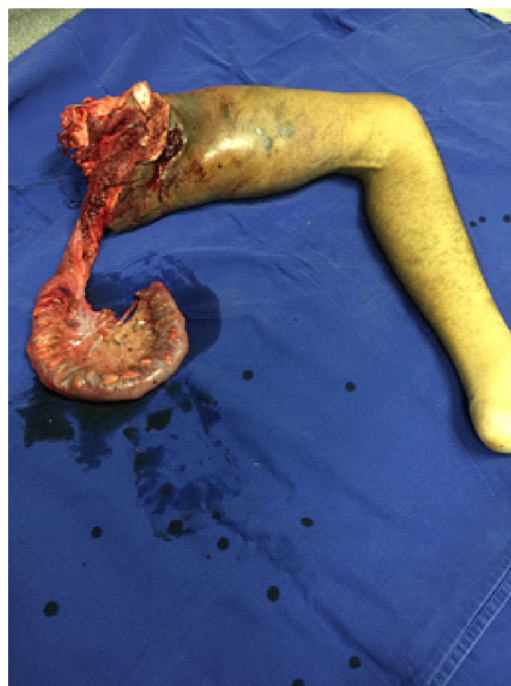

Fig. 2 – Surgical piece in monobloc.

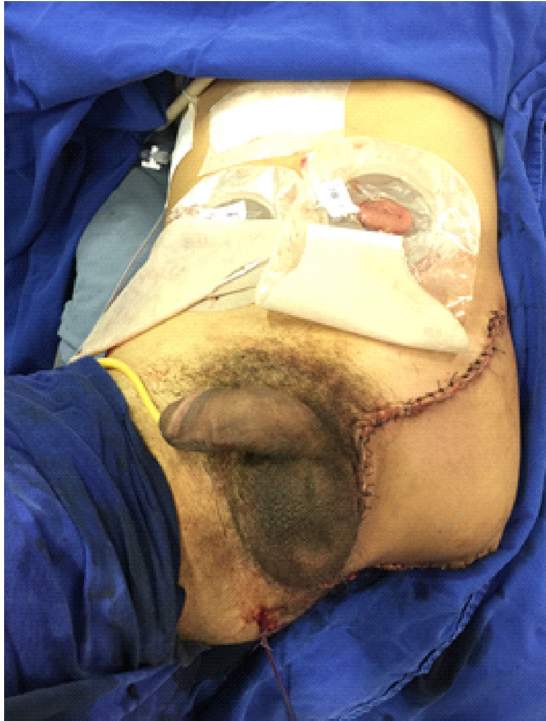

Fig. 3 – Final aspect after reconstruction with lateral thigh flap.

Discussion

The proximal ES is a rare subtype of soft tissue sarcoma corresponding to less than 1% of all types, with a higher incidence in young male adults. The diagnosis considers the histopathological and immunohistochemical characteristics for epithelial markers. The proximal subtype differs from the classic type due to its multinodular growth pattern, predominantly proximal location (pelvis, perineum and genital tract) and more aggressive clinical behavior since the beginning of the presentation,⁸ with high rates of local recurrence after resection, and hematogenous metastasis, especially to the lungs, and lymphatic areas.

There is no consensus about the treatment of proximal ES. Most patients undergo a multimodal treatment that includes surgical resection, plus radiotherapy and chemotherapy. Studies with neoadjuvant chemotherapy regimens for soft tissue sarcomas indicate a 30–60% response rate and a significant improvement in recurrence and disease-free survival. The association with radiotherapy seems to increase resectability and limb preservation rates. Additionally, adjuvant radiotherapy has a well-defined role in the best local control of the disease, being indicated for high-grade tumors, those larger than 5 cm and/or compromised surgical margins.⁹

In the present case, combined chemotherapy with ifosfamide and doxorubicin, associated with radiotherapy was carried out as neoadjuvant therapy due to the large extension

of the lesion, aiming to increase the chances of curative resection. The multidisciplinary approach consisted of extensive resection with enlarged laparoscopic abdominoperineal amputation to the left perineal region associated with *en bloc* left hemipelvectomy. The anatomopathological examination showed free surgical margins and there was no lymph node involvement among the 19 dissected lymph nodes, even though it was a proximal epithelioid sarcoma, where such occurrence is more frequent. These patients require strict postoperative follow-up to detect local, regional and distant metastases.

Conclusion

The proximal ES is a rare type of soft tissue sarcoma, of which histological diagnosis is difficult, as well as its treatment, due to high rates of local recurrence, distant metastasis and low response to chemotherapy and isolated radiotherapy. In many cases, extensive surgical resection with great mutilating potential are necessary, in view of their proximal site of involvement. Postoperative follow-up should be stringent, and the prognosis is poor, since 80% of cases die from the disease within the first 3 years after the initial diagnosis.

Conflicts of interest

The authors declare no conflicts of interest.

REFERENCES

1. Enzinger FM. Epithelioid sarcoma. A sarcoma simulating a granuloma or a carcinoma. *Cancer*. 1970;26:1029–41.
2. Guillou L, Wadden C, Coindre JM, Krausz T, Fletcher CD. 'Proximal-type' epithelioid sarcoma, a distinctive aggressive neoplasm showing rhabdoid features. Clinicopathologic, immunohistochemical, and ultrastructural study of a series. *Am J Surg Pathol*. 1997;21:130–46.
3. Chase DR, Enzinger FM. Epithelioid sarcoma. Diagnosis, prognostic indicators, and treatment. *Am J Surg Pathol*. 1985;9:241–63.
4. Ross HM, Lewis JJ, Woodruff JM, Brennan MF. Epithelioid sarcoma: clinical behavior and prognostic factors of survival. *Ann Surg Oncol*. 1997;4:491–5.
5. Fong Y, Coit DG, Woodruff JF, Brennan MF. Lymph node metastasis from soft tissue sarcoma in adults. Analysis of data from a prospective database of 1771 sarcoma patients. *Ann Surg*. 1992;217:72–7.
6. Bos GD, Pritchard DJ, Reiman HM, Dobyns JH, Ilstrup DM, Landon GC. Epithelioid sarcoma. An analysis of fifty-one cases. *J Bone Joint Surg Am*. 1988;70:862–70.
7. Hasegawa T, Matsuno Y, Shimoda T, Umeda T, Yokoyama R, Hiro-hashi S. Proximal-type epithelioid sarcoma: a clinicopathologic study of 20 cases. *Mod Pathol*. 2001;14:655–63.
8. Armah HB, Parwani AV. Epithelioid sarcoma. *Arch Pathol Lab Med*. 2009;133:814–9.
9. Hikosaka A, Yamada K, Fujita K, Iwase Y, Tada T. Proximal-type epithelioid sarcoma of the perineum: calling attention of urologists. *Int J Urol*. 2006;13:1542–4.