



Journal of Coloproctology

www.jcol.org.br



Original Article

The role of Phosphatidylinositol 3 kinase (PI3K) and Cyclooxygenase-2 (COX2) in carcinogenesis of colorectal polyps[☆]



Raul Alberto Anselmi Júnior^a, Cleber Machado de Souza^b,
Marina Luise Viola de Azevedo^b, Mário Rodrigues Montemor Netto^c,
Rosimeri Kuhl Svoboda Baldin^{d,*}, Ana Paula Martins Sebastião^d,
Luiz Felipe Paula Soares^e, Luis Fernando Tullio^e, Lúcia de Noronha^a

^a Pontifícia Universidade Católica do Paraná (PUCPR), Faculdade de Medicina, Curitiba, PR, Brazil

^b Pontifícia Universidade Católica do Paraná (PUCPR), Escola de Saúde e Biociências, Curitiba, PR, Brazil

^c Universidade Estadual de Ponta Grossa (UEPG), Ponta Grossa, PR, Brazil

^d Universidade Federal do Paraná (UFPR), Departamento de Patologia Médica, Curitiba, PR, Brazil

^e Hospital Santa Cruz, Serviço de Endoscopia, Curitiba, PR, Brazil

ARTICLE INFO

Article history:

Received 11 July 2017

Accepted 26 August 2017

Available online 20 November 2017

Keywords:

PI3K

COX2

Colorectal cancer

Adenoma

ABSTRACT

Objectives: Determine immunohistochemical expression of Phosphatase and tensin homolog (PTEN), Phosphatidylinositol 3 kinase (PI3K), Cyclooxygenase-2 (COX2) and one proliferation marker (Ki67) in colorectal polyps and correlate with clinical and pathological data in search of carcinogenic pathways.

Methods: The reports of 297 polyps diagnosed through endoscopy were reviewed for parameters including age, gender, prior colorectal cancer, the presence of multiple polyps, and polyps' location, appearance and size. Was conducted a microscopic morphometric computerized analysis of immunohistochemical expression using the selected antibodies and correlated with clinical and pathological variables.

Results: The tissue immunohistochemical expression was higher in right colon polyps for the proliferation marker and Phosphatidylinositol 3 kinase ($p \leq 0.0001$ and 0.057 respectively). Cyclooxygenase-2 and Phosphatase and tensin homolog demonstrated higher tissue immunorexpression in pedunculated polyps ($p = 0.009$ and 0.002 respectively). Cyclooxygenase-2 exhibited higher immunorexpression in larger polyps ($p = 0.005$). Phosphatidylinositol 3 kinase, Cyclooxygenase-2, Phosphatase and tensin homolog and the proliferation marker exhibited higher immunorexpression in high-grade dysplastic polyps ($p = 0.031$, 0.013 , 0.044 and <0.001 respectively). Phosphatase and tensin homolog labeling was higher in polyps with high-grade dysplasia and lower in some of serrated lesions ($p = 0.044$).

Conclusions: The greater expression of the proliferation marker and Phosphatidylinositol 3 kinase in the right colon may be related to right-sided colorectal carcinogenesis. The

[☆] Study conducted at Pontifícia Universidade Católica do Paraná (PUCPR), Faculdade de Medicina, Curitiba, PR, Brazil.

* Corresponding author.

E-mail: rosimeribaldin@gmail.com (R.K. Baldin).

<https://doi.org/10.1016/j.jcol.2017.08.005>

2237-9363/© 2017 Sociedade Brasileira de Coloproctologia. Published by Elsevier Editora Ltda. This is an open access article under the CC BY-NC-ND license (<http://creativecommons.org/licenses/by-nc-nd/4.0/>).

proliferation marker, Cyclooxygenase-2 and Phosphatidylinositol 3 kinase results can be associated with progression of polyps to colorectal cancer. The higher Phosphatase and tensin homolog expression suggests its attempt to control the cell cycle.

© 2017 Sociedade Brasileira de Coloproctologia. Published by Elsevier Editora Ltda. This is an open access article under the CC BY-NC-ND license (<http://creativecommons.org/licenses/by-nc-nd/4.0/>).

O papel de PI3K e COX2 na carcinogênese de pólipos colorretais

R E S U M O

Palavras-chave:

PI3K
COX2
Câncer colorretal
Adenoma

Objetivos: Determinar a expressão imuno-histoquímica de Fosfatase homóloga a tensina (PTEN), Fosfatidilinositol-3-cinase (PI3K), Ciclooxygenase-2 (COX2) e um marcador de proliferação (Ki67) em pólipos colorretais e correlacionar com dados clínicos e patológicos buscando sua correspondência na carcinogênese.

Métodos: Revisados 297 pólipos diagnosticados através de endoscopia quanto a idade, gênero, história de câncer colorretal, número, localização, aparência e tamanho dos pólipos. Realizadas as avaliações morfométricas computadorizadas das expressões imuno-histoquímicas dos marcadores selecionados, que foram correlacionadas com variáveis clínicas e patológicas.

Resultados: A expressão do marcador de proliferação e da Fosfatidilinositol-3-cinase foi maior nos pólipos do cólon direito ($p < 0,0001$ e $0,057$ respectivamente). Ciclooxygenase-2 e Fosfatase homóloga a tensina demonstraram maior imunexpressão em pólipos pediculados ($p = 0,009$ e $0,002$, respectivamente). Ciclooxygenase-2 expressou mais em pólipos maiores ($p = 0,005$). Fosfatidilinositol-3-cinase, Ciclooxygenase-2, Fosfatase homóloga a tensina e o marcador de proliferação expressaram mais em pólipos com displasia de alto grau ($p = 0,031$, $0,013$, $0,044$ e $< 0,001$, respectivamente). Fosfatase homóloga a tensina marcou mais pólipos com displasia de alto grau que lesões serrilhadas ($p = 0,044$).

Conclusões: A maior expressão do marcador de proliferação e Fosfatidilinositol-3-cinase à direita pode estar relacionada à carcinogênese do lado direito do cólon. Os resultados do marcador de proliferação, Ciclooxygenase-2 e Fosfatidilinositol-3-cinase podem ser associados à progressão dos pólipos para câncer. A expressão aumentada de Fosfatase homóloga a tensina sugere tentativa de controle do ciclo celular.

© 2017 Sociedade Brasileira de Coloproctologia. Publicado por Elsevier Editora Ltda. Este é um artigo Open Access sob uma licença CC BY-NC-ND (<http://creativecommons.org/licenses/by-nc-nd/4.0/>).

Introduction

Colorectal cancer is the third most frequently diagnosed malignancy in men and the second most frequently diagnosed cancer type in women worldwide, with 1.3 million new case reports and 694,000 deaths in 2012.¹⁻⁴

Colorectal carcinogenesis phenomena may be studied through the evaluation of signaling pathway protein expression as these events may be the result of alterations in genes that are coding proteins of cycle cell.⁵⁻⁷ Thus, the changes in these proteins' structure may modify functional aspects involving these molecules.

It has already been well-characterized three molecular pathways of colorectal carcinogenesis: chromosomal instability, microsatellite instability and serrated pathway.⁶

The pathway of chromosomal instability, also called the classical pathway, occurs due to somatic or germline mutation. This pathway occurs through a sequence of cumulative molecular changes, denominated "adenoma-carcinoma sequence".⁵

Concerning the pathway of microsatellite instability, there is a dysfunction of deoxyribonucleic acid (DNA) repair enzymes, due to germline mutations in mismatch repair genes (MMR), with formation of tens to hundreds of repetitions of short sequences of nucleotide bases by the genome, called microsatellites.⁸

Regarding the serrated pathway, there is no mutation of MMR genes but an epigenetic phenomenon, called hypermethylation of promoter gene MMR enzyme that makes the silencing of their gene expression.^{9,10}

Apparently, genetic alterations that occur in colorectal cancer follow the histologic progression of adenomas.¹¹ The use of molecular and tissue immunohistochemical markers for colorectal polyp evaluation has been helpful in predicting malignant transformation and has provided a better understanding of this neoplastic biological behavior.¹²

PTEN (phosphatase and tensin homolog) acts on the negative regulation of the PI3K-AKT-mTOR (phosphatidylinositol 3-kinase – serine/threonine kinase – mechanistic target of rapamycin) pathways and on the silencing of growth factor

receptors such as Epidermal growth factor receptor (EGFR), Human Epidermal growth factor Receptor-type 2 (HER-2) and insulin-like growth factor 1 (IGFR). *PTEN* function loss occurs through mutations, deletions or genetic silencing in a wide range of human cancers. *PTEN* is the second most mutated tumor suppressor gene after the tumor protein p53 (*Tp53*) gene.^{13,14}

PI3K promote cellular proliferation and survival. Phosphatidylinositol-4,5-bisphosphate 3-kinase, catalytic subunit alpha isoform (*PIK3CA*) gene mutations have been identified in 10–20% of colorectal cancer case reports, and these mutations may also occur in non-malignant colorectal lesions, demonstrating that these alterations may be significant events in colorectal carcinogenesis.^{15–17} PI3K pathway activation increases cyclooxygenase-2 (COX2) activity, resulting in the inhibition of apoptosis.^{18–20} PI3K activity is opposed by *PTEN*; because its negative regulation is essential to cellular growth control maintenance.^{21,22}

COX2 is responsible for prostaglandin E2 (PGE2) production, which is involved in colorectal tumorigenesis. Some authors have highlighted the importance of PGE2 as an effector cell signaling pathway activator, including the PI3K/AKT pathways.^{23–27}

Ki67 (mouse monoclonal antibody against a nuclear antigen expressed in human cells during G1, S, G2 and M phases of cell cycle) indicates the fraction of tumor growth, signifying the potential of cellular division that a specific group of cells presents at a certain moment.^{28–30}

This study will evaluate the tissue immunohistochemical expression of biomarkers such as *PTEN*, PI3K, COX2 and Ki67 in benign colorectal polyps, correlating these findings with clinical and pathological data.

Methods

Study group

297 benign colon polyp formalin-fixed paraffin-embedded (FFPE) samples (adenomatous and non-adenomatous) from 229 consecutive patients undergoing colonoscopy at the Hospital Santa Cruz, Curitiba, Brazil (2008), were evaluated. Patients with inflammatory bowel disease, familial adenomatous polyposis and Lynch Syndrome were excluded. Data such as age, sex, location, presence of multiple polyps, history of previous cancer, polyp size and endoscopic appearance were retrieved from the respective endoscopy reports. Fulguration and fragmentation artifacts and inflammatory polyps were excluded from the analysis. This study was approved by the Ethical Committee in Research at Hospital de Clínicas of Universidade Federal do Paraná and have a Certificate of Presentation for Ethical Appreciation number 34605914.3.0000.0096.

Case review and immunohistochemical methods

Microscopic slides stained with hematoxylin–eosin were reviewed, with samples categorized according to current World Health Organization (WHO) histologic classification of tumors of the digestive system³¹ (conventional adenomas and

serrated polyps), and their dysplasia grades (low or high). All samples were then segregated into six histologic groups: (1) high-grade dysplastic conventional adenomas, including tubular and villous (HDA); (2) low-grade dysplastic conventional adenomas, including tubular and villous (LDA); (3) traditional serrated adenomas (TSA); (4) sessile serrated adenomas (SSA); (5) microvesicular hyperplastic polyps (MVHP) and (6) goblet cell rich hyperplastic polyps (GCHP). No mucin poor hyperplastic polyps (MPHP) were found among studied cases.

Tissue microarrays (TMA) that contained 1 sample per case (3 mm diameter) were constructed.³² All TMA slides were stained together with a positive control slide (colon cancer sample) and a negative control slide to which no primary antibody was added.

For immunohistochemistry, the immunoperoxidase assay as reported by some authors³² was used, with modifications. Antigen retrieval was performed using the BioSB[®]™ immunoretriever (Santa Barbara, CA, USA). The samples were incubated with the secondary antibody (DAKO ADVANCE[™]™ HRP (horseradish peroxidase) SYSTEM, DakoCytomation, Inc., CA, USA) for 30 min.³² The antibodies used were rabbit anti-COX2 polyclonal antibody (Spring Bioscience, Pleasanton, CA, USA), 1:200; rabbit anti-human PIK3CA monoclonal antibody (Spring Bioscience, Pleasanton, CA, USA), 1:100; mouse anti-Ki67, Clone MIB-1 (mindbomb E3 ubiquitin protein ligase 1) Dako – Code IR626, Glostrup, Denmark, ready-to-use; and *PTEN* monoclonal antibody (Novocastra Buffalo Grove, IL, USA), 1:200.

The immunostained slides were observed using an optical microscope Olympus[®] BX50 (Tokyo, Japan), coupled to a Dinoeye video camera enhanced by image analysis software Image Pro Plus[™] (Maryland, USA). For each sample, four photomicrographs were taken in HPF (high power field = 400×), with a total area of 115,226.1 μm² and with 1024 × 768 pixels. The positive control HPF photomicrography was chosen as the “mask”, which contained adequate levels of positive tissue immunoeexpression signal. The mask was then superimposed to the samples photomicrographs. Based on the ideal positive tissue immunoeexpression signal obtained from the mask, the image analysis software Image Pro Plus[™] identified the positive areas in the samples and is able to transform these results into positive immunoeexpression area per square micron (μm²). The area in μm² obtained with this method was divided by the constant 115,226.1 μm², which is the total area of the HPF observed, thus generating a percentage value for each HPF. For each polyp, an average percentage of positive area was determined in four HPF images. This method was used for *PTEN*, *PIK3CA* and *COX2* biomarkers.

For Ki67, positive cell numbers were counted for 100 cells per HPF, and the results were reported in %.

The statistical analysis compared the studied biomarkers' immunohistochemical expression with the previous presence of cancer; presence or absence of multiple polyps; location in the right or left colon; sessile or pedunculated endoscopic appearance; polyp diameter size less than 5 mm, between 6 and 10 mm and larger than 10 mm; and the six histological groups. The results were described using Mann–Whitney and Kruskal–Wallis non-parametric tests. A Receiver Operating

Characteristic (ROC) curve was adjusted to evaluate the discrimination power of each variable; *p* (calculated probability) <0.05 values indicated statistical significance. Data were analyzed using the Statistical Package for the Social Sciences (SPSS) v.20.0 computer program.

Results

The clinical and pathological data were grouped in Table 1.

The values for the results of the biomarker tissue immunohistochemical expression compared with clinical-pathological and endoscopic variables are summarized in Table 2.

We can observe that Ki67 exhibited higher values in right colon polyps than in left colon polyps and highest tissue immunoeexpression occurred in high-grade and low-grade dysplastic conventional adenomas.

PI3K exhibited higher values in high-grade dysplastic conventional adenomas. Highest tissue immunoeexpression of COX2 and PTEN were observed in pedunculated polyps and an increasing tissue immunoeexpression of COX2 was observed with greater polyp size.

Concerning the histologic diagnosis of Table 2, the comparison between the results of the types of colonic polyps is seen in Fig. 1, in the Box plots.

A significant *p* value comparing the immunoreactivity of Ki67, PI3K and PTEN between MVHPs with HDA and SSA with HDA was observed.

The expression of COX2 in GCHP was significantly lower than that found in all other examined polyps.

The most significant results obtained by ROC curve analysis of variables are described below.

The evaluation between HDA and LDA, using the cut point of 0.50% of immunopositivity per HPF for PIK3 antibody, found significant difference ($p = 0.013$). The PIK3 was more frequently higher than 0.50% in HDA when comparing with LDA.

For COX2 antibody, the cut point of 7.5%, showed significant difference between the diagnosis of GCHP and LDA ($p = 0.041$). LDA were more frequently higher than 7.5% when compared to GCHP.

About PTEN, there is significant difference ($p = 0.045$) between MVHP and LDA, using the cut point 1.5%. When PTEN was higher than 1.5%, was more probable the LDA diagnosis.

The cut point of 45% for KI67, showed significance for comparing LDA and the three most common serrated polyps (SSA, MVHP and GCHP), all of them with *p* value <0.001. When KI67 was higher than 45%, it was more probably LDA.

Discussion

Ki67 immunoeexpression was present in all polyp histological types. The highest tissue immunoeexpression occurred in HDA and LDA, followed by SSA and hyperplastic polyp (HP).

In this study, Ki67 exhibited higher values in right colon polyps than in left colon polyps. It can be related to the fact that we found more conventional adenomas in the right side (80.6%) than in the left side (69.6%), and this type of polyp got the highest values for Ki67. However, no relevant difference in Ki67 values regarding the colon location was observed in all

conventional adenomas from a study of 47 colorectal polyps in a Middle Eastern population.³³

Furthermore, some authors⁷ have observed higher Ki67 expression in serrated lesions and high-grade dysplastic adenomas.³³⁻³⁵ The highest Ki67 expression in more dysplastic polyps may point to greater proliferating activity, as well as to more cells with self-regulation ability loss.³⁰ Thus, the significance of Ki67 activity may be noteworthy even in the evaluation of the potential progression of benign polyps, possibly indicating a different follow-up for patients with these polyp location.

Moreover, the significance of 45% cut point for Ki67, in our results ($p < 0.001$), suggest that this biomarker can be helpful for pathologists in differential diagnosis between LDA and the three most common serrated polyps (SSA, MVHP and GCHP). When Ki67 was higher than 45% was more probably LDA.

In the case of tissue immunoeexpression of PI3K, an increase was observed in the right colon compared with the left colon, it was not significant ($p = 0.057$) but had a strong statistical trend. To date, no evaluation of PI3K colorectal polyp tissue immunohistochemical expression has been available in the literature. Moreover, it is known that the PIK3CA gene (a gene that promotes PI3K regulation) mutation occurs more often in right-sided colorectal cancer.³⁶ In this study, higher PI3K tissue immunoeexpression in right colon polyps might be related to this gene's higher mutation rates, with consequent alterations in the progression of the polyp's carcinogenesis pathways.

HDA yielded the highest tissue immunoeexpression of PI3K. Some authors who evaluated the presence or absence of the PIK3CA mutation gene in 426 colorectal polyps observed that all 4 mutations occurred in tubular-villous conventional adenomas, findings that may or may not be related to the immunoeexpression of PI3K.³⁷ The positive PI3K labeling findings in benign polyps in this study may have posttranscriptional influences other than the PIK3CA gene mutation because the latter, as presented in the literature, is less frequent in these polyps and more frequent in colorectal cancer. Moreover, the finding of highest immunolabeling in more dysplastic polyps may be related to tumor progression occurring in benign colon polyps.

It is being proposed that MVHP can be a precursor of SSA and share the same carcinogenic via,³⁸ the serrated pathway to colorectal carcinoma with microsatellite instability (MSI), a different pathway from that is proposed for the majority of conventional adenomas, the chromosomal instability pathway.³⁹

The higher and significant values for PI3K for HDA when comparing with MVHP and SSA in Fig. 1 may be related with PI3K and RAS interaction. As PI3K is being consider one of the main effector pathways of RAS,⁴⁰ and mutations in proto-oncogenes such as KRAS lead to conventional adenomatous polyp formation,³⁹ the higher expression of PI3K in HDA, may be related with RAS mutation in HDA.

Besides, in a classification of colorectal cancer in five groups,⁴¹ taking account molecular, clinical and morphological features, KRAS mutation is more related with chromosomal instability pathway and is originated more frequently in conventional adenomas.

In addition to, our results also raise the possibility of the use of PI3K antibody for pathological graduation of conventional

Table 1 – Clinical, endoscopic and anatomopathological data for colorectal polyps.

Total number of polyps (n = 297)	Characteristics	Number of polyps by categoryn (%)
Age of individuals with polyp(s)	Minimum: 19 years Maximum: 91 years Median: 60 years	
Gender	Polyps in men Polyps in women	170 (57.2) 127 (42.7)
Previous cancer history	With no previous cancer With previous cancer	285 (96) 12 (4)
One or multiple	One polyp: Multiple polyps:	106 (35.7) 191 (64.3)
Location	Right side Left side	129 (43.4) 168 (56.6)
Appearance	Pedunculated Sessile	28 (9.4) 269 (90.6)
Size	Polyps >10 mm Polyps 6–10 mm Polyps ≤5 mm	66 (22.2) 31 (6.10.4) 200 (67.3)
Histologic diagnosis	High-grade dysplastic conventional adenoma Sessile serrated adenoma Traditional serrated adenoma Low-grade dysplastic conventional adenoma Microvesicular hyperplastic polyp Globet cell rich hyperplastic polyp	22 (7.4) 26 (8.8) 4 (1.3) 200 (67.3) 25 (8.4) 20 (6.7)

Table 2 – Comparison of immunoexpression and p values between clinical, endoscopic and anatomopathological data.

		PI3K (%)			COX2 (%)			PTEN (%)			Ki67 (%)			
		n	Average	Median	p value	Average	Median	p value	Average	Median	p value	Average	Median	p value
Previous Ca	No	285	1.09	0.42	0.966	8.41	8.84	0.481	2.40	1.88	0.098	43.4	40.0	0.715
	Yes	12	1.03	0.34		7.58	7.81		3.26	2.58		44.2	40.0	
One or multiple	One	106	0.99	0.36	0.640	8.25	8.94	0.936	2.53	2.15	0.567	43.5	40.0	0.862
	Multiple	191	1.14	0.45		8.45	8.80		2.39	1.86		43.4	40.0	
Location	Right	129	1.24	0.53	<u>0.057</u>	8.40	8.84	0.824	2.33	1.98	0.762	47.4	50.0	<u>≤0.0001</u>
	Left	168	0.97	0.35		8.36	8.78		2.52	1.89		40.3	40.0	
Appearance	Sessile	269	1.08	0.38	0.133	8.24	8.77	<u>0.009</u>	2.34	1.84	<u>0.002</u>	43.2	40.0	0.331
	Pedunculated	28	1.18	0.93		9.65	9.63		3.34	3.23		46.7	40.0	
Size	≤5 mm	200	1.04	0.39	0.081	8.12	8.38	<u>0.005</u>	2.33	1.82	0.123	42.6	40.0	0.348
	6–10 mm	31	0.74	0.74		8.25	9.31		2.30	1.89		47.0	40.0	
	>10 mm	66	1.39	0.56		9.25	9.60		2.83	2.27		44.6	40.0	
Histologic diagnosis	HDA	22	2.08	1.12	<u>0.031</u>	9.61	9.43	<u>0.013</u>	3.17	2.80	<u>0.044</u>	48.4	40.0	<u>≤0.001</u>
	LDA	200	1.06	0.38		8.34	8.79		2.50	2.06		47.5	50.0	
	TSA	4	0.86	1.03		9.47	9.64		2.57	3.13		22.5	25.0	
	MVHP	25	0.67	0.22		8.73	9.16		2.11	1.43		31.4	40.0	
	GCHP	20	1.28	0.57		6.42	7.04		2.23	1.87		30.5	30.0	
	SSA	26	0.77	0.43		8.62	8.75		1.82	1.31		34.4	40.0	

Significant p values or values with strong statistical trends are underlined and bold faced.

HAD, high-grade dysplastic conventional adenomas; LDA, low-grade dysplastic conventional adenomas; TSA, traditional serrated adenomas; MVHP, microvesicular hyperplastic polyps; GCHP, globet cell rich hyperplastic polyps; SSA, sessile serrated adenomas.

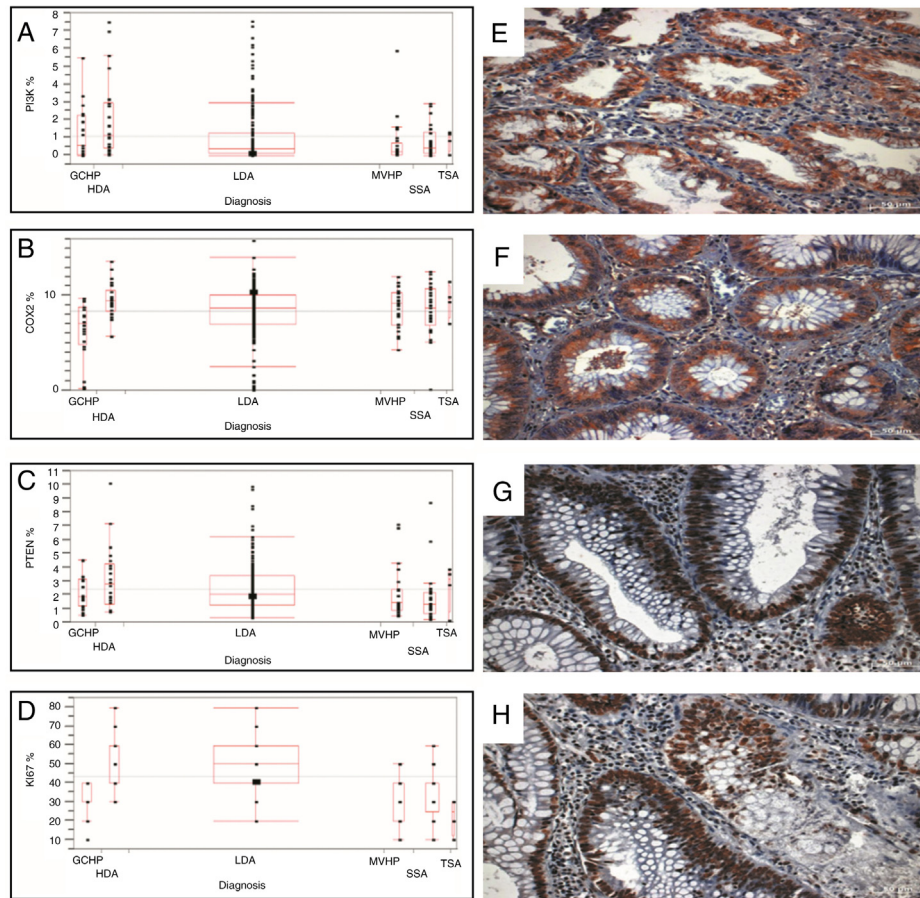


Fig. 1 – Results and some images of immunohistochemical expression of biomarkers. Left column: Box plots representing an average percentage of positive area for PI3K (A), COX2 (B), PTEN (C) and Ki67 (D) biomarkers in HDA, LDA, TSA, MVHP, GCHP and SSA. Significant statistic differences (*p* value) were: for PI3K: HDA vs LDA (0.008), MVHP (0.001), SSA (0.016); for COX2: GCHP vs HDA (<0.001), LDA (0.003), TSA (0.041), MVHP (0.009), SSA (0.011); for PTEN: HDA vs MVHP (0.039), SSA (0.005), LDA vs SSA (0.008) and for Ki67 HDA vs TSA (<0.001), MVHP (<0.001), GCHP (<0.001), SSA (<0.001), LDA vs TSA (0.001), MVHP (<0.001), GCHP (<0.001), SSA (0.003). Right column: Microphotographs of immunohistochemical expression of PI3K (E) in a SSA, COX2 (F) in a LDA, PTEN (G) in a LDA and Ki67 (H) in a LDA. Magnification 200 \times . HAD, high-grade dysplastic conventional adenomas; LDA, low-grade dysplastic conventional adenomas; TSA, traditional serrated adenomas; MVHP, microvesicular hyperplastic polyps; GCHP, globet cell rich hyperplastic polyps; SSA, sessile serrated adenomas; PI3K, phosphatidylinositide-3-kinase; COX2, cyclooxygenase-2; PTEN, phosphatase and tensin homolog; Ki 67, mouse monoclonal antibody against a nuclear antigen expressed in human cells during G1, S, G2 and M phases of cell cycle.

adenomas. By using the cut point of 0.50% we found significance comparing HDA and LDA ($p=0.013$). HDA is more probable when PI3K is higher than 0.50%.

Pedunculated polyps in the study were also observed to be larger in size, which may explain the higher values of COX2 because this protein increases during polyp tumor progression.⁴²

Some authors have already reported these findings concerning COX2, with higher COX2 values presenting as directly proportional to the diameter of the polyps.⁴³ These findings also suggest that COX2 may perform a significant role in colorectal cancer promotion and development through the adenoma-carcinoma pathway. Therefore, the use of COX2 inhibitors, such as aspirin, in colorectal cancer prevention through this

pathway⁴³⁻⁴⁵ would be important. Thus, this finding may help facilitate the development of an effective drug therapy.

A significant higher tissue immunoexpression of COX2 was observed in HDA. Investigators who studied 212 polyps from 175 patients noted that almost 90% of the high-grade dysplastic polyps presented high levels of COX2 labeling, whereas almost 50% of low-grade dysplastic polyps were positive for COX2 and only 24% of polyps with no dysplasia were positive for the same label. Villous histology also presented higher labeling in this series.⁴³

The lower value of COX2 in GCHP comparing to all others polyps was different of the others authors results,⁴⁶ but in their comparison, the HP were not classified in MVHP, GCHP and MPH.

Furthermore, for COX2 the cut point of 7.5% was significant when comparing LDA with GCHP, suggesting its use to help this differentiation. It is more probably LDA when COX2 is >7.5%. These lesions sometimes can be difficult to differentiate by pathologists, mainly when there is a disorientation of the lesion at the cut, or the specimen has artifacts, or the specimen is small.

Regarding PTEN, higher tissue immunoexpression was observed for HDA and TSA, followed by LDA and lower immunoexpression for others serrated lesions (GCHP, MVHP and SSA). The literature supports progressive PTEN expression loss in colorectal carcinogenesis stages with the lowest expression in malignant lesions⁴⁷; however, differences between polyp types were not reported.⁴⁸ The colorectal tumorigenesis process is usually slow, with adenomas appearing usually 10 to 15 years prior to colorectal adenocarcinomas.⁴⁹ How PTEN behaves at critical tumorigenesis stages is unknown. The major findings in this study concerning PTEN immunoexpression in more cytological dysplastic polyps may signify a containment attempt regarding the progression of this lesion tumor type. The lowest expression of PTEN found in this study was in GCHP, MVHP and SSA might be related to an expression suppression of this molecule and consequently, a more rapid carcinogenesis pathway in this type of polyp. Moreover, it may indirectly represent a possible apoptosis loss in these polyps, a finding that has already been described for conventional adenomas.⁴⁷

The main limitations of this study refer to the fact that this is a retrospective study using immunohistochemistry evaluation. Further studies with colon polyps, using molecular biology techniques could help in understanding the carcinogenesis of colon cancer.

Conclusions

The results support the observation that lesions with more severe dysplasia tend to have higher values of Ki67, which appears to coincide with higher values of PTEN, perhaps reflecting an attempt to control the cellular cycle and consequently, tumorigenesis. The higher values in these polyps of PI3K and COX2 data support the hypothesis that both increase while colonic polyp dysplasia increases. In this series of 297 benign colon polyps, Ki67 and PI3K presented higher tissue immunoexpression in the right colon, which may suggest a different carcinogenesis pathway in this colonic segment. Pedunculated polyps presented higher COX2 and PTEN tissue expression, which may be related, in the case of COX2, to tumor progression, and with respect to PTEN, to an attempted containment of the same tumor progression. COX2 presented the highest values in larger polyps and in polyps with higher-grade dysplasia. PI3K presented highest tissue immunoexpression in the most dysplastic polyp histologic type. PTEN presented higher labeling in high-grade dysplastic conventional adenomas, which may signify an attempted containment of tumor progression. Moreover, PTEN presented lower labeling values in sessile serrated adenomas, which may be related to greater apoptosis loss, with more rapid tumor progression in these polyps.

Conflicts of interest

The authors declare no conflicts of interest.

REFERENCES

- Jemal A, Bray F, Ferlay J. Global cancer statistics: 2011. *CA Cancer J Clin.* 2011;61:69–90.
- American Cancer Society: cancer facts and figures. Atlanta, GA: American Cancer Society; 2012. p. 2012.
- Instituto Nacional de Cancer José Alencar Gomes da Silva. INCA – Instituto Nacional de Câncer – Estimativa 2016 [Internet]. Ministério da Saúde Instituto Nacional de Cancer José Alencar Gomes da Silva; 2016. Available from: <http://www.inca.gov.br/estimativa/2014/sintese-de-resultados-comentarios.asp>
- Kohler BA, Ward E, McCarthy BJ, Schymura MJ, Ries LAG, Ehemann C, et al. Annual report to the nation on the status of cancer, 1975–2007, featuring tumors of the brain and other nervous system. *J Natl Cancer Inst.* 2011;103:714–36.
- Fearon ER, Vogelstein B. A genetic model for colorectal tumorigenesis. *Cell.* 1990;61:759–67.
- Hagland HR, Berg M, Jolma IW, Carlsen A, Søreide K. Molecular pathways and cellular metabolism in colorectal cancer. *Digest Surg.* 2013;30:12–25.
- Noffsinger AE. Serrated polyps and colorectal cancer: new pathway to malignancy. *Annu Rev Pathol: Mech Dis.* 2009;4:343–64.
- Morán A. Differential colorectal carcinogenesis: molecular basis and clinical relevance. *World J Gastrointest Oncol.* 2010;2:151.
- Rosty C, Hewett DG, Brown IS, Leggett BA, Whitehall VLJ. Serrated polyps of the large intestine: current understanding of diagnosis, pathogenesis, and clinical management. *J Gastroenterol.* 2013;48:287–302.
- O'Brien MJ, Yang S, Huang CS, Shepherd C, Cerda S, Farraye FA. The serrated polyp pathway to colorectal carcinoma. *Diagn Histopathol.* 2008;14:78–93.
- Fodde R. The APC gene in colorectal cancer. *Eur J Cancer.* 2002;38:867–71.
- Kawasaki T, Nosho K, Ohnishi M, Suemoto Y, Glickman JN, Chan AT, et al. Cyclooxygenase-2 overexpression is common in serrated and non-serrated colorectal adenoma, but uncommon in hyperplastic polyp and sessile serrated polyp/adenoma. *BMC Cancer BioMed Central.* 2008;8:33.
- Salmena L, Carracedo A, Pandolfi PP. Tenets of PTEN tumor suppression. *Cell.* 2008;133:403–14.
- Stokoe D. PTEN. *Curr Biol.* 2001;11:R502.
- Velho S, Moutinho C, Cirmes L, Albuquerque C, Hamelin R, Schmitt F, et al. BRAF, KRAS and PIK3CA mutations in colorectal serrated polyps and cancer: primary or secondary genetic events in colorectal carcinogenesis? *BMC Cancer.* 2008;8:255.
- Samuels Y. High frequency of mutations of the PIK3CA gene in human cancers. *Science.* 2004;304:554.
- Nosho K, Kawasaki T, Longtine JA, Fuchs CS, Ohnishi M, Suemoto Y, et al. PIK3CA mutation in colorectal cancer: relationship with genetic and epigenetic alterations. *Neoplasia.* 2008;10:534–41.
- Kaur J, Sanyal SN. PI3-kinase/Wnt association mediates COX-2/PGE2 pathway to inhibit apoptosis in early stages of colon carcinogenesis: chemoprevention by diclofenac. *Tumor Biol.* 2010;31:623–31.

19. Uddin S, Ahmed M, Hussain A, Assad L, Al-Dayel F, Bavi P, et al. Cyclooxygenase-2 inhibition inhibits PI3K/AKT kinase activity in epithelial ovarian cancer. *Int J Cancer*. 2010;126:382-94.
20. Liao X, Lochhead P, Nishihara R, Morikawa T, Kuchiba A, Yamauchi M, et al. Aspirin use, tumor PIK3CA mutation, and colorectal-cancer survival. *N Engl J Med*. 2012;367:1596-606.
21. Dillon RL, White DE, Muller WJ. The phosphatidylinositol 3-kinase signaling network: implications for human breast cancer. *Oncogene*. 2007;26:1338-45.
22. Saal LH, Johansson P, Holm K, Gruberger-Saal SK, She Q-B, Maurer M, et al. Poor prognosis in carcinoma is associated with a gene expression signature of aberrant PTEN tumor suppressor pathway activity. *Proc Natl Acad Sci U S A*. 2007;104:7564-9.
23. Sinicrope FA, Gill S. Role of cyclooxygenase-2 in colorectal cancer. *Cancer Metastasis Rev*. 2004;23:63-75.
24. Hanahan D, Weinberg RA. The hallmarks of cancer. *Cell*. 2000;100:57-70.
25. Greenhough A, Smartt HJM, Moore AE, Roberts HR, Williams AC, Paraskeva C, et al. The COX-2/PGE2 pathway: key roles in the hallmarks of cancer and adaptation to the tumour microenvironment. *Carcinogenesis*. 2009;30:377-86.
26. Sheng H, Shao J, Washington MK, DuBois RN. Prostaglandin E2 increases growth and motility of colorectal carcinoma cells. *J Biol Chem*. 2001;276:18075-81.
27. Tessner TG, Muhale F, Riehl TE, Anant S, Stenson WF. Prostaglandin E2 reduces radiation-induced epithelial apoptosis through a mechanism involving AKT activation and bax translocation. *J Clin Invest*. 2004;114:1676-85.
28. Gerdes J, Schwab U, Lemke H, Stein H. Production of a mouse monoclonal antibody reactive with a human nuclear antigen associated with cell proliferation. *Int J Cancer*. 1983;31:13-20.
29. Brown DC, Gatter KC. Ki67 protein: the immaculate deception? *Histopathology*. 2002;40:2-11.
30. Scholzen T, Gerdes J. The Ki-67 protein: from the known and the unknown. *J Cell Physiol*. 2000;182:311-22.
31. Snover DC, Ahnen DJ, Burt RW, Odze RD. Serrated polyps of the colon and rectum and serrated ("hyperplastic") poliposis. In: Bosman FT, Carneiro F, Hruban RH, Theise N, editors. *WHO classification of tumours of the digestive system*. 4th ed Berlin: Springer-Verlag; 2010. p. 160-5.
32. Debur MC, Raboni SM, Flizikowski FB, Chong DC, Persicote AP, Nogueira MB, et al. Immunohistochemical assessment of respiratory viruses in necropsy samples from lethal non-pandemic seasonal respiratory infections. *J Clin Pathol*. 2010;63:930-4.
33. Nussrat FL, Ali HH, Hussein HG, Al-Ukashi RJ. Immunohistochemical expression of ki-67 and p53 in colorectal adenomas: a clinicopathological study. *Oman Med J*. 2011;26:229-34.
34. Fujimori Y, Fujimori T, Imura J, Sugai T, Yao T, Wada R, et al. An assessment of the diagnostic criteria for sessile serrated adenoma/polyps: SSA/Ps using image processing software analysis for Ki67 immunohistochemistry. *Diagn Pathol*. 2012;7:59.
35. Radovanovic-Dinic B, Nagorni A, Katic V, Stamenkovic I, Zlatic A. An immunohistochemical study of Ki-67 in colorectal adenoma. *Medicinski Arhiv*. 2009;63:16-8.
36. Brulé SY, Jonker DJ, Karapetis CS, O'Callaghan CJ, Moore MJ, Wong R, et al. Location of colon cancer (right-sided versus left-sided) as a prognostic factor and a predictor of benefit from cetuximab in NCIC CO.17. *Eur J Cancer*. 2015;51:1405-14.
37. Whitehall VLJ, Rickman C, Bond CE, Ramsnes I, Greco SA, Umapathy A, et al. Oncogenic PIK3CA mutations in colorectal cancers and polyps. *Int J Cancer*. 2012;131:813-20.
38. Crockett SD, Snover DC, Ahnen DJ, Baron JA. Sessile serrated adenomas: an evidence-based guide to management. *Clin Gastroenterol Hepatol [Internet]*. 2015;13:11-26. Elsevier.
39. Fearon EF, Vogelstein B. A genetic model for colorectal tumorigenesis. *Cell*. 1990;61:759-67.
40. Castellano E, Downward J. RAS interaction with PI3K: more than just another effector pathway. *Genes Cancer*. 2011;2:261-74.
41. Jass JR. Classification of colorectal cancer based on correlation of clinical, morphological and molecular features. *Histopathology*. 2007;50:113-30.
42. Hasegawa K, Ichikawa W, Fujita T, Ohno R, Okusa T, Yoshinaga K, et al. Expression of cyclooxygenase-2 (COX-2) mRNA in human colorectal adenomas. *Eur J Cancer*. 2001;37:1469-74.
43. Wasilewicz MP, Kołodziej B, Bojułko T, Kaczmarczyk M, Sulzyc-Bielicka V, Bielicki D. Expression of cyclooxygenase-2 in colonic polyps. *Pol Arch Med Wewn*. 2010;120:20-31.
44. Balbinotti RA, Ribeiro U, Sakai P, Safatle-Ribeiro AV, Balbinotti SS, Scapulatempo C, et al. hMLH1, hMSH2 and cyclooxygenase-2 (Cox-2) in sporadic colorectal polyps. *Anticancer Res*. 2007;27:4465-71.
45. Chan AT, Ogino S, Fuchs CS. Aspirin and the risk of colorectal cancer in relation to the expression of COX-2. *N Engl J Med*. 2007;356:2131-42.
46. Szyłberg Ł, Janiczek M, Popiel A, Marszałek A. Expression of COX-2, IL-1β, TNF-α and IL-4 in epithelium of serrated adenoma, adenoma and hyperplastic polyp. *Arch Med Sci*. 2016;1:172-8. Termedia Publishing.
47. Waniczek D, Śnietura M, Młynarczyk-Liszka J, Pięłowski W, Kopeć A, Lange D, et al. PTEN expression profiles in colorectal adenocarcinoma and its precancerous lesions. *Polish J Pathol*. 2013;64:15-20.
48. Waniczek D, Śnietura M, Pięłowski W, Rdes J, Kopeć A, Młynarczyk-Liszka J, et al. Analysis of PTEN expression in large intestine polyps and its relation to the recognized histopathological and clinical risk factors for cancer development in this location. *Współczesna Onkologia*. 2012;4:310-5.
49. Chan AT, Giovannucci EL. Primary prevention of colorectal cancer. *Gastroenterology*. 2010;138:2029-43.