



Original Article

Influence of the cotton and silastic seton on the distance of the anal sphincter cables after fistulotomy in rats

Ana Laura Sanches Lima^a, Beatriz Schorro Gianini^a, Bruna Miranda Santana^a, Carlos Henrique Marques dos Santos^{id a,b,*}, Doroty Mesquita Dourado^a, Juliano Seger Falcão^a, Lucas Bannwart^a, Sara Jéssica Falcão Câmara^a

^a Universidade Anhanguera (Uniderp), Campo Grande, MS, Brazil

^b Universidade Federal de Mato Grosso do Sul, Hospital Universitário Maria Aparecida Pedrossian, Campo Grande, MS, Brazil

ARTICLE INFO

Article history:

Received 5 July 2019

Accepted 15 September 2019

Available online 19 October 2019

Keywords:

Rectal fistula

Cotton

Silastic

Fistulotomy

Fecal incontinence

ABSTRACT

Rationale: Fistulotomy is a procedure widely used in the treatment of anal fistulas but is associated with varying degrees of fecal incontinence that could be minimized by previous use of sedentum, and the material used may influence the outcome.

Purpose: To compare cotton and silastic used as setons in the spacing of the sphincter cables of rats subjected to fistulotomy.

Method: Thirty Wistar rats were used, which after 30 days of fistula production were distributed in: Control Group (GC): the steel wire was removed, followed by fistulotomy; Cotton Group (GA) and Silastic Group (GS), in which were applied cotton and silastic setons respectively for 30 days when fistulotomy was performed; after seven days, euthanasia and removal of the specimens were performed for histological study, and the results were submitted to statistical assessment using Kruskal–Wallis non-parametric test, establishing a significance level of $p < 0.05$.

Results: The distance between the muscular cables was $107.9 \mu\text{m}$ in the GC, $82.4 \mu\text{m}$ in the GA and $53.5 \mu\text{m}$ in the GS ($p = 0.00001$). The mean inflammation scores were 1.9 in the CG, 1.0 in the GA and 0 in the GS ($p < 0.05$). The fibrosis scores were 1.1 in GC, 0.9 in GA and 0.6 in GS ($p > 0.05$).

Conclusion: The silastic seton prior to fistulotomy caused less detachment of the muscular cables and less local inflammatory process.

© 2019 Sociedade Brasileira de Coloproctologia. Published by Elsevier Editora Ltda. This is an open access article under the CC BY-NC-ND license (<http://creativecommons.org/licenses/by-nc-nd/4.0/>).

* Corresponding author.

E-mail: carlos.marques@anhanguera.com (C.H. Santos).
<https://doi.org/10.1016/j.jcol.2019.09.002>

2237-9363/© 2019 Sociedade Brasileira de Coloproctologia. Published by Elsevier Editora Ltda. This is an open access article under the CC BY-NC-ND license (<http://creativecommons.org/licenses/by-nc-nd/4.0/>).

Influência do sedenho de algodão e silastic no afastamento dos cabos musculares do esfíncter anal após fistulotomia em ratos

R E S U M O

Palavras-chave:

Fistula retal
Fio de algodão
Silastic
Fistulotomia
Incontinência fecal

Racional: A fistulotomia é um procedimento muito utilizado no tratamento das fístulas anais mas está associado a graus variáveis de incontinência fecal que poderia ser minimizado pelo uso prévio de sedenho, sendo que o material utilizado pode ter influência no resultado.

Objetivo: Comparar os fios de algodão e sonda de silastic utilizados como sedenhos no afastamento dos cabos musculares do esfíncter anal de ratos submetidos a fistulotomia.

Método: Utilizou-se 30 ratos Wistar, que após 30 dias da confecção da fistula foram distribuídos em: Grupo Controle (GC): foi retirado o fio de aço seguido por fistulotomia; Grupo Algodão (GA) e Grupo Silastic (GS), nos quais aplicou-se sedenho de algodão e silastic respectivamente por 30 dias quando foi realizada fistulotomia; após sete dias realizou-se eutanásia e remoção dos espécimes para estudo histológico, sendo os resultados submetidos a tratamento estatístico pelo teste não-paramétrico de Kruskal-Wallis, estabelecendo-se como significante $p < 0,05$.

Resultados: O afastamento entre os cabos musculares foi 107,9 μm no GC; 82,4 μm no GA e 53,5 μm no GS ($p = 0,00001$). As médias dos escores de inflamação foram 1,9 no GC; 1,0 no GA e 0 no GS ($p < 0,05$). Os escores de fibrose foram 1,1 no GC; 0,9 no GA e 0,6 no GS ($p > 0,05$).

Conclusão: O sedenho de silastic previamente à fistulotomia causou menor afastamento dos cabos musculares e menor processo inflamatório local.

© 2019 Sociedade Brasileira de Coloproctologia. Publicado por Elsevier Editora Ltda. Este é um artigo Open Access sob uma licença CC BY-NC-ND (<http://creativecommons.org/licenses/by-nc-nd/4.0/>).

Introduction

Fistulotomy is the most widely used technique for anal fistula treatment, considering that it is applicable to low intersphincteric and transsphincteric anal fistulas, achieving relapse-free healing in up to 90% of cases.^{1,2} In addition to providing good healing results, the postoperative period is relatively uncomplicated, with mild pain and healing within 30 days in most cases. The major problem with the technique, however, is the variable number of cases of fecal incontinence, with reported rates ranging from 0% to 35% in cases of superficial fistulas.^{3,4}

It is known that the use of seton is a common step to many of the techniques used in the treatment of fistulas, and may be the only stage of surgical treatment, as in the case of fistulas in Crohn's disease patients, in whom conventional surgery is hardly used, and seton would be an adjunct for preventing abscesses until biological therapy achieves the expected result, in which case the smooth and flexible seton would be the preferable. It can also be used as a bridge for a definitive treatment, as in the LIFT technique, in which case the seton would induce fibrosis and further tract definition, so that after a few weeks the tract ligation could be performed.⁵

Another situation where setons are commonly used is in complex fistulas in order to induce fibrosis and subsequently be able to perform sphincter sectioning without impairing sphincter function.^{4,5} However, this advantage in using seton is an assumption, as there is no strong scientific basis for it.⁶ In addition, if there is really a positive effect with a prior application of seton, it would still remain to know which material could offer the best result.

Based on the situations presented here, it was proposed for the present study to assess whether there is an advantage in using seton prior to sphincter section and also investigate whether there is a difference between the two materials commonly used in this situation.

Objective

To evaluate the degree of inflammation, fibrosis, and distance of muscle cables in rats undergoing fistulotomy with and without previous use of seton by comparing the difference between cotton and silastic in animals previously treated with seton.

Method

The study design was approved by the Ethics Committee for Animal Experimentation of Anhanguera University – Uniderp.

We evaluated 30 adult male Wistar albino rats, about 300 g each, from the vivarium of the Universidade para o Desenvolvimento do Estado e da Região do Pantanal, where the experiment was conducted, following all ethical standards established by the Brazilian College of Animal Experimentation – COBEA.

Rats were anesthetized for anal fistulae with intraperitoneal administration of ketamine and xylazine in the same syringe, with the solution containing 2 mL of 10% ketamine and 1 mL of 2% xylazine. For each 100 g of body weight, 0.1 mL of anesthetic solution was infused.

After anesthesia, the anal sphincter was transected with a #1 steel wire, introduced into the pectineal line and

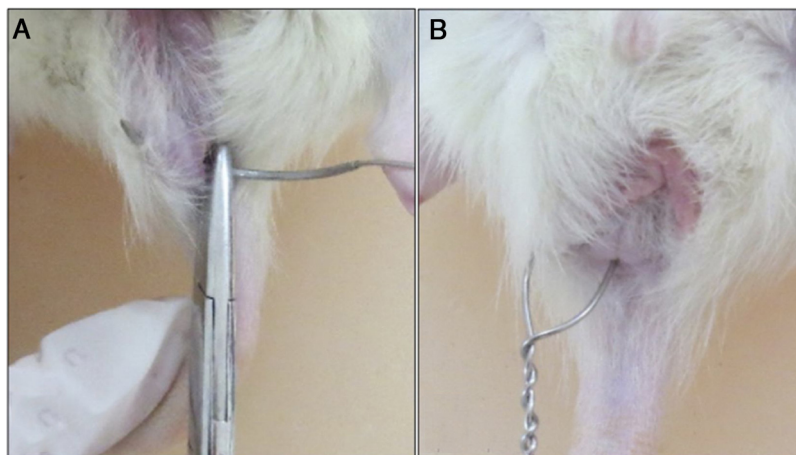


Fig. 1 – A, Transection of the anal sphincter with steel wire; B, steel wire positioned for fistula creation.

exteriorized 1 cm laterally to the right anal margin (Fig. 1A). The wire was cut, twisted and held in place for 30 days (Fig. 1B).

After 30 days, the rats were divided into three groups:

CG – Control Group: consisting of 10 rats, in which the steel wire was removed and immediately followed by fistulotomy;

GA – Cotton Group: consisting of 10 rats, in which the steel wire was removed followed by placement of cotton seton, which remained for 30 days and, after this period, fistulotomy was performed;

GS – Silastic Group: consisting of 10 rats, in which the steel wire was removed followed by placement of silastic seton, which remained for 30 days and, after this period, fistulotomy was performed.

After fistulotomy, all animals underwent sterile gauze compression for 10 min for hemostasis. Seven days after fistulotomy, a new intraperitoneal anesthesia was performed, euthanasia by deepening the anesthetic plane, and resection of a tissue cube of about 2×2 cm surrounding the anal canal and the entire area containing the fistulous tract up to the skin. Specimens were identified and fixed in 10% buffered formalin. Subsequently, the material was processed in increasing concentrations of alcohol, diaphanized in xylol, and embedded in histological paraffin. Cross sections of $5 \mu\text{m}$ thickness were made with the aid of a rotating microtome (Microm, HM320). The obtained sections were stained using the Hematoxylin-Eosin (HE) technique for qualitative histopathological analysis. Digital imaging of HE and TG stained slides was performed using a Carl Zeiss photo microscope attached to a Samsung micro-camera connected to a computer with an image capture card. The professional who read and interpreted the findings was blind to each animal's group designation.

Histological analysis was performed considering the following aspects: inflammatory infiltrate; fibrosis; area between the muscle cables.

For inflammatory infiltrate determination, a score system was used to verify the local inflammatory process and its intensity, which was classified as: (0) absence of inflammatory infiltrate; (1) mild inflammatory infiltrate; (2) moderate inflammatory infiltrate; and (3) intense inflammatory infiltrate.

Table 1 – Evaluation of the area between muscle stumps after fistulotomy in the studied animals.

Rats	Groups		
	GC	GA	GS
1	105	96	68
2	106	81	62
3	116	88	54
4	110	95	45
5	104	69	41
6	110	70	56
7	106	90	48
8	105	82	49
9	109	75	53
10	108	78	59
Mean	107.9	82.4	53.5 ^a

^a $p = 0.00001$.

The degree of fibrosis was assessed using optical microscopy and applying the following score: (0) absent; (1) mild; (2) moderate; and (3) intense.

To assess the area between the muscle cables, a coronal plane slide analysis of the removed sample was performed by demarcating the ends of the sphincter cables, measuring the pixels area, and converting to square micrometers (μm^2) using the Bioestat software.

Data analysis and comparison between experimental groups was performed using the non-parametric Kruskal-Wallis test considering a significance level of 5%.

Results

The mean distance between the muscle cables after fistulotomy was $107.9 \mu\text{m}$ in Control Group, $82.4 \mu\text{m}$ in Cotton Group, and $53.5 \mu\text{m}$ in Silastic Group ($p = 0.00001$) (Table 1).

The mean fibrosis in segments where fistulotomy was performed was 1.1 in Control Group, 0.9 in Cotton Group, and 0.6 in Silastic Group ($p > 0.05$) (Table 2).

The mean inflammatory infiltrate score was 1.9 in CG, 1.0 in GA, and 0 in GS ($p < 0.05$) (Table 3).

Table 2 – Evaluation of the degree of fibrosis in the segment where fistulotomy was performed in the animals studied.

Rats	Groups		
	GC	GA	GS
1	0	1	0
2	1	1	1
3	0	0	0
4	2	2	1
5	1	1	0
6	1	2	1
7	2	1	1
8	1	0	0
9	2	1	1
10	1	0	1
Mean	1.1	0.9	0.6

Table 3 – Evaluation of the degree of inflammatory infiltrate around the fistulous tract in the studied animals.

Rats	Groups		
	GC	GA	GS
1	2	1	0
2	1	0	0
3	2	1	0
4	1	2	0
5	3	1	0
6	2	2	0
7	3	1	0
8	2	0	0
9	1	1	0
10	2	1	0
Mean	1.9	1.0	0

p < 0.05.

Discussion

Although the use of seton has been extremely frequent in the treatment of complex anal fistulas for many years, the seton material has not been comprehensively studied in order to verify its influence on the result of the technique. Subhas et al.⁷ have probably published the largest literature review assessing the different materials used as setons for fistula-in-ano repair, noting that there is no direct comparison between such products, so it is currently unknown whether or not there is a difference in their effectiveness.

In proctology practice, it is observed that many professionals have personal preferences regarding the material to be used as a seton, arguing in favor of siliconized or rubber products because they are potentially more comfortable to patients, besides producing less secretion as they are free of porosity.⁸ These potential characteristics, however, have no clear scientific backing and are based solely on surgeons' personal experience and some case reports.⁹ This fact makes the importance of conducting the present study relevant, but, on the other hand, it does not allow us to compare the results found here.

Galvao et al.⁸ evaluated the inflammatory process caused by different materials used as setons and found that cotton led to more severe inflammation, which would be somewhat expected as it is a multifilament material, while latex and silastic caused less inflammation due to its smooth surface. In the present study, the same was true, although applying a method very similar to that of Galvão et al.,⁸ which demonstrates that silastic actually has advantages when one intends to avoid an intense inflammatory process and, mainly, to avoid fecal incontinence secondary to the withdrawal of muscle cables.

Some authors have reported experience with the use of rubber seton (Penrose drain) with satisfactory results. In fulfilling its role as a seton with similar efficacy to other materials, it should be noted the great advantage of this product as it is low cost and available in most fistula treatment centers, particularly in developing countries, a very relevant factor that should be taken into consideration when choosing the material. Moreover, rubber is an inert material, very flexible, and non-porous, theoretically causing less production of purulent secretion while the seton is in place.^{8,10}

The different characteristics of materials with consequent different results are useful information at the time of application, since when applying a seton to an anal fistula the objectives may be different depending on the patient. In the treatment of complex Crohn's disease fistulas, where the goal of seton is to keep the tract open, avoiding abscess formation while awaiting for the action of biological agents,¹¹ the material that best serves this purpose would be silastic or latex. When applying seton as the first stage of surgical treatment in order to cause fibrosis and better delimit the fistulous tract, as in the LIFT and mucosal flap advancement, cotton would be the material that would better meet these requirements. When using a tight or loose seton while waiting for its elimination,¹¹⁻¹⁴ causing a slow section of the sphincters, the inert materials would most likely be more suitable because they caused less discomfort to patients.

The present study demonstrated that in the evaluation of the muscle cable removal after fistulotomy, the animals treated with silastic seton had better results, since the distance between the muscle cables was smaller than in the other groups. It can be inferred that there would be less possibility of fecal incontinence, since there was less change in local anatomy, but this observation needs a manometric evaluation. In this sense, silastic seems to be the most suitable material when performing fistulotomy, especially in cases where the seton is left for long periods and, when it seems to be superficial, the sphincter section is chosen.

In the present study, there was no statistically significant difference between groups regarding local fibrosis, which may seem counterintuitive, since fibrosis is a consequence of inflammation, and it occurred at different intensities between groups; that is, more fibrosis would be expected in the groups that presented more inflammation and it should be less intense in the silastic group who had no inflammation. However, it was understood here that as all animals underwent the same process of fistula creation (steel wire in place for 30 days), it is likely that during this period there was an initial inflammation and the formation of fibrosis that delimits the fistulous

tract. It should be remembered that rats have faster stages of inflammation and healing than humans.¹⁵ Thus, when the cotton and silastic setons were placed, a new stage was started, with a consequent difference between groups showing that cotton seton causes inflammation while the silastic seton in the model used remained inert. In the Control Group, on the other hand, the inflammation would be explained by the sphincter section, great distance of the muscle cables, and consequently greater inflammatory activity.

Several other aspects are reported in the publication by Subhas et al.,⁷ such as placement technique, curettage technique, seton fixation method, sphincter tension etc., which certainly may also influence treatment results; therefore, there is a very large field of research on this subject. The present study provided important information regarding the action of cotton setons prior to fistulotomy, demonstrating that silastic seton allowed for less distance of the muscle cables. It remains to be known, and it is the main limitation of this study, whether this apparent benefit could in fact enable better postoperative sphincter control.

Conclusion

The silastic seton prior to fistulotomy caused less detachment of the muscular cables and less local inflammatory process.

Conflicts of interest

The authors declare no conflicts of interest.

REFERENCES

- Garg P. Comparing existing classifications of fistula-in-ano in 440 operated patients: is it time for a new classification? A retrospective cohort study. *Int J Surg*. 2017;42:34-40.
- Murtaza G, Shaikh FA, Chawla T, Rajput BU, Shahzad N, Ansari S. Fistulotomy versus fistulectomy for simple fistula in ano: a retrospective cohort study. *J Pak Med Assoc*. 2017;67:339-42.
- Awad RA, Camacho S, Flores F, Altamirano E, García MA. Rectal tone and compliance affected in patients with fecal incontinence after fistulotomy. *World J Gastroenterol*. 2015;21:4000-5.
- Cavanaugh M, Hyman N, Osler T. Fecal incontinence severity index after fistulotomy: a predictor of quality of life. *Dis Colon Rectum*. 2002;45:349-53.
- Shirah BH, Shirah HA. The impact of the outcome of treating a high anal fistula by using a cutting seton and staged fistulotomy on Saudi Arabian patients. *Ann Coloproctol*. 2018;34:234-40.
- Rosen DR, Kaiser AM. Definitive seton management for transsphincteric fistula-in-ano: harm or charm? *Colorectal Dis*. 2016;18:488-95.
- Subhas G, Singh Bhullar J, Al-Omari A, Unawane A, Mittal VK, Pearlman R. Setons in the treatment of anal fistula: review of variations in materials and techniques. *Dig Surg*. 2012;29:292-300.
- Galvão MO, Santos CHM, Falcão GR. Evaluation of the inflammatory response induced by different materials in the treatment of perianal fistulas: experimental study in rats. *J Coloproctol*. 2016;36:16-20.
- Steele SR, Kumar R, Feingold DL, Rafferty JL, Buie WD. Practice parameters for the management of perianal abscess and fistula-in-ano. *Dis Colon Rectum*. 2011;54:1465-74.
- Lim CH, Shin HK, Kang WH, Park CH, Hong SM, Jeong SK, et al. The use of a staged drainage seton for the treatment of anal fistulae or fistulous abscesses. *J Korean Soc Coloproctol*. 2012;28:309-14.
- Causey MW, Nelson D, Johnson EK, Maykel J, Davis B, Rivadeneira DE, et al. An NSQIP evaluation of practice patterns and outcomes following surgery for anorectal abscess and fistula in patients with and without Crohn's disease. *Gastroenterol Rep*. 2013;1:58-63.
- Dalbem CS, Tomiyoshi SDT, Santos CHM. Assessment of LIFT (ligation of the intersphincteric fistula tract) technique in patients with perianal transsphincteric fistulas. *J Coloproctol*. 2014;34:250-3.
- Hong KD, Kang S, Kalaskar S, Wexner SD. Ligation of intersphincteric fistula tract (LIFT) to treat anal fistula: systematic review and meta-analysis. *Tech Coloproctol*. 2014;18:685-91.
- Vial M, Parés D, Pera M, Grande L. Faecal incontinence after seton treatment for anal fistulae with and without surgical division of internal anal sphincter: a systematic review. *Colorectal Dis*. 2010;12:172-8.
- Antonini JM, Roberts JR, Schwegler-Berry D, Mercer RR. Comparative microscopic study of human and rat lungs after overexposure to welding fume. *Ann Occup Hyg*. 2013;57:1167-79.