



Case Report

Primary extraperitoneal rectum lymphoma in AIDS patient



Ana Maria Stapasolla Vargas Garcia ^{a,*}, Marlei Sangali^a,
Antoninho Jose Tonatto Filho^a, Caroline Lara^b, Cibele Corbellini Rosa da Silva^b,
Marcos Paulo Barreto Saturnino^b, Luciano Pinto de Carvalho^b

^a Hospital Nossa Senhora da Conceição, Serviço de Cirurgia Geral, Porto Alegre, RS, Brazil

^b Hospital Nossa Senhora da Conceição, Serviço de Coloproctologia, Porto Alegre, RS, Brazil

ARTICLE INFO

Article history:

Received 20 September 2019

Accepted 18 November 2019

Available online 9 December 2019

Keywords:

Lymphoma

Rectum

Gastrointestinal lymphoma

Colonic lymphoma

ABSTRACT

Introduction: The gastrointestinal lymphoma can be classified in primary or secondary, and this is important regarding diagnosis and subsequent treatment. Primary gastrointestinal lymphoma of the rectum is rare and therefore lacks data in medical literature. Its incidence has been increasing and that fact may be related to a higher incidence in immunosuppressive therapy and immunosuppressive diseases (such as AIDS).

Methodology: 19 articles have been reviewed, searched online on the Scielo and PubMed databases. The goal was to increase data available regarding this pathology and improve its therapy.

Discussion: Primary GI lymphoma of the rectum presents as hematochezia, rectal pain, change in bowel habits. PET/CT is the first choice exam to pursue investigation; however abdominal CT and MRI reveal sufficient information and are much more available in daily practice. Plasmablastic lymphoma is an aggressive subtype and is usually associated with AIDS patients. There are no available treatment protocols for this specific type of lymphoma and colonic lymphoma's therapy is usually used for this patient (such as ECHOP and CHOP). **Conclusion:** As rare as this pathology is, this article aims to improve the available data and provide useful information regarding diagnosis and therapy.

© 2019 Sociedade Brasileira de Coloproctologia. Published by Elsevier Editora Ltda. This is an open access article under the CC BY-NC-ND license (<http://creativecommons.org/licenses/by-nc-nd/4.0/>).

* Corresponding author.

E-mail: ana.svgarcia@gmail.com (A.M. Garcia).

<https://doi.org/10.1016/j.jcol.2019.11.488>

2237-9363/© 2019 Sociedade Brasileira de Coloproctologia. Published by Elsevier Editora Ltda. This is an open access article under the CC BY-NC-ND license (<http://creativecommons.org/licenses/by-nc-nd/4.0/>).

Linfoma primário de reto extraperitoneal em paciente SIDA

R E S U M O

Palavras-chave:

Linfoma
Reto
Linfoma gastrointestinal
Linfoma colón

Introdução: O linfoma do TGI pode ser dividido entre primário e secundário, com importância diagnóstica e terapêutica. O linfoma primário de reto é patologia rara, pouco relatada em literatura médica. Sua incidência tem aumentado e possivelmente esse fenômeno esteja associado ao aumento no número de pacientes com imunossupressão (seja por SIDA ou drogas imunossupressoras).

Metodologia: Foram revisados 19 artigos nas bases de dados Scielo e PubMed, com o objetivo de aumentar o número de relatos dessa patologia e consequentemente expandir o conhecimento disponível, visando melhorar a terapêutica e, principalmente, o diagnóstico desse tipo de linfoma.

Discussão: Quando o linfoma tem seu sítio primário no reto, as principais manifestações são sangramento, dor retal, tenesmo e mudança nos hábitos intestinais (diarreia ou constipação). O exame de investigação de escolha é o PET/CT, porém a TC e RNM fornecem as informações necessárias e são mais disponíveis na prática clínica. O linfoma plasmoblástico é um subtipo bastante agressivo e associado aos pacientes com SIDA. Não existem ainda protocolos definidos para o tratamento do linfoma primário de reto, sendo optado por seguir a mesma terapêutica dos linfomas de cólon com esquemas EPOCH e CHOP.

Conclusão: Por se tratar de patologia rara e pouco descrita na literatura, espera-se que este relato contribua na formação de protocolos de tratamento específicos.

© 2019 Sociedade Brasileira de Coloproctologia. Publicado por Elsevier Editora Ltda. Este é um artigo Open Access sob uma licença CC BY-NC-ND (<http://creativecommons.org/licenses/by-nc-nd/4.0/>).

Introduction

Primary gastrointestinal lymphoma is a rare condition, defined as lymphomas involving the Gastrointestinal Tract (GIT) or presenting with gastrointestinal symptoms. The lymphoma with secondary involvement of TGI is more commonly found.^{1,2} This differentiation guides the treatment.

Primary colonic lymphoma is rare and accounts for only 0.2 %–0.4 % of all colon cancers, 10 %–5 % of all primary gastrointestinal lymphomas and about 30 % of extra-nodal lymphomas.^{3,4} The most commonly affected sites are the stomach, followed by the small intestine and ileocecal transition.⁵

The most common colonic location is the caecum (70 %), followed by the rectum and ascending colon.⁶

Intestinal lymphomas can be classified into B-cell lymphomas (85 %) and T-cell lymphomas (15 %). Among B-cell lymphomas, mantle cell lymphoma has a worse prognosis, whereas Mucosa-Associated Lymphoid Tissue (MALT) lymphomas have a better prognosis than other B-cell tumors.⁶

Studies suggest that the incidence of primary gastrointestinal lymphoma has increased,⁷ which may be explained by the presence of immunosuppression, either due to mediated Acquired Immunodeficiency Syndrome (AIDS), by an increase in the prescription of immunosuppressive drugs used after transplantation or associated with treatments for autoimmune diseases.^{7,8} Drugs related to increased incidence of lymphomas include thiopurines (azathioprine and 6-mercaptopurine),^{9,10} and, to a lesser extent, the anti-Tumor Necrosis Factor (anti-TNF) therapy.¹¹

Methodology and objectives

Totally, 19 articles retrieved from the Scielo and PubMed databases were reviewed in order to increase the number of reports regarding this pathology and consequently expand the available knowledge, aiming at improving the therapy and, particularly, the diagnosis of this type of lymphoma.

Case report

Male patient, 19-year-old, treated at the HNSC emergency department, with a history of anal bleeding (bright red blood) for a year, associated with pain and anal tumor for a month, who had undergone at least two attempts to drain the lesion. Prior to hospitalization, he had hypothyroidism, clinically treated with hormone replacement, in addition to depression and irregular psychiatric treatment. Anal inspection revealed right posterolateral perianal lesion, about 6 cm in diameter, hardened, without drainage of secretion, but with incisions in the central portion. The overlying skin had hemorrhagic suffusion (Figs. 1 and 2). Rectal examination revealed a hypotonic sphincter in a 3 cm anal canal with apparent hardened lesion in the right posterior and lateral anal canal, adjacent to the described perianal tumor lesion. No blood or pus. Mild anemia was evidenced during the initial examination. A pelvic MRI scan (Fig. 3) demonstrated a 11.2 × 7.6 × 7.4 cm tumor extensively invading the right levator ani muscles (mainly the puborectalis). In the right intergluteal sulcus there was a small area with fluid inside (1.2 × 1.0), with a probable fistulous path to the skin. The prostate and seminal

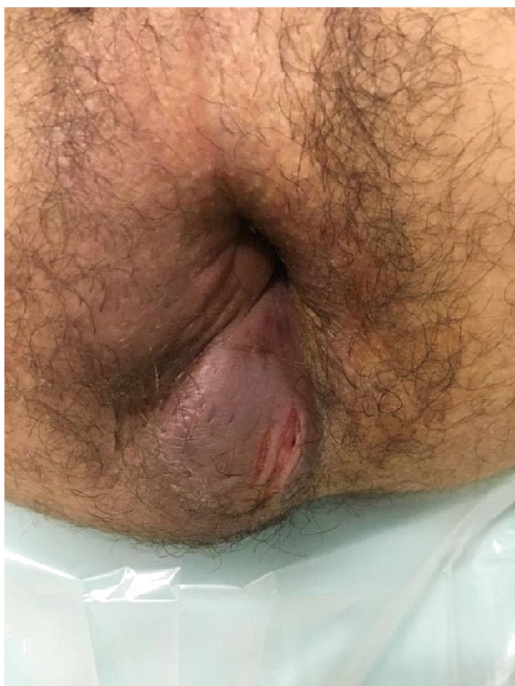

Fig. 1 – Perineal lesion.

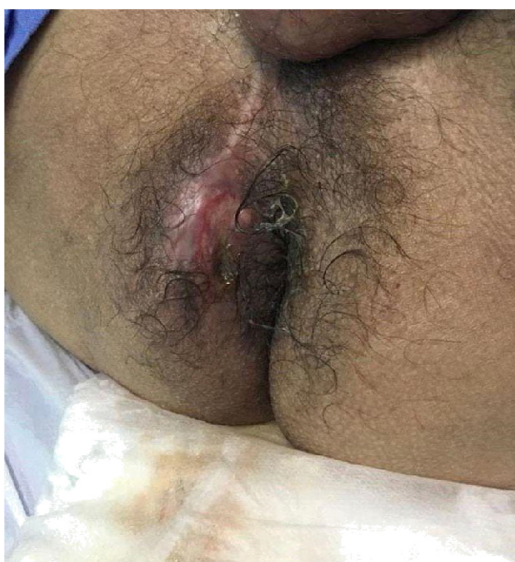


Fig. 2 – Perineal lesion.

vesicles were displaced anteriorly, without invasion and preserving the capsule contour. Defining cleavage plan with the sacrum; prominent bilateral inguinal lymph nodes, especially to the right (largest = 1.1 × 0.9); absence of lymph node enlargement or free fluid in the pelvis. Subsequently, an incisional biopsy of the lesion was performed under general anesthesia, with anatomopathological results compatible with large cell non-Hodgkin's lymphoma and immunohistochemical profile compatible with immunophenotype B lymphoma, plasmablastic lymphoma, positive for CD10, CD20, CD138, ki-67, Bcl-2 and negative for EBV. Also during the investigation, he

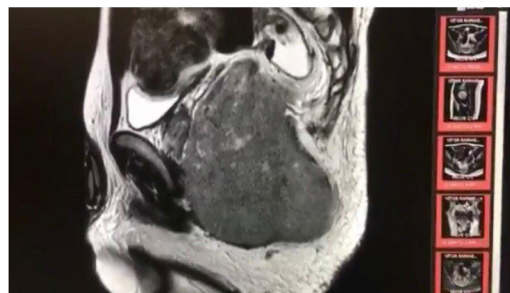

Fig. 3 – Pelvic NMR showing extraperitoneal rectal lesion of 11.2 × 7.6 × 7.4 cm.

was diagnosed with HIV infection, with significant immunosuppression (CD4 37 and CV 541,213 copies).

Afterwards, the patient was transferred to the hematology department for therapeutic planning and, during this period, he presented with compressive urinary tract symptoms (with doxazosin response) and psychiatric decompensation, requiring antipsychotic drugs due to the high risk of suicide. After a bone marrow biopsy negative for lymphoma infiltration, chemotherapy with Etoposide + Doxorubicin + Vincristine (EPOCH) was started. Antiretroviral Therapy (ART) was started with an alternative regimen (abacavir + lamivudina + dolutegravir), associated with prophylactic trimethoprim-sulfamethoxazole.

After the second cycle of chemotherapy, a control CT scan was performed, which showed complete regression of the rectal lesion. The chemotherapy regimen was maintained until the fourth cycle and then PET-CT was performed, which demonstrated absence of areas of abnormal metabolic activity characteristic of active lymphoproliferative disease and absence of parietal thickening or abnormal metabolic increase in the rectum (Lugano score 1).

Discussion

The clinical, radiological, and endoscopic features of the primary gastrointestinal lymphoma are nonspecific, which may hinder the diagnosis, making the clinical picture often indistinguishable from other colon diseases, whether neoplastic or inflammatory. When lymphoma has its primary site in the rectum, the main manifestations are bleeding, rectal pain, tenesmus and change in bowel habits (diarrhea or constipation).¹²

PET/CT is the image of choice for analysis of mass, area of stenosis, and lymph node involvement,¹³ but imaging tests such as pelvic CT and MRI are often sufficient to identify the lesion and are more available in clinical practice. Colonoscopy can show variable mucosal involvement, whether it is a mass, ulceration or infiltration,¹⁴ and allows biopsies for histopathological diagnosis.

Plasmablastic Lymphoma (PBL) is classified by the World Health Organization as a type of mature B-cell lymphoma that expresses plasma antigens (CD38, CD138, MUM1) and common B-cell antigens (CD20, CD19, PAX5) with negative CD45.^{15,16} While its pathogenesis is not yet fully understood, it has been shown that Epstein Barr Virus (EBV) is present

in most cases. In addition, an association with MYC gene rearrangement has been found in a small percentage of cases.⁴ PBL lymphoma was initially identified in the oral cavity of patients with Human Immunodeficiency Virus (HIV) and approximately 80 % of PBL cases are associated with this HIV-positive population.¹⁷ PBL has also been found in areas outside the oral cavity, favoring sites such as the Gastrointestinal (GI) tract, lymph nodes, and skin.¹⁸ The GI tract is one of the most common extranodal sites. PBL is considered an aggressive lymphoma with a median overall survival of 14 months.^{17,18} Regarding treatment, there are no exclusive protocols to guide the extraperitoneal rectal lymphoma management, and cases are treated following the guidelines of intraperitoneal rectal lymphoma. Although both CHOP and EPOCH are considered common therapeutic choices, standard therapy or treatment guidelines have not yet been established. Autologous transplantation is considered optional and tends to have a good outcome, but there is little experience with this treatment.¹⁹ Surgical treatments are rarely needed and are usually indicated in case of complications.

Conclusion

Primary gastrointestinal lymphomas are themselves rare pathologies, with extraperitoneal rectal lymphoma being an even rarer form. Primary gastrointestinal lymphomas are rare pathologies in themselves, with extraperitoneal rectal lymphoma being an even rarer form. It represents a diagnostic challenge and lacks specific protocols to guide therapy. With this report, it is expected to add data to the currently available literature.

Conflicts of interest

The authors declare no conflicts of interest.

REFERENCES

- Dawson IM, Cornes JS, Morson BC. Primary malignant lymphoid tumours of the intestinal tract. Report of 37 cases with a study of factors influencing prognosis. *Br J Surg*. 1961;49:80.
- Lewin KJ, Ranchod M, Dorfman RF. Lymphomas of the gastrointestinal tract: a study of cases presenting with gastrointestinal disease. *Cancer*. 1978;42:693.
- Chim CS, Shek TW, Chung LP, Liang R. Unusual abdominal tumors: Case 3. Multiple lymphomatous polyposis in lymphoma of the colon. *J Clin Oncol*. 2003;21:953–5.
- Henry CA, Berry RE. Primary lymphoma of the large intestine. *Am Surg*. 1988;54:262–6.
- Cai S, Cannizzo F Jr, Bullard Dunn KM, Gibbs JF, Czuczman M, Raiput A. The role of surgical intervention in non-Hodgkin's lymphoma of the colon and rectum. *Am J Surg*. 2007;193:409–12.
- Kohnno S, Ohshima K, Yoneda S, Kodama T, Shirakusa T, Kikuchi M. Clinicopathological analysis of 143 primary malignant lymphomas in the small and large intestines based on the new WHO classification. *Histopathology*. 2003;43:135–43.
- Gurney KA, Gurney KA, Cartwright RA. Increasing incidence and descriptive epidemiology of extranodal non-Hodgkin lymphoma in parts of England and Wales. *Hematol J*. 2002;3:95–104.
- Wong MT, Eu KW. Primary colorectal lymphomas. *Colorectal Dis*. 2006;8:586–91.
- Beaugerie L, Brousse N, Bouvier AM, Colombel JF, Lémann M, Cosnes J, et al. Lymphoproliferative disorders in patients receiving thiopurines for inflammatory bowel disease: a prospective observational cohort study. *Lancet*. 2009;374:1617–25.
- Kandiel A, Fraser AG, Korelitz B, Bresinger C, Lewis JD. Increased risk of lymphoma among inflammatory bowel disease patients treated with azathioprine and 6-mercaptopurine. *Gut*. 2005;54:1121–5.
- Siegel CA, Marden SM, Persing SM, Larson RJ, Sands BE. Risk of lymphoma associated with combination anti-tumor necrosis factor and immunomodulator therapy for the treatment of Crohn's disease: a meta-analysis. *Clin Gastroenterol Hepatol*. 2009;7:874–81.
- Quayle FJ, Lowney JK. Lymphoma colorrectal. *Clin Colon rectal Cirurg*. 2006;19:49–53.
- Lee HJ, Han JK, Kim TK, Kim YH, Kim AY, Kim KW, et al. Primary colorectal lymphoma: spectrum of imaging findings with pathologic correlation. *Eur Radiol*. 2002;12:2242–9.
- Wang MH, Wong JM, Lien HC, Lin CW, Wang CY. Colonoscopic manifestations of primary colorectal lymphoma. *Endoscopy*. 2001;3:605–9.
- Hsi ED, Lorsbach RB, Fend F, Dogan A. Plasmablastic lymphoma and related disorders. *Am J Clin Pathol*. 2011;136:183–94.
- Stein H, Campo E. Plasmablastic Lymphoma. In: Swerdlow SH, Campo E, Harris NL, Jaffe ES, Pileri SA, Stein H, editors. *WHO Classification of Tumours of the Haematopoietic and Lymphoid Tissues*. 4th ed. Sterling, VA: International Agency for Research on Cancer (IARC); 2008.
- Hansra D, Montague N, Stefanovic A, Akunyili I, Harzand A, Natkunam Y, et al. Oral and extraoral plasmablastic lymphoma: similarities and differences in clinicopathologic characteristics. *Am J Clin Pathol*. 2010;134:710–9.
- Castillo JJ, Reagan JL. Plasmablastic lymphoma: a systematic review. *ScientificWorldJournal*. 2011;11:687–96.
- Luria L, Nguyen J, Zhou J, Jaglal M, Sokol L, Messina JL, et al. Manifestations of gastrointestinal plasmablastic lymphoma: A case series with literature review. *World J Gastroenterol*. 2014;20:11894–903.