



## Case Report

# Perforated acute abdomen in a patient with COVID-19: an atypical manifestation of the disease<sup>☆</sup>



Isaac José Felipe Corrêa Neto <sup>\*</sup>, Kaline Fortes Viana, Milena Braga Soares da Silva, Leandro Mariano da Silva, Gustavo de Oliveira, Angelo Rossi da Silva Cecchini, Alexander Sá Rolim, Laercio Robles

Hospital Santa Marcelina, Serviço de Coloproctologia, São Paulo, SP, Brazil

### ARTICLE INFO

#### Article history:

Received 8 May 2020

Accepted 10 May 2020

Available online 31 May 2020

#### Keywords:

Coronavirus

COVID

Pneumothorax

Pneumoperitoneum

### ABSTRACT

**Introduction:** The Coronavirus belongs to a family of RNA viruses that can cause respiratory infection, with the possibility of gastrointestinal manifestations in approximately 5–50% of the cases.

**Objective:** To report a surgical case with a diagnosis of COVID-19 that developed acute perforated abdomen and pneumothorax.

**Case report:** This was an 80-year-old female patient with respiratory symptoms, with dry cough and fever and diffuse abdominal pain with signs of peritonitis. She had leukocytosis, kidney dysfunction and an increase in D-dimer with positive PCR for COVID. Computed tomography of the chest and abdomen showed pneumothorax on the right and extensive pneumoperitoneum.

**Conclusion:** The presentation of COVID-19 with severe pulmonary and abdominal complications requires specialized and emergency treatments, but it has high mortality rates.

© 2020 Sociedade Brasileira de Coloproctologia. Published by Elsevier Editora Ltda. This is an open access article under the CC BY-NC-ND license (<http://creativecommons.org/licenses/by-nc-nd/4.0/>).

## Abdome agudo perfurativo em paciente com COVID-19: uma manifestação atípica da doença

### RESUMO

**Introdução:** O coronavírus pertence a uma família de vírus RNA que pode causar infecção respiratória com possibilidade de manifestações gastrintestinais em torno de 5% a 50% dos casos.

**Objetivo:** Relatar caso operado com diagnóstico de COVID-19 e evolução com abdome agudo perfurativo e pneumotórax.

#### Palavras-chave:

Coronavírus

COVID

Pneumotórax

Pneumoperitônio

<sup>☆</sup> Work carried out at the Service of Coloproctology of the Department of General Surgery of Hospital Santa Marcelina, São Paulo, SP, Brazil.

<sup>\*</sup> Corresponding author.

E-mail: [isaacneto@hotmail.com](mailto:isaacneto@hotmail.com) (I.J. Corrêa Neto).

<https://doi.org/10.1016/j.jcol.2020.05.011>

2237-9363/© 2020 Sociedade Brasileira de Coloproctologia. Published by Elsevier Editora Ltda. This is an open access article under the CC BY-NC-ND license (<http://creativecommons.org/licenses/by-nc-nd/4.0/>).

**Relato do caso:** Paciente do sexo feminino de 80 anos com sintomas respiratórios com tosse seca e febre e dor abdominal difusa com sinais de peritonite. Apresentava leucocitose, disfunção renal e aumento de D-dímero com PCR positivo para COVID. Tomografia computadorizada de tórax e abdome demonstrando pneumotórax à direita e extenso pneumoperitônio.

**Conclusão:** A apresentação do COVID-19 com sérias complicações pulmonar e abdominal requer tratamentos especializados e em regime de emergência, entretanto com altas taxas de mortalidade.

© 2020 Sociedade Brasileira de Coloproctologia. Publicado por Elsevier Editora Ltda. Este é um artigo Open Access sob uma licença CC BY-NC-ND (<http://creativecommons.org/licenses/by-nc-nd/4.0/>).

## Introduction

The Coronavirus belongs to a family of RNA viruses that can cause respiratory infection with varied symptoms, with COVID-19 being a new type of microorganism belonging to this family described in the last months of 2019, of which symptoms usually include coughing, fever, fatigue, headache and myalgia after 2–14 days of exposure.<sup>1–5</sup>

The virus enters the cells through the angiotensin-converting enzyme-2 receptor, which is also expressed in the epithelium of the gastrointestinal tract, from the esophagus to the colon.<sup>6,7</sup> Gastrointestinal (GI) involvement, described as viral detection in feces and evidence of fecal-oral transmission, can be characterized by abdominal pain, hyporexia, nausea and vomiting<sup>1,4,7–9</sup> with a variable incidence ranging from 5% to 50% of cases<sup>3,10,11</sup>; it may precede the respiratory symptoms, but they commonly coexist,<sup>4</sup> although in 10% of cases the pulmonary imaging exam is normal.<sup>12</sup>

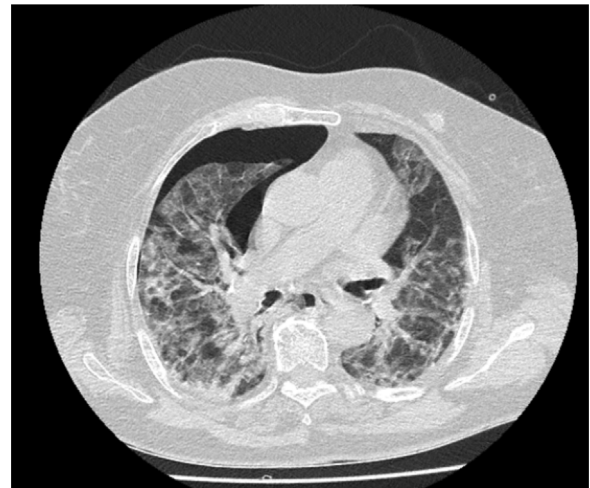Additionally, COVID-19 may also predispose to venous and arterial thromboembolic diseases due to excessive inflammation, hypoxia and diffuse intravascular coagulation through the hypercoagulable state triad, blood stasis and endothelial injury.<sup>2,8</sup> Salad et al.<sup>13</sup> emphasize the occurrence of vascular thickening and thromboembolic phenomena, mainly in lobar ramifications of the lungs in patients affected by this disease, resulting in increasing hypoxemia with predictive value of adverse results related to D-dimer levels.

The aim is to report on a surgical case treated at Hospital Santa Marcelina, São Paulo, SP, Brazil with a diagnosis of COVID-19 and patient evolution that included acute perforated abdomen and pneumothorax.

## Case report

This case was an 80-year-old female patient, hospitalized after 10 days of dry and persistent cough, fever and shortness of breath, already using Tamiflu and Azithromycin for 5 days prescribed at a primary health care unit. She had a previous pathological history of systemic arterial hypertension and ischemic heart disease, and used Clopidogrel, ASA, Losartan and Carvedilol.

On physical examination, she had tachypnea, 91% oxygen saturation in ambient air, fever and pulmonary auscultation disclosed decreased breath sounds on the right with



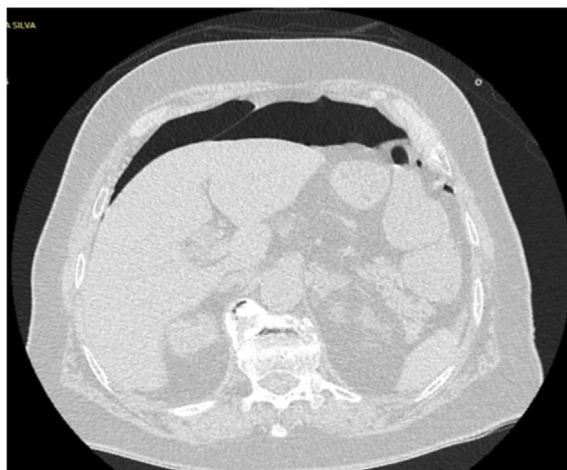
**Fig. 1 – Computed tomography image showing alveolar interstitial infiltrate and right pneumothorax.**

crackling rales on the left lung base and diffuse rhonchi, in addition to diffuse abdominal pain and stiffness, not localized and with signs of peritoneal irritation.

Complementary blood tests showed leukocytosis of 19,950 mm<sup>3</sup> with 8% rods and 76% segmented, with 3% monocytes, in addition to an increase in platelets to 507,200 mm<sup>3</sup>, GOT = 23.00 U/L, GPT = 41.00 U/L, elevation in nitrogenous compounds, with creatinine of 5.54 mg/dL and urea of 139 mg/dL. Other associated laboratory alterations were: D-dimer of 1466.8 ng/dL, ferritin of 1199 ng/dL, creatine phosphokinase of 239.00 U/L and positive PCR for COVID-19.

She was submitted to Computed Tomography of the chest, abdomen and pelvis, with evidence of ground-glass pattern in the bilateral pulmonary parenchyma, pneumothorax on the right and extensive pneumoperitoneum, with free intracavitary fluid (Figs. 1 and 2).

Clinical resuscitation measures were initiated, with intravenous hydration, orotracheal intubation, broad-spectrum antibiotic therapy (Tazocin 4.5 g 3×/day and Azithromycin 500 mg/day) and medications for COVID-19. After the initial stabilization, she was submitted to right chest drainage and exploratory laparotomy, with evidence of reduced visceral perfusion in the entire gastrointestinal tract and four punctate lesions in the sigmoid colon, with leakage of fecal content into



**Fig. 2 – Computed tomography image showing extensive pneumoperitoneum.**

the cavity. A rectosigmoidectomy with terminal colostomy was performed.

On the second postoperative day, the patient developed refractory septic shock and died. The anatomopathological examination showed ulcerated and perforated colonic segmental necrosis with hemorrhage, and peri-intestinal lymph nodes showing vascular congestion.

## Discussion

The identification or, at least the investigation, of the association of pulmonary and abdominal symptoms for a faster diagnosis, more effective, orderly therapy and better adoption of isolation measures, should be the routine and a premise, especially in urgency and emergency services, during this time of the COVID-19 pandemic.

In the case reported here, it should be noted that disease progression was abrupt, with the development of important clinical complications with pneumothorax and pneumoperitoneum, secondary to ischemia and perforation of the sigmoid colon.

The occurrence of pneumothorax is reported in approximately 1% of patients with COVID-19<sup>14–16</sup> and should be suspected in cases of sudden and significant dyspnea in these patients. It usually results from alveolar rupture and its risk factors comprise smoking, age, short stature, male gender, low body mass index, prolonged coughing (as in the case presented herein), strenuous exercise and chronic obstructive pulmonary disease.<sup>1,4,16,17</sup>

On the other hand, the ischemia of the entire GIT with colon perforation reported here may result from septic and thromboembolic phenomena, caused directly or indirectly by the viral infection. Studies have stated that critically-ill patients with COVID-19 are more likely to have a hypercoagulable state, with the manifestation of intravascular coagulation due to local damage.<sup>8,15,17</sup>

Additionally, the coronavirus has an extensive tissue distribution, causing the release of a high number of pro-inflammatory cytokines that damage the microvascular

system, promoting abnormal activation of the coagulation system, which manifests itself as generalized small-vessel vasculitis and extensive microthrombi.<sup>2,8</sup> This fact, associated with the patient's comorbidities, such as hypertension and coronary disease, are associated with high mortality rates and a high risk of coagulation dysfunction.

In the case reported herein, it is noteworthy that the blood tests showed pulmonary and septic dysfunction at two sites – pulmonary and abdominal. Moreover, the monocyte and transaminase counts were found to be normal and some articles mention the association of these tests with only an abdominal picture in COVID-19.<sup>4,14</sup>

## Conclusion

The presentation of COVID-19 with severe pulmonary and abdominal complications requires specialized and emergency treatments, but it has high mortality rates.

## Conflicts of interest

The authors declare no conflicts of interest.

## REFERENCES

1. Poggiali E, Ramos PM, Bastoni D, Vercelli A, Magnacavallo A. Abdominal pain: a real challenge in novel COVID-19 infection. *Eur J Case Rep Intern Med.* 2020;7:001632.
2. Chen N, Zhou M, Dong X, Qu J, Gong F, Han Y, et al. Epidemiological and clinical characteristics of 99 cases of 2019 novel coronavirus pneumonia in Wuhan, China: a descriptive study. *Lancet.* 2020;395:507–13.
3. Huang C, Wang Y, Li X, Ren L, Zhao J, Hu Y, et al. Clinical features of patients infected with 2019 novel coronavirus in Wuhan, China. *Lancet.* 2020;395:497–506.
4. Pan L, Mu M, Yang P, Sun Y, Wang R, Yan J, et al. Clinical characteristics of covid-19 patients with digestive symptoms in Hubei, China: a descriptive, cross-sectional, multicenter study. *Am J Gastroenterol.* 2020;115:766–73.
5. Lai CC, Shih TP, Ko WC, Tang HJ, Hsueh PR. Severe acute respiratory syndrome coronavirus 2 (SARS-CoV-2) and coronavirus disease-2019 (COVID-19): the epidemic and the challenges. *Int J Antimicrob Agents.* 2020;55:105924.
6. Wu F, Zhao S, Yu B, Chen Y-M, Wang W, Song Z-G, et al. A new coronavirus associated with human respiratory disease in China. *Nature.* 2020, <http://dx.doi.org/10.1038/s41586-020-2008-3>. Published online February 3.
7. Tian Y, Rong L, Nian W, He Y. Review article: gastrointestinal features in COVID-19 and the possibility of faecal transmission. *Aliment Pharmacol Ther.* 2020;51:843–51.
8. Song Y, Liu P, Shi XL, Chu YL, Zhang J, Xia J, et al. SARS-CoV-2 induced diarrhoea as onset symptom in patient with COVID-19. *Gut.* 2020, <http://dx.doi.org/10.1136/gutjnl-2020-320891> [Epub ahead of print].
9. Liang W, Feng Z, Rao S, Xiao C, Xue X, Lin Z, et al. Diarrhoea may be underestimated: a missing link in 2019 novel coronavirus. *Gut.* 2020, <http://dx.doi.org/10.1136/gutjnl-2020-320832> [Epub ahead of print].

10. Nobel YR, Phipps M, Zucker J, Lebwohl B, Wang TC, Sobieszczyk ME, et al. Gastrointestinal symptoms and COVID-19: case–control study from the United States. *Gastroenterology*. 2020, <http://dx.doi.org/10.1053/j.gastro.2020.04.017> [Epub ahead of print].
11. Hormati A, Shah-hamzeh A, Afifan M, Khodadust F, Ahmadpour S. Can COVID-19 present unusual GI symptoms? *J Microbiol Immunol Infect*. 2020, <http://dx.doi.org/10.1016/j.jmii.2020.03.020> [Epub ahead of print].
12. Jin X, Lian JS, Hu JH, Gao J, Zheng L, Zhang YM, et al. Epidemiological, clinical and virological characteristics of 74 cases of coronavirus-infected disease 2019 (COVID-19) with gastrointestinal symptoms. *Gut*. 2020:1–8.
13. Qanadli SD, Beigelman-Aubry C, Rotzinger DC. *Am J Roentgenology*. W1. <https://doi.org/10.2214/AJR.20.2318>.
14. Al-mufarrej F, Gharagozloo F, Tempesta B, Margolis M. Spontaneous cervicothoracolumbar pneumorrhachis, pneumomediastinum and pneumoperitoneum. *Clin Resp J*. 2009;3:239–43.
15. Wang W, Gao R, Zheng Y, Jiang L. COVID-19 with spontaneous pneumothorax, pneumomediastinum and subcutaneous emphysem. *J Travel Med*. 2020, <http://dx.doi.org/10.1093/jtm/taaa062> [Epub ahead of print].
16. Wang J, Su X, Zhang T, Zheng C. Spontaneous pneumomediastinum: a probable unusual complication of coronavirus disease 2019 (COVID-19) pneumonia. *Korean J Radiol*. 2020;21:627–8.
17. Zhou B, She J, Wang Y, Ma X. Venous thrombosis and arteriosclerosis obliterans of lower extremities in a very severe patient with 2019 novel coronavirus disease: a case report. *J Thromb Thrombolysis*. 2020, <http://dx.doi.org/10.1007/s11239-020-02084-w> [Epub ahead of print].