







Ovarian Metastasis from Colorectal Adenocarcinoma

Metástase ovariana de adenocarcinoma colorretal

Lúcio Sarubbi Fillmann¹ Henrique Sarubbi Fillmann¹ Laura Pinho Fillmann²
Ana Paula Reginatto Tubiana² Raquel Ribeiro² Mariana Coelho²

¹Coloproctology Service, Hospital São Lucas, Pontifícia Universidade Católica do Rio Grande do Sul (PUCRS), Porto Alegre, Rio Grande do Sul, RS, Brasil

²Escola de Medicina, Pontifícia Universidade Católica do Rio Grande do Sul (PUCRS), Porto Alegre, Rio Grande do Sul, RS, Brasil

Address for correspondence Lúcio Fillmann, PhD, Avenida Ipiranga 6.690, sala 307, Centro Clínico PUCRS, Porto Alegre, Rio Grande do Sul, RS, 90610-000, Brasil (e-mail: lsfillmann@yahoo.com.br).

J Coloproctol 2021;41(2):176–181.

Abstract

Introduction Ovarian metastases of gastrointestinal origin, also called Krukenberg tumors, have a guarded prognosis. Physicians need to look for alternatives in diagnosis and treatment for this clinical condition in order to improve the outcome of the patients.

Objectives To report the experience of the authors in the treatment of these patients, and to perform a review of the literature on the epidemiology, clinical presentation, diagnosis, treatment, and prognosis for ovarian metastases from colorectal cancer.

Methods We collected clinical information regarding the patients treated for ovarian metastasis from colorectal adenocarcinoma at our coloproctology service, and performed a search on the PubMed database using the terms *colorectal cancer*, *ovarian metastasis*, *Krukenberg tumor* and *surgery*.

Conclusion Large abdominal tumors are the most frequent presentation of ovarian metastasis from colorectal cancer. The diagnosis is based on a histopathological analysis, levels of carcinoembryonic antigen (CEA) and cancer antigen 125 (CA-125), and immunohistochemical studies for the cytokeratin 20 (CK20), *caudal-type homeobox 2 (CDX2)* and vilina markers. Cytoreductive surgical procedures are the most promising approach to treatment, with the highest impact on overall survival. The prognosis is negatively influenced by the extent of the metastasis, by cytoreductive surgical procedures with persistence of macro- or microscopic foci of the disease, and by low scores on the general well-being index of the patient.

Keywords

- ▶ colorectal cancer
- ▶ ovarian metastasis
- ▶ surgery

received
July 10, 2020
accepted
January 15, 2021

DOI <https://doi.org/10.1055/s-0041-1730426>.
ISSN 2317-6423.

© 2021. Sociedade Brasileira de Coloproctologia. All rights reserved.

This is an open access article published by Thieme under the terms of the Creative Commons Attribution-NonDerivative-NonCommercial-License, permitting copying and reproduction so long as the original work is given appropriate credit. Contents may not be used for commercial purposes, or adapted, remixed, transformed or built upon. (<https://creativecommons.org/licenses/by-nc-nd/4.0/>)

Thieme Revinter Publicações Ltda., Rua do Matoso 170, Rio de Janeiro, RJ, CEP 20270-135, Brazil

Resumo

Introdução As metástases ovarianas de tumores gastrointestinais, também chamadas de tumores de Krukenberg, são neoplasias de prognóstico reservado. Exigem conhecimento de alternativas diagnósticas e terapêuticas para garantir melhora da sobrevida das pacientes.

Objetivos Relatar a experiência dos autores no tratamento dessas pacientes, e fazer uma revisão da literatura sobre a epidemiologia, apresentação clínica, diagnóstico, tratamento e prognóstico das metástases ovarianas do câncer colorretal.

Métodos Foi realizada uma coleta de informações clínicas de pacientes tratados por metástases ovarianas de adenocarcinoma colorretal em nosso serviço de coloproctologia, em conjunto com uma pesquisa na base de dados PubMed com os termos *colorectal cancer*, *ovarian metastasis*, *Krukenberg tumor*, e *surgery*.

Conclusão Volumosas massas abdominais constituem a principal apresentação clínica da doença. As alternativas diagnósticas incluem a avaliação histopatológica, a identificação dos níveis de antígeno cárcino-embriônico (ACE) e de antígeno de câncer 125 (CA-125), e exame imunoistoquímico de espécimes cirúrgicos para os marcadores citoqueratina 20 (CK20), *homeobox 2 do tipo caudal (CDX2)*, e vilina. O tratamento citorrredutor completo demonstrou o maior impacto na sobrevida dos pacientes. O prognóstico é influenciado negativamente pela extensão da doença metastática, por cirurgia citorrredutiva com persistência focos microscópicos ou macroscópicos da doença, e baixo escore de índice de bem-estar geral do paciente.

Palavras-chave

- ▶ câncer colorretal
- ▶ metástase ovariana
- ▶ cirurgia

Introduction

Krukenberg tumor is a metastatic ovarian neoplasm of primary origin in the gastrointestinal tract.¹ It represents a disease with a reserved prognosis due to malignant dissemination in the abdominal cavity associated with its origin, turning it essential to evaluate treatment alternatives that can improve the survival of the patients, such as cytoreductive surgery.^{1,2} The differential diagnosis between primary and metastatic ovarian tumors is quite difficult,^{2,4} requiring knowledge of specific clinical features in addition to other diagnostic techniques, such as histopathological evaluation,⁵ immunohistochemistry,² and tumor marker values such as carcinoembryonic antigen (CEA) and cancer antigen 125 (CA-125).⁶

Objectives

The purpose of the present study is to report our experience with the care for these ovarian lesions combined with a review of the literature on the epidemiology, clinical presentation, diagnosis, treatment, and prognosis of ovarian metastases from colorectal cancer.

Methods

A collection of clinical data from patients treated for ovarian metastases from colorectal adenocarcinoma in our proctology service and a search for the terms *colorectal cancer*, *ovarian metastasis*, *Krukenberg tumor*, and *surgery* in the PubMed database were performed. Studies published from 1981 to 2019 were included.

Epidemiology

Metastatic involvement of the ovary is estimated to account for 5% to 30% of all ovarian neoplasms, originating from both colorectal cancer and malignant tumors of the endometrium, stomach, appendix, and breast.⁷ The average age of women with ovarian metastasis from colorectal cancer is 45 years, but there is wide variation in the literature.⁶ Between 12.5% and 49% of ovarian metastatic lesions originate from adenocarcinomas of the colon and rectum.⁷ Yet, the ovary is an uncommon site for the development of metastases from these neoplasms, with a frequency of synchronous and metachronous ovarian involvement of around 9% and 7% respectively.⁷

Clinical Presentation

Ovarian metastasis from colorectal cancer usually presents as a palpable abdominal mass.^{2,8} Reports indicate that between 3% and 20.9% of women with colon and rectal carcinoma, an ovarian mass was observed before the suspicion of intestinal disease.^{5,6} In our small series of cases, an increase in abdominal volume combined with a palpable mass was the main clinical presentation, with the development of these lesions always occurring during the follow-up period of the primary lesion.

The most reported symptoms include pain or discomfort in the abdomen,^{2,6,7,9} in addition to progressive abdominal distention² and cramps.⁸ Ascites is a frequent finding upon physical examination,^{2,10} with an increase in abdominal circumference observed in approximately 63% of the

patients.⁷ In addition, the growth of ovarian tumors was associated with anorexia, constipation, changes in the voiding pattern, and, less frequently, diarrhea and vaginal bleeding.⁶⁻⁸

The differential diagnosis between primary tumors and ovarian metastases is often difficult.^{2,4} Symptoms associated with the development of ovarian cancer can mask intestinal disease. Besides, primary and metastatic ovarian lesions look both clinically and morphologically alike.⁴

Diagnosis

There are many difficulties in making the correct differential diagnosis of primary or metastatic ovarian tumor. In our experience, despite the suspicion of metastatic disease, a conclusive diagnosis was only possible after the surgical approach. Cases of synchronic intestinal and ovarian lesions can be even more complicated. The possibility of ovarian metastasis in patients being evaluated for pelvic tumors is often not considered. Therefore, no attempt is made to look for a primary tumor in the gastrointestinal tract.⁸ This problem occurs because, in some cases, the symptoms of metastasis appear before the symptoms of the primary site.⁸ The serum values of CEA and CA-125 have an important role in the differential diagnosis. Elevations in CEA above 5 U/ml and CA-125 levels above 35 U/ml have been described in approximately 93% and 80% of patients with colorectal ovarian metastases respectively.^{6,10} Therefore, the simultaneous increase in both markers seems quite useful for the diagnosis of metastatic ovarian disease.⁶

In a transoperative finding, frozen biosy proved to be of little value to differentiate primary from metastatic disease to the ovary. There are reports that this type of anatomopathological analysis is able to establish a diagnosis of metastatic ovarian disease in up to 58% of the cases.⁶ High-grade, low-

differentiated serous carcinomas, endometrioid carcinomas, and mucinous adenocarcinomas are the most difficult to distinguish.⁶ Even so, histopathological investigation can be useful, since the histological subtype of ovarian metastasis is very similar to the subtype of primary intestinal carcinomas in several cases.⁵

Metastases can be histologically subclassified, in decreasing order of frequency, in pseudoendometrioid adenocarcinomas, mucinous carcinomas, and mixed tumors, in which there are morphological components of both previous lesions.^{5,10} In the cases treated by our team, we observed infiltration of the ovarian stroma by atypical glandular structures, especially between well- or moderately-differentiated intestinal adenocarcinomas (–Figs. 1 and 2). It is interesting to note that metastatic disease produces cystic or semicystic ovarian lesions that hinder the differential diagnosis with cystadenocarcinomas and endometrioid carcinomas of the ovary.⁵ Upon histopathological examination, metastasis has crown-shaped or cribriform structures associated with rounded glandular aggregates with necrosis in its walls.⁵ The presence of a scaly component helps to rule out the intestinal origin of the neoplasm, since it is extremely rare in colorectal adenocarcinomas, and can be present in up to 50% of ovarian endometrioid tumors.⁵ Another important characteristic is the occurrence of bilateral lesions, which are described in more than 60% of metastatic cases.¹ On the other hand, less than 20% of primary endometrioid tumors or stage-1 cystadenocarcinomas involve both ovaries.⁵

We believe that immunohistochemistry plays a fundamental role in the diagnosis. In most cases, primary ovarian neoplasia has a positive color for cytokeratin 7 (CK7) and negative for cytokeratin 20 (CK20),² whereas colorectal carcinoma is more often negative for CK7 and positive for CK20.² These findings were fundamental for the diagnostic

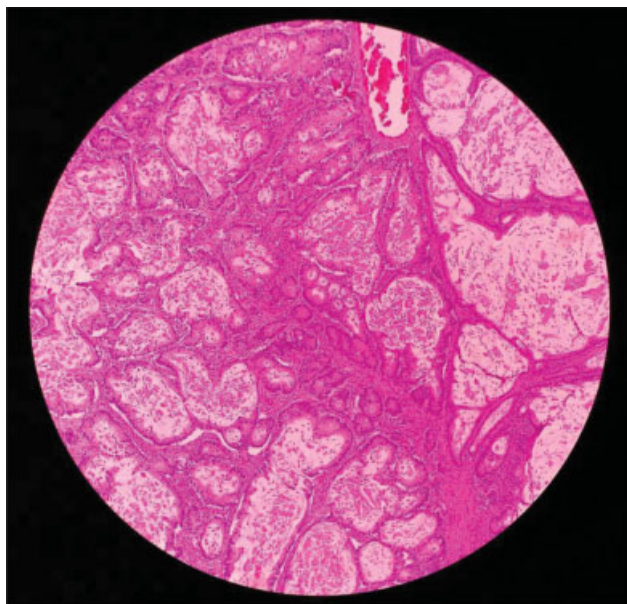


Fig. 1 Ovary hematoxylin and eosin (H&E) staining, magnification of 100X – moderately differentiated adenocarcinoma area infiltrating the ovarian stroma.

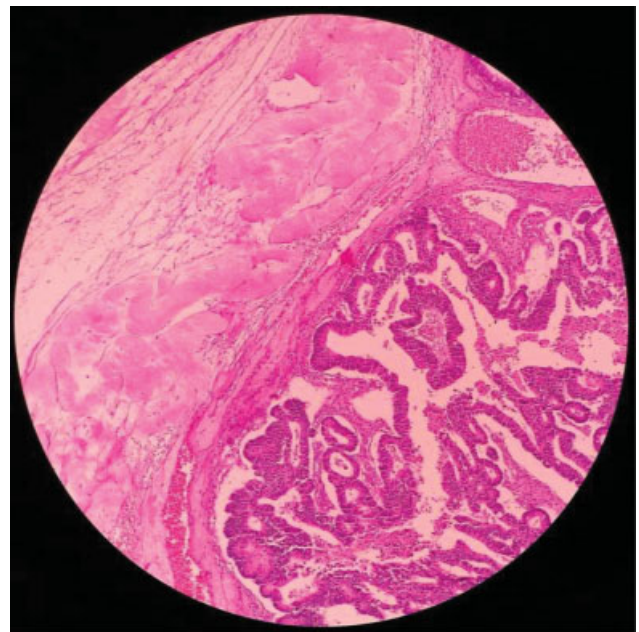


Fig. 2 Ovary hematoxylin and eosin (H&E) staining, magnification of 100X. On the left of the image, an albicant body. On the right, adenocarcinoma infiltrating the ovarian stroma.

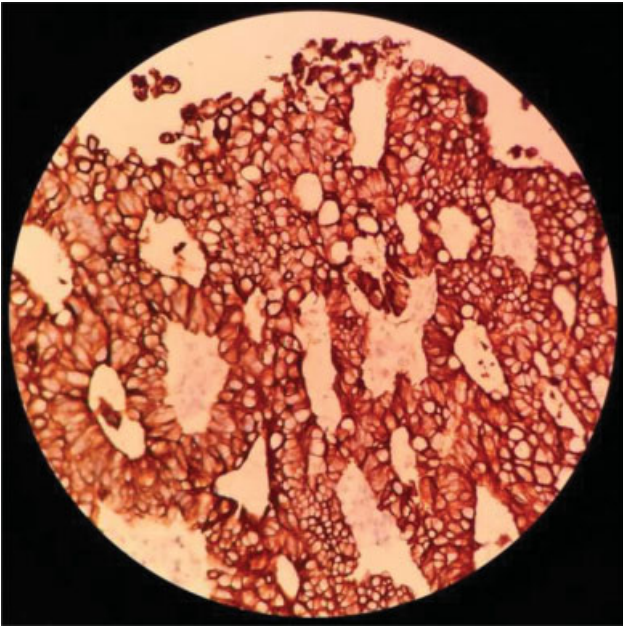


Fig. 3 Ovary in magnification of 400X – positive reaction to CK20 staining the cytoplasm of intestinal neoplastic cells in the ovary.

clarification of the cases treated in our surgical unit (► **Fig. 3**). The *caudal-type homeobox 2 (CDX2)* gene expressed in the nucleus of intestinal epithelial cells is an important marker for gastrointestinal adenocarcinoma, and should also be evaluated.² By combining these two markers in our series, we have increased the diagnostic sensitivity for metastatic disease (► **Fig. 4**). In addition to these, we used villin in the parametrization of our immunohistochemical study (► **Fig. 5**), which has a fundamental role in detecting the origin of a metastatic carcinoma, since its expression is

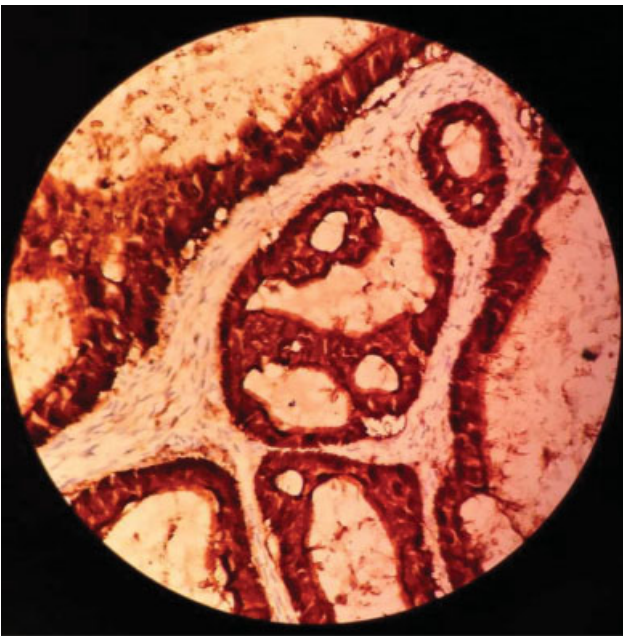

Fig. 5 Ovary in magnification of 400X – positive reaction to villin staining the membrane and cytoplasm of neoplastic cells in the ovary. It is a relatively specific marker for gastrointestinal epithelium with microvilli (“brush border”) or adenocarcinomas derived from it.

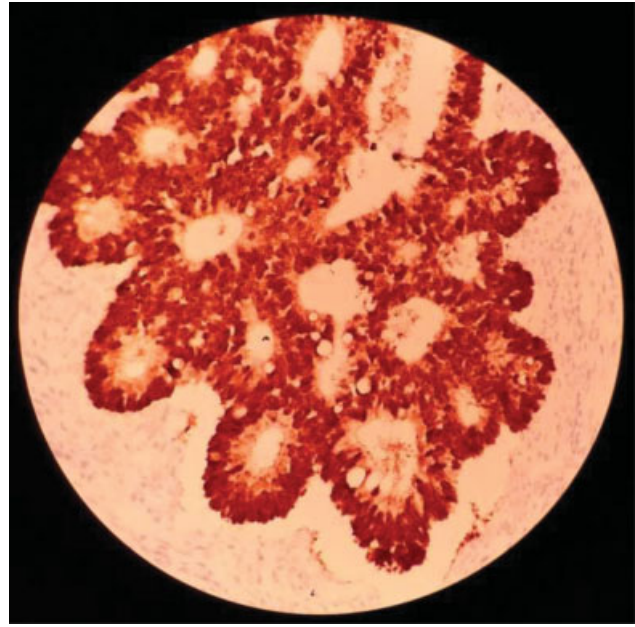


Fig. 4 Ovary in magnification of 400X – positive reaction to *CDX2* staining the nuclei of the neoplastic cells in the ovary.

associated with cells that have the “brush border” characteristic typically seen in enterocytes and renal cells of the proximal tubule.¹¹ Thus, villin is related to colon adenocarcinomas, and is expressed as a thin line on the apical surface of tumor cells, the same pattern found in normal intestinal epithelial cells.¹¹

Treatment

We consider the surgical approach as the main therapeutic strategy in cases of suspicion of ovarian metastasis from a colorectal carcinoma. Its importance also resides in obtaining material for the histological and immunohistochemical analyses, which are vital for the differential diagnosis between primary and metastatic lesions. Besides, ovarian metastasis from colorectal cancer is less responsive to chemotherapy when compared to the primary tumor¹ or other extra-ovarian metastases.⁷ Thus, cytoreductive surgery appears as an important treatment alternative and an improvement in prognosis. The therapeutic approach to these patients should include a cytoreductive surgical procedure, which increases the response of the adjuvant chemotherapy.^{1,6} Neoadjuvant chemotherapy can be used in cases of unresectable tumors.⁶ In a study⁹ with 13 patients diagnosed with ovarian metastasis from colorectal carcinoma in which 10 received treatment with 5-fluoracil, there was complete response for 8 months in 1 patient, partial response of short duration in 4 patients, and 5 did not respond to any chemotherapy regimen. Although neoadjuvant and adjuvant chemotherapy constitute a possibility for the treatment, conservative approaches did not show conclusive beneficial effects even when including other modalities such as radiotherapy and immunotherapy.⁹ Another study¹ with 57 patients with colorectal Krukenberg tumor demonstrated an important improvement in survival in patients with

metastasis to the lymph nodes with the use of systemic chemotherapy (17-month increase in survival).

Studies have shown that cytoreductive surgery was an important factor to improve prognosis in women diagnosed with Krukenberg tumor of different origins.³ In a first study,³ the overall 5-year survival rate of these patients was of only 12.5%, while the survival of those who underwent complete metastasectomy (only with microscopic residues) reached 23.4% (average of 29.6 months of survival). In another study¹ in which the overall 5-year survival rate of patients with Krukenberg tumor was of only 25%, the authors observed that this rate reached 46% (average of 56 months of survival) when complete cytoreductive surgery was performed. Patients with persistent postsurgical macroscopic disease had an average survival between 10 and 13 months, none reaching 5 years.^{1,3} Another study¹⁰ with 34 patients with ovarian metastasis from colorectal adenocarcinoma also demonstrated the prognostic importance of complete cytoreductive surgery, which increased survival in 21 months among patients only submitted to palliative treatment. The percentage of patients in whom it was possible to perform this complete cytoreductive procedure varied between 59.3%³ and 73.7%,¹ with the higher resection rates among patients with colorectal metastasis (69.6%) than among those with metastasis of gastric origin (46.2%).³

However, it should be taken into account that patients with ovarian metastasis from colorectal adenocarcinoma may be less tolerant to complex treatments with a higher risk of surgical complications.¹ Low scores on the general well-being index of the patient may negatively influence the surgical prognosis.^{1,3} Therefore, the cytoreductive treatment should be preceded by an assessment not only of the patient's general clinical status, but also of the possibility of a procedure that removes the entire tumor lesion as well as other metastatic extensions of the disease.³ Due to the high risk of complications, interventions in cases of metastases exceeding the limit of the pelvis are not recommended.¹ In a study¹⁰ with 34 patients with ovarian metastasis from colorectal adenocarcinoma, complete resection of the lesion was only not possible in 1 of the 10 patients with metastasis confined to the pelvis. The other 24 patients underwent palliative treatments due to inoperable liver, bone, lung injuries, or the presence of massive peritoneal carcinomatosis.¹⁰ Palliative procedures were performed in cases of intestinal obstruction, abdominal distension, pain and ascites.⁸ Therefore, the benefits of performing cytoreductive surgery should be evaluated according to the general condition of each patient, which may indicate only palliative interventions in some cases.⁹

Bilateral oophorectomy is recommended in cases of confirmation of metastatic involvement of the ovary in patients with colorectal cancer,¹ and the frequency of patients with bilateral involvement can reach up to 63.2%.¹ During resection of a primary tumor of the bowel, it is important to observe the ovaries for any indication of metastatic involvement,⁸ and it is recommended to previously ask the patient about the expectation of becoming pregnant if a simultaneous bilateral oophorectomy is necessary.⁹ There is still discussion about the indications for prophylactic oopherec-

tomy. Some of the indications include the presence of an abnormal ovary and a primary tumor adjacent to the ovaries or uterus.⁸ Regarding age, there is debate about the indication of oophorectomy in patients older than 40 years of age or in menopause.^{5,8} However, some studies⁵ suggest that there is no justification for the prophylactic removal of the ovaries due to the low incidence of ovarian metastases.

Prognosis

Patients diagnosed with ovarian metastasis from gastrointestinal tract adenocarcinoma have a very guarded prognosis.^{1,2} The survival recorded in the literature varies from an average of 17.8 months in patients who underwent surgical treatment for Krukenberg tumor of different origins³ to an average of 12 months in cases of colorectal origin that underwent palliative treatments.¹ It is believed that this prognosis is due to the extensive malignant spread of colorectal adenocarcinoma in the abdominal cavity.¹ The most significant prognostic factors are the origin of the primary neoplasia, the extension of the metastatic disease (restricted to the pelvis or not), cytoreductive surgery with persistent micro- or macroscopic foci of the disease, the synchronous or metachronic diagnosis of metastasis, and low score on the Karnofsky Performance Scale (KPS, an index that measures the general well-being of the patients).^{1,3}

Women diagnosed with Krukenberg tumor of gastric origin have the worst prognosis of all.³ In a study³ with 54 patients with tumors of different origins, those with gastric origin had an average survival of 13 months, while ovarian metastases from colorectal or other primary sites (breast, pancreas, cholangiocarcinoma) had a survival rate of 29.6 and 48.2 months respectively. This is due to the characteristics associated with gastric tumors, in addition to common clinical conditions that include anemia, cachexia and coagulation disorders, which can also make it difficult to perform the surgical treatment.³

The extent of the metastatic disease also affects the prognosis of these cases: the more extensive the disease, the worse the prognosis. In a study¹ with patients with colorectal ovarian metastases in which the average 5-year survival rate was of 25%, there were no cases with such long survival when the metastatic disease extended beyond the pelvic limits. In these situations, there is a greater risk of surgical complications, and greater difficulty in performing complete cytoreductive surgery.¹ Better prognosis was associated with the absence of peritoneal extension (53% 5-year survival versus 22% with peritoneal extension),¹ and with unilateral involvement of the ovary in cases of metastasis restricted to the pelvis.¹⁰

Complete resection of ovarian metastasis has shown to be superior to palliative treatment because it increased survival from 15 months to 36 months in women with colorectal neoplasms.¹⁰ Likewise, none of the patients diagnosed with Krukenberg tumor of other primary sites who persisted with macroscopic disease residues after cytoreductive surgery had a survival greater than 4 years, while 23.4% of patients who underwent complete surgery reached the 5-year mark.³

The prognostic relevance of synchronic or metachronic diagnosis is controversial. A study¹ with patients with colorectal metastases demonstrated a 23-month increase in patient survival when the diagnostic interval exceeded 2 years. However, a study³ with patients with tumors of different origins recorded a 0.3-month increase in the survival of patients with synchronous diagnosis, concluding that synchronicity could represent a better or equal prognosis in relation to the metachronic diagnosis.

Conclusion

Krukenberg tumors have a guarded prognosis that is influenced by the extent of the metastatic disease, cytoreductive surgery with persistence of micro- or macroscopic foci of the disease, and low score regarding the general well-being of the patient. Although difficult, differential diagnosis must be made early to minimize the complications. The diagnostic alternatives include histopathological assessment with the identification of metastatic histological subtypes similar to primary colorectal cancer subtypes, with pseudoendometrioid adenocarcinomas being more common. In addition, CEA and CA-125 with values above 5 U/ml and 35 U/ml respectively, and positive immunohistochemical analysis for markers CK20, CDX2, and villin are important for diagnostic confirmation. The complete cytoreductive treatment showed an impact on patient survival, and it may be associated with neoadjuvant and/or adjuvant chemotherapy, becoming the preferred therapeutic approach in cases of ovarian metastatic involvement in colorectal adenocarcinoma.

Conflict of interests

The authors have no conflicts of interest to declare.

References

- 1 Xu KY, Gao H, Lian ZJ, Ding L, Li M, Gu J. Clinical analysis of Krukenberg tumours in patients with colorectal cancer—a review of 57 cases. *World J Surg Oncol* 2017;15(01):25–31
- 2 Shimazaki J, Tabuchi T, Nishida K, et al. Synchronous ovarian metastasis from colorectal cancer: A report of two cases. *Oncol Lett* 2016;12(01):257–261
- 3 Jiang R, Tang J, Cheng X, Zang RY. Surgical treatment for patients with different origins of Krukenberg tumors: outcomes and prognostic factors. *Eur J Surg Oncol* 2009;35(01):92–97
- 4 Lee SJ, Bae JH, Lee AW, Tong SY, Park YG, Park JS. Clinical characteristics of metastatic tumors to the ovaries. *J Korean Med Sci* 2009;24(01):114–119
- 5 Lash RH, Hart WR. Intestinal adenocarcinomas metastatic to the ovaries. A clinicopathologic evaluation of 22 cases. *Am J Surg Pathol* 1987;11(02):114–121
- 6 Lee KC, Lin H, ChangChien CC, et al. Difficulty in diagnosis and different prognoses between colorectal cancer with ovarian metastasis and advanced ovarian cancer: An empirical study of different surgical adoptions. *Taiwan J Obstet Gynecol* 2017;56(01):62–67
- 7 Mori Y, Nyuya A, Yasui K, et al. Clinical outcomes of women with ovarian metastases of colorectal cancer treated with oophorectomy with respect to their somatic mutation profiles. *Oncotarget* 2018;9(23):16477–16488
- 8 Mason MH III, Kovalcik PJ. Ovarian metastases from colon carcinoma. *J Surg Oncol* 1981;17(01):33–38
- 9 Herrera-Ornelas L, Mittelman A. Results of synchronous surgical removal of primary colorectal adenocarcinoma and ovarian metastases. *Oncology* 1984;41(02):96–100
- 10 Chung TS, Chang HJ, Jung KH, et al. Role of surgery in the treatment of ovarian metastases from colorectal cancer. *J Surg Oncol* 2009;100(07):570–574
- 11 Moll R, Robine S, Dudouet B, Louvard D. Villin: a cytoskeletal protein and a differentiation marker expressed in some human adenocarcinomas. *Virchows Arch B Cell Pathol Incl Mol Pathol* 1987;54(03):155–169