







McKittrick-Wheelock Syndrome Secondary to Rectal Adenocarcinoma

Bruno Augusto Alves Martins¹  Ana Clara Ramalho Gomes²  Maria Eduarda de Almeida Santos² 
Natascha Mourão Moreira¹  Romulo Medeiros de Almeida^{1,2}  João Batista de Sousa^{1,2} 

¹ Serviço de Coloproctologia, Hospital Universitário de Brasília, Brasília, DF, Brazil

² Faculdade de Medicina, Universidade de Brasília, Brasília, DF, Brazil

Address for correspondence Bruno Augusto Alves Martins, MSc, SQN 212, bloco B, apto. 205, Brasília, DF, Brasil 70864-020 (e-mail: brunomartins.coloprocto@gmail.com).

J Coloproctol 2022;42(2):187–189.

Abstract

Introduction McKittrick-Wheelock syndrome is a rare condition that arises from a hypersecretory state secondary to large colorectal tumors, mainly villous adenomas, leading to an electrolytic disorder associated with chronic diarrhea that usually persists for years. It is a relatively unknown disease that can lead to severe complications such as acute kidney injury, severe hyponatremia, and hypokalemia. In fact, it causes death in most untreated cases. Surgical removal of the tumor is the most successful treatment, and symptoms tend to disappear after proper management.

Case Report A 62-year-old man with a 2-year history of mucoid diarrhea preceded by abdominal pain presented with acute kidney injury, hyponatremia, and hypokalemia. A digital rectal examination and sigmoidoscopy were performed, and revealed a large laterally-spreading tumor in the rectum. Further investigation showed a rectal tubulovillous adenoma with secondary McKittrick-Wheelock syndrome. An anterior resection of the rectum with a colonic J-pouch and a diverting ileostomy were performed, and the patient improved with the resolution of the renal failure and electrolyte disturbances. The histopathological analysis revealed an invasive rectal adenocarcinoma.

Discussion McKittrick-Wheelock syndrome is a condition with a low incidence that needs early intervention and proper diagnosis. It is of extreme importance that this disease is included in the differential diagnoses for chronic diarrhea associated with an electrolytic disorder.

Keywords

- ▶ colorectal neoplasms
- ▶ colorectal surgery
- ▶ syndromes
- ▶ acute kidney injury
- ▶ electrolyte disturbance
- ▶ chronic diarrhea

Background

Originally described in 1954, McKittrick-Wheelock syndrome (MKWS) is a rare syndrome characterized by a triad of conditions, including acute kidney failure and an electrolytic disorder associated with chronic diarrhea due to an underlying

large distal colorectal tumor, most commonly a villous adenoma.^{1–3} A hypersecretory state secondary to a large villous adenoma is responsible for most of the syndrome's signs and symptoms, and its cause is due to the secretion of a large amount of fluid which overwhelms the reabsorption capacity of the colorectal mucosa.⁴

received

August 5, 2021

accepted after revision

October 25, 2021

DOI <https://doi.org/>

10.1055/s-0041-1742255.

ISSN 2237-9363.

© 2022. Sociedade Brasileira de Coloproctologia. All rights reserved.

This is an open access article published by Thieme under the terms of the Creative Commons Attribution-NonDerivative-NonCommercial-License, permitting copying and reproduction so long as the original work is given appropriate credit. Contents may not be used for commercial purposes, or adapted, remixed, transformed or built upon. (<https://creativecommons.org/licenses/by-nc-nd/4.0/>)

Thieme Revinter Publicações Ltda., Rua do Matoso 170, Rio de Janeiro, RJ, CEP 20270-135, Brazil

Without proper management, the mortality rate of this condition can reach 100%.⁵ However, a correct diagnosis associated with immediate treatment can completely reverse the symptoms. The recommended management includes the surgical removal of the tumor.⁶

In view of the clinical severity of this syndrome and its relatively uncommon association with malignant tumors, the present work describes a rare case of a 62-year-old man diagnosed with rectal adenocarcinoma associated with MKWS.

Case Report

A 62-year-old man presented with a 2-year history of mucoid diarrhea, which occurred up to 10 times per day and was preceded by abdominal pain. He denied hematochezia and weight loss. He reported that, 3 months before, he started having migratory cramps and nausea. He also had a history of smoking (20 cigarettes per day for 25 years; quit 20 years ago) and use of alcohol (quit 2 years ago). He was admitted to an emergency service due to complaints of nausea and migratory cramps associated with the chronic diarrhea. He had a heart rate of 150 bpm and a blood pressure of 90/65 mmHg. Laboratory tests revealed a potassium level of 2.8 mEq/L, a calcium level of 11.1 mg/dL, a sodium level of 127 mEq/L, a urea level of 226 mg/dL, a creatinine level of 4.3 mg/dL, a hemoglobin level of 18.8 g/dL, and a red blood cell count of 56.7%. The patient was diagnosed with electrolyte disturbance, dehydration and acute renal failure (ARF). He remained hospitalized for five days, and was referred to a specialist for further care.

A digital rectal examination revealed a tumor 6 cm from the anal margin. Flexible sigmoidoscopy showed a polypoid lesion of the villous surface, characterized by lateral growth and located from the first Houston valve to the rectosigmoid transition. The histopathology revealed a tubulovillous adenoma with high-grade dysplasia.

An abdominal computed tomography (CT) scan showed parietal, endophytic, asymmetric and irregular thickening of the upper rectum, extending 112 mm craniocaudally, associated with a stretched lumen due to the presence of liquid material (→ **Figure 1**). A tridimensional endorectal ultrasound scan showed an area of mixed echogenicity occupying approximately 85% of the circumference of the middle and lower rectum. No growth beyond the mucosa and no spread

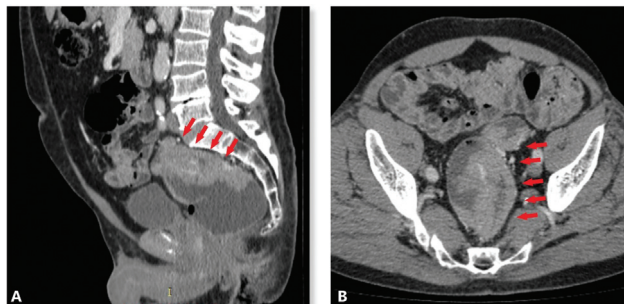


Fig. 1 Abdominal CT scan showing a large rectal tumor. (A) Sagittal view. (B) Axial view.

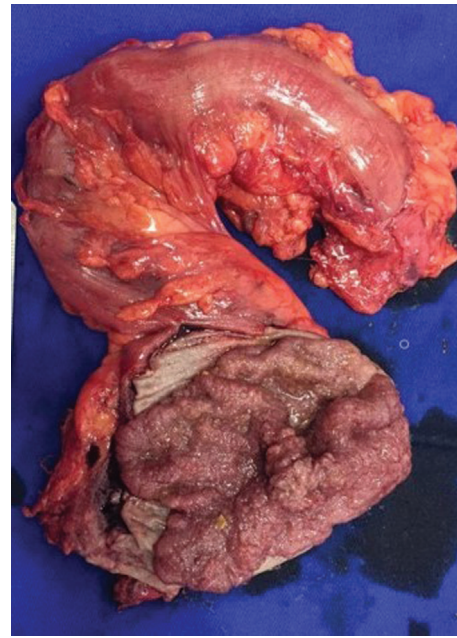

Fig. 2 Macroscopic appearance of the rectal tumor.

of metastases to nearby lymph nodes were identified (uTis uN0). Longitudinally, the lesion measured more than 6 cm, and its lower extremity was 37 mm above the posterior plane of the puborectal muscle.

Considering the typical clinical presentation and the findings of acute kidney injury and electrolyte disturbances associated with the patient's rectal neoplasia, MKWS was diagnosed. An open low anterior resection of the rectum was performed with a colonic J-pouch and a diverting loop ileostomy (→ **Figure 2**). In the postoperative period, he developed a pelvic abscess which had to be drained through an exploratory laparotomy. Closure of the ileostomy was performed after 18 months, and the patient remained asymptomatic, with normalization of the renal function and electrolytes, and without signs of tumor recurrence. The histopathological results revealed an invasive rectal adenocarcinoma with submucosal invasion (pathological staging pT1pN0).

Discussion

The case herein reported draws attention to a rare and potentially deadly condition that is typically associated with large distal colorectal adenomas, although it may also occur in the presence of underlying adenocarcinomas.⁷

First described in 1954, MKWS is characterized by a long latent phase of mucous diarrhea followed by an acute phase of severe electrolyte disturbance, dehydration, and prerenal acute kidney failure secondary to a hypersecretory adenoma.⁸

Although the exact pathophysiology of the depletion syndrome has not been completely explored, studies^{4,7,9,10} have shown that the large surface area of the tumor probably leads to an increase in the secretion of fluid, mainly because of the overexpression of prostaglandin E2 (it has been reported that cyclooxygenase 2 [COX-2] expression is significantly higher in tubulovillous adenomas), which overwhelms the ability of the

remaining normal colorectal mucosa to reabsorb the extra fluid. The distal location of the tumor makes it difficult for an adequate compensatory reabsorption mechanism to occur, causing watery diarrhea and volume depletion.

McKittrick-Wheelock syndrome is an uncommon disease that usually affects elderly men and initially manifests as chronic watery diarrhea, with a median stool frequency of 10 times within 24 hours. A long duration of symptoms is another characteristic feature of this syndrome, and patients commonly have symptoms for more than 24 months.⁸ With the progression of the electrolytic disorder, which is worsened by fluid loss through the diarrhea, MKWS can lead to acute kidney failure, severe hyponatremia, and hypokalemia, and patients usually present with a history of multiple hospital admissions.¹

It has been indicated that more severe syndromes can develop with larger and more distal adenomas, and severe cases may present with complications such as azotemia and coma. The diagnostic delay can be very harmful, and can provoke chronic renal failure and/or cardiac arrhythmias.^{1,2}

McKittrick-Wheelock syndrome is frequently related to a villous adenoma; however, rarely, it can be secondary to malignant tumors. Malik et al.⁷ (2016) reviewed the features of 35 cases of MKWS, and reported that 22 had a villous adenoma, 8 cases had an underlying adenocarcinoma, 1 case had a hyperplastic polyp, and 1 case had a neuroendocrine tumor of the rectum with liver metastasis.⁷

Important steps in the management include thorough history taking and physical examination. Because it is a rare condition, there may be a delay in the diagnosis, and other diagnoses are usually considered first. However, to avoid patients reaching the decompensation stage, some studies^{8,9,11} suggest that clinicians who identify large tumors on endoscopy should promptly ask for recent renal function and electrolyte laboratory values and consider this syndrome as a differential diagnosis.

Recommendations at admission include aggressive fluid resuscitation to match the losses through the rectum. The early use of flexible sigmoidoscopy may also reveal a definitive diagnosis in 99% of cases, and a CT of the abdomen and pelvis can be a useful tool as part of the preoperative workup once renal function has been established. In terms of medical management, indomethacin and octreotide have been used to reduce fluid losses while awaiting surgery.^{7,8,12}

Surgical alternatives are most effective when treating the underlying disease, and an anterior resection is the most commonly used approach. Complete removal of the lesion prevents the progression of the tumor and resolves the depletion syndrome. Some authors^{13,14} have reported successful outcomes obtained with laparoscopic rectal resections and intersphincteric rectal resections.

Despite its low incidence, especially when associated with malignancy, MKWS is an important disease of which all clinicians must be aware. It should be included in the differential diagnoses of chronic diarrhea associated with an electrolytic disorder, mostly because the correct diagnosis

and proper management enables the complete reversal of symptoms and can be life-saving in most cases.

Funding statement

The present research did not receive any specific grants from funding agencies in the public, commercial, or nonprofit sectors.

Conflict of Interests

The authors have no conflict of interests to declare.

References

- McKittrick LS, Wheelock FC. Carcinoma of the colon. 1954. *Dis Colon Rectum* 1997;40(12):1494–1495, discussion 1495–1496. Doi: 10.1007/BF02070718
- Kapoor S. McKittrick-Wheelock syndrome: an often, overlooked complication of rectal adenomas. *Surg Endosc* 2014;28(07):2247–2247. Doi: 10.1007/s00464-014-3462-5
- Matsuura N, Kawano A, Tai H, Imamura T. McKittrick-Wheelock Syndrome (Electrolyte Depletion Syndrome). *Intern Med* 2017;56(09):1113–1114. Doi: 10.2169/internalmedicine.56.7925
- Hsieh M-C, Chen C-J, Huang W-S. McKittrick-Wheelock Syndrome. *Clin Gastroenterol Hepatol* 2016;14(04):e41–e42. Doi: 10.1016/j.cgh.2015.09.001
- Mois El, Graur F, Sechel R, Al-Hajjar N. McKittrick-Wheelock syndrome: a rare case report of acute renal failure. *Clujul Med* 2016;89(02):301–303. Doi: 10.15386/cjmed-536
- Chen Y-H, Kang J-C, Lai H-J. Rectal Villous Adenoma with McKittrick-Wheelock Syndrome: Report of a Rare Case. *Viszeralmedizin* 2013;29(01):55–58. Doi: 10.1159/000348494
- Malik S, Mallick B, Makkar K, Kumar V, Sharma V, Rana SS. Malignant McKittrick-Wheelock syndrome as a cause of acute kidney injury and hypokalemia: Report of a case and review of literature. *Intractable Rare Dis Res* 2016;5(03):218–221. Doi: 10.5582/irdr.2016.01011
- Orchard MR, Hooper J, Wright JA, McCarthy K. A systematic review of McKittrick-Wheelock syndrome. *Ann R Coll Surg Engl* 2018;100(08):1–7. Doi: 10.1308/rcsann.2018.0184
- Agnes A, Novelli D, Doglietto GB, Papa V. A case report of a giant rectal adenoma causing secretory diarrhea and acute renal failure: McKittrick-Wheelock syndrome. *BMC Surg* 2016;16(01):39. Doi: 10.1186/s12893-016-0153-2
- Winstanley V, Little MA, Wadsworth C, Cohen P, Martin NM. The McKittrick-Wheelock syndrome: a case of acute renal failure due to neoplastic cholera. *Ren Fail* 2008;30(04):469–473. Doi: 10.1080/08860220801964277
- López-Fernández J, Fernández-San Millán D, Navarro-Sánchez A, Hernández Hernández JR. McKittrick-Wheelock syndrome: A rare cause of metabolic coma. *Gastroenterol Hepatol* 2017;40(05):349–351. Doi: 10.1016/j.gastre.2016.04.014(English Edition)
- Kagan MD, Schmidt K, Sangha G. Indomethacin therapy effective in a patient with depletion syndrome from secretory villous adenoma. *BMJ Case Reports*. Published online February 10, 2017;bcr2016217211 Doi: 10.1136/bcr-2016-217211
- Bruno A, Chimienti D, Montanaro A, et al. The mckittrick-wheelock syndrome: a rare cause of severe hydroelectrolyte disorders and acute renal failure. *Case Rep Nephrol* 2011;2011:765689. Doi: 10.1155/2011/765689
- Targarona EM, Hernandez PM, Balague C, et al. McKittrick-Wheelock syndrome treated by laparoscopy: report of 3 cases. *Surg Laparosc Endosc Percutan Tech* 2008;18(05):536–538. Doi: 10.1097/SLE.0b013e31818135ad