

# *Campsiandra laurifolia* Reduces Oxidative Stress and Inflammation in Rats with Ulcerative Colitis

Sandielly Rebeca Benitez da Fonseca<sup>1,2,\*</sup> Lucas Petitemberte de Souza<sup>3</sup>  
 Henrique Sarubbi Fillmann<sup>4</sup> Renata Minuzzo Hartmann<sup>2</sup> Josieli Raskopf Colares<sup>2</sup>  
 Elizângela Gonçalves Schemitt<sup>2</sup> Marilda da Silva Brasil<sup>2,5</sup> Edna Sayuri Suyenaga<sup>6</sup>  
 Norma Anair Possa Marroni<sup>1,2,5</sup>

<sup>1</sup> Post-graduation Program in Medical Sciences, Universidade Federal do Rio Grande do Sul (UFRGS), Porto Alegre, RS, Brazil

<sup>2</sup> Experimental Laboratory of Pulmonary Sciences and Inflammation, Hospital de Clínicas de Porto Alegre (HCPA), Porto Alegre, RS, Brazil

<sup>3</sup> Post-graduation Program in Biotechnology, Universidade Federal de Pelotas (UFPEL), Pelotas, RS, Brazil

<sup>4</sup> School of Medicine, Pontifícia Universidade Católica do Rio Grande do Sul (PUCRS), Porto Alegre, RS, Brazil

<sup>5</sup> Post-graduation Program in Biological Sciences - Physiology, Universidade Federal do Rio Grande do Sul (UFRGS), Porto Alegre, RS, Brazil

<sup>6</sup> Health School, Universidade do Vale do Rio dos Sinos (UNISINOS), São Leopoldo, RS, Brazil

Address for correspondence Sandielly Rebeca Benitez da Fonseca, Ramiro Barcelos, 2400, Santa Cecília, Porto Alegre, RS, 90035-002, Brazil (e-mail: sandielly.benitez@gmail.com).

J Coloproctol 2022;42(3):238–244.

## Abstract

Ulcerative colitis (UC) affects the mucosa and submucosa of the large intestine. One of the mechanisms involved in its etiology is oxidative stress (OS), directly involved in the inflammatory process characteristic of UC. The *Campsiandra laurifolia*, known as acapurana, was described as possessing antioxidant properties. We used 24 male Wistar rats, divided into control (CO), control + acapurana (CO + A), colitis (CL), and colitis + acapurana (CL + A) groups. This study performed histological analysis, measuring anal sphincter pressure (ASP) and lipoperoxidation (LPO). The activity of the antioxidant enzyme superoxide dismutase (SOD) and glutathione (GSH) levels were evaluated. The expression of the nuclear factor kappa B (NFκB) and inducible nitric oxide synthase (iNOS) was analyzed by immunohistochemistry. The statistical analysis used was the one-way analysis of variance (ANOVA), followed by the Student-Newman-Keuls test; values were expressed as mean ± standard error, and the significance level was  $p < 0.05$ . In the animals of the CL group, we observed the destruction of the crypts and the presence of mucosal ulcers, edema, and submucosal inflammatory infiltrate, as well as increased damage to the intestinal mucosa, reduced ASP, increased LPO and SOD activity, reduced GSH levels, and increased expression of NFκB and iNOS. The administration of *C. laurifolia* in the CL + A group was shown to cause regeneration of crypts, reduction of inflammatory infiltrate, reduction of damage to the intestinal

## Keywords

- ▶ ulcerative colitis
- ▶ antioxidant
- ▶ anti-inflammatory
- ▶ *campsiandra laurifolia*

received  
 April 15, 2022  
 accepted after revision  
 July 6, 2022

DOI <https://doi.org/10.1055/s-0042-1755346>.  
 ISSN 2237-9363.

© 2022. Sociedade Brasileira de Coloproctologia. All rights reserved.

This is an open access article published by Thieme under the terms of the Creative Commons Attribution-NonDerivative-NonCommercial-License, permitting copying and reproduction so long as the original work is given appropriate credit. Contents may not be used for commercial purposes, or adapted, remixed, transformed or built upon. (<https://creativecommons.org/licenses/by-nc-nd/4.0/>)

Thieme Revinter Publicações Ltda., Rua do Matoso 170, Rio de Janeiro, RJ, CEP 20270-135, Brazil

mucosa, increase in ASP, and reduction in LPO with the restoration of SOD activity and GSH levels. The immunohistochemistry of NFκB and iNOS was significantly reduced. Therefore, the *C. laurifolia* aqueous extract appears to exert an antioxidant and anti-inflammatory effect in rats with AA-induced colitis.

## Introduction

Ulcerative colitis (UC) is a chronic inflammatory disease that affects the mucosa and submucosa of the large intestine; it could be more limited, affecting only the rectum, or in a more extensive form when it involves the entire colon. Some typical features of the disease are crypt abscesses, inflammatory infiltrates, superficial ulcerations, edema, necrosis, and hemorrhage. Several mechanisms may be involved in the etiology of UC, such as genetic, environmental, dietary factors, inflammatory mediators, and oxidative stress (OS).<sup>1–6</sup>

The induction of experimental colitis in rats by AA instillation by enema is a reproducible model that allows the observation of many similarities with UC in humans, including histological, metabolic, and inflammatory infiltrate by macrophages and neutrophils in the colon mucosa, in addition to increased production of inflammatory mediators and reactive oxygen species (ROS).<sup>5,7–10</sup>

The OS process is established from an imbalance between the number of oxidizing substances and the antioxidant capacity, and this imbalance can be caused by the high production of ROS or by the reduction of antioxidant defenses.<sup>11,12</sup>

Experimental studies have shown a correlation between nitric oxide (NO) and anal sphincter pressure (ASP) reduction through an inhibitory action on smooth muscles, which causes anal sphincter relaxation. An important source of NO is the inducible nitric oxide synthase (iNOS) enzyme, which is induced by proinflammatory cytokines and has a fundamental role in the inflammatory process.<sup>7,13,14</sup>

The nuclear factor kappa B (NFκB) is present in the cytoplasm in its inactive form and, when activated, migrates to the nucleus and triggers the transcription of genes involved in the inflammatory response. Studies have shown that NFκB causes an increase in inflammatory mediators such as interleukins, TNF-α, COX-2, and iNOS.<sup>7,13,15</sup>

The *Campsiandra laurifolia*, popularly known as acapurana, is used to treat abscesses, impingement, uterine infections, malaria, ulcers, arthritis, rheumatism, and especially lesions caused by leishmaniasis, as it reduces its inflammatory reactions.<sup>16–20</sup> Recently, a study showed that the aqueous extract obtained from the leaves of *C. laurifolia* has saponins, tannins, and flavonoids, as well as a high content of phenolic compounds and total tannins, a small content of total flavonoids, and a high antioxidant potential, surpassing the potential quercetin antioxidant.<sup>21</sup>

Taking into account the high antioxidant potential of the aqueous extract of *C. laurifolia* already evidenced, as well as the lack of information about its toxicity, we aimed to

analyze the antioxidant effect of the 25 mg/kg dose in rats' UC, as well as analyze the expression of inflammatory mediators iNOS and NFκB in these animals.

## Methodology

Colitis induction was performed using an enema containing 4 ml of 4% AA, this model being an adaptation of what was described by Yamada et al. and Tannahill et al. The animals in the control groups received 0.9% saline solution by enema in a volume of 4 mL.<sup>22,23</sup>

A total of 24 male Wistar rats, 60 days old and weighing 350 g, were used. The animals were purchased according to the specifications of the Animal Experimentation Unit from registered suppliers of the Hospital de Clínicas de Porto Alegre (HCPA). The animals were kept on a 12-hour light/dark cycle, at a temperature of 22 ± 2°C, and water and feed were freely given. They were randomly divided into 4 experimental groups, each with 6 animals: in the rats in the control (CO) and control + acapurana (CO + A) groups, an enema with 0.9% saline solution was performed, whereas in the animals in the colitis (CL) and colitis + acapurana (CL + A) groups, enemas were performed to induce colitis with AA. The aqueous extract of *C. laurifolia* hulls was provided by the Phytochemistry Laboratory of the Lutheran University of Brazil (Canoas, RS, Brazil). The extract (25 mg/kg) was administered orally by gavage, 24 and 48 hours after the enema in animals in the CO + A and CL + A groups.

On the third day after colitis induction, the animals were anesthetized with isoflurane (4–5% induction and 2–3% maintenance) diluted in 100% O<sub>2</sub> (O<sub>2</sub> flow = 0.5 L/min), and 8 cm were removed from the distal portion of the large intestine, with a part of the tissue immersed in 10% formalin for histological and immunohistochemical analyses. The other portion was frozen at -80°C for further analysis. All procedures performed were approved by the Comissão de Ética no Uso de Animais of the HCPA under number 2019-0196, and were in accordance with the established by the Comitê de Ética em Pesquisa of the Grupo de Pesquisa e Pós-Graduação (GPPG) of the HCPA, and following the recommendations of the European Animal Research Association (EARA).

## Histological Analysis

Histological analysis was performed with the material included in paraffin blocks, 3 μm-thick sections were made with a microtome, and slides were produced that underwent staining techniques with hematoxylin-eosin (HE). The changes observed microscopically were classified according to the following scale: 0 = no damage and mucosal

inflammatory infiltrate; 1 = presence of mild damage and little inflammatory infiltrate in the mucosa; 2 = presence of damage and moderate inflammatory infiltrate in two or more areas of the mucosa; 3 = damage and severe inflammatory infiltrate in the mucosa, with ulceration and presence of edema and hemorrhage in the submucosa. The slides were analyzed in a BX51 binocular microscope (Olympus, Shinjuku, Tokyo, Japan) at 100x magnification.

### Anal Sphincter Pressure

The ASP levels were measured before euthanasia, and the animals were anesthetized at the time of the procedure. Three consecutive measurements were taken using an anorectal manometer (Proctosystem-Viotti, São Paulo, SP, Brazil) with a balloon catheter, and the mean between the three values was calculated for the pressure result, which was expressed in cmH<sub>2</sub>O.

### Intestinal Homogenization

For tissue homogenate, 5ml of phosphate buffer (1.15% KCl) per gram of tissue, and phenylmethylsulfonyl fluoride (PMSF) at a concentration of 100 mM in isopropanol (10 µL/ml of KCl) were used. A homogenizer (QIAGEN GmbH, Hilden, NRW, Germany) was used for one minute to obtain the tissue homogenate, subsequently centrifuged for 10 minutes at 3000 rpm in a refrigerated centrifuge. The supernatant was removed and stored in a freezer at -80°C for biochemical analysis.<sup>24</sup>

### Proteins

Protein concentration was determined by the Bradford method, using bovine albumin as a standard. The samples were analyzed in a spectrophotometer at 595 nm, and the results were expressed in mg/ml and used to analyze lipoperoxidation, superoxide dismutase activity, and glutathione levels.<sup>25</sup>

### Lipoperoxidation

Lipoperoxidation was evaluated by analyzing thiobarbituric acid reactive substances (TBARS). A mixture of trichloroacetic acid (TCA) 10% and thiobarbituric acid (TBA) 0.67% was added to the homogenate. The samples were heated to 100°C and after cooled, and butanol was added to extract the pigment formed from the reaction of TBA with the lipoperoxidation products, and centrifugation was carried out at 3:00 PM. The supernatant containing the colored product was analyzed in a spectrophotometer at 535 nm. The concentration of TBARS was expressed in nmol per milligram of protein.<sup>26</sup>

### Superoxide Dismutase Activity and Glutathione Levels

The analysis of the superoxide dismutase activity was made through the enzyme's ability to inhibit the reaction of the superoxide anion radical with adrenaline. The adrenochrome is formed when adrenaline oxidation occurs, which is detected spectrophotometrically at 480 nm. Results were expressed in superoxide dismutase (SOD) units per milligram of protein (USOD/mg prot).<sup>27</sup>

A phosphate buffer and dithionitrobenzoic acid (DTNB) solution measured glutathione (GSH) levels in tissue homogenates. The spectrophotometer measured the GSH level at 412 nm in micromol per milligram of protein.<sup>28</sup>

### Immunohistochemical Analysis

The expression of inflammatory mediators NFκB and iNOS was determined by immunohistochemical analysis. Sections of the material included in paraffin blocks were obtained; these sections were deparaffinized and rehydrated. Afterwards, antigen recovery and blocking of endogenous peroxidase activity were performed. The slides were incubated with monoclonal antibodies to NFκB and iNOS (Santa Cruz Biotechnology, Santa Cruz, CA, USA). After washing them with buffer, we incubated secondary anti-mouse IgG antibodies (Santa Cruz Biotechnology, Santa Cruz, CA, USA) on the slides.

The results were evaluated through a microscope equipped with a digital camera to capture images using the Qcapture (Teledyne Qimaging, Tucson, AZ, USA) software, version 2.9.13. The quantification of NFκB and iNOS expression was performed with the Adobe Photoshop (Adobe Systems Inc., Mountain View, CA, USA) software, version CS3, which quantifies the expression of positive pixels.

### Statistical Analysis

Statistical analysis was performed with the GraphPad InStat (GraphPad Software, San Diego, CA, USA) software, version 3.0. The one-way analysis of variance (ANOVA) test was used to analyze the results' variance, followed by the Student-Newman-Keuls test for parametric data. The results are expressed as mean ± standard error, and the adopted significance level was at least 5% ( $p < 0.05$ ).

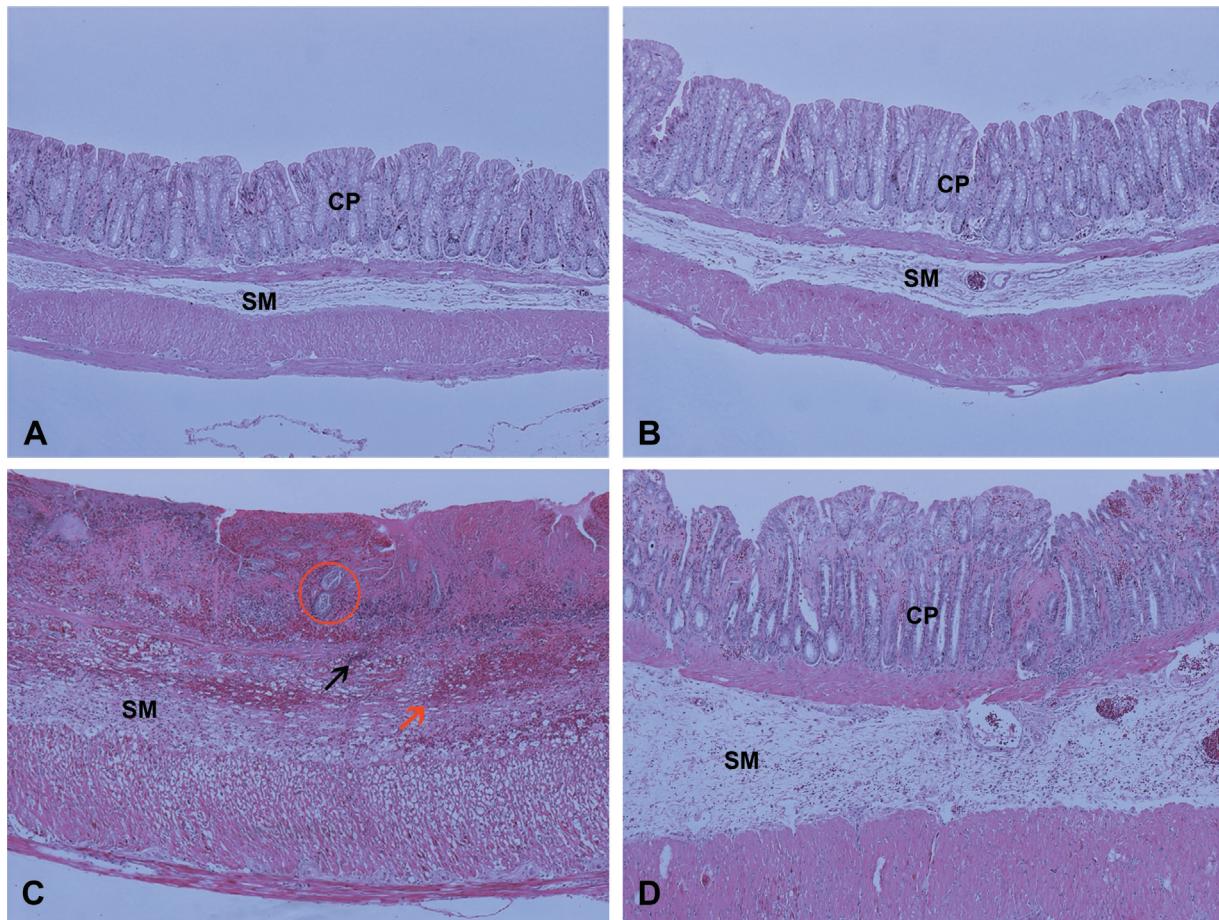
## Results

### Histological Analysis

In the histological slides of the animals in the CO and CO + A groups (► **Figs. 1a and -1b**), it was possible to observe the typical architecture of the intestine. The animals in the CL group (► **Fig. 1c**) showed destruction and abscess in the crypts, inflammatory infiltrate, edema, and hemorrhage in the submucosa. In the animals in the CL + A group (► **Fig. 1d**), it was possible to visualize crypt regeneration, reduction of inflammatory infiltrate, and hemorrhage. The administration of the aqueous extract of *C. laurifolia* significantly ( $p < 0.01$ ) reduced the damage to the intestinal mucosa ( $p < 0.01$ ), as well as the edema and the inflammatory infiltrate in the CL + A group, when compared with the CL group (► **Table 1**).

### Anal Sphincter Pressure

When measuring ASP, a significant reduction ( $p < 0.01$ ) was observed in the CL group when compared with the CO and CO + A groups. The same parameter, when analyzed in the CL + A group, showed a significant increase ( $p < 0.05$ ) concerning the CL group, with the reestablishment of the ASP in the animals treated with *C. laurifolia* (► **Table 1**).



**Fig. 1** Histological analysis of the intestine of healthy rats with colitis and treated with *C. laurifolia*. **Notes:** A - control (CO); B - control + acapurana (CO + A); C - colitis (CL); D - colitis + acapurana (CL + A). Magnification 100x. **Legend:** CP – crypts; SM – submucosa; black arrow – inflammatory infiltrate; red arrow – hemorrhage; red circle – abscess in the crypts. **Source:** Authors (2021).

**Lipoperoxidation**

The evaluation of lipoperoxidation by TBARS showed a significant increase ( $p < 0.01$ ) in the CL group, when compared with the CO and CO + A groups. It also revealed a significant reduction ( $p < 0.01$ ) in the CL + A group, when compared with the CL group (→ **Table 1**).

**Superoxide Dismutase Activity and Glutathione Levels**

The SOD activity increased significantly ( $p < 0.01$ ) in the CL group, when compared with the control groups, whereas in the colitis group that received *C. laurifolia* treatment (CL + A), there was a significant reduction ( $p < 0.01$ ) of the enzyme

activity when compared with the CL group (→ **Table 1**). In the evaluation of GSH levels, it was possible to observe a significant reduction ( $p < 0.01$ ) in the CL group, when compared with the CO and CO + A groups. Through this analysis, we also observed a significant increase ( $p < 0.01$ ) in the levels of GSH in the CL + A group, when compared with the same parameter in the CL group (→ **Table 1**).

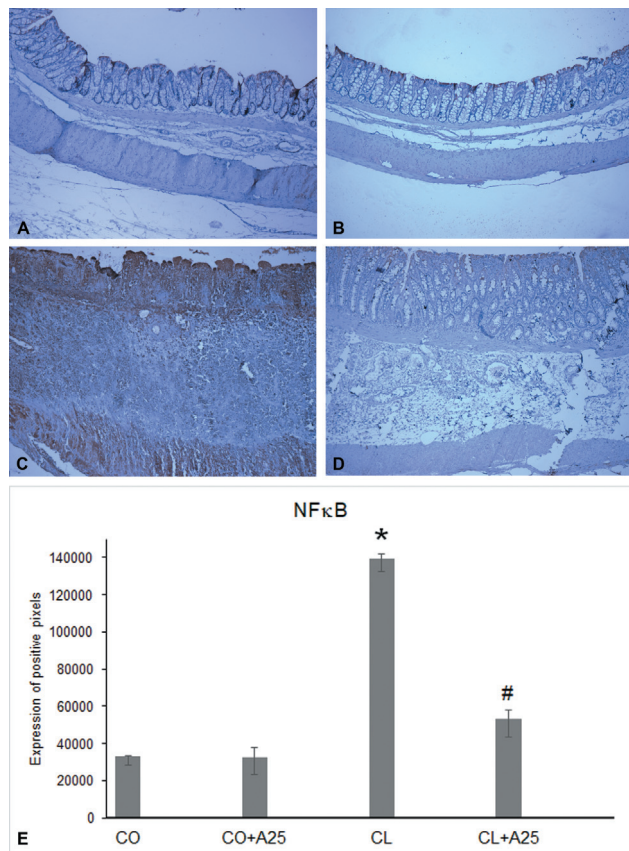
**Immunohistochemical Analysis**

In the evaluation of NFκB by immunohistochemistry, it was possible to observe a low marking, visible by the brown coloration, in the CO and CO + A groups (→ **Fig. 2a and -2b**); in

**Table 1** Microscopic damage rating values, ASP, TBARS, SOD activity, and GSH levels

Group	Histological Score	ASP (cmH <sub>2</sub> O)	TBARS (nmol/mg prot)	SOD (USOD/mg prot)	GSH (μmol/mg prot)
CO	0 ± 0	30.4 ± 1.3	0.34 ± 0.03	6.18 ± 1.17	0.088 ± 0.005
CO + A	0 ± 0	30.6 ± 2,5	0.3 ± 0.03	5.18 ± 1.41	0.084 ± 0.002
CL	3 ± 0*	13.7 ± 0.7*	0.88 ± 0.12*	12.78 ± 1.63*	0.046 ± 0.005*
CL + A	1.5 ± 0.22#	23.0 ± 0.7#	0.51 ± 0.1#	3.9 ± 1.4#	0.089 ± 0.01#

**Abbreviations:** ASP, anal sphincter pressure; TBARS, thiobarbituric acid reactive substances; SOD, superoxide dismutase; GSH, glutathione. **Notes:** \* Statistically significant difference between the CL group with the CO and CO + A groups. # Statistically significant difference between CL + A and CL group. **Source:** Authors (2021).

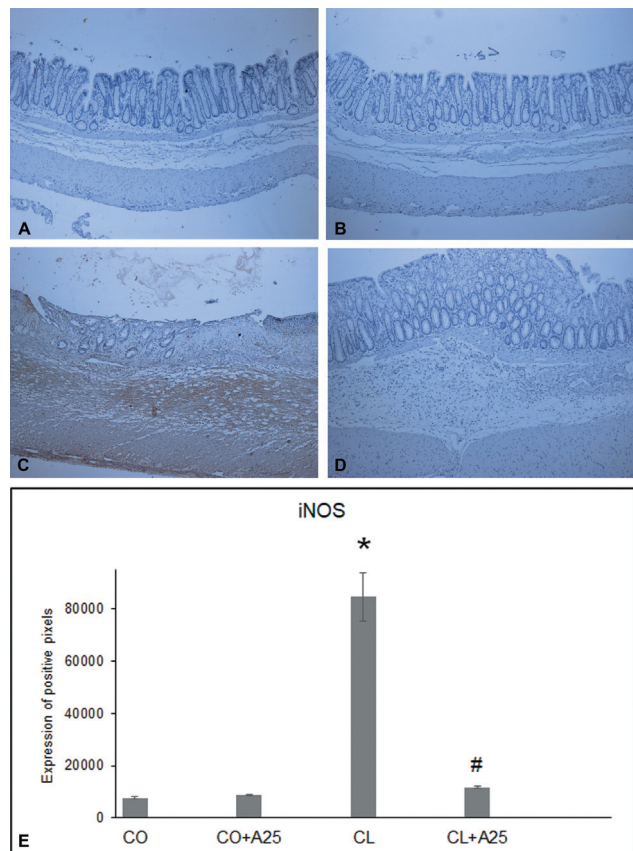


**Fig. 2** The NFκB immunohistochemical analysis. **Notes:** A - control (CO); B - control + acapurana (CO + A); C - colitis (CL); D - colitis + acapurana (CL + A). Magnification 100x. E - NFκB expression. \*Statistically significant difference ( $p < 0.01$ ) of the CL group regarding the CO and CO + A groups; #Statistically significant difference ( $p < 0.01$ ) of the CL + A group compared with the CL group. **Source:** Authors (2021).

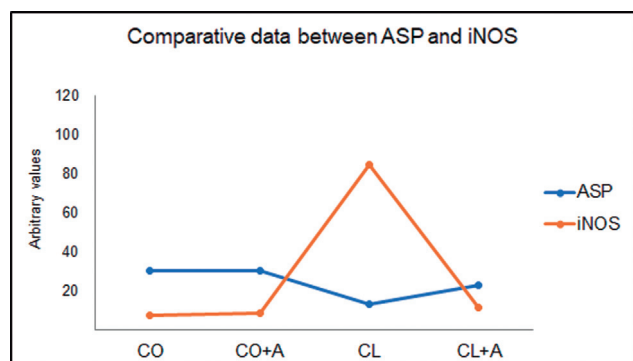
the CL group (►Fig. 2c), there was intense marking; and in the CL + A group, treated with *C. laurifolia* extract, the marking visibly reduced (►Fig. 2d). The quantification of NFκB expression (►Fig. 2e) showed that in the CL group, there was a significant increase ( $p < 0.01$ ) compared with the control groups (CO and CO + A), and this expression was significantly reduced ( $p < 0.01$ ) when the animals were treated with *C. laurifolia*.

In the CL group (►Fig. 3c), intense labeling for the iNOS enzyme was observed through immunohistochemistry, whereas the CO and CO + A groups (►Fig. 3a and -3b) showed low labeling for the enzyme. The treatment with *C. laurifolia* reduced the positive labeling for iNOS in the CL + A group (►Fig. 3d). By quantifying the expression of iNOS (►Fig. 3e), it was found that there was a significant increase ( $p < 0.01$ ) in the colitis group, when compared with the control groups, and that when *C. laurifolia* was administered in the CL + A group, there was a significant reduction ( $p < 0.01$ ) of the expression of this enzyme compared with that observed in the colitis group.

Through simple correlation analysis between ASP and iNOS expression, it was found that there is a negative correlation between the two variables. That is, as iNOS expression increases, ASP decreases (►Fig. 4).



**Fig. 3** The iNOS immunohistochemical analysis. **Notes:** A - control (CO); B - control + acapurana (CO + A); C - colitis (CL); D - colitis + acapurana (CL + A). Magnification 100x. E - iNOS expression. \*Statistically significant difference ( $p < 0.01$ ) of the CL group compared with the CO and CO + A groups. #Statistically significant difference ( $p < 0.01$ ) of the CL + A group compared with the CL group. **Source:** Authors (2021).



**Fig. 4** Simple correlation analysis between ASP and iNOS expression. **Note:** Control (CO); Control + Acapurana (CO + A); Colitis (CL); Colitis + Acapurana (CL + A). Significance level was  $p < 0.05$ ; Correlation coefficient ( $r$ ) = -0.9893. **Source:** Authors (2021).

## Discussion

Although the etiology of UC is not fully known, it is known that OS is a mechanism directly linked to the inflammatory process present in this disease. Chemical models of colitis are widely used and can be adapted to acute or chronic models,

with AA, TNBS, and SDS being the main inducing agents used. The AA colitis induction model was used for this study to reproduce many acute features of UC in humans.<sup>7-10</sup>

A study examining the antioxidant properties an aqueous extract of *C. laurifolia* shown the ability to regrow intestinal crypts, reduce inflammatory infiltrates and edema, and increase in the anal sphincter pressure and GSH levels. Additionally, it reduces lipoperoxidation and increases superoxide dismutase activity in rats treated with AA-induced colitis, and given 50 mg/kg of the extract.<sup>21</sup> Based on the results obtained in the study, as mentioned above, we propose investigating whether a dose of 25 mg/kg of the same extract would provide the observed antioxidant effects, and whether it was capable of reducing the expression of inflammatory markers involved in the pathophysiology of UC.

When examining the histology of the CO and CO + A groups under the microscope, it can be seen that the crypts and submucosa are preserved, and the intestinal mucosa is intact. In the CL group, inflammatory focuses and severe lesions in the intestinal mucosa are observed. In the colitis group treated with *C. laurifolia* (CL + A), regeneration of the crypts, reduction of hemorrhage, edema, and inflammatory infiltrate can be seen, with a 50% reduction in the histopathological score of bowel damage compared with the CL group. We found these same results in other studies using antioxidants. Filmann et al. used glutamine to treat AA-induced colitis, and Helal and Elhameed used soursop in their studies. Finally, Souza et al. used 50 mg/kg of *C. laurifolia* extract and found no difference between the two doses.<sup>7,21,29</sup>

Nitric oxide (NO) acts in smooth muscle relaxation, as the anal sphincter is composed of smooth muscle, NO is directly linked to ASP. Previous studies have shown that in AA-induced colitis, NO production increases, causing anal sphincter relaxation, a reduction in ASP, and loss of control over evacuation.<sup>7,13</sup> When *C. laurifolia* extract was administered to animals with colitis, ASP increased in 68.3%, which is similar to the increase observed in the CO + A group. The ASP levels were reduced by 55.2% in the CL group, when compared with the control group. According to these results, we found the 25 mg/kg dose to be as effective in restoring ASP of rats with colitis as the 50 mg/kg dose used in the study.<sup>21</sup>

A significant increase of 173.9% in lipoperoxidation (LPO) in the intestine was measured using the TBARS technique in animals in the colitis group (CL) compared with the control groups. Moreover, ► **Fig. 1c** illustrates tissue degradation due to the increase in LPO, which leads to the destruction of crypts and cell structures. When animals with colitis were treated with *C. laurifolia*, there was a significant reduction of 41.8% in LPO, when compared with the CL group. Souza et al. found a reduction in LPO in the intestine of animals with colitis treated with *C. laurifolia*, which can be attributed to the composition of the extract rich in flavonoids and phenolic compounds, since these substances can reduce free radicals due to their free radical scavenger action.<sup>21</sup>

The SOD enzyme activity showed a significant increase of 125% in the CL group, compared with the enzyme activity in the control groups. The observed increase in enzyme activity

may result from an attempt to reduce the damage caused by the AA. When animals with colitis were treated with *C. laurifolia*, there was a significant reduction of 70% in SOD enzyme activity, when compared with animals in the CL group, approaching the values found in the control groups. This result agrees with what was observed by Souza et al., who used the 50 mg/kg dose of *C. laurifolia* aqueous extract to treat AA-induced UC, and our results demonstrate that half of this dose was also successful in re-establishing SOD activity. The results obtained in the CL + A group can be attributed to the presence of flavonoids and tannins in the aqueous extract of *C. laurifolia*, as they are capable of scavenging free radicals reorganizing the intestinal mucosa.<sup>21,30</sup>

Analyzing the GSH levels, a significant reduction of 47% in the CL group is observed, compared with the controls. This data corroborates the experimental findings observed in other studies, and the reduction in GSH levels may be due to an increase in OS. In the CL + A group, there was a significant 96% increase in GSH levels, compared with the CL group. By evaluating this data, along with lipoperoxidation results, it is believed that the antioxidant action of the *C. laurifolia* extract reduced the OS, causing a lower consumption of GSH, keeping its levels similar to those observed in the CO and CO + A groups. The results obtained in this work corroborate the data obtained in other studies such as the one performed by Hartmann et al., in which *Boswellia serrata* was used as an antioxidant in the treatment of AA-induced colitis, as well as with the results observed by Souza et al. who administered the aqueous extract of *C. laurifolia* at a dose of 50 mg/kg in rats with colitis.<sup>8,21</sup>

Through immunohistochemical analysis, it was observed that there was a significant increase of 348% in the expression of NFκB in animals with colitis induced by AA, compared with animals in the control groups, and that when the *C. laurifolia* extract was administered to animals with colitis, this expression reduced 63% regarding the CL group.

In the present study, we have shown that animals with colitis have an increased OS, because of an increase in reactive oxygen species (ROS), which caused a rise in NFκB expression due to ROS, which has been known to activate NFκB.<sup>7,13,15</sup> There was also a decrease in lipoperoxidation and an increase in GSH, as *C. laurifolia* at a dose of 25 mg/kg protected the intestinal mucosa in animals with colitis.

Several studies have shown that NFκB activation in animals with colitis causes an increase in other inflammatory mediators, such as iNOS, which was also investigated in this study; we found a significant increase of 921% in the CL group, compared with control groups. It was also observed that when *C. laurifolia* was administered, iNOS expression reduced to 86%, compared with the CL group, being similar to controls.<sup>30</sup> The iNOS is one of the main NO-producing enzymes, and this is directly linked to anal sphincter relaxation, so the increase in iNOS expression in animals with colitis indeed increased NO levels, and, consequently, reduced ASP. Furthermore, *C. laurifolia* reduced iNOS expression in animals from the CL + A group and, consequently, reduced NO levels, which caused an increase in ASP. This was demonstrated through the simple correlation analysis,

where it was possible to evidence that there is a negative correlation between the ASP and the expression of iNOS, being  $(r) = 0.9893$ .

## Conclusion

As a consequence of the results of this study, we could conclude that the *C. laurifolia* aqueous extract exerted an anti-inflammatory and antioxidant effect in rats with UC induced by AA, restoring the crypts, decreasing inflammatory infiltrates in the tissue, increasing the SOD, lowering LPO, and restoring superoxide dismutase enzyme activity and GSH levels, thereby restoring the intestinal mucosal architecture. It is suggested that these results are attributed to the high antioxidant and anti-inflammatory potential, as well as the high concentration of phenolic compounds, such as tannins, found in the aqueous extract of *C. laurifolia*.

### Support Sources

CAPES; CNPq; FIPE-HCPA.

### Conflict of Interests

The authors have no conflict of interests to declare.

## References

- Misiewicz JJ, Pounder RE, Venables CW. Diseases of the gut and pancreas 2th. Oxford: Blackwell Scientific Publications; 1994
- Fiocchi C. Inflammatory bowel disease: etiology and pathogenesis. *Gastroenterology* 1998;115(01):182–205
- Awaad AS, El-Meligy RM, Soliman GA. Natural products in treatment of ulcerative colitis and peptic ulcer. *J Sau Chem. Soci.* 2013; 17:101–124
- Dogan Z, Ergul B, Sarikaya M, et al. The antioxidant effect of *Echinacea angustifolia* and *Echinacea purpurea* in rat colitis model induced by acetic acid. *Bratisl Lek Listy* 2014;115(07):411–415
- Bastaki SMA, Adeghate E, Amir N, Ojha S, Oz M. Menthol inhibits oxidative stress and inflammation in acetic acid-induced colitis in rat colonic mucosa. *Am J Transl Res* 2018;10(12):4210–4222
- Bademci R, Erdoğan MA, Kara AY, Yiğittürk G, Erbaş O. Therapeutic effects of vitamin D on acetic acid-induced colitis in rats. *Acta Cir Bras* 2020;35(04):e202000404
- Fillmann H, Kretzmann NA, San-Miguel B, et al. Glutamine inhibits over-expression of pro-inflammatory genes and down-regulates the nuclear factor kappaB pathway in an experimental model of colitis in the rat. *Toxicology* 2007;236(03):217–226
- Hartmann RM, Morgan Martins MI, Tieppo J, Fillmann HS, Marroni NP. Effect of *Boswellia serrata* on antioxidant status in an experimental model of colitis rats induced by acetic acid. *Dig Dis Sci* 2012;57(08):2038–2044
- Colares JR, Schemitt EG, Hartmann RM, et al. Effect of lecithin on oxidative stress in an experimental model of rats colitis induced by acetic acid. *J Coloproctol (Rio J)* 2016;36:97–103
- Moura RM, Hartmann RM, Licks F, et al. Antioxidant effect of mesalazine in the experimental colitis model induced by acetic acid. *J Coloproctol (Rio J)* 2016;36:139–148
- Sies H. Strategies of antioxidant defense. *Eur J Biochem* 1993;215(02):213–219
- Halliwell B, Gutteridge JMC. Free radicals in Biology and Medicine 4th. Oxford Uni Press; 2007:851
- Kretzmann NA, Fillmann H, Mauriz JL, et al. Effects of glutamine on proinflammatory gene expression and activation of nuclear factor kappa B and signal transducers and activators of transcription in TNBS-induced colitis. *Inflamm Bowel Dis* 2008;14(11):1504–1513
- Hartmann RM, Fillmann HS, Martins MI, Meurer L, Marroni NP. *Boswellia serrata* has beneficial anti-inflammatory and antioxidant properties in a model of experimental colitis. *Phytother Res* 2014;28(09):1392–1398
- Wu XF, Ouyang ZJ, Feng LL, et al. Suppression of NF- $\kappa$ B signaling and NLRP3 inflammasome activation in macrophages is responsible for the amelioration of experimental murine colitis by the natural compound fraxinellone. *Toxicol Appl Pharmacol* 2014; 281(01):146–156
- Van Den Berg ME, Silva MHL. Contribuição ao Conhecimento da Flora Medicinal de Roraima. *Acta Amazon* 1988;18:23–35
- Vásquez R. Sistemática de las plantas medicinales de uso frecuente en el área de Iquitos. *Folia Amazonica*. 1992;4(01):65–80
- Belém HRF, Menezes CCS. As terapias tradicionais dos quilombolas de Aracuaã. 2003. Cen Univ do Pará: Belém. 2003
- Chagas AP, Müller AH, Soares MBP, Garcez LM. Anti-Leishmania and immunomodulatory potential of extracts of *Campsiandra laurifolia* Benth. (Fabaceae). *Rev Panamazonica Saude* 2010;1(01):117–124
- Ferreira AB, Ming LC, Haverroth M, Daly DC, Caballero J, Ballesté AM. Plants used to treat malaria in the regions of Rio Branco-Acre state and southern Amazonas state – Brazil. *Int J of Phytocos Nat Ingrid.* 2015;2(09):1–5
- Souza LP, Fillmann HS, Fonseca SRB, Brasil MS, Marroni NAP, Ferraz ABF. Antioxidant Evaluation of the Aqueous Extract of Hulls of *Campsiandra laurifolia* in Colitis Induced by Acetic Acid in Wistar Rats. *J Coloproctol (Rio J)* 2021;41(02):138–144
- Yamada Y, Post SR, Wang K, Tager HS, Bell GI, Seino S. Cloning and functional characterization of a family of human and mouse somatostatin receptors expressed in brain, gastrointestinal tract, and kidney. *Proc Natl Acad Sci U S A* 1992;89(01):251–255
- Tannahill CL, Stevenot SA, Campbell-Thompson M, Nick HS, Valentine JF. Induction and immunolocalization of manganese superoxide dismutase in acute acetic acid-induced colitis in the rat. *Gastroenterology* 1995;109(03):800–811
- Llesuy SF, Milei J, Molina H, Boveris A, Milei S. Comparison of lipid peroxidation and myocardial damage induced by adriamycin and 4'-epiadriamycin in mice. *Tumori* 1985;71(03):241–249
- Bradford MM. A rapid and sensitive method for the quantitation of microgram quantities of protein utilizing the principle of protein-dye binding. *Anal Biochem* 1976;72(1–2):248–254
- Buege JA, Aust SD. Microsomal lipid peroxidation. *Methods Enzymol* 1978;52:302–310
- Misra HP, Fridovich I. The role of superoxide anion in the autoxidation of epinephrine and a simple assay for superoxide dismutase. *J Biol Chem* 1972;247(10):3170–3175
- Beutler E, Duron O, Kelly BM. Improved method for the determination of blood glutathione. *J Lab Clin Med* 1963;61:882–888
- Helal MG, Abd Elhameed AG. *Graviola* mitigates acetic acid-induced ulcerative colitis in rats: insight on apoptosis and Wnt/Hh signaling crosstalk. *Environ Sci Pollut Res Int* 2021;28(23):29615–29628
- Kazi HA, Qian Z. Crocetin reduces TNBS-induced experimental colitis in mice by downregulation of NF $\kappa$ B. *Saudi J Gastroenterol* 2009;15(03):181–187