



## CLINICAL IMAGES

### A case report of “pearl necklace” in the abdomen: magnetic beads ingestion resulting in an anesthetic emergency

Dong Yan<sup>a</sup>, Xiaona Xia<sup>b</sup>, Fei Rong<sup>a</sup>, Haipeng Zhou<sup>a,\*</sup>, Penghui Wei<sup>id a,\*</sup>

<sup>a</sup> Shandong University, Cheeloo College of Medicine, Qilu Hospital (Qingdao), Department of Anesthesiology, Qingdao, China

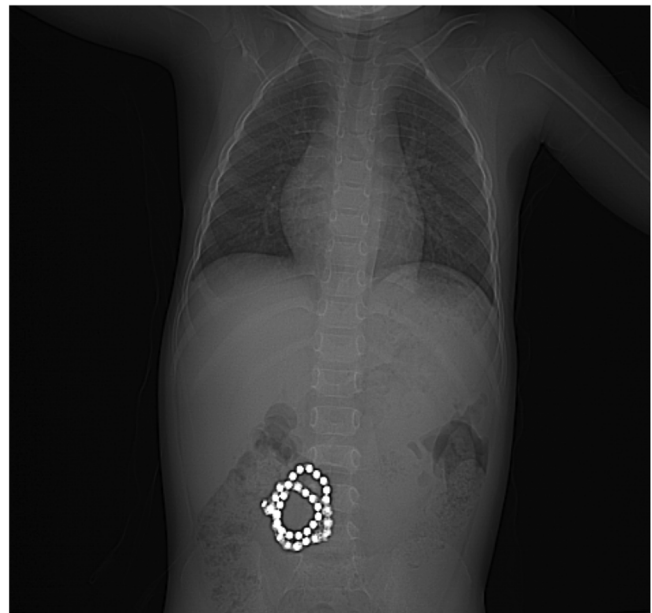
<sup>b</sup> Shandong University, Cheeloo College of Medicine, Qilu Hospital (Qingdao), Department of Radiology, Qingdao, China

Received 24 April 2021; accepted 20 July 2021

Available online 9 August 2021

Accidental ingestion of magnetic foreign bodies is a common pediatric problem attributed to the increasing availability of magnetic toys. A single magnet ingestion may be harmless; however, swallowing of numerous magnets can lead to catastrophic consequences.<sup>1</sup> The image from a 4-year-old boy following ingestion of 36 magnetic beads showed a tight intact beaded “pearl necklace” appearance located in the right abdomen (Fig. 1). The ingestion and possible magnetic beads interaction across the intestinal wall propose the risk of pressure-induced intestinal necrosis with forces up to 1,300 G, contributing to subsequent obstruction, fistulation, perforation, and even toxic shock.<sup>1</sup>

Urgent removal often requires the use of general anesthesia and is recommended in all cases of multiple magnet ingestion, unlike the expectant approach performed in the majority of foreign body ingestion. For the urgent removal, a rapid-sequence anesthesia induction and endotracheal tube should be preferred due to a possibility of a full stomach and the need to secure the airway.<sup>2</sup> Although magnetic beads are radio-opaque and abdominal radiography is the best choice for diagnosis, ultrasound-guided fast evaluation conducted by anesthesiologists may be more helpful in determining the location of magnets before skin incision in emergency laparoscopic surgery.<sup>3</sup> Considering the potential serious complications, including septic shock from intraperitoneal



**Figure 1** The figure showed a tight intact beaded “pearl necklace” appearance located in the right abdomen in a 4-year-old boy following ingestion of 36 magnetic beads.

infection and significant intraprocedural hemorrhage owing to the erosion of mesenteric vessels between the magnets, large bore intravenous access for rapid infusion and an arterial line for monitoring real-time hemodynamics should be

\* Corresponding authors.

E-mails: hope6968@hotmail.com (H. Zhou), weipenghuihui@sina.com (P. Wei).

<https://doi.org/10.1016/j.bjane.2021.07.020>

© 2021 Sociedade Brasileira de Anestesiologia. Published by Elsevier Editora Ltda. This is an open access article under the CC BY-NC-ND license (<http://creativecommons.org/licenses/by-nc-nd/4.0/>).

preoperatively obtained. Patients with complications may be appropriately transferred to the intensive care unit intubated and sedated for further treatment after surgery. The written informed consent was obtained from the patient's guardian.

### Funding

This work was funded by the Natural Science Foundation of Shandong Province (ZR2020QH291), the Qingdao Key Health Discipline Development Fund (2019) and the Scientific Research Foundation of Qilu Hospital of Shandong University (Qingdao) (QDKY2020QN04).

### Conflicts of interest

The authors declare no conflicts of interest.

### References

1. George AT, Motiwale S. Magnet ingestion in children-a potentially sticky issue? *Lancet*. 2012;379:2341–2.
2. Eck JB, Ames WA. Anesthetic Implications of Button Battery Ingestion in Children. *Anesthesiology*. 2020;132:917–24.
3. Salmon M, Doniger SJ. Ingested foreign bodies: a case series demonstrating a novel application of point-of-care ultrasonography in children. *Pediatr Emerg Care*. 2013;29:870–3.