

One wire tubeless ureteral reimplant: preliminary experience and step-by-step technique

Marcos Tobias-Machado^I, Alexandre Kyoshi Hidaka^{II}, Leticia Lumy Kanawa Sato^{III}, Roberto Javier Almeida-Carrera^{IV}, Eliney Ferreira Faria^V, Hamilton Zampolli^{VI}

^I Faculdade de Medicina do ABC, Santo André, Departamento de Urologia, Instituto do Câncer Arnaldo Vieira de Carvalho SP, Brasil.

^{II} Departamento de Urologia, Faculdade de Medicina do ABC, Santo André, SP, Brasil

^{III} Faculdade de Medicina do ABC, Residente de Cirurgia Geral, Santo André, SP, Brasil

^{IV} Faculdade de Medicina do ABC, Fellowship em cirurgia minimamente invasiva Santo André, Brasil

^V Hospital de Câncer de Barretos, Barretos, SP, Brasil

^{VI} Instituto do Câncer Arnaldo Vieira de Carvalho, Hospital Alemão Oswaldo Cruz, Departamento de Urologia, São Paulo, SP, Brasil.

BACKGROUND AND OBJECTIVES: Ureteral Reimplant is commonly used in pediatric and gynecologic surgery. Most techniques demand an experienced surgeon and lasts 2-3 hours. There is no consensus about the preferred technique until today. We report a simple modification of the Taguchi to reduce duration and make it more suitable for laparoscopic approach.

METHOD: Three patients underwent distal ureteral reimplant, based on our modified Taguchi minimally invasive approach technique. Cystography and ultrasonography were performed on the 30th, 90th and 180th postoperative days to monitor kidneys; a one-year follow-up for recurrence or clinical symptoms was also performed.

RESULTS: Operative time for ureteral reimplant using our technique was 15-25 minutes. The results of the performed exams on postoperative days showed normal kidneys without hydro-nephrosis. At the one-year follow-up no signs of recurrence or clinical symptoms were present.

CONCLUSION: Our modifications allowed a faster and easier management of distal ureteral reimplant, with excellent perioperative and post-operative outcomes. To our knowledge this is the first detailed description of this technique through minimally invasive approach. However, further studies and a longer follow up will be necessary to confirm the long-term outcomes and clinical benefits of our technical proposal.

KEYWORDS: ureteral reimplantation, laparoscopy, Taguchi procedure.

Tobias-Machado M, Hidaka AK, Sato LLK, Almeida-Carrera RJ, Faria EF, Zampolli H. One Wire Tubeless Ureteral Reimplantation: Preliminary Experience And Step-By-Step Technique. MedicalExpress (São Paulo, Online). 2017 Feb;4(1):M170106

Received for Publication on October 24, 2016; **First review** on November 24, 2016; **Accepted for publication** on February 7, 2017; **Online on** February 20, 2017

E-mail: tobias-machado@uol.com.br

INTRODUCTION

The source procedure for ureteral reimplant (UR) was described in 1959 by Paquin;¹ This was subsequently modified by Lich and Gregoir^{2,3} and by Taguchi et al.⁴ The standard Lich-Gregoir procedure using a laparoscopic pelvic approach represents at least 1-2h of extra operative time.⁵

Comparative studies in the open surgery era concluded that Taguchi technique is faster than other techniques.⁴ It has acceptable clinical complications in patients that underwent kidney transplantation.⁶

Surprisingly we could not find published descriptions of this technique applied to laparoscopy.

The aim of this study is to report a simple modification of the Taguchi procedure⁴ to make it more suitable for laparoscopic approach and to simplify and shorten the reconstructive tempo of the procedure.

MATERIALS AND METHODS

Procedures performed on three cases are described. Study participants were recruited through the inclusion criteria:

DOI: 10.5935/MedicalExpress.2017.01.06

Patient 1: A 54 years old man diagnosed with asymptomatic low risk localized prostate cancer. Laparoscopic radical prostatectomy was indicated. During posterior dissection approach, right distal ureteral transection occurred and immediate repair was needed. We judged that using our modified Taguchi minimally invasive approach technique was the best indication, as it allowed us to proceed in a much faster approach with efficiency. Saving time was valuable to complete prostatectomy afterwards, without using much extra time of anesthesia.

Patient 2: A 43 years old man diagnosed with ureteral stone in the anastomotic site of the left ureter. This patient had a history of left Lich-Gregoir ureteral reimplantation, two years earlier due to obstructive megaureter. Ureteral reimplantation of the distal ureter was indicated.

Patient 3: A 35 years old woman diagnosed with severe endometriosis compromising the posterior fornix, with infiltration of the left distal ureter. The left kidney was obstructed but the parenchyma was preserved. Ureteral reimplantation of the distal ureter was indicated.

■ SURGICAL TECHNIQUE

The patient is submitted under to general anesthesia and placed in supine position with both arms alongside the torso. A vesical catheter is placed. Then, the patient is positioned in the Trendelenburg position at 30°. Standard laparoscopic instruments were used. For the ureteral reimplantation we applied only one monofilament synthetic absorbable suture of 4-0 POLYGLYPTONE™ 6211.

The surgeon operates from the left. The assistant operates from optic 0°. The laparoscopic suction-irrigation device comes from the right side. The trocars are placed in an arc position, which allowed us to access the pelvic region; pneumoperitoneum was established at 10 mmHg with CO₂. The bladder was filled with 250ml of regular saline solution. The ureteral reimplantation began with a gentle dissection of the ureter. The peritoneal attachments were released to ensure a tension-free repair, without comprising the vascularization. After that, the laparoscopic scissor was used to spatulate the distal ureter. The ureter length should be sufficient to reach the bladder dome and perform a tension-free reimplant, without requiring the use the psoas-hitch procedure. Then, the detrusor is opened lengthwise, from 2.0 to 2.5 cm on the anterior surface of the bladder dome maintaining the mucosa intact. Next, we performed a mucosal incision as caudal as possible, equal to ureteral diameter. The tension free U-Stitch was completed with one 4-0 POLYGLYPTONE™ 6211 (Caprosyn™ 4/0) suture. Then, we Initiated the suture proximally at 1.5cm from muscular incision. The needle is inserted from outside-to-inside in the hiatus, twice through ureteral lumen (Figure 1 A/B/C/D) after that, it is moved back to the hiatus from inside-to-outside and passing near the first

entry (Figure 1D). The wire is then pulled to push the ureter back inside the bladder; a simple knot is performed to fix the ureter (Figure 2E). Using the same wire, the detrusor was approached with a continuous suture (Figure 2F) to cover the ureter and accomplish the submucosal anti reflux mechanism (Figure 3). Again, a simple knot was performed and the continuous suture was performed. At this moment fibrin glue may be applied to cover the final suture, improving the ureter fixation with fibrotic tissue. Suture integrity was confirmed filling the bladder with 250 ml of regular saline solution. A Penrose drain was placed behind the anastomosis, through the lowest trocar incision. A Vesical catheter was placed to assure minimal bladder distention for at least 7 days.

Cystography and ultrasonography were performed on the 30th, 90th and 180th postoperative days, to identify possible urine leakage, ureteral stenosis, and signals of hydronephrosis. We also kept a one year follow-up for recurrence or clinical symptoms.

■ RESULTS

The mean age of the study participants was 44 years old (35-54). Mean body mass index was 24.2kg/m² (22.4-26.0). Among these patients, 2 of them (66.7%) had left ureter reimplant, and 1 (33.3%) had right ureter reimplant. Mean operative time of distal ureteral reimplant in this study was 20 min (15-25). Estimated bleeding was minimal. Open conversion was not required in any of the cases. Patient 2 developed hematuria in the first post-operative day. This was solved with high flow saline wash through vesical catheter. A cystogram, performed after seven days, revealed no leaks or vesicoureteral reflux. The average hospitalization time for these study participants was 3 days. The bladder catheter was used for 7 days. Cystography and ultrasonography were performed at the 30th, 90th and 180th postoperative days and demonstrated normal kidneys without hydronephrosis. The one year follow-up ended with no signs of recurrence or clinical symptoms. Thus, we state that all patients underwent successfully to our modified Taguchi approach technique.

■ DISCUSSION

In urology, laparoscopy has become a refined surgical modality. However, the manipulation of small and delicate structures may be compromised for hands non-ergonomic design; also, it demands an experienced surgeon to accomplish the laparoscopic suturing. Therefore, reconstructive techniques are the hardest to perform through this kind of surgical modality.

The ureter-vesical anastomose is the major challenge in the ureteral reimplant because of the soft tissue of the

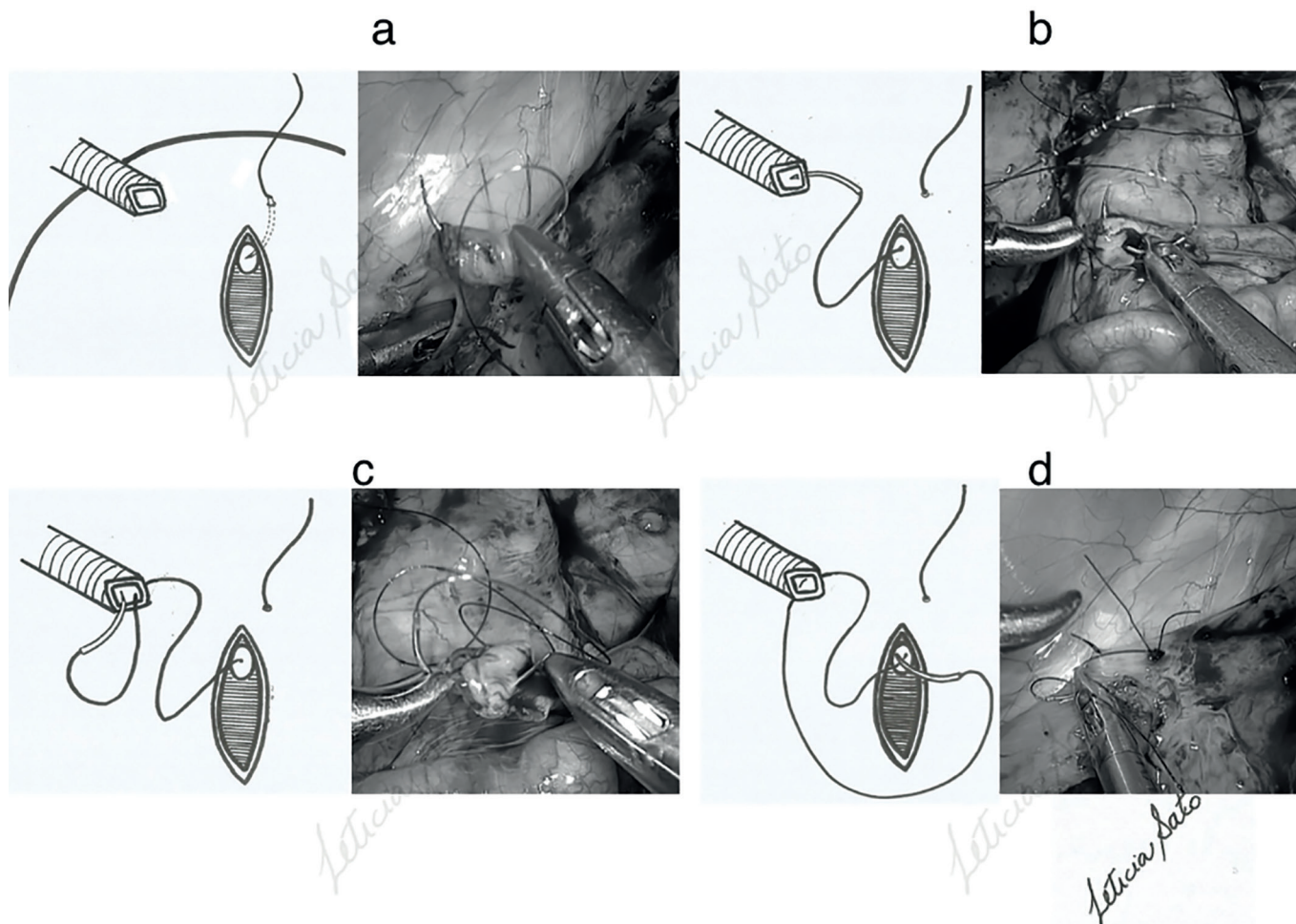


Figure 1 - Steps of the U-Stitch ureteral reimplantation. Suture passes through the hiatus outside to inside and through the ureter and goes back through the hiatus inside to outside with same suture wire.

bladder, the lack of stability of the ureter and reproduction of the technique is also a problem. In this age of laparoscopic surgery, reconstruction by laparoscopy approach is managed by few surgeons. Most prefer to convert to open surgery.⁷ Ureteral reimplant by robot-assisted laparoscopic rises worldwide. This is due the technical challenges of pure laparoscopy and especially because of laparoscopic suturing. Some centers try to reproduce the main open ureteral reimplant techniques.⁸⁻¹¹ But, to the best of our knowledge, no randomized multi-center clinical trial has determined the real benefit of laparoscopy and robotic approach to ureteral reimplant.

Several ureter-vesical anastomose techniques are used today. However, there is no consensus about the preferred technique. The most used techniques are performed by transperitoneal approach: they are the intravesical Politano-Leadbetter¹¹ and the extravesical Lich-Gregoir¹² procedures. The Taguchi or U-stitch technique was compared to other techniques in open surgery;^{6,12} unfortunately there are no reports of this use through laparoscopic surgery. There are some meta-analyses which

compare the three techniques and some others making comparisons between them, with and without the use of stent on kidney transplantation.^{6,13,14} However, there are several stenting biases which lead to no definitive conclusions about the clinical benefits of stent placement as a routine measure.^{13,14} Due this lack of evidence we decided not to apply the stent in our series.

Taguchi is easier to perform when compared with other techniques. The LG and PL techniques have significantly more surgical steps and demands a high amount of suturing in comparison with the Taguchi technique. As described here, the use of only one wire that goes from outside-to-inside the bladder through the ureter and from inside-to-outside the bladder without using stent placement; using only one knot to fix the ureter and using only a wire to perform continuous suturing of the muscular tunnel, highly favors the repair performed by laparoscopic approach. Spanish experience supports Taguchi due to short operative times and acceptable complications.¹⁵

There are a few studies with controversial results comparing Taguchi with other techniques previously

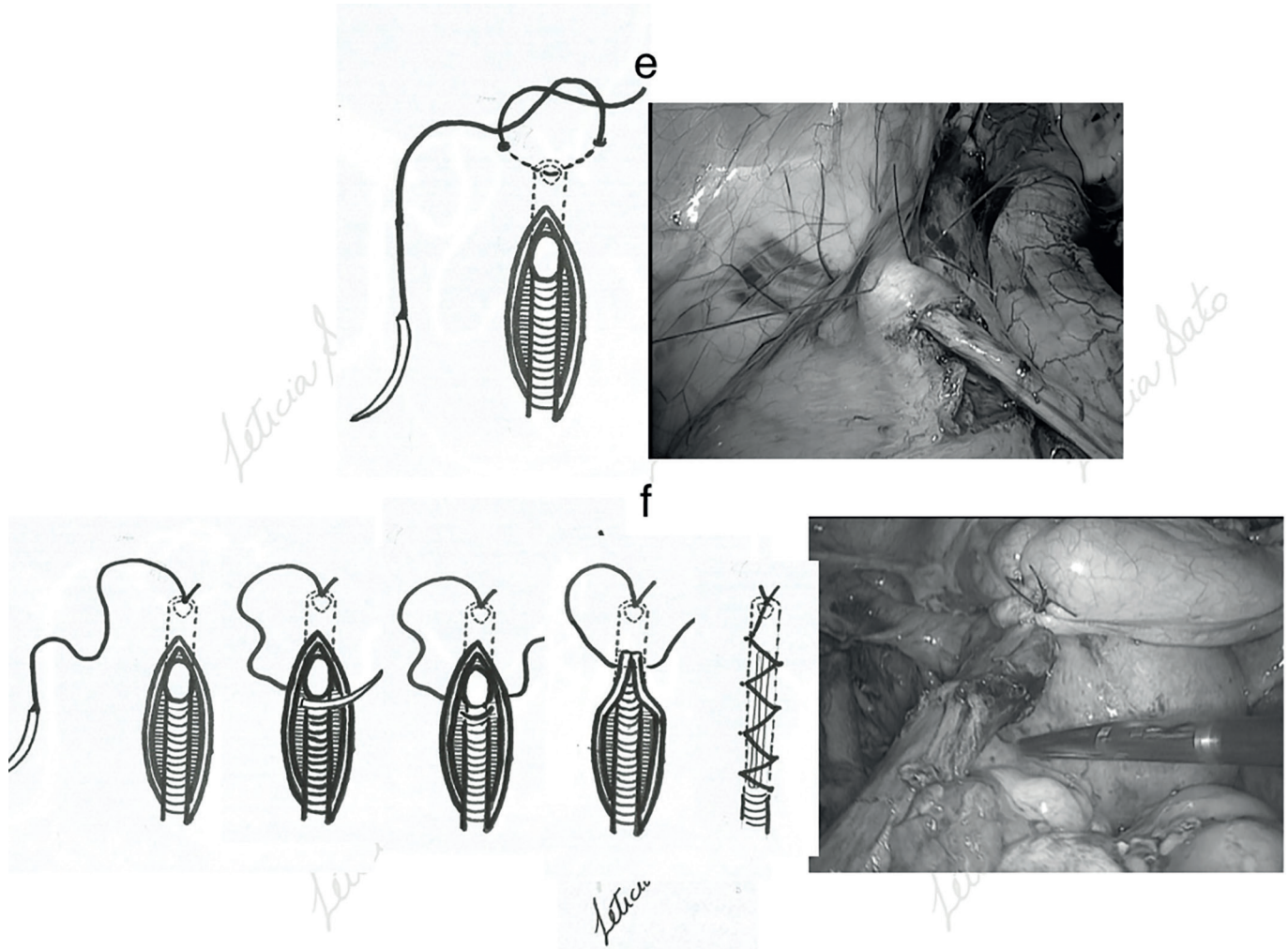


Figure 2 - Ureter fixation(e) and confection of the detrusor tunnel(f) with the same suture of the U-Stitch.

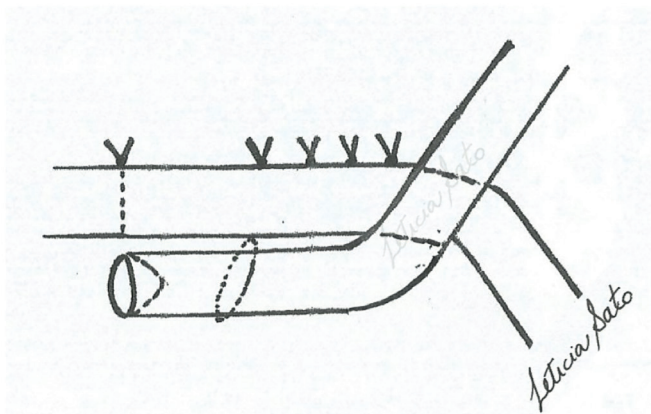


Figure 3 - Lateral view of the antireflux submucosal tunnel

reported.^{6,16-18} The main urologic complications of these techniques for ureteral reimplant are vesicoureteral reflux, urinary leakage, ureteral stenosis, and hematuria. American studies have reported that the Taguchi technique presents more urological events such as hematuria when compared

with PL and LG in open reimplantation.¹⁷⁻¹⁸ However, they conclude that there was no clinical significance in terms of outcome.

To complement the anastomosis, Rausweller et al. advocate the use of vesico-psoas hitch to stabilize the anastomosis.¹⁶ We believe that the use of this technique to stabilize the anastomoses if tension occurs would be the best approach. We also recommend the use of fibrin glue to cover tissue over the suture and improve the stabilization of the anastomosis, creating a fibrotic tissue.

As with other ureteral reimplant techniques our proposal basically duplicates a highly validated principle of open surgery. In this way, it is expected that the outcomes from the adapted version of the Taguchi reimplant for laparoscopy has no difference in comparison with open surgery.

We believe that this technique may be used by robotic approach in ureter vesical reimplant and to perform ureteroileal reimplant during cystectomy.

More experience is necessary to define clearly the clinical applications and complications of this technical

proposal for ureteral reimplant in urologic minimally invasive surgery.

■ CONFLICT OF INTEREST

None of the authors has a financial interest in any of the products, devices, or drugs mentioned in this manuscript.

■ AUTHOR PARTICIPATION

Study design: Tobias-Machado; Data collection: Tobias-Machado, Zampolli, Faria, Almeida-Carrera; Data analysis: Tobias-Machado, Hidaka, Zampolli, Faria; Data interpretation: Tobias-Machado, Zampolli, Faria; Literature search: Tobias-Machado, Hidaka, Almeida-Carrera; Figures and Tables: Tobias-Machado, Sato, Hidaka; Manuscript writing: Tobias-Machado, Hidaka.

ONE WIRE TUBELESS URETERAL REIMPLANTATION: EXPERIÊNCIA PRELIMINAR E TÉCNICA PASSO-A-PASSO

JUSTIFICATIVA E OBJETIVOS: O reimplante ureteral é comumente utilizado em cirurgia pediátrica e ginecológica. A maioria das técnicas exigem um cirurgião experiente e dura 2-3 horas. Não há consenso sobre a técnica preferida até hoje. Relatamos uma modificação simples do Taguchi para reduzir sua duração e torná-lo mais adequado para a abordagem laparoscópica.

MÉTODO: Três pacientes foram submetidos a reimplante ureteral distal, com base na técnica de abordagem minimamente invasiva de Taguchi modificada. Cistografia e ultra-sonografia foram realizadas no 30º, 90º e 180º dias de pós-operatório para monitorização dos rins; um acompanhamento de um ano para recorrência ou sintomas clínicos também foi realizado.

RESULTADOS: O tempo operatório para o reimplante ureteral utilizando a nossa técnica foi de 15-25 minutos. Os resultados dos exames realizados nos dias pós-operatórios mostraram rins normais sem hidronefrose. No seguimento de um ano não houve sinais de recorrência ou sintomas clínicos.

CONCLUSÃO: Nossas modificações permitiram um manejo mais rápido e fácil do reimplante ureteral distal, com excelentes resultados peri- e pós-operatórios. Tanto quanto sabemos, esta é a primeira descrição detalhada desta técnica através de abordagem minimamente invasiva. No entanto, estudos adicionais e um acompanhamento mais longo serão necessários para confirmar os resultados a longo prazo e os benefícios clínicos da técnica proposta.

PALAVRAS-CHAVE: reimplante ureteral, laparoscopia, procedimento de Taguchi

■ REFERENCES

1. Paquin AJ Jr. Ureterovesical anastomosis: The description and evaluation of a technique. *J Urol* 1959;82:573-83
2. Lich RJ, Howerton LW, Davis LA. Recurrent urosepsis in children. *J Urol*. 1961;86:554-8
3. Gregoir W & Van Regemorter G. Le reflux vesicoureteral congenital. *Urol Int*. 1964;18(2):122-36. DOI:10.1159/000279233
4. Taguchi Y, Klauber GT, MacKinnon KJ. Implantation of transplant ureters: a technique. *J Urol*. 1971;105(2):194-5.
5. Teber D, Gözen AS, Cresswell J, Canda AE, Yencilek F, Rassweiler J. Prevention and management of ureteral injuries occurring during laparoscopic radical prostatectomy: the Heilbronn experience and a review of the literature. *World J Urol*. 2009 Oct;27(5):613-8. DOI 10.1007/s00345-009-0428-7.
6. Alberts VP, Idu MM, Legemate DA, Pes MPL, Minnee RC. Ureterovesical anastomotic techniques for kidney transplantation: a systematic review and meta-analysis. *Transpl Int*. 2014;27(6):593-605. DOI 10.1111/tri.12301.
7. Rassweiler J, Pini G, Gözen AS, Klein J, Teber D. Role of laparoscopy in reconstructive surgery. *Curr Opin Urol*. 2010 Nov;20(6):471-82. DOI 10.1097/MOU.0b013e32833f21bd.
8. Kozinn SI, Canes D, Sorcini A, Moizadeh A. Robotic versus open distal ureteral reconstruction and reimplantation for benign stricture disease. *J Endourol*. 2012;26(2):147-51. DOI 10.1089/end.2011.0234.
9. Stanasel I, Atala A, Hemal A: Robotic assisted ureteral reimplantation: current status. *Curr Urol Rep*. 2013;14(1):32-6. DOI 10.1007/s11934-012-0298-1.
10. Schober MS, Jayanthi VR. Vesicoscopic Ureteral Reimplant: Is There a Role in the Age of Robotics? *Urol Clin North Am*. 2015;42(1):53-9. DOI 10.1016/j.ucl.2014.09.005.
11. Politano VA, Leadbetter WF. An operative technique for the correction of vesicoureteral reflux. *J Urol*. 2017;197(2S):S94-100. DOI: 10.1016/j.juro.2016.10.093.
12. Moreno-Alarcón C, López-Cubillana P, López-González PÁ, Prieto-González A, Ruiz-Morcillo JC, Olarte-Barragán EH. Lich-Gregoir Technique and Routine Use of Double J Catheter as the Best Combination to Avoid Urinary Complications in Kidney Transplantation; *Transplant Proc*. 2014;46(1):167-9. DOI:10.1016/j.transproceed.2013.12.002.
13. Mangus RS, Haag BW. Stented versus nonstented extravesical ureteroneocystostomy in renal transplantation: a metaanalysis; *Am J Transplant*. 2004;4(11):1889-96. DOI: 10.1111/j.1600-6143.2004.00595.x
14. Wilson CH, Bhatti AA, Rix DA, Manas DM. Routine intraoperative ureteric stenting for kidney transplant recipients. *Cochrane Database Syst Rev*. 2005;(4):CD004925. DOI: 10.1002/14651858.CD004925.pub2
15. Caparos J, Regalado RI, Sanchez-Martín F, Villavicencio H. *World J Urol*. 1996;14(4):236-8. DOI: 10.1007/BF00182073.
16. Rassweiler J, Gözen AS, Erdogru T, Sugiono M, Teber D. Ureteral reimplantation for management of ureteral strictures: a retrospective comparison of laparoscopic and open techniques. *Eur Urol*. 2007 Feb;51(2):512-22; discussion 522-3. DOI: 10.1016/j.euro.2006.08.004
17. Lee CT, Chen BT, Gong E, Hafez KS, Sheffield JH, Montie JE. Comparison of modified Taguchi and Bricker ureteral reimplantation techniques after radical cystectomy. *Urology*. 2004;64:940-4, 2004. DOI: 10.1016/j.urology.2004.07.005
18. Lee RS, Bakthavatsalam R, Marsh CL, Kuhr CS. Ureteral Complications in Renal Transplantation: A Comparison of the Lich-Gregoir Versus the Taguchi Technique. *Transplant Proc*. 2007;39(5):1461-4. DOI: 10.1016/j.transproceed.2006.11.017