

Chagas Disease Cardiomyopathy

Marcus Vinicius Simões, Minna Moreira Dias Romano, André Schmidt, Káryta Suely Macedo Martins, José Antonio Marin-Neto

Divisão de Cardiologia - Departamento de Clínica Médica - Faculdade de Medicina de Ribeirão Preto da Universidade de São Paulo, SP - Brazil

Abstract

Chronic Chagas disease cardiomyopathy (CCC) is a result of low-intensity, but incessant, focal fibrosing myocarditis, caused by persistent *T. cruzi* infection associated with inflammation, mediated by adverse immune mechanisms. About 30 percent of infected individuals have developed throughout life the chronic cardiac form of Chagas' disease with protean clinical manifestations, such as sudden death, signs and symptoms of heart failure, cardioembolic events, arrhythmia and angiod symptoms. Sudden death and the progression of heart failure (HF) are the most common mechanisms of death in this condition. The most relevant prognostic aspects are symptoms of advanced HF (NYHA Fc III-IV), cardiomegaly, LV systolic dysfunction and nonsustained ventricular tachycardia. Preventing cardioembolic events is an important aspect in the management of patients with CCC. Oral anticoagulant agents must be prescribed for high-risk patients according to the presence of a set of risk factors: LV systolic dysfunction, apical aneurysm, altered ventricular repolarization by ECG and advanced age. The treatment of HF in patients with CCC follows the same principles applied to HF secondary to dilated cardiomyopathy of other etiologies.

Introduction

Chagas disease (ChD) is caused by the protozoan parasite *Trypanosoma cruzi*, which causes an acute myocarditis and subsequently a low-grade incessant chronic fibrosing myocarditis, which produces progressive myocardial damage and later results in chronic cardiomyopathy of chronic Chagas' disease (CCC). Cardiac impairment in

Keywords

Cardiomyopathies; Chagas Cardiomyopathy; *Trypanosoma Cruzi*; Chagas Disease; Heart Failure.

patients in the chronic phase of the disease includes relevant morbidity and mortality, in addition to being the main cause of nonischemic cardiomyopathy in Latin America.

Epidemiology

Chagas Disease transmission cycle has been based mostly on *triatomine* species as main *vectors of the disease*. However, after several national campaigns and multinational initiatives, transmission by this means is partially controlled. In 2006, Brazil was certified by the World Health Organization (WHO) as an area free of ChD vectorial transmission by the most important domiciled vector, the *Triatoma infestans*.^{1,2} This in no way represents the disease eradication— an inherently unreachable goal – which continues to occur, through outbreaks mediated by other transmission mechanisms, such as the oral route. From 1975 to 1995, the Southern Cone Initiative against Chagas' disease detected an 89% reduction in the disease transmission.³ Mortality rates secondary to Chagas' disease have also been reduced to 75% since the 1990's.⁴

However, WHO still estimates that 300,000 new cases of the disease are diagnosed each year in Latin America and believes that there are 8 million infected people worldwide. CCC is considered a major public health problem in the endemic areas of Latin America, and represents one of the greatest causes of heart failure and sudden death. Nowadays, due to globalization and migratory currents, it is also an emergent disease in nonendemic countries, such as the United States of America, Canada, Spain, France, Switzerland, Italy, Japan, and other countries in Asia and Oceania.^{1,5,6}

National history and evolutive stages

The natural history of ChD includes acute and chronic phases. Most patients with the acute disease are

Mailing Address: Prof. Dr. Marcus Vinicius Simões, MD, PhD

Cardiology Division – Internal Medicine Department

Hospital das Clínicas da Faculdade de Medicina de Ribeirão Preto, 3900 Bandeirantes Avenue, Ribeirão Preto, SP – Brazil

e-mail: msimoes@fmrp.usp.br

asymptomatic or have only the mild and non-specific symptoms of an infectious syndrome, and rarely present myocarditis or symptomatic meningoencephalitis. As soon as the acute phase collapses, generally after 4 to 8 weeks, the patient evolves to a chronic phase, which includes two forms of the disease: an indeterminate (latent or preclinical) form, and a determined form, with clinical expression, which subdivides into cardiac, digestive or cardiodigestive. There may also be a direct evolution from the acute phase to the chronic phase, without the occurrence of the indeterminate form, in 5 to 10% of cases.⁷ Reactivation of the chronic disease can also occur, presenting as an acute (exacerbated) disease, in individuals with natural immunosuppression, due to diseases such as AIDS, or iatrogenically (e.g. in solid-organ-transplanted patients). Figure 1 represents the natural evolution of the disease.

The indeterminate form includes patients with evidence of *T. cruzi* infection (positive serological tests, based on the presence of antiparasite circulating antibodies), but without clinical manifestations of cardiac or digestive tract disease. About 30 to 50% of patients with the indeterminate form, which may usually last from 10 to 30 years, will develop CCC throughout their lives.⁸

CCC not only is the most common manifestation, but it is also the most severe, with morbidity rates of up to 30%.^{9,10}

Also, considering that late evolution of CCC involves the appearance of a clinical picture of dilated cardiomyopathy, with global LV dysfunction, and heart failure syndrome, the Latin American guidelines for the diagnosis and treatment of Chagas cardiomyopathy have proposed a clinical classification of LV dysfunction in Chagas' disease which reflects the progression of evolutionary stages of heart failure adopted in the international guidelines for this syndrome. Thus, the chronic phase of CCC can be classified into 5 evolutionary stages (A, B1, B2, C and D) of LV dysfunction (Chart 1).

Etiopathogeny

In the acute phase, organic damage is clearly associated with parasitic infestation and multiplication in the myocardium, in addition to other commonly impaired tissues, such as the nervous system and the digestive tract. Lymphadenopathy and enlargement of the spleen and liver are a result of the systemic immune reaction and correlate with the high parasitemia.

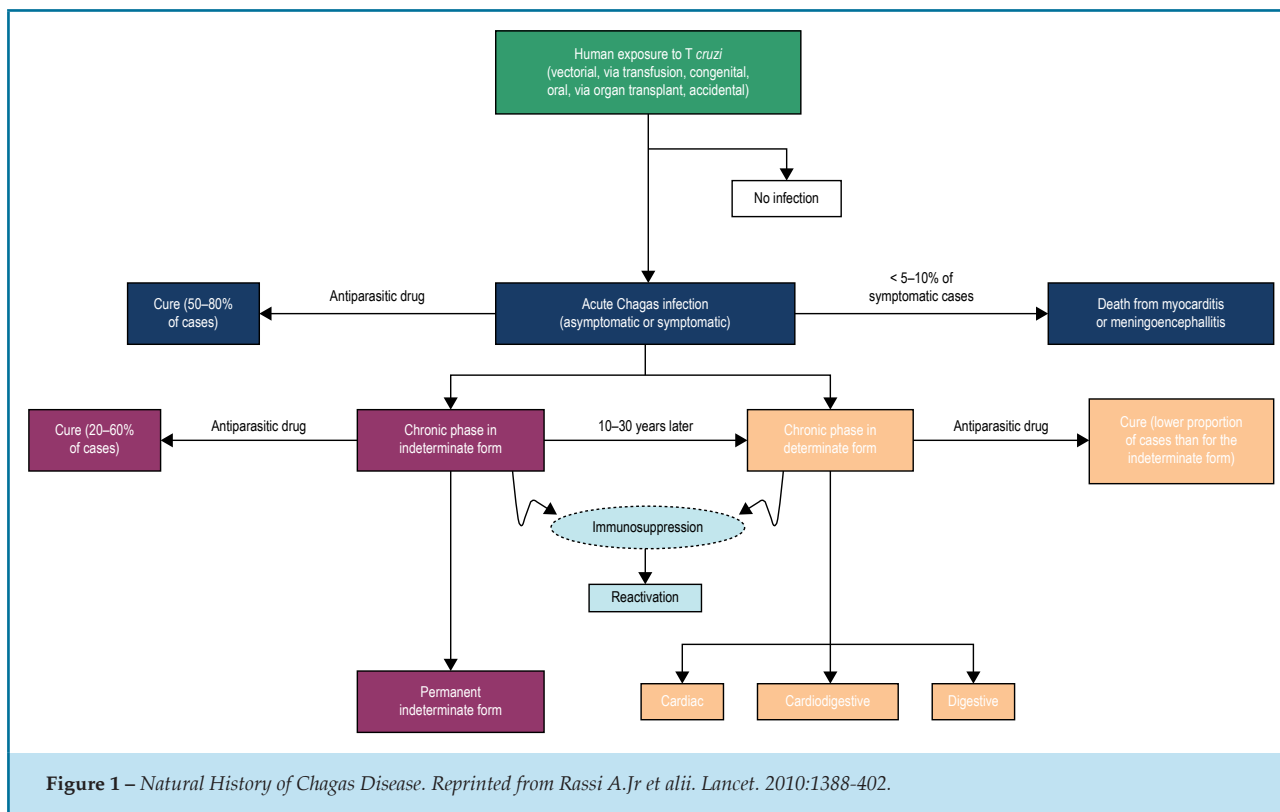


Figure 1 – Natural History of Chagas Disease. Reprinted from Rassi A.Jr et alii. Lancet. 2010:1388-402.

Chart 1 – Clinical classification of left ventricular dysfunction in Chagas' heart disease (apud Andrade J et alii)

Acute phase	Chronic phase				
	Indeterminate form	Cardiac form with no ventricular dysfunction	Cardiac form with ventricular dysfunction		
	A	B1	B2	C	D
Patients with findings compatible with acute Chagas disease	Patients at risk for developing CHF. They have positive serology, neither structural cardiopathy nor CHF symptoms. No digestive changes	Patients with structural cardiopathy, evidenced by electrocardiographic or echocardiographic changes, but with normal global ventricular function and neither current nor previous signs and symptoms of CHF	Patients with structural cardiopathy characterized by global ventricular dysfunction, and neither current nor previous signs and symptoms of CHF	Patients with ventricular dysfunction and current or previous symptoms of CHF (NYHA FC I, II, III or IV)	Patients with refractory symptoms of CHF at rest, despite optimized clinical treatment, requiring specialized interventions

With remission of the parasitemia and systemic inflammatory reactions, the patient enters the chronic phase of the disease, in which it is believed that, a process of low-intensity, but incessant, focal myocarditis occurs since the indeterminate form, which causes progressive destruction of fibers and restorative myocardial fibrosis. This causes cumulative myocardial damage, and results in a picture of late dilated cardiomyopathy, usually accompanied by severe arrhythmias, thromboembolic complications and sudden death in a high proportion of cases. It is believed that chronic myocarditis in Chagas' disease is due to two main pathogenetic processes: myocardial damage associated directly with inflammation caused by parasitized cardiac fibers, with multiple but low-intensity outbreaks; and myocardial aggression caused by adverse immune reaction directed, and continuously fed, by the reiterated presentation of antigens linked to persistent cardiac parasitism.

In addition, there is evidence to support the idea that there are still two auxiliary and amplifying mechanisms of the myocardial injury: myocardial perfusion disorders due to the presence of abnormalities in coronary microcirculation and autonomic cardiac innervation (Figure 2).¹¹

Acute phase

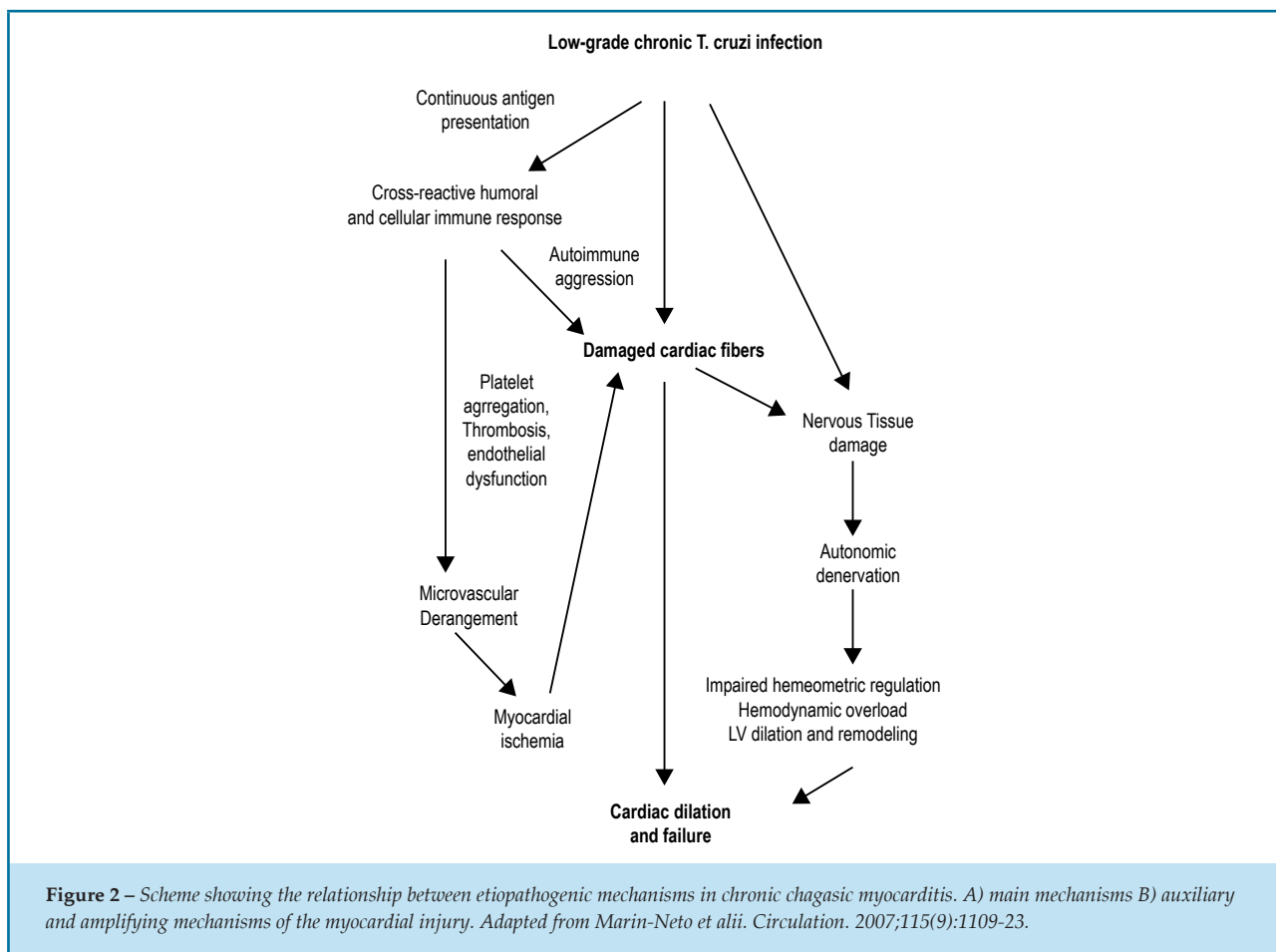
Signs and Symptoms

The acute phase begins after an incubation period usually of 1-4 week after exposure to *T. cruzi*. The lesions known

as “chagomas”, including the typical, but non-specific, Romaña's sign, are a result of mucosal or cutaneous edema at the site of inoculation. Most patients present asymptomatic or show systemic infection symptoms (fever, hepatosplenomegaly, diaphoresis, myalgia), accompanied by equally non-specific laboratory alterations, especially leukocytosis, with absolute lymphocytosis. A minority of patients present a clinical picture of myocarditis, with signs and symptoms similar to myocarditis of other causes: dyspnea, fatigue and other commemorative symptoms of heart failure. In these cases, the ECG may show sinus tachycardia, ventricular ectopic beats, low voltage of the QRS complexes, branch block, diffuse disturbances of ventricular repolarization, first-degree or more advanced AV block. Chest x-ray may show increased cardiothoracic ratio in more severe cases, which may be associated with increased heart chambers and/or pericardial effusion. The echocardiogram often shows pericardial effusion, segmental changes in parietal mobility and insufficiency of mitral and tricuspid valves and, less frequently, cavitory dilation and decreased global systolic performance. These abnormalities usually resolve in the majority of patients over the first year of follow-up.^{12,13}

Diagnosis

Serological tests are usually negative in the first weeks of infection. The diagnosis is made by detection of circulating parasites or their genetic material (PCR) through a variety of methods, such as blood culture, direct visualization of the parasite in peripheral blood,



xenodiagnosis, or the presence of parasite nests in amastigote form revealed by biopsy with histopathology of affected organs, or of cutaneous “chagomas”.

Endomyocardial biopsy is rarely used for the diagnosis, but may be necessary, especially in cases of suspected reactivation of Chagas disease after heart transplantation, in which a clear distinction from implant rejection is critical in patient management.¹⁴

Clinical Course

The clinical course of the acute phase in Chagas disease is often benign and the signs and symptoms typically resolve spontaneously over 1 to 3 months. It is estimated that fatal evolution occurs in <5% of patients in the acute phase, when contaminated through classic vectorial transmission (via the bite of a triatomine bug), predominantly in patients with refractory heart failure. However, in acute cases resulting from contamination by the oral route (for example after ingestion of *T. cruzi* contaminated sugar cane juice or açai), the acute disease is usually more severe and the rates of

mortality are higher. This is probably due to inoculation of high parasite load and ease of penetration through the gastrointestinal mucosa, which is highly permeable to the parasite, in these cases.

Treatment

The treatment of clinical manifestations of myocarditis and heart failure is similar to the one recommended for cases of myocarditis of other etiologies, including intensive measures of circulatory support in more severe cases.

However, more specifically, although there is no conclusive evidence concerning possible clinically relevant benefits that could be achieved, antiparasitic treatment with benznidazole or nifurtimox is indicated for all cases of acute Chagas disease, independently of the infection route or the reactivation mechanism, since it may decrease the severity of the symptoms, reduce disease time and the duration of detectable parasitemia. The occurrence of parasitological cure, besides clinical cure, is estimated in 60 to 85% of cases.^{15,16}

Chronic phase

Indeterminate form

The indeterminate form of the disease is classically defined as the clinical situation of an individual with parasitological and/or serological evidence of chronic *T. cruzi* infection, but without symptoms or physical signs of the disease, with normal ECG and chest X-ray and without digestive tract (esophagus and colon) impairment seen in radiological exams.

However, more accurate complementary exams (i.e. echocardiography, nuclear angiocardigraphy, hemodynamic study and autonomic cardiac assessment) may demonstrate - usually subtle and of no prognostic relevance - cardiac alterations in this group of patients classified as indeterminate by classical criteria.¹⁷⁻¹⁹ In spite of these minor abnormalities verified in many patients, those classified as indeterminate by the classical criteria, while maintaining their normal ECG status, present excellent prognosis and mortality rates comparable to those of the control group of the same age without *T. cruzi*.^{4,20,21}

Guidelines for monitoring chagasic patients in the indeterminate form

There are no formal guidelines in relation to the conduction of exams for early detection of left ventricular dysfunction in patients with the indeterminate form of Chagas disease. On the other hand, there are no identifiable factors in this phase that can distinguish the individuals who will develop the clinical cardiomyopathy from those who will remain asymptomatic during their whole lives, just keeping the serological positivity.

It is suggested that the ECG be repeated every 1 or 2 years and a simple chest X-ray every 3 or 5 years. Though it is more controversial, one may also suggest that the transthoracic echocardiography can be performed initially, and later on at regular intervals as well, every 3 to 5 years.^{8,17,22,23}

Cardiac Chronic Form

Asymptomatic condition in Chronic Chagas' disease cardiomyopathy

The absence of symptoms is most marked in individuals who are in incipient stages of the chronic disease, when (discrete) myocardial injury can be detected only due to alterations in complementary exams, such as ECG

conduction disturbance, changes in LV segmental parietal mobility on ECG or Holter arrhythmias. In these individuals, however, sudden death may occur due to arrhythmic events, as evidenced by studies demonstrating a worsen prognosis in individuals with alterations in the ECG, even when asymptomatic.²⁴ In a 10-year cohort study of 885 seropositive individuals, it was shown that *T. cruzi* infected individuals with normal ECG had a survival of 97.4%, comparable to the survival of seronegative individuals. On the other hand, survival of those with abnormal ECG was 61.3%, with a nine-fold increased risk in this group.²⁵ It is estimated that 2 to 5% of patients without any apparent cardiomyopathy will develop new ECG alterations and evidence of cardiomyopathy each year.^{19,26,27}

Clinical manifestations

The symptoms and physical signs present in the chronic phase of the Chagas disease cardiomyopathy are a result of four essential syndromes that can often coexist in the same patient: heart failure, arrhythmias, thromboembolism and anginal manifestations.

Heart Failure Syndrome

The clinical picture of CCC with ventricular dysfunction is described in a quite uniform manner in several literature reports, following the pioneering remarks of Chagas and Villela.²⁸ In the early stages of manifestation, the most frequent symptoms are fatigue and dyspnea on exertion, but the registry of more intense symptoms of pulmonary congestion, such as paroxysmal nocturnal dyspnea and decubitus with orthopnea, are uncommon. In the disease evolution, there occur the symptoms of systemic venous congestion (jugular swelling, hepatomegaly, lower limb edema and ascites) and the evolution can still progress to anasarca, adynamia, or cardiac cachexia, similar to what happens in other cardiopathies with advanced ventricular dysfunction. At clinical examination, there are also signs of cardiomegaly resulting from deviation of the *ictus cordis*, there may be a muffled S1 heart sound in the mitral area, fixed doubling of second heart sound due to RBBB, third heart sound and atrioventricular valve regurgitation murmur, which may occur secondarily to the dilation of ventricular chambers. Signs of low systemic output may occur in advanced cases, such as filiform pulse, slow and oliguria peripheral perfusion. These signs are common to other clinical syndromes of heart failure. In contrast to these similarities, in heart failure of Chagasic etiology, pulmonary congestion is

commonly mild in the advanced stages of the disease, compared to the more exuberant systemic congestion, and the pulmonary semiology may be more affected by the signs of pleural effusion than by crepitations, as well as by lower systemic pressure levels in this group of patients. The progression to acute pulmonary edema in these cases is even more rare.²⁰ These particularities in the clinical presentation may relate to the most frequent concomitance of biventricular dysfunction, with right ventricular heart failure, sometimes earlier and more pronounced than the left one in *T. cruzi* infected patients.

Thromboembolic manifestations

Pulmonary and systemic embolisms are common manifestations in patients with CCC, as a result of murine thrombosis from cardiac chambers and systemic vein thrombosis, and are a major cause of embolic stroke and other morbidities. Thromboembolic accidents are often the first manifestation of the disease and may occur in stages without ventricular dysfunction (Stage B2). However, as in several other cardiopathies, cavity dilation and HF syndrome are known associated risk factors. Nevertheless, it is chronic regional ventricular dyskinesia, mainly apical, such as the classic aneurysm of the glove finger, which has shown a special propensity for the formation of mural thrombi and the consequent embolic events, particularly the systemic ones. As predicted, atrial fibrillation, even when present in the minority of this population, as a relatively late and secondary manifestation to the ventricular dysfunction, also constitutes an additional thrombogenic factor. Pulmonary embolization, which can originate from peripheral venous thrombi and right cardiac cavities, is much less frequently clinically diagnosed, but its incidence is certainly underestimated, compared to its prevalence in necropsy material.²⁹

There is a clear lack of data to provide an estimate of the actual incidence of clinical thromboembolism in CCC, but series of autopsies and clinical studies indicate high rates of intracardiac thrombi and thromboembolic events in this population. In a revision of 1345 necropsies of patients with chronic chagasic cardiomyopathy, thromboemboli and/or intracardiac thrombi were observed in 44% of cases.²⁹ Thrombi were equally frequent in right and left cardiac cavities. Systemic circulation thromboembolism was more frequent, but more associated with fatal events.

A transthoracic and transesophageal echocardiography study showed that thromboembolism frequently originated from the heart in 75 *T. cruzi* chronically infected patients without symptoms of heart failure, or with mild symptoms. Left ventricular mural thrombi were found in 23% of patients and were associated with previous history of stroke. Apical aneurysm was identified in 47% of patients and was significantly related to mural thrombosis and the occurrence of stroke. Left and *right atrial appendage thrombosis* was present in 4 and 1 patient, respectively. During the 24-month follow-up period, 1 non-fatal stroke event and 13 deaths were observed, 7 of which were sudden, 5 due to HF progression and 1 death by stroke.^{30,31}

Systematic revision of 8 observational studies, involving 4158 patients, addressed the association between CCC and the risk of stroke.³² The results indicate that chronically *T. cruzi* infected patients, when compared to the non-infected, had an excess risk of stroke of about 70% (RR = 1.70; HF 95%: 1.06 to 2.71). When the analysis was limited to 3 studies, with more strict criteria for stroke, an even higher excess risk was found (RR = 6.02; HF 95%: 1.86 to 19.49).

The characteristics of stroke patients with CCC were explored in a study of 94 patients with acute ischemic stroke, compared with the characteristics of a control group of patients without CCC. *T. cruzi* infected individuals showed higher rates of cardioembolic stroke (56% versus 9%), left ventricular dilatation (23% versus 5%), LV mural thrombosis (12% versus 2%), apical aneurysm (37% versus 1%) and atrial fibrillation (14% versus 5%).²³

Prevention of cardioembolic stroke in patients with CCC

The I Latin American Guideline for the Diagnosis and Treatment of Chagas Cardiopathy adopted recommendations for estimation and prevention of cardioembolic stroke risk through the use of oral antithrombotic agents,¹ based on a prospective cohort study of 1,043 patient with CCC. The total incidence reported in this event was 3.0%, or 0.56%/year. In the final risk model for cardioembolic stroke prediction, a score was calculated in which the presence of LV systolic dysfunction added two points, and apical aneurysm, alteration of the ventricular repolarization at the ECG and age > 48 years added one point for each alteration. Considering the risk-benefit ratio, warfarin would be

indicated for patients with 4-5 points (in this subgroup, there is incidence of 4.4% of stroke versus 2.0% of major bleeding per year). In the 3 point score group, stroke and major bleeding rates with OAC are equivalent, and acetylsalicylic acid (ASA) or warfarin can be indicated.³² In 2 point patients with low incidence of stroke (1.2% per year), ASA was recommended, or no prophylaxis. Patients with 0-1 point, with incidence close to zero, would not require prophylaxis.³³

Arrhythmic manifestations

CCC is essentially an arrhythmogenic cardiomyopathy, with pathophysiological peculiarities in this context, which makes it uniquely distinct from other cardiopathies. Virtually, all types of atrial and ventricular arrhythmia may occur, including sinus node dysfunction, intermittent or complete AV block and complex ventricular arrhythmias. The arrhythmias may course asymptomatic or present with non-specific malaise or sudden, fleeting and spontaneously resolved onset palpitation, at rest or by exertion. Symptoms of low cardiac output due to Stokes-Adams syndrome are less common, but more ominous, including presyncope, lipotimia, or even syncope, which can occasionally be preceded by palpitations. These episodes can either correspond to (sustained or nonsustained) ventricular tachycardia, with or without hemodynamic instability, or to bradyarrhythmias due to atrioventricular block.³⁴

In some cases, the standard 12-lead ECG with rhythm strip shows premature and ectopic ventricular depolarization, and even ventricular tachycardia outbreaks, in addition to atrial fibrillation or complete atrioventricular block (AVB). Tachycardic ventricular arrhythmias and AV conduction disorders leading to periods of bradycardia can often alternate, frequently coexisting during the same Holter recording.

At clinical examination, it is possible to detect fixed doubling of the second heart sound (at a pulmonary focus), irregular heart rhythm, or even bradycardia, often associated with typical signs of a-waves, periodically incremented in the jugular venous pulse and reinforcement of the first heart sound, in cannon waves, when there is a temporal correlation between atrial and ventricular systoles, which is suggestive of complete atrioventricular block.

The presence and density of arrhythmia correlate with the degree of ventricular dysfunction in many cases, but can also occur in patients with preserved

global left ventricular function, constituting the "isolated arrhythmogenic form" of the disease. This characteristic, which distinguishes CCC from coronary artery disease in patients with ventricular dysfunction, as well as from other cardiomyopathies, and makes T. cruzi infected patients especially susceptible to early sudden death, derives from its pathophysiological peculiarities and peculiar pathogenesis.

In fact, the mechanism of severe ventricular arrhythmia in CCC is mainly associated with the presence of regional fibrosis (especially in the posterolateral regions of the LV) and macroreentry circuits formation.³⁵ Recent studies using cardiac magnetic resonance have reinforced the idea that the presence of regional fibrosis is a major factor for the arrhythmic mechanism in this disease.³⁶⁻³⁸

Another relevant pathophysiological factor that potentially triggers severe ventricular arrhythmia and sudden death in CCC patients is regional myocardial extensive and early sympathetic denervation. In a study with patients with CCC and normal or slightly reduced LV function, the presence of sustained ventricular tachycardia has been associated with more extensive areas of viable denervated myocardium, detected through I-MIBG myocardial scintigraphy.^{123, 39}

Sudden Death

It is estimated that sudden death is the leading cause of mortality throughout the various phases of CCC, corresponding to 55 - 65% of deaths.²² Sudden death is often triggered by physical effort and may be caused both by severe tachyarrhythmias, such as ventricular tachycardia and fibrillation (probably in 80-90% of cases), and (less frequently) by asystole or complete AV block.⁴⁰ The detection of nonsustained and especially of sustained ventricular tachycardias increases the chance of sudden death, but it occurs mainly in patients with advanced ventricular dysfunction.

Anginal manifestations

Complaints of precordialgia in patients with CCC are quite common. This pain has characteristics that are often atypical for myocardial ischemia, described as stabbing, fleeting, or, conversely, long lasting (hours or even days), poorly located, usually not related to efforts, sometimes caused by emotional stress and with recurrent patterns throughout the day. However, sometimes, the episodes may be more acute, with typically ischemic characteristics, making the diagnosis even more

difficult. Evidence of microcirculatory disorders as causes of anginal manifestations in this group accumulates in the literature.^{11,41,42}

Clinical diagnosis

The diagnosis of Chagas' heart disease must be based on epidemiological criteria, clinical manifestations, serological tests and on the results of some complementary tests.

Serological tests

Given the low parasitaemia in the chronic phase of the disease, the serological tests must be able to detect antibodies against *T. cruzi* antigens. The most commonly used tests are: immunoenzymatic assay (ELISA), indirect immunofluorescence (IFI), and indirect hemagglutination (HAI). When all 3 are performed, agreement (90-98%) was observed among them. Since ELISA and IFI have similar characteristics in terms of their accuracy, with higher sensitivity, but slightly reduced specificity than the HAI assay, a positive result in two of these three tests is recommended for the diagnosis. However, when the first test is negative, in the current practice based on the high sensitivity of all serological tests, there is no need for a second test.⁴³

Complementary cardiologic exams

The main complementary diagnostic tests used in Chagas' heart disease are briefly described below, with emphasis on those focusing on the characterization and gradation of ventricular dysfunction.

Electrocardiography and Holter Monitoring: The most prevalent electrocardiographic alterations in patients with CCC are right bundle branch disorders and the left anterior hemiblock, and may reach 50% in patients of this group.⁴⁴ These changes in the cardiac conduction system may be evolutionary, such as AV conduction delays. Sinus node dysfunction can also cause bradycardia. However, atrial arrhythmias tend to occur in the evolution of the heart disease with advanced ventricular dysfunction. It is crucial to observe that, although ventricular ectopic beats can be seen in normal individuals during the recording of a standard ECG, when it is verified in patients with CCC, the meaning of this alteration is completely different and it usually indicates that the ventricular arrhythmia is an integral part of the syndrome and

it constitutes an element of strong prognostic value. Symptoms suggestive of arrhythmic syndromes also make ECG Holter monitoring mandatory, since it allows the assessment of episodes of both tachyarrhythmias and bradycardia for risk stratification in these patients.³⁴ Recording for at least 24 hours allows determining the density of ventricular ectopy, detecting episodes of nonsustainable or sustained ventricular tachycardia, as well as determining the duration of sinus pauses and of asystolia of different origins. It is worth recalling that, to compose the Rassi score, used for predicting mortality in patients with CCC, the 24-hour Holter test is essential to assess the prognostic criteria, with independent value, of nonsustained ventricular tachycardia, as it will be seen later.

Other frequent changes in ECG at rest are: diffuse T wave and ST segment abnormalities, pathological Q waves, prolongation of the QT interval and increased QT dispersion. The evaluation of fibrosis using the QRS score applied to the standard ECG correlates with the NYHA functional class and with the extent of myocardial fibrosis detected in Late Gadolinium Enhanced (LGE) cardiac magnetic resonance imaging.⁴⁵

Chest X-ray: Advanced stages of the disease are marked by (often massive) cardiomegaly, which may include signs of not only increased LV, but also of increased RV and both atrial dilation; however, pulmonary congestion differs from other cardiopathies because it is often discrete, in contrast to the degree of cardiothoracic ratio. Cardiomegaly is also an important prognostic factor in these patients, stratified by the Rassi score, as discussed next.

Echocardiography: Echocardiography is a non-invasive imaging method that allows the geometrical and functional diagnosis of both ventricles, which is essentially important in CCC. Alterations in segmental mobility in the inferior and inferolateral regions of the LV are quite common in patients with the cardiac chronic form.⁴⁶⁻⁵⁰ Even though the detection of LV apical aneurysm (a very common alteration in patients with CCC)⁵¹ may be subject to operational limitations, it is one of the typical changes found in the disease, and may be filled with thrombus (Figure 3, A). Although early changes in LV regional mobility can be detected on ECG, both through conventional techniques^{17,52,53} and analysis of myocardial deformation, in some patients classified as having the indeterminate form, or even with CCC and function preserved by other methods,^{18,53,54} the prognostic value of these alterations is not well established yet.^{50,55}

Two-dimensional echocardiographic evaluation of the right ventricle can be performed through an acquisition protocol with images dedicated to this investigation.⁵⁶ New methods for the assessment of right ventricular systolic function, such as the analysis of myocardial deformation (Figura 3, B), have already shown to correlate quite often to the quantification of RV ejection fraction by other methods, such as magnetic resonance imaging, in groups of patients with Chagas' disease. Although three-dimensional echocardiography presents the benefit of volumetric quantification of cavities and, as a result, of ventricular ejection fractions, its role in patients with CCC has not been adequately established yet.

Nuclear Medicine: Radioisotope ventriculography (RIV), also known as radionuclear angiocardiology, can be used as an alternative method to echocardiography to measure the LV ejection fraction (EF), and presents the advantage of being a quantitative method free from geometric inferences, thereby granting it the role of a real gold standard method in this context. When simultaneous measurement of the right and left ventricular ejection fraction (RVEF, LVEF) is required, RIV has been used successfully and may detect earlier and more severe RV dysfunction, including in patients with the digestive form of Chagas' disease.⁵⁷

Myocardial perfusion scintigraphy may be required for non-invasive investigation of Chagas disease patients with precordialgia. Negative findings for myocardial ischemia virtually excludes the presence of significant coronary artery disease, indicating a high negative predictive value. However, reversible perfusion defects have been detected in 30 to 50% of patients, in the absence of atherosclerotic epicardial CAD.⁵⁸⁻⁶⁰ These perfusion changes have been attributed to coronary microcirculation in CCC and it has been postulated that such ischemic changes can contribute to regional myocardial damage in the chronic phase of the cardiomyopathy.^{37,60} Fixed perfusion defects, on the other hand, are also frequently observed in patients with CCC and, in general, represent areas of fibrosis caused by the typical pathophysiology of Chagas disease.⁴²

Iodine-123-labeled meta-iodobenzylguanidine myocardial scintigraphy (¹²³I-MIBG) allows the non-invasive evaluation of the neuronal integrity of the cardiac sympathetic nervous system at a myocardial level. The use of this imaging technique allowed the identification of regional myocardial denervation in early stages of chronic Chagas' disease in patients with no apparent impairment of left ventricular function, involving mainly the basal parts of the posterolateral

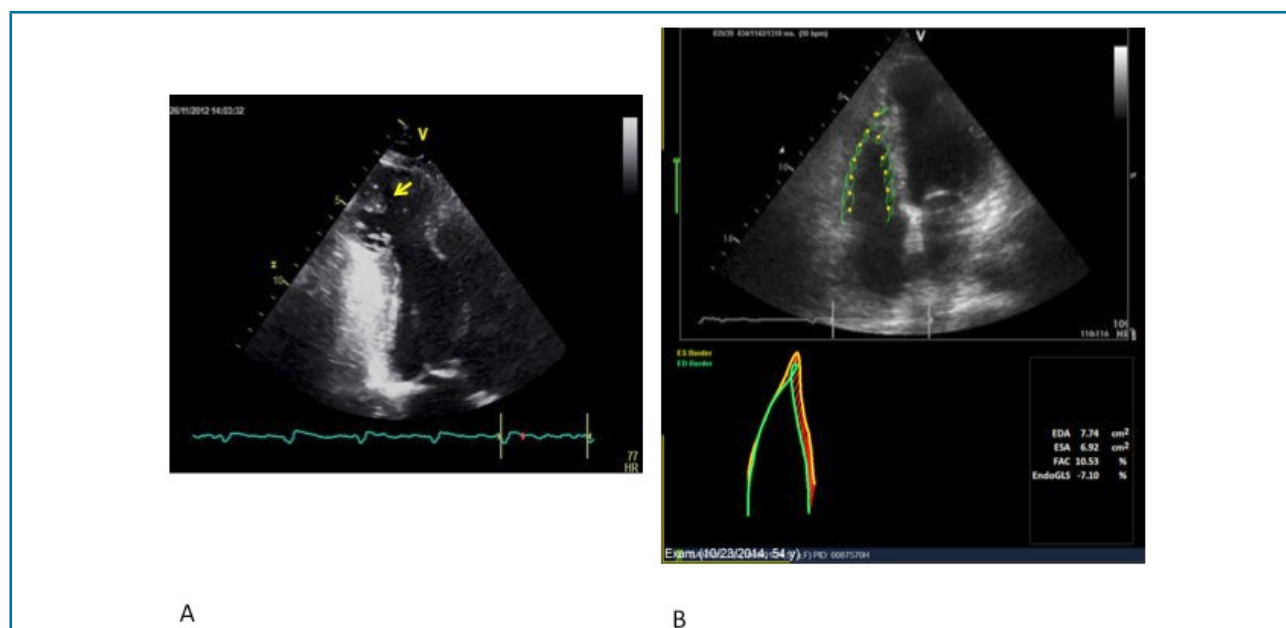

Figure 3 – Chart A: Echocardiography of apical two-chamber view of the left ventricle shows an image suggestive of a large apical aneurysm filled with thrombus (yellow arrow). Chart B: Point Tracking Technique (Speckle tracking) supporting the analysis of RV systolic function in a patient with Chagas' disease. EDA: end-diastole area; ESA: end-systole area; FAC: Fractional area change; GLS-endo: Global longitudinal strain in the endocardial layer.

and inferior walls and of the apical region.⁶¹ The results of these studies suggest that the extension/severity of the regional myocardial denervation and the intensity of the global derangement of sympathetic innervation (detected in planar images) correlate with the severity of LV systolic dysfunction.⁶¹ A more recent study has shown that cardiac patients with preserved or slightly reduced systolic function and sustained ventricular tachycardia (SVT) presented greater extension of sympathetic denervation evaluated by 123I-MIBG myocardial scintigraphy, compared to individuals without SVT, which reinforces the idea that autonomic cardiac denervation can play an important role in the arrhythmogenesis of this myocardial disease - Figure 4.³⁹

Magnetic Resonance Imaging: MRI is a methodology which allows analysis of morpho-functional parameters of the heart with high degree of two-dimensional detailing, and can be quite elucidative, especially in cases where the quality of the echocardiographic images is poor, or when there are ventricular cavities with advanced geometric changes, making it difficult to perform echocardiographic measurement with the usual techniques. It is a method with great capacity for quantitative analysis of ventricular volumes and accurate calculation of LV ejection fraction.⁶²⁻⁶⁶ It can also be quite useful for specific analysis of the right ventricular cavity, according to recent studies.⁶⁷ More recent studies call attention for the potential of

MRI for detecting the regions of myocardial fibrosis in patients with CCC and for being a potentially valuable non-invasive risk prediction tool to assess sudden death risk in these patients, even in those with preserved left ventricular ejection fraction.³⁸ The fibrosis pattern is varied, with the presence of focal or diffusely distributed fibrosis, and even with transmural impairment, simulating a fibrosis area usually seen in myocardial infarction due to obstructive coronary disease (Figure 5).

Electrophysiological study (EPS): The general indications for EPS apply for patients with CCC. The EPS is required for the evaluation of the sinus node function and AV conduction when the origin of symptoms, particularly syncope, remains uncertain after noninvasive evaluation. In most patients with preserved left ventricular function who have nonsustained ventricular tachycardia or without spontaneous arrhythmia, the EPS does not provide any relevant additional prognostic information. The use of EPS has been proposed in survivors of sudden cardiac death and those with SVT for prognostic evaluation and indication of drug therapy and implantation of antiarrhythmic devices, but the data on the efficacy of this approach are still limited.⁶⁸⁻⁷⁰

Cardiac catheterization: CCC can mimic several clinical aspects of ischemic heart disease. In fact, patients with CCC may show precordial pain, electrocardiographic changes of the ST-T segment and pathological Q waves,

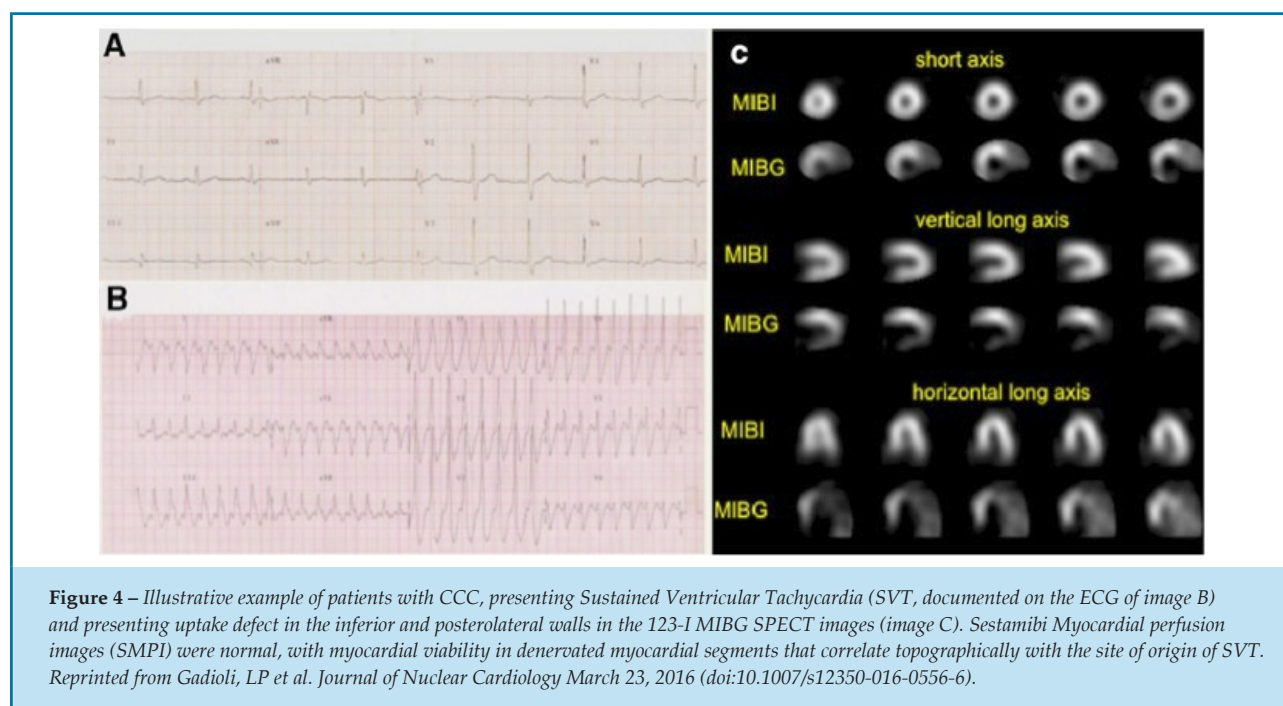

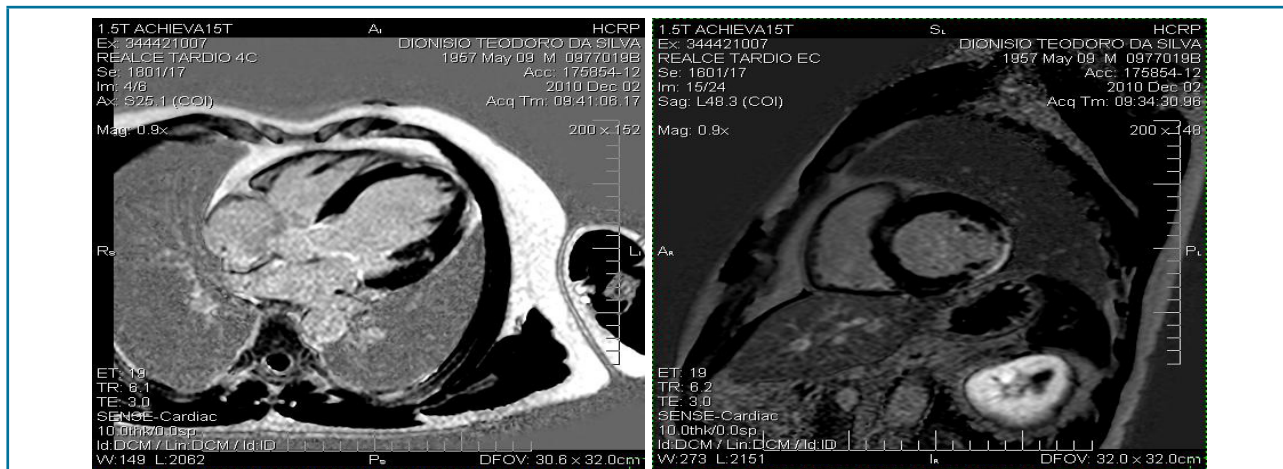


Figure 5 – Delayed enhanced images where fibrosis can be seen as the white area inserted in the (dark) muscle, indicated by arrows. Left panel shows a small mesomyocardial area in the LV lateral wall in a four-chambered image. Right panel shows extensive transmural impairment of the posterolateral wall.

in addition to changes in LV segmental parietal mobility. Thus, the requirement of coronary angiography is not uncommon to rule out the presence of coronary artery disease in patients with risk factors for this condition. As stressed above, in the vast majority of patients referred for cardiac catheterization, with CCC, the subepicardial coronary arteries are essentially normal or have non-significant hemodynamically obstructive lesions.^{42,59}

Prognosis

The prognosis of CCC depends on various factors, among them the stage of the disease presented by each patient, as already described in this text.

In the chronic phase, in relation to the clinical form with LV impairment, several observational series have shown worse prognosis in patients with CCC compared to those with other heart diseases manifested by heart failure. In a recent prospective observational study, including 456 patients with heart failure, the 68 patients with CCC had lower survival compared to the ones with other etiologies.⁷¹ Several pathophysiological factors can explain this difference, but some prognostic markers have already been defined as independent predictors, among them LV contractile dysfunction, both evaluated by echocardiography and suggested by cardiomegaly on chest x-ray.^{4,72}

The Rassi score, used for mortality risk stratification in patients with chronic chagasic cardiopathy,^{9,73-75} consists of points assigned to simple characteristics and obtained

through basic assignment methods (Table 1). This score allows detecting relevant extracts on the risk of mortality in patients with CCC.

Over about 10 years of follow-up, patients classified as low risk (score from 0 to 6) had mortality of 9 to 10%; those with intermediate risk (score between 7 and 11) had mortality from 37 to 44% and those with high risk (score between 12 and 20) had mortality from 84 to 85%. The combination of LV systolic function (even if only regional) and NSVT was associated with a particularly elevated risk of mortality, of the order of 15.1 times. The detection of NSVT alone was associated with a 2.15 times increase in death.

Figure 6 reproduces the algorithm for risk stratification in patients with CCC, derived from a systematic review of observational studies.⁷³

Treatment

Etiological Treatment

The role of antiparasitic agents in the treatment of *T. cruzi* infection is considerably limited in the chronic phase of Chagas heart disease, since much reversal of established tissue damage should not be expected at these advanced stages of the disease.⁷⁶

The BENEFIT study,⁷⁷ released in 2015, was the only large-scale clinical trial carried out on Chagas Disease. The study randomized 2854 patients, who received benznidazole or placebo, with the essential

Table 1 – Rassi score for mortality risk stratification in patients with chronic chagasic cardiopathy

Clinical Characteristic	Punctuation
Male Gender	2
ECG with low QRS voltage	2
Nonsustained ventricular tachycardia	3
Global LV alteration or LV segmental motion	3
Cardiomegaly on chest x-ray	5
Heart failure FC III-IV (NYHA)	5

objective of evaluating the efficacy of this treatment. Trypanosomicidal treatment was only effective to detect negative parasitological test results evaluated by the polymerase chain reaction technique (PCR) (66% in the treatment group versus 34% in the control group) even though a negative result did not correlate with clinical benefit over the 5-year follow-up.⁷⁶ After the initial publication of the results, supplementary analysis comparing the outcomes verified in Brazil with the ones obtained in the other four countries allows the hypothesis that, probably due to the predominance of *T. cruzi* lineage II, which is more sensitive to the trypanocidal action of benznidazole, in Brazil, the effect of the etiological treatment may turn out to have a clinical benefit for chronically infected Brazilian patients without very advanced heart disease.⁷⁷ Thus, the treatment could be offered, on an individual basis, for patients with this profile, in order to reach a potential decision following sharing models with the responsible physician.

Heart Failure Treatment

Drug Therapy

There is a clear lack of evidence supporting the clinical benefit of conventional systolic heart failure drug therapy, based primarily on neurohormonal block, in patients with CCC. However, considering that the general phenotype of HF caused by CCC is that of a dilated cardiomyopathy, the treatment for heart failure of other etiologies is empirically extrapolated for the treatment of patients suffering from CCC. This position was ratified by the recommendations of the Brazilian Guidelines on Diagnosis and Treatment of Chronic HF according to which all treatment recommendations were extended to the etiology of CCC.⁷⁸

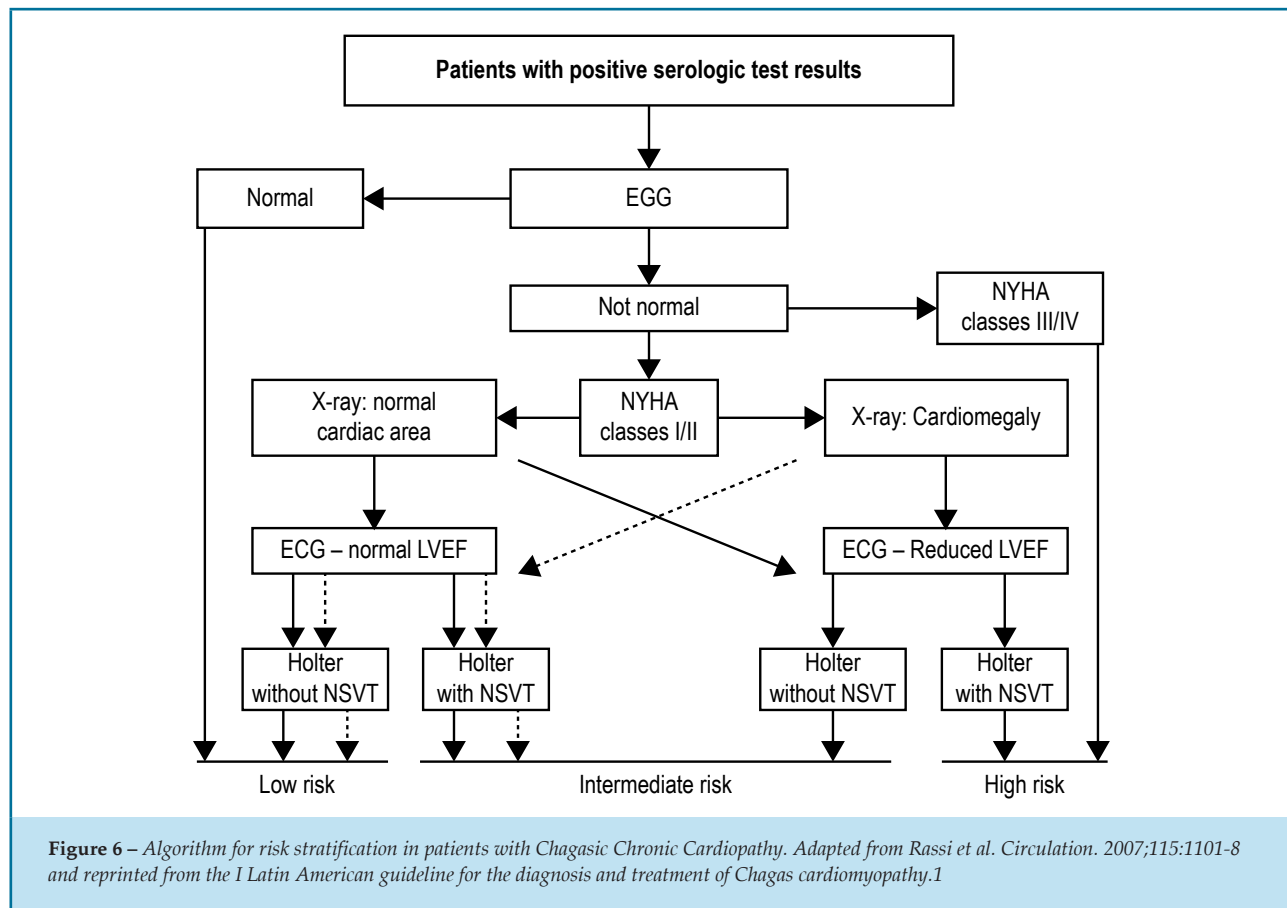
However, certain particularities in the management of patients with HF secondary to CCC must be highlighted. Several studies suggest that these patients exhibit a higher risk of symptomatic bradycardia and AV block with the use of beta-blockers, thus the heart rate in these patients must be carefully monitored. This precaution is especially applicable when, due to antiarrhythmic indication, amiodarone has already been initiated for the patient. In spite of this aspect, the results of a recent prospective observational cohort study suggest that beta-blockers can have a positive effect on the survival in patients with chronic HF caused by CCC.⁷⁹

Alternative therapies

Several clinical studies have shown that the efficacy of the *cardiac resynchronization therapy*, through multisite pacemaker implantation, depends on the presence of left bundle branch block on ECG, a pattern found in the vast majority of patients included in large multicenter studies who have tested this therapy. However, due to evident predominance of RBBB, the usefulness of CRT in patients with CCC has not been demonstrated.

Heart transplantation has been successfully used in patients with advanced HF secondary to CCC.⁸⁰ In a study of 117 patients with CCC who received the transplant, the survival reported at 1, 4, 8 and 12 years after the procedure, was 71, 57, 55 and 46%, respectively. These observational studies show that the survival of patients with CCC was better than that observed in patients with HF of other etiologies,⁸¹ which seems to be a consequence of several aspects, such as less advanced age and lower number of comorbidities in transplanted patients with CCC.

This series of cases has also shown that the reactivation of the *T. cruzi* infection is a common clinical problem, as a result of post-transplantation immunosuppression, and sometimes



difficult to differentiate from organ rejection; however, results through the use of trypanosomicidal therapy were found.

Treatment of cardiac arrhythmias

Bradycardias and AV block

Patients with second- or third-degree AVB or symptomatic sinus node dysfunction require definitive pacemaker implantation. In this respect, CCC does not seem to differ from other etiologies, and usual guidelines for indicating these devices must be followed.

Arritmias ventriculares e morte súbita arritmica

The optimal approach for the management of severe ventricular arrhythmias and resuscitated sudden cardiac death secondary to CCC is still uncertain due to absolute lack of data. The first therapeutic measure in patients with CCC under risk of malignant ventricular arrhythmia is the optimization of drug therapy for those who also have heart failure, preferably with the concomitant use of beta-blockers and amiodarone.

The ICD implantation is useful in the secondary prevention of sudden cardiac death, in survivors of sudden arrhythmic death or with sustained ventricular tachycardia, especially when accompanied by hemodynamic instability. For those who are not candidates for the implantation of this device, the use of amiodarone is recommended. In fact, there is acceptable evidence of potential benefit for this antiarrhythmic drug in patients with ventricular arrhythmias of Chagas disease etiology. The concomitant use of amiodarone and beta-blockers is also recommended routinely to reduce the number of therapies, even when appropriate, due to ICD implantation in patients with CCC.

A multicenter randomized trial (CHAGASICS) is underway to assess the ICD benefit versus amiodarone, for primary prevention of sudden death in patients with CCC and high Rassi score.⁸² Amiodarone can be used, ideally associated with a beta-blocker, for patients with CCC, Rassi risk score of ≥ 10 points and nonsustained ventricular tachycardia detected on Holter monitoring.

Author contributions

Conception and design of the research: Simões MV, Romano MMD, Schmidt A, Martins KSM. Acquisition of data: Simões MV, Romano MMD, Schmidt A, Martins KSM. Analysis and interpretation of the data: Simões MV, Romano MMD, Marin-Neto JA. Writing of the manuscript: Simões MV, Romano MMD, Schmidt A, Martins KSM, Marin-Neto JA. Critical revision of the manuscript for intellectual content: Simões MV, Romano MMD, Schmidt A, Marin-Neto JA.

Potential Conflict of Interest

No potential conflict of interest relevant to this article was reported.

Sources of Funding

There were no external funding sources for this study.

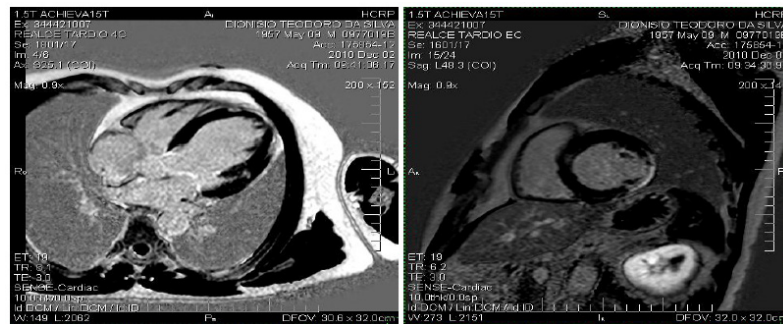Study Association

This study is not associated with any thesis or dissertation work.

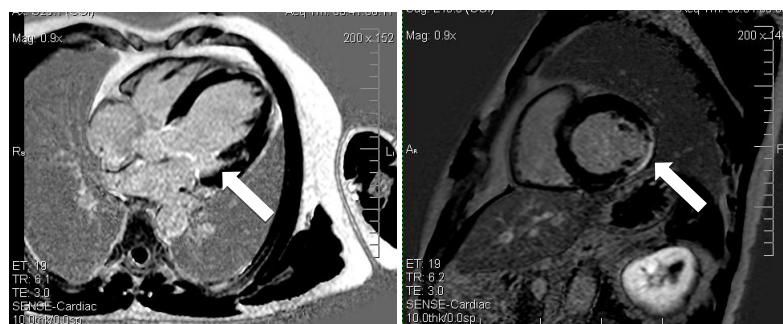Erratum

In the manuscript "Chagas Disease Cardiomyopathy", DOI number: : 10.5935/2359-4802.20180011, published in the International Journal of Cardiovascular Sciences, 2018;31(2):173-189, on page: 183, Figure 5 – Delayed enhanced images where fibrosis can be seen as the white area inserted in the (dark) muscle, indicated by arrows. Left panel shows a small mesomyocardial area in the LV lateral wall in a four-chambered image. Right panel shows extensive transmural impairment of the posterolateral wall.

Where it read:



Now it reads:



References

- Andrade JP, Marin-Neto JA, Paola AA, Vilas-Boas F, Oliveira GM, Bacal F, et al; Sociedade Brasileira de Cardiologia. [Latin American guidelines for the diagnosis and treatment of Chagas cardiomyopathy]. *Arq Bras Cardiol.* 2011;97(2 Suppl 3):1-48. PMID: 21952638.
- Marin-Neto JA, Rassi A Jr. Update on Chagas heart disease on the first centenary of its discovery. *Rev Esp Cardiol.* 2009;62(11):1211-6. PMID: 19889330.
- Wanderley DM, Correa FM. Epidemiology of Chagas' heart disease. *Sao Paulo Med J.* 1995;113(2):742-9. doi: <http://dx.doi.org/10.1590/S1516-31801995000200003>.
- Rassi A Jr, Rassi A, Marin-Neto JA. Chagas disease. *Lancet.* 2010;375(9723):1388-402. doi: [10.1016/S0140-6736\(10\)60061-X](https://doi.org/10.1016/S0140-6736(10)60061-X).
- World Health Organization. (WHO). UNICEF/UNDP/World Bank/WHO Special Programme for Research and Training in Tropical Diseases., Pan American Health Organization. Reporte del grupo de trabajo científico sobre la enfermedad de Chagas : 17-20 de abril de 2005, actualizado en julio de 2007, Buenos Aires (Argentina); 2007.
- World Health Organization. (WHO). First WHO Report on neglected tropical diseases: working to overcome the global impact of neglected tropical diseases. In: Organization WH. (editor): Geneva; 2010. p. 172.
- World Health Organization. (WHO). Control of Chagas' disease: second report of the WHO expert committee. Geneva; 2002. (WHO technical report series, 905).
- Marin-Neto JA, Almeida Filho OC, Pazin-Filho A, Maciel BC. [Indeterminate form of Chagas' disease: proposal of new diagnostic criteria and perspectives for early treatment of cardiomyopathy]. *Arq Bras Cardiol.* 2002;79(6):623-7. PMID: 12532446..
- Rassi Jr A, Rassi A, Marin-Neto JA. Chagas heart disease: pathophysiologic mechanisms, prognostic factors and risk stratification. *Mem Inst Oswaldo Cruz.* 2009;104 Suppl 1:152-8. doi: <http://dx.doi.org/10.1590/S0074-02762009000900021>.
- Coura JR, De Abreu LL, Dubois LE, Lima FD, De Arruda Junior E, Willcox HP, et al. [Morbidity of Chagas' disease. II - Sectional studies in 4 field areas in Brazil]. *Mem Inst Oswaldo Cruz.* 1984;79(1):101-24. doi: <http://dx.doi.org/10.1590/S0074-02761984000100012>.
- Marin-Neto JA, Cunha-Neto E, Maciel BC, Simoes MV. Pathogenesis of chronic Chagas heart disease. *Circulation.* 2007;115(9):1109-23. doi: [10.1161/CIRCULATIONAHA.106.624296](https://doi.org/10.1161/CIRCULATIONAHA.106.624296).
- Dias E, Laranja FS, Miranda A, Nobrega G. Chagas' disease; a clinical, epidemiologic, and pathologic study. *Circulation.* 1956;14(6):1035-60. PMID: 13383798.
- Coura JR, Vinas PA, Brum-Soares LM, de Sousa AS, Xavier SS. Morbidity of Chagas heart disease in the microregion of Rio Negro, Amazonian Brazil: a case-control study. *Mem Inst Oswaldo Cruz.* 2013;108(8):1009-13. doi: <http://dx.doi.org/10.1590/0074-0276130425>.
- Souza FF, Castro ES, Marin Neto JA, Sankarankutty AK, Teixeira AC, Martinelli AL, et al. Acute chagasic myocardiopathy after orthotopic liver transplantation with donor and recipient serologically negative for *Trypanosoma cruzi*: a case report. *Transplant Proc.* 2008;40(3):875-8. doi: [10.1016/j.transproceed.2008.02.032](https://doi.org/10.1016/j.transproceed.2008.02.032).
- Wegner DH, Rohwedder RW. The effect of nifurtimox in acute Chagas' infection. *Arzneimittelforschung.* 1972;22(9):1624-35. PMID: 4630485.
- Kirchhoff LV. Chagas disease. *American trypanosomiasis. Infect Dis Clin North Am.* 1993;7(3):487-502. PMID: 8254156.
- Pazin-Filho A, Romano MM, Almeida-Filho OC, Furuta MS, Viviani LF, Schmidt A, et al. Minor segmental wall motion abnormalities detected in patients with Chagas' disease have adverse prognostic implications. *Braz J Med Biol Res.* 2006;39(4):483-7. doi: <http://dx.doi.org/10.1590/S0100-879X2006000400008>.
- Garcia-Alvarez A, Sitges M, Regueiro A, Poyatos S, Jesus Pinazo M, Posada E, et al. Myocardial deformation analysis in Chagas heart disease with the use of speckle tracking echocardiography. *J Card Fail.* 2011;17(12):1028-34. doi: [10.1016/j.cardfail.2011.08.007](https://doi.org/10.1016/j.cardfail.2011.08.007).
- Dias JC. The indeterminate form of human chronic Chagas' disease: a clinical epidemiological review. *Rev Soc Bras Med Trop.* 1989;22(3):147-56. <http://dx.doi.org/10.1590/S0037-86821989000300007>.
- Marin-Neto JA, Simoes MV, Sarabanda AV. Forma crônica cardíaca. *Trypanosoma cruzi e Doença de Chagas.* 2ª ed. São Paulo: Guanabara-Koogan; 2000. p. 266-96.
- Ianni BM, Arteaga E, Frimm CC, Pereira Barretto AC, Mady C. Chagas' heart disease: evolutive evaluation of electrocardiographic and echocardiographic parameters in patients with the indeterminate form. *Arq Bras Cardiol.* 2001;77(1):59-62. doi: <http://dx.doi.org/10.1590/S0066-782X2001000700006>.
- Rassi A Jr, Rassi SG, Rassi A. Sudden death in Chagas' disease. *Arq Bras Cardiol.* 2001;76(1):75-96. doi: <http://dx.doi.org/10.1590/S0066-782X2001000100008>.
- Carod-Artal FJ, Vargas AP, Horan TA, Nunes LG. Chagasic cardiomyopathy is independently associated with ischemic stroke in Chagas disease. *Stroke.* 2005;36(5):965-70. doi: [10.1161/01.STR.0000163104.92943.50](https://doi.org/10.1161/01.STR.0000163104.92943.50).
- Maguire JH, Hoff R, Sherlock I, Guimaraes AC, Sleight AC, Ramos NB, et al. Cardiac morbidity and mortality due to Chagas' disease: prospective electrocardiographic study of a Brazilian community. *Circulation.* 1987;75(6):1140-5. PMID: 3552307.
- Forichon E. Contribution aux estimations de morbidité et de mortalité dans la maladie de Chagas. Toulouse (France): Univers. Paul Sabatier; 1974.
- Nunes MC, Dones W, Morillo CA, Encina JJ, Ribeiro AL; Council on Chagas Disease of the Interamerican Society of Cardiology. Chagas disease: an overview of clinical and epidemiological aspects. *J Am Coll Cardiol.* 2013;62(9):767-76. doi: [10.1016/j.jacc.2013.05.046](https://doi.org/10.1016/j.jacc.2013.05.046).
- Manzullo EC, Darraidou MA, Libonatti O, Rozlosnik J, Bazzano AC. Estudio longitudinal de la cardiopatía chagásica crónica. [Tese]. Centro de Chagas de la Catedra de Enfermedades Infecciosas de la Facultad de Ciencias Medicas de Buenos Aires. Buenos Aires; 1982.
- Chagas C. A short chronicle of the discovery of Chagas' disease. *Pacing Clin Electrophysiol.* 1988;11(7):1108-13. PMID: 2457892.
- Samuel J, Oliveira M, Correa De Araujo RR, Navarro MA, Muccillo G. Cardiac thrombosis and thromboembolism in chronic Chagas' heart disease. *Am J Cardiol.* 1983;52(1):147-51. PMID: 6858902.
- Nunes Mdo C, Barbosa MM, Rocha MO. Peculiar aspects of cardiogenic embolism in patients with Chagas' cardiomyopathy: a transthoracic and transesophageal echocardiographic study. *J Am Soc Echocardiogr.* 2005;18(7):761-7. doi: [10.1016/j.echo.2005.01.026](https://doi.org/10.1016/j.echo.2005.01.026).
- Carod-Artal FJ, Gascon J. Chagas disease and stroke. *Lancet Neurol.* 2010;9(5):533-42. doi: [10.1016/S1474-4422\(10\)70042-9](https://doi.org/10.1016/S1474-4422(10)70042-9).
- Cardoso RN, Macedo FY, Garcia MN, Garcia DC, Benjo AM, Aguilar D, et al. Chagas' cardiomyopathy is associated with higher incidence of stroke: a meta-analysis of observational studies. *J Card Fail.* 2014;20(12):931-8. doi: [10.1016/j.cardfail.2014.09.003](https://doi.org/10.1016/j.cardfail.2014.09.003).
- Souza AS, Xavier SS, Freitas GR, Hasslocher-Moreno A. Prevention strategies of cardioembolic ischemic stroke in Chagas' disease. *Arq Bras Cardiol.* 2008;91(5):306-10. doi: <http://dx.doi.org/10.1590/S0066-782X2008001700004>.
- Rassi Junior A, Gabriel Rassi A, Gabriel Rassi S, Rassi Junior L, Rassi A. [Ventricular arrhythmia in Chagas disease. Diagnostic, prognostic, and therapeutic features]. *Arq Bras Cardiol.* 1995;65(4):377-87. PMID: 8728815.

35. Sarabanda AV, Sosa E, Simoes MV, Figueiredo GL, Pintya AO, Marin-Neto JA. Ventricular tachycardia in Chagas' disease: a comparison of clinical, angiographic, electrophysiologic and myocardial perfusion disturbances between patients presenting with either sustained or nonsustained forms. *Int J Cardiol.* 2005;102(1):9-19. doi: 10.1016/j.ijcard.2004.03.087.
36. Rochitte CE, Oliveira PF, Andrade JM, Ianni BM, Parga JR, Avila LF, et al. Myocardial delayed enhancement by magnetic resonance imaging in patients with Chagas' disease: a marker of disease severity. *J Am Coll Cardiol.* 2005;46(8):1553-8. doi: 10.1016/j.jacc.2005.06.067.
37. Mello RP, Szarf G, Schwartzman PR, Nakano EM, Espinosa MM, Szejnfeld D, et al. Delayed enhancement cardiac magnetic resonance imaging can identify the risk for ventricular tachycardia in chronic Chagas' heart disease. *Arq Bras Cardiol.* 2012;98(5):421-30. doi: http://dx.doi.org/10.1590/S0066-782X2012005000031.
38. Schmidt A, Romano MM, Maciel BC, Marin-Neto JA. Cardiac magnetic resonance imaging for sudden cardiac death: much more than another method to measure LVEF. *Current Cardiovascular Imaging Reports.* 2013;6(6):431-4.
39. Miranda CH, Figueiredo AB, Maciel BC, Marin-Neto JA, Simoes MV. Sustained ventricular tachycardia is associated with regional myocardial sympathetic denervation assessed with 123I-metaiodobenzylguanidine in chronic Chagas cardiomyopathy. *J Nucl Med.* 2011;52(4):504-10. doi: 10.2967/jnumed.110.082032.
40. Mendoza I, Camardo J, Moleiro F, Castellanos A, Medina V, Gomez J, et al. Sustained ventricular tachycardia in chronic chagasic myocarditis: electrophysiologic and pharmacologic characteristics. *Am J Cardiol.* 1986;57(6):423-7. PMID: 3946258.
41. Radico F, Cicchitti V, Zimarino M, De Caterina R. Angina pectoris and myocardial ischemia in the absence of obstructive coronary artery disease: practical considerations for diagnostic tests. *JACC Cardiovasc Interv.* 2014;7(5):453-63. doi: 10.1016/j.jcin.2014.01.157.
42. Marin-Neto JA, Simoes MV, Rassi Junior A. Pathogenesis of chronic Chagas cardiomyopathy: the role of coronary microvascular derangements. *Rev Soc Bras Med Trop.* 2013;46(5):536-41. doi: http://dx.doi.org/10.1590/0037-8682-0028-2013.
43. da Silveira JF, Umezawa ES, Luquetti AO. Chagas disease: recombinant *Trypanosoma cruzi* antigens for serological diagnosis. *Trends Parasitol.* 2001;17(6):286-91. PMID: 11378036.
44. Dias JC, Kloetzel K. The prognostic value of the electrocardiographic features of chronic Chagas' disease. *Rev Inst Med Trop Sao Paulo.* 1968;10(3):158-62. PMID: 4982469.
45. Strauss DG, Cardoso S, Lima JA, Rochitte CE, Wu KC. ECG scar quantification correlates with cardiac magnetic resonance scar size and prognostic factors in Chagas' disease. *Heart.* 2011;97(5):357-61. doi: 10.1136/hrt.2010.210047.
46. Acquatella H. Echocardiography in Chagas heart disease. *Circulation.* 2007;115(9):1124-31. doi: 10.1161/CIRCULATIONAHA.106.627323.
47. Bem C, Montgomery SP, Herwaldt BL, Rassi A Jr, Marin-Neto JA, Dantas RO, et al. Evaluation and treatment of chagas disease in the United States: a systematic review. *JAMA.* 2007;298(18):2171-81. doi: 10.1001/jama.298.18.2171.
48. Patel AR, Lima C, Parro A, Arsenault M, Vannan MA, Pandian NG. Echocardiographic analysis of regional and global left ventricular shape in Chagas' cardiomyopathy. *Am J Cardiol.* 1998;82(2):197-202. PMID: 9678291.
49. Sousa AC, Marin-Neto JA, Maciel BC, Gallo Junior L, Amorim Dde S, Barreto-Martins LE. [Systolic and diastolic dysfunction in the indeterminate, digestive and chronic cardiac forms of Chagas' disease]. *Arq Bras Cardiol.* 1988;50(5):293-9. PMID: 3240108.
50. Viotti RJ, Vigliano C, Laucella S, Lococo B, Petti M, Bertocchi G, et al. Value of echocardiography for diagnosis and prognosis of chronic Chagas disease cardiomyopathy without heart failure. *Heart.* 2004;90(6):655-60. PMID: 15145872.
51. de Almeida-Filho OC, Maciel BC, Schmidt A, Pazin-Filho A, Marin-Neto JA. Minor segmental dyssynergy reflects extensive myocardial damage and global left ventricle dysfunction in chronic Chagas disease. *J Am Soc Echocardiogr.* 2002;15(6):610-6. PMID: 12050602.
52. Pazin-Filho A, Romano MM, Gomes Furtado R, de Almeida Filho OC, Schmidt A, Marin-Neto JA, et al. Left ventricular global performance and diastolic function in indeterminate and cardiac forms of Chagas' disease. *J Am Soc Echocardiogr.* 2007;20(12):1338-43. doi: 10.1016/j.echo.2007.04.029.
53. Gomes VA, Alves GF, Hadlich M, Azevedo CF, Pereira IM, Santos CR, et al. Analysis of regional left ventricular strain in patients with chagas disease and normal left ventricular systolic function. *J Am Soc Echocardiogr.* 2016;29(7):679-88. doi: 10.1016/j.echo.2016.03.007.
54. Barbosa MM, Costa Rocha MO, Vidigal DF, Bicalho Carneiro Rde C, Araújo RD, Palma MC, et al. Early detection of left ventricular contractility abnormalities by two-dimensional speckle tracking strain in Chagas' disease. *Ecocardiography.* 2014;31(5):623-30. doi: 10.1111/echo.12426.
55. Rudski LG, Lai WW, Afilalo J, Hua L, Handschumacher MD, Chandrasekaran K, et al. Guidelines for the echocardiographic assessment of the right heart in adults: a report from the American Society of Echocardiography endorsed by the European Association of Echocardiography, a registered branch of the European Society of Cardiology, and the Canadian Society of Echocardiography. *J Am Soc Echocardiogr.* 2010;23(7):685-713. doi: 10.1016/j.echo.2010.05.010.
56. Moreira HT, Volpe GJ, Marin-Neto JA, Nwabuo CC, Ambale-Venkatesh B, Gali LG, et al. Right ventricular systolic dysfunction in Chagas disease defined by speckle-tracking echocardiography: a comparative study with cardiac magnetic resonance imaging. *J Am Soc Echocardiogr.* 2017;30(5):493-502. doi: 10.1016/j.echo.2017.01.010.
57. Marin-Neto JA, Bromberg-Marín G, Pazin-Filho A, Simoes MV, Maciel BC. Cardiac autonomic impairment and early myocardial damage involving the right ventricle are independent phenomena in Chagas' disease. *Int J Cardiol.* 1998;65(3):261-9. PMID: 9740483.
58. Simoes MV, Ayres EM, Santos JL, Schmidt A, Pintya AO, Maciel BC, et al. [Detection of myocardial ischemia in chronic Chagas disease patients with atypical precordial pain by exercise and Holter tests]. *Arq Bras Cardiol.* 1993;60(5):315-9. PMID: 831747.
59. Marin-Neto JA, Simoes MV, Ayres-Neto EM, Attab-Santos JL, Gallo L Jr, Amorim DS, et al. Studies of the coronary circulation in Chagas' heart disease. *Sao Paulo Med J.* 1995;113(2):826-34. doi: http://dx.doi.org/10.1590/S1516-31801995000200014.
60. Hiss FC, Lascala TF, Maciel BC, Marin-Neto JA, Simoes MV. Changes in myocardial perfusion correlate with deterioration of left ventricular systolic function in chronic Chagas' cardiomyopathy. *JACC Cardiovasc Imaging.* 2009;2(2):164-72. doi: 10.1016/j.jcmg.2008.09.012.
61. Simoes MV, Pintya AO, Bromberg-Marín G, Sarabanda AV, Antloga CM, Pazin-Filho A, et al. Relation of regional sympathetic denervation and myocardial perfusion disturbance to wall motion impairment in Chagas' cardiomyopathy. *Am J Cardiol.* 2000;86(9):975-81. PMID: 11053710.
62. Kalil Filho R, de Albuquerque CP. Magnetic resonance imaging in Chagas' heart disease. *Sao Paulo Med J.* 1995;113(2):880-3. doi: http://dx.doi.org/10.1590/S1516-31801995000200022.
63. Bocchi EA, Kalil R, Bacal F, de Lourdes Higuchi M, Meneghetti C, Magalhaes A, et al. Magnetic resonance imaging in chronic Chagas' disease: correlation with endomyocardial biopsy findings and Gallium-67 cardiac uptake. *Echocardiography.* 1998;15(3):279-88. PMID: 11175041.
64. Rochitte CE, Nacif MS, de Oliveira Junior AC, Siqueira-Batista R, Marchiori E, Uellendahl M, et al. Cardiac magnetic resonance in Chagas' disease. *Artif Organs.* 2007;31(4):259-67. doi: 10.1111/j.1525-1594.2007.00373.x.

65. Moreira HT, Volpe GJ, Marin-Neto JA, Ambale-Venkatesh B, Nwabuo CC, Trad HS, et al. Evaluation of right ventricular systolic function in Chagas disease using cardiac magnetic resonance imaging. *Circ Cardiovasc Imaging*. 2017;10(3). pii: e005571. doi: 10.1161/CIRCIMAGING.116.005571.
66. Moreira HT, Volpe GJ, Marin-Neto JA, Nwabuo CC, Ambale-Venkatesh B, Gali LG, et al. Right ventricular systolic dysfunction in Chagas disease defined by speckle-tracking echocardiography: a comparative study with cardiac magnetic resonance imaging. *J Am Soc Echocardiogr*. 2017;30(5):493-502. doi: 10.1016/j.echo.2017.01.010.
67. Moreira HT, Volpe GJ, Trad HS, Santos MK, Romano MD, Pazin-Filho A, et al. Right ventricular dysfunction in Chagas' cardiomyopathy. Primary involvement or a resonant manifestation of left ventricular dysfunction? *J Cardiovasc Magn Reson*. 2014;16(Suppl 1):P301.
68. Scanavacca M, Sosa E. Electrophysiologic study in chronic Chagas' heart disease. *Sao Paulo Med J*. 1995;113(2):841-50. doi: http://dx.doi.org/10.1590/S1516-31801995000200016.
69. de Paola AA, Horowitz LN, Miyamoto MH, Pinheiro R, Ferreira DF, Terzian AB, et al. Angiographic and electrophysiologic substrates of ventricular tachycardia in chronic Chagasic myocarditis. *Am J Cardiol*. 1990;65(5):360-3. PMID: 2301265.
70. Leite LR, Fenelon G, Simoes A Jr, Silva GG, Friedman PA, de Paola AA. Clinical usefulness of electrophysiologic testing in patients with ventricular tachycardia and chronic chagasic cardiomyopathy treated with amiodarone or sotalol. *J Cardiovasc Electrophysiol*. 2003;14(6):567-73. PMID: 12875414.
71. Issa VS, Bocchi EA. Antitrypanosomal agents: treatment or threat? *Lancet*. 2010;376(9743):768; author reply -9. doi: 10.1016/S0140-6736(10)61372-4.
72. Silva CP, Del Carlo CH, Oliveira Junior MT, Scipioni A, Strunz-Cassaró C, Ramirez JA, et al. Why do patients with chagasic cardiomyopathy have worse outcomes than those with non-chagasic cardiomyopathy? *Arq Bras Cardiol*. 2008;91(6):358-62. doi: http://dx.doi.org/10.1590/S0066-782X2008001800006.
73. Meira WS, de Castro AM, Gontijo ED, Rassi A, Luquetti AO, Machado-Coelhos GL, et al. [Evaluation of blood tests, complement-mediated lysis and polymerase chain reaction in the verification of therapeutic efficacy in Chagas disease]. *Rev Soc Bras Med Trop*. 2006;39 Suppl 3:107-9. PMID: 17605216.
74. Rassi A Jr, Rassi A, Rassi SG. Predictors of mortality in chronic Chagas disease: a systematic review of observational studies. *Circulation*. 2007;115(9):1101-8. doi: 10.1161/CIRCULATIONAHA.106.627265.
75. Rassi A Jr, Rassi A, Little WC, Xavier SS, Rassi SG, Rassi AG, et al. Development and validation of a risk score for predicting death in Chagas' heart disease. *N Engl J Med*. 2006;355(8):799-808. doi: 10.1056/NEJMoa053241.
76. Morillo CA, Marin-Neto JA, Avezum A, Sosa-Estani S, Rassi A Jr, Rosas F, et al; BENEFIT Investigators. Randomized trial of benznidazole for chronic Chagas' cardiomyopathy. *N Engl J Med*. 2015;373(14):1295-306. doi: 10.1056/NEJMoa1507574.
77. Rassi A Jr, Marin JA Neto, Rassi A. Chronic Chagas cardiomyopathy: a review of the main pathogenic mechanisms and the efficacy of aetiological treatment following the BENznidazole Evaluation for Interrupting Trypanosomiasis (BENEFIT) trial. *Mem Inst Oswaldo Cruz*. 2017;112(3):224-35. doi: 10.1590/0074-02760160334.
78. Bocchi EA, Marcondes-Braga FG, Bacal F, Ferraz AS, Albuquerque D, Rodrigues Dde A, et al. Atualização da diretriz brasileira de insuficiência cardíaca crônica. *Arq Bras Cardiol*. 2012;98(1 Suppl 1):1-33. doi: http://dx.doi.org/10.1590/50066-782X2012000700001.
79. Issa VS, Amaral AF, Cruz FD, Ferreira SM, Guimaraes GV, Chizzola PR, et al. Beta-blocker therapy and mortality of patients with Chagas cardiomyopathy: a subanalysis of the REMADHE prospective trial. *Circ Heart Fail*. 2010;3(1):82-8. doi: 10.1161/CIRCHEARTFAILURE.109.882035.
80. Bocchi EA, Bellotti G, Mocelin AO, Uip D, Bacal F, Higuchi ML, et al. Heart transplantation for chronic Chagas' heart disease. *Ann Thorac Surg*. 1996;61(6):1727-33. doi: 10.1016/0003-4975(96)00141-5.
81. Bocchi EA, Fiorelli A. The paradox of survival results after heart transplantation for cardiomyopathy caused by *Trypanosoma cruzi*. First Guidelines Group for Heart Transplantation of the Brazilian Society of Cardiology. *Ann Thorac Surg*. 2001;71(6):1833-8. PMID: 11426756.
82. Martinelli M, Rassi A Jr, Marin-Neto JA, de Paola AA, Berwanger O, Scanavacca MI, et al. CHronic use of Amiodarone aGAINSt Implantable cardioverter-defibrillator therapy for primary prevention of death in patients with Chagas cardiomyopathy Study: rationale and design of a randomized clinical trial. *Am Heart J*. 2013;166(6):976-82 e4. doi: 10.1016/j.ahj.2013.08.027.

