

REVIEW ARTICLE

The Role of ¹⁸F-FDG PET/CT in Cardiac Sarcoidosis

Christiane Wiefels,^{1,2} Olabimpe Lamai,¹ Riina Kandolin,³ David Birnie,¹ Eugene Leung,¹ Claudio Tinoco Mesquita,² Rob Beanlands³

University of Ottawa Heart Institute,¹ Ottawa – Canada

Universidade Federal Fluminense,² Niterói, RJ – Brazil

Heart and Lung Center, Helsinki University Central Hospital,³ Helsinki – Finland

Cardiac sarcoidosis (CS) is a rare and potentially fatal condition, characterized by the presence of non-necrotizing granulomatous inflammation and concomitant fibrosis. A variety of clinical manifestation has been described, such as conduction disorders, ventricular arrhythmias, congestive heart failure and sudden cardiac death, making a prompt diagnosis and early treatment desirable. Endomyocardial biopsy is the gold-standard diagnostic test, but has a low sensitivity due to the multifocal aspect of the disease. Advanced imaging modalities, such as cardiac magnetic resonance and positron emission tomography (PET) with 18F-fluorodeoxyglucose are now part of the diagnostic criteria and also assist in determining treatment response. However, the interpretation of those studies can be challenging and needs to be made by specialists, as the misdiagnosis could be harmful for the patient. This article describes the pathophysiology of CS and advanced imaging modalities (with a major focus on PET) that should be considered for diagnostic approach and therapy monitoring. Also, newer clinical trials evaluating treatment strategies are described.

Introduction

Systemic sarcoidosis (SS) was first described more than a century ago by the Norwegian dermatologist Caesar Boeck. He correlated skin nodules with epithelioid cells

Keywords

Cardiomyopathies; Sarcoidosis; Heart Failure; Metabolism Disorders; Sudden Cardiac Death; Diagnostic, Imaging; Magnetic Resonance Imaging/diagnostic; Positron Emission Tomography Computed Tomography/diagnostic.

with large nuclei and giant cells as “multiple benign sarcoid of the skin”, for their resemblance with sarcoma.¹ Today, the cause of the disease remains unknown, but evidence points toward immunological response to an unidentified antigenic trigger in individuals with genetic susceptibility.² The estimation of the prevalence of SS in the population varies in the literature also depending on the type of study: epidemiologic, autopsy or imaging.

Some previous data showed prevalence as high as 100-330 cases per 100,000 inhabitants.^{3,4} Environmental factors have been attributed to those differences, including sex, age and ethnicity,⁵ showing a predisposition for environmental and genetic factors. The reported incidence is similar across sex in North American population but greater in females in Scandinavian and Japanese populations,^{6,7} but more likely to be chronic and fatal in black Americans.⁸ The disease usually develops before the age of 50 years, with a peak incidence at 20 to 39 years old,^{9,10} and is very uncommon under the age or 15 or older than 70.² Symptomatic cardiac sarcoidosis (CS) has been reported in 2-5% of the patients with the systemic form.¹¹⁻¹³ However, with the advance of new cardiac imaging techniques, cases of asymptomatic (clinically silent) cardiac involvement have been diagnosed.¹⁴ The disease has been reported in at least 20% of the autopsies and imaging report in the United States to as much as 50% in Japan.^{7,15}

Pathophysiology

The presence of non-necrotizing granulomatous inflammation is the major characteristic of CS and is sometimes associated with fibrosis. Histologic proof of non-necrotizing granuloma differentiates CS from

Mailing Address: Christiane Wiefels

University of Ottawa Heart Institute 40, Ruskin Street, Ottawa, ON, K1Y 4W7, Canada
E-mail: cwiefels@ottawaheart.ca

lymphocytic or viral myocarditis and from tuberculosis with necrotizing granulomas. Although frequent in the lungs, sarcoidosis may affect any organ. In addition, any part of the heart can be involved, particularly the basal septum, the lateral wall, the papillary muscle and the right ventricle. In an autopsy study of post-mortem diagnosis of CS, the scar was more frequently located in the interventricular septum, posterior left ventricle, right and anterior left ventricle and lateral left ventricle (in descending order of frequency).¹⁶ Although a positive endomyocardial biopsy (EMB) is definitive for the diagnosis of CS, its sensitivity is around 30% due to the patchy involvement of the myocardium.¹⁷

Clinical features

CS has different types of manifestations, including clinically silent form, sudden cardiac death, conduction disturbances, ventricular arrhythmias and heart failure.^{5,18-21} Other rare findings can be pericardial effusion or coronary involvement.^{13,22} CS is the most malignant manifestation of sarcoidosis and 25% of the deaths are related to the cardiac form.⁵ The extent of left systolic dysfunction has been pointed as the most significant independent predictor of mortality. Patients with severe left ventricular (LV) dysfunction with left ventricular ejection fraction (LVEF) < 30% at the time of presentation had a 10-y survival rate >80% in Japanese studies.²³ Also, the 10-year transplantation-free cardiac survival was 83% in a large population-based cohort.⁶

Diagnosis

The diagnosis of sarcoidosis requires three elements: 1) compatible clinical and radiographic manifestations; 2) exclusion of other diseases that may present similarly and 3) histopathologic detection of noncaseating granulomas. Multiple criteria have been proposed for diagnosing CS but the most commonly used are those by the Japanese Ministry of Health and Welfare (JMHW), revised in 2017²⁴ and those by the Heart Rhythm Society (HRS) published in 2014²⁵ (Tables 1 and 2). Their basic difference is that the revised 2006 criteria did not mandate positive biopsies (either cardiac or extracardiac) for the clinical diagnosis of CS. Due to its patchy and mid-myocardial involvement, EMB has an elevated number of false-negative and there is an ongoing debate whether positive histology is required for the diagnosis.²⁶ New imaging techniques – positron emission tomography (PET), cardiac magnetic

resonance imaging (MRI), electrocardiography, and electroanatomic voltage mapping – can increase the sensitivity of the EMB.²⁷ The JMHW defines the presence of myocardial Gallium-67 uptake, a SPECT tracer, as a major criterion, due to its high specificity (despite its low sensitivity). However, this radiotracer causes a high radiation exposure to the patient (high half-life of 78h) and has a lower resolution than the PET. Cardiac MRI, perfusion studies and echocardiography findings are considered minor criteria. Both 18F-fluorodeoxyglucose (18F-FDG) PET and Gallium-67 are diagnostic but have also the potential role for monitoring disease activity and therapy response. The A Case Control Etiology of Sarcoidosis Study (ACCESS) is a sarcoidosis organ assessment instrument that categorizes SS clinical manifestations as: a) highly probable, as at least 90% likelihood of sarcoidosis causing this manifestation; b) probable: 50-90% likelihood of sarcoidosis causing this manifestation of c) possible: <50% of likelihood of sarcoidosis causing this manifestation. This instrument was developed by expert opinion and is useful for clinicians and researchers in establishing criteria for sarcoidosis organ involvement.²⁸

Diagnostic imaging tools

Echocardiography

Traditionally, transthoracic echocardiography is the initial imaging modality in patients with suspected CS, as for all types of cardiomyopathy. LV systolic and diastolic function can be easily assessed, as well as LV geometry, volumes, right ventricular (RV) performance and myocardial thinning or thickening. Echocardiography is able to identify some of the CS diagnostic criteria such as depressed LVEF, basal thinning of the interventricular septum and structural or wall motion abnormality. It is important to know that echocardiography is very operator-dependent, and despite a high specificity and a positive predictive value up to 92%,²⁹ its sensitivity is reduced, and a normal study cannot rule out the presence of CS.

SPECT

SPECT studies with 99m-Tc-perfusion agents or 201-Tl are other diagnostic tools to evaluate the presence of scar at rest, as microvascular compression or fibrogranulomatous replacement of the myocardium

Table 1 – Heart Rhythm Society diagnostic criteria for cardiac sarcoidosis**Histologic diagnosis from myocardial tissue**

Noncaseating granuloma on endomyocardial biopsy with no alternative cause identified

Clinical diagnosis

Probable diagnosis of cardiac sarcoidosis exists if there is histologic diagnosis of extra-cardiac sarcoidosis and one or more of the following is present:

Cardiomyopathy or atrioventricular block responsive to immunosuppressive treatment

Unexplained reduced LVEF (<40%)

Unexplained ventricular tachycardia

Mobitz II second- or third-degree heart block

Patchy ¹⁸F-FDG uptake on cardiac PET consistent with cardiac sarcoidosis

Late gadolinium enhancement on cardiac MRI consistent with cardiac sarcoidosis

Cardiac gallium-67 uptake *and*

Exclusion of other causes of cardiac manifestations

LVEF: left ventricular ejection fraction; PET: positron emission tomography; MRI: magnetic resonance imaging. Adapted from Blankstein et al.⁵⁸

Table 2 – 2017 Revised Japanese criteria for cardiac sarcoidosis**1. Major criteria**

1. (a) High-grade atrioventricular block (including complete atrioventricular block) or fatal ventricular arrhythmia (e.g., sustained ventricular tachycardia and ventricular fibrillation)
2. (b) Basal thinning of the ventricular septum or abnormal ventricular wall anatomy (ventricular aneurysm, thinning of the middle or upper ventricular septum, regional ventricular wall thickening)
3. (c) Left ventricular contractile dysfunction (left ventricular ejection fraction less than 50%)
4. (d) Gallium-67 citrate scintigraphy or ¹⁸F-FDG PET reveals abnormally high tracer accumulation in the heart
5. (e) Gadolinium-enhanced MRI reveals delayed contrast enhancement of the myocardium

2. Minor criteria

6. (f) Abnormal ECG findings: Ventricular arrhythmias (nonsustained ventricular tachycardia, multifocal or frequent premature ventricular contractions), bundle branch block, axis deviation, or abnormal Q waves
7. (g) Perfusion defects on myocardial perfusion scintigraphy (SPECT)
8. (h) Endomyocardial biopsy: monocyte infiltration and moderate or severe myocardial interstitial fibrosis

PET: positron emission tomography; MRI: magnetic cardiac imaging; ECG: electrocardiogram; SPECT: single-photon emission computed tomography. Adapted from Terasaki F, Yoshinaga K. New guidelines for diagnosis of cardiac sarcoidosis in Japan. Ann Nucl Cardiol. 2017; 3(1):42-45.

can lead to a perfusion defect. Usually, those defects do not follow the typical vascular distribution of coronary disease, unless when very extensive. Another finding described in some rest-stress perfusion studies is the reverse distribution.^{30,31} It happens when a perfusion defect at rest improves on stress imaging and it is probably related to a focal reversible microvascular constriction in coronary arterioles around granulomas, however not specific to CS. SPECT imaging can be used

together with 18F-FDG PET to evaluate the presence of active inflammation and its relation with scar.

Despite being less sensitive than 18F-FDG PET and exposing the patient to a higher amount of radiation, gallium-67 scintigraphy using both planar imaging and SPECT is still used in CS, especially in areas with limited access to PET equipment. Gallium-67 citrate is produced in a cyclotron and has the advantage of being more available as its longer half-life can

facilitate its distribution to distant services at reduced cost. Granulomas with giant cells are exquisitely avid for this radiotracer uptake (**Figure 1**) and a positive gallium-67 scintigraphy is considered as a major criterion for the diagnosis of CS by the consensus of specialists of the HRS.²⁵

MRI

As an advanced cardiac imaging modality, besides giving detailed assessment of biventricular function, CMR has the capacity to detect myocardial edema, perfusion abnormalities and to evaluate the presence and size of scar. The addition of T2 weighted imaging and T2 mapping give CMR the capacity to detect edema and inflammation and some have suggested could be an alternative to 18F-FDG PET(32) (**Figure 2**). The use of gadolinium, an extracellular contrast agent, is recommended to evaluate the presence of myocardial scar as it demonstrates slower washout from areas of fibrosis and inflammation compared to normal myocardium. The pattern of late gadolinium enhancement (LGE) findings follows the same pathophysiological distribution of the areas of fibrosis,^{33,34} with sometimes an extension into the RV insertion points.³⁵ CMR has the capacity to distinguish subcentimeter lesions and to differentiate between subepicardium, midmyocardium and subendocardium, due to its excellent in-plane spatial resolution. This distribution is helpful in recognizing CS,

however it is not entirely specific and similar findings can be seen in other pathologies. CS have a tendency to spare the subendocardium, which is a common finding in ischemic cardiomyopathy with prior infarct.^{35,36} CMR sensitivity for CS approaches 75-100% and its specificity 76-78%.^{33,37} The prognostic capacity of LGE was studied in a previous study that analyzed 155 patients with systemic sarcoidosis who underwent CMR for workup of CS involvement.¹² The median follow-up time was 2.6 years and the primary end-points were death, aborted sudden cardiac death and appropriate implantable cardioverter defibrillator (ICD) discharge. They found the presence of LGE in 25.5% of the patients with a hazard ratio of 31.6 for the primary end-points and 33.9 for any event. Regarding the patients with no LGE, no one had an adverse event (except for one patient who died from pulmonary infection). Those findings suggested that in patients with SS, scar indicated by LGE was the best independent predictor of potentially lethal events, stronger than LVEF and end-diastolic volume with a very high negative predictive value for adverse outcomes, including arrhythmic events. Ise et al.,³⁸ described in 43 consecutive LGE-positive patients that the presence of large-extent LGE ($\geq 20\%$ of left ventricular mass) correlated with absence of functional LV recovery following steroid therapy and higher risk of cardiac mortality, hospitalization for heart failure and life-threatening arrhythmias.³⁸

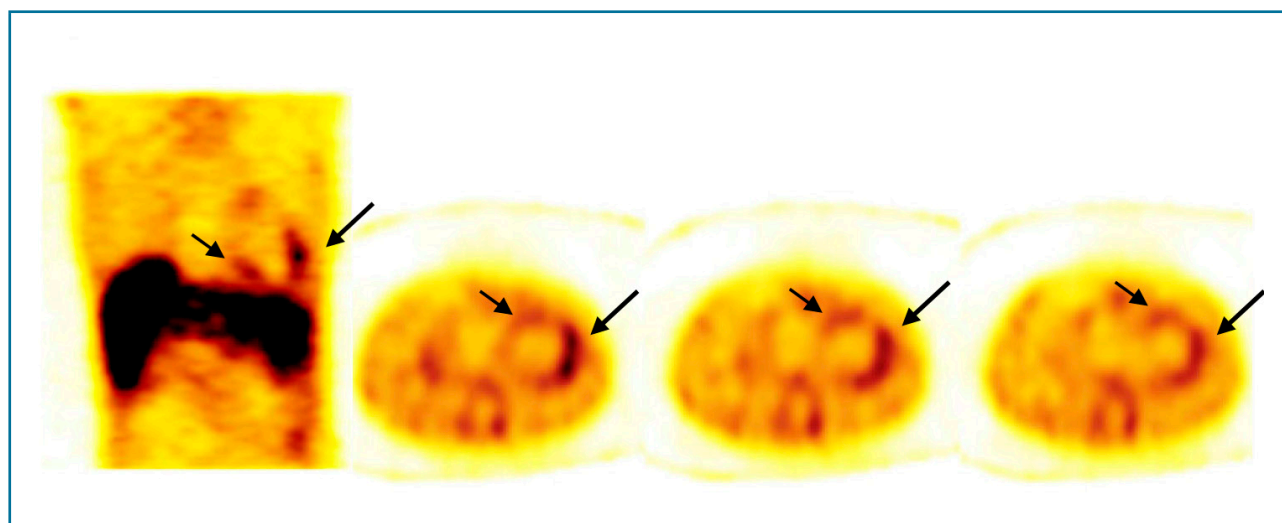
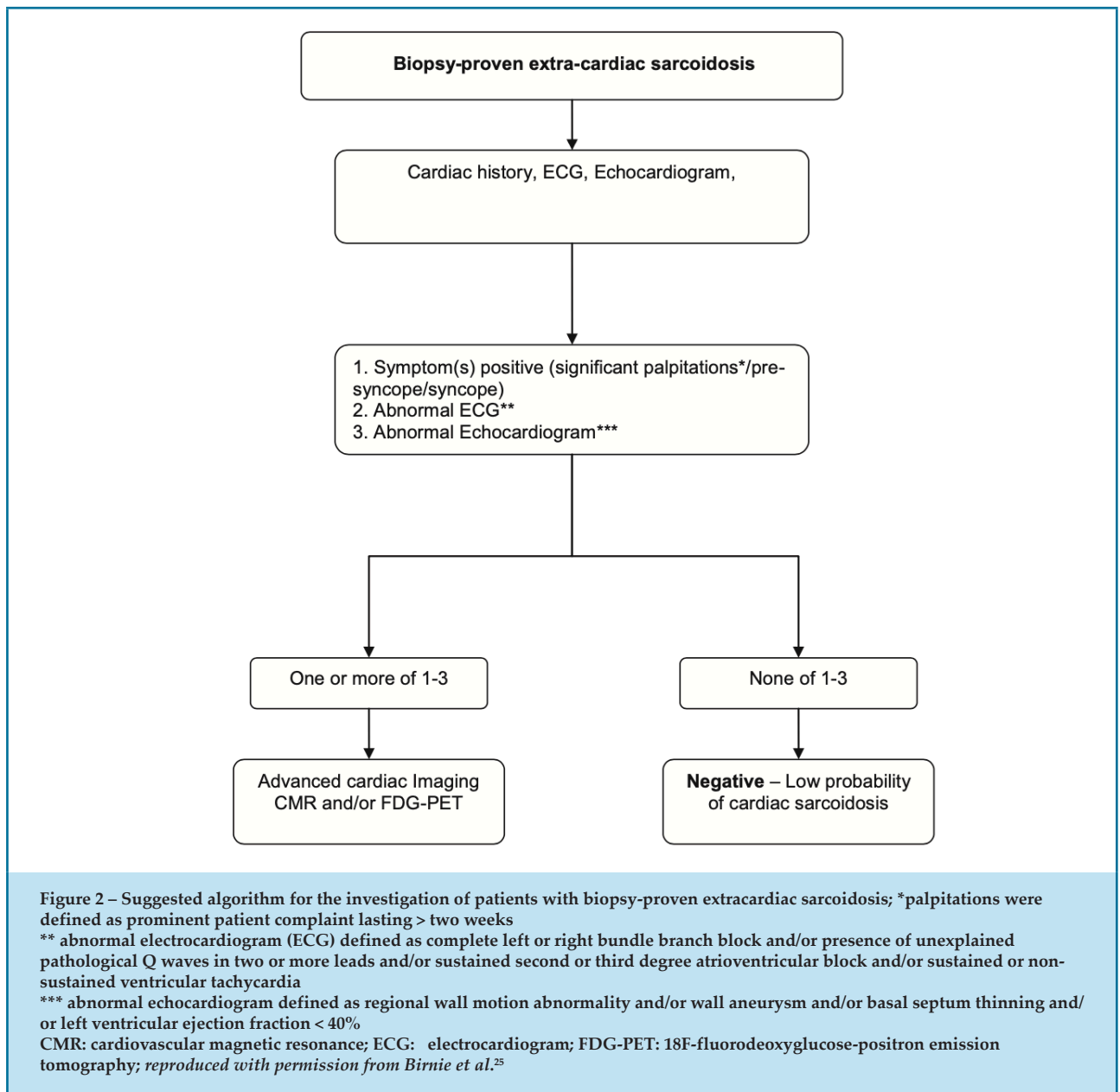


Figure 1 – Gallium-67 SPECT of a 36-year-old female patient with newly-diagnosed left ventricular systolic dysfunction. Coronal and axial sections demonstrate accumulation of the radiotracer in the left ventricular lateral wall (long arrow) and in the interventricular septum (short arrow); endomyocardial biopsy confirmed the presence of granulomas of giant non-caseous cells compatible with active sarcoidosis. After steroid therapy systolic function improved and the follow-up scintigraphy was negative



CMR has some benefits compared with PET imaging, as there is no exposure to ionizing radiation and no need for patient preparation such as specific diet before the image acquisition. CMR is useful when the diagnosis is complex in order to rule out other types of cardiomyopathies and/or infiltrative diseases. However, CMR imaging is limited in patients with recently implanted pacemakers or other metallic devices and gadolinium is contra-indicated in patients with advanced renal disease (estimated glomerular filtration rate [eGFR] < 30 mL/min/1.73 m²).³⁹

PET for CS

18F-FDG is a glucose analog used in PET imaging to evaluate myocardial inflammation.^{40,41} Myocardial cells use a mixture of free fatty acids and glucose for energy production under normal resting conditions. When preferentially switched to free fatty acid substrate, the presence of 18F-FDG uptake can indicate an inflammatory lesion. Inflammatory cells such as macrophages and lymphocytes utilize glucose as their primary energy source.^{42,43} 18F-FDG follows the

pathway of glucose crossing the cellular membrane via glucose transporter (GLUT 1 and 3) and being phosphorylated by hexokinase inside the cell, where it gets trapped, and can be detected by PET imaging.^{44,45} To improve the specificity in identifying pathological glucose uptake, background physiologic myocardial glucose metabolism must be suppressed; to accomplish this, the patient needs to undergo a specific preparation including dietary manipulation with a high-fat, low-carbohydrate diet, prolonged fasting, intravenous heparin or a combination of these approaches as described in the Joint SNMMI-ASNC Expert Consensus Document on the Role of ¹⁸F-FDG PET/CT in Cardiac Sarcoid Detection and Therapy Monitoring.⁴⁶ ¹⁸F-FDG PET imaging is commonly performed concurrently with a PET or SPECT myocardial perfusion scan.⁴⁷ The combination of both perfusion defects and ¹⁸F-FDG uptake in multiple areas following a non-coronary distribution makes the diagnosis more likely. Youssef et al.,⁴⁸ in a meta-analysis, collected data from 164 patients and showed that PET had a pooled sensitivity of 89% and a pooled specificity of 83% in diagnosing CS.⁴⁸ A recent meta-analysis by Kim et al.,⁴⁹ had similar results, with a pooled sensitivity of 84% and a pooled specificity of 83%. The specificity increases with the correlation with extra-cardiac findings, seen in a ¹⁸F-FDG whole-body imaging, such as positive mediastinal and/or hilar lymphadenopathy. However, the presence of ¹⁸F-FDG uptake in a mismatch pattern with perfusion defect can also be seen in the presence of hibernating myocardium, and a careful differentiation must be made in patients with known ischemic cardiomyopathies.³² It is important to keep in mind that ¹⁸F-FDG uptake is related to active inflammation within the myocardium, and the absence of uptake cannot rule out the presence of CS.⁴⁶

Indications for cardiac PET

Diagnosis

In the absence of histologic confirmation, PET is useful to investigate suspected CS; however, the diagnosis should not be based on PET findings alone but in combination with other methods including ECG, Holter and echocardiography. Some clinical scenarios in which cardiac PET may be useful have been previously described:⁴⁶ 1) patients with histologic evidence of extra-cardiac sarcoidosis with an abnormal screening

for CS, such as left bundle branch block or unexplained pathologic Q waves on ECG, regional wall motion abnormalities, wall aneurysm, basal septal thinning or LVEF $\leq 50\%$, sustained or non-sustained ventricular tachycardia, LGE on MRI, unexplained palpitations or syncope; 2) patients with new onset of conduction disease, unexplained by other diagnosis, normally found in younger patients (<60 years old) with second or third degree atrioventricular block; or 3) patients with idiopathic sustained ventricular tachycardia.

Monitoring response to therapy

PET imaging is useful in monitoring patients who undergo immunosuppressive therapy as it has the capacity to quantify inflammatory state before and after treatment using the standardized uptake value (SUV), and therefore assess treatment response.⁵⁰ It can help in important decisions such as the duration or the intensity of the medication used and choosing the more appropriate immunosuppressive therapy.

Patterns of uptake – visual interpretation

¹⁸F-FDG PET is normally acquired as a whole-body imaging and commonly uses computed tomography (CT) for attenuation-correction and anatomy correlation, and thereby has to be visualized using standard views (short-axis, sagittal and coronal views).⁴⁶ It is important to have an adequate alignment between PET and CT and to correlate the findings with the non-corrected images, in order to rule-out artifacts due to partial volume. There should also be a dedicated cardiac acquisition, normally visualized using the traditional cardiac imaging display, to compare with the perfusion imaging (PET or SPECT). Both images are generally normalized to the maximum counts per pixel of the image. The use of gated imaging can also add information such as LV volume, wall motion and systolic function. Both perfusion and ¹⁸F-FDG images should be interpreted simultaneously. A normal study should show a complete absence of ¹⁸F-FDG uptake in the myocardium and an absence of perfusion defect.⁴⁰ Another physiological or non-specific pattern is a focal and homogeneous ¹⁸F-FDG uptake in the lateral wall, without any perfusion defect.⁴⁶ Diffuse uptake is a non-specific finding and can be seen in both normal controls and patients with sarcoidosis.⁴⁰

Inflammation should be considered in the presence of focal or diffuse ¹⁸F-FDG uptake⁴⁰ (**Table 3**).

Table 3 – Positron emission tomography (PET) interpretation of the perfusion and metabolism findings

PET findings				
Perfusion	Normal	Normal	Abnormal (perfusion defect)	Abnormal (perfusion defect)
Metabolism	Normal (negative) Diffuse / lateral wall uptake (non-specific)	Focal increase	Focal increase Multiple areas	Normal (negative)
Interpretation	Normal	Early disease Inflammation No scar	Mismatch pattern Scar and inflammation	Scar and no active inflammation

Adapted from Blankstein et al.⁵⁸

Resting perfusion defects can be due to compression of the microvasculature by inflammation, with a mismatch between.⁴⁶ In the later phases of the disease, scarring/fibrosis can be seen, in addition to a matching pattern with rest perfusion defect and no 18F-FDG uptake. However, not all patients with CS develop scarring. When multiple focal areas of FDG uptake, involving the basal antero-septum, basal inferior and basal lateral walls are present, CS should be considered. Some areas of scar with no inflammation (match) can coexist with areas of scar with inflammation (mismatch). The combination of both findings (mismatch) has been associated with the worst outcome,^{51,52} as well as the presence of RV uptake.

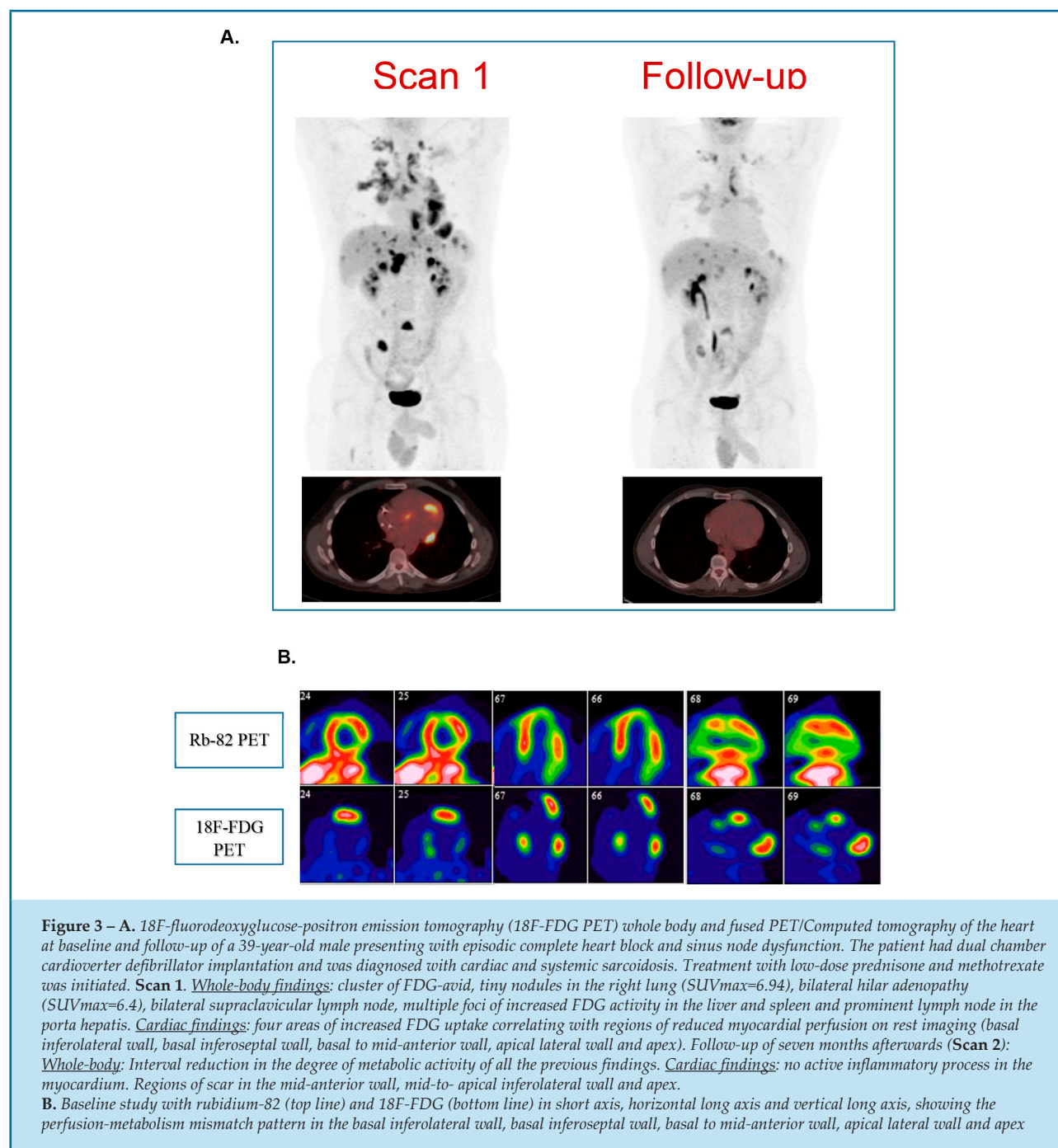
Challenges with FDG PET

The diagnose of CS with 18F-FDG is often a challenge. Patients can have comorbidities such as ischemic cardiomyopathy that can make the diagnosis even more difficult. Scar can be seen in both diseases and the presence of hibernating myocardium can mimic areas of inflammation due to CS. The same can happen in patients with active myocarditis or systemic rheumatologic conditions with cardiac involvement. Studies of patients with ICD leads have to be interpreted carefully using both attenuation-corrected and non-attenuation-corrected images as false 18F-FDG uptake can be seen near the leads due to partial-volume artifact and misinterpreted as positive. One of the greatest challenges with 18F-FDG is the adequate preparation for the test, since a poor adherence to the diet may lead to diffuse 18F-FDG uptake, making the study uninterpretable. Moreover, up to 25% of the patients do not respond

to any of the strategies to reduced myocardial uptake leading to a high rate of false-positives or inconclusive results.^{32,53} Therefore, 18F-FDG PET studies for CS should be conducted in experienced centers, with qualified physicians, since false-positive studies could be harmful to immunosuppressed patients. **Figures 3** and **4** illustrate two different cases before and after therapy.

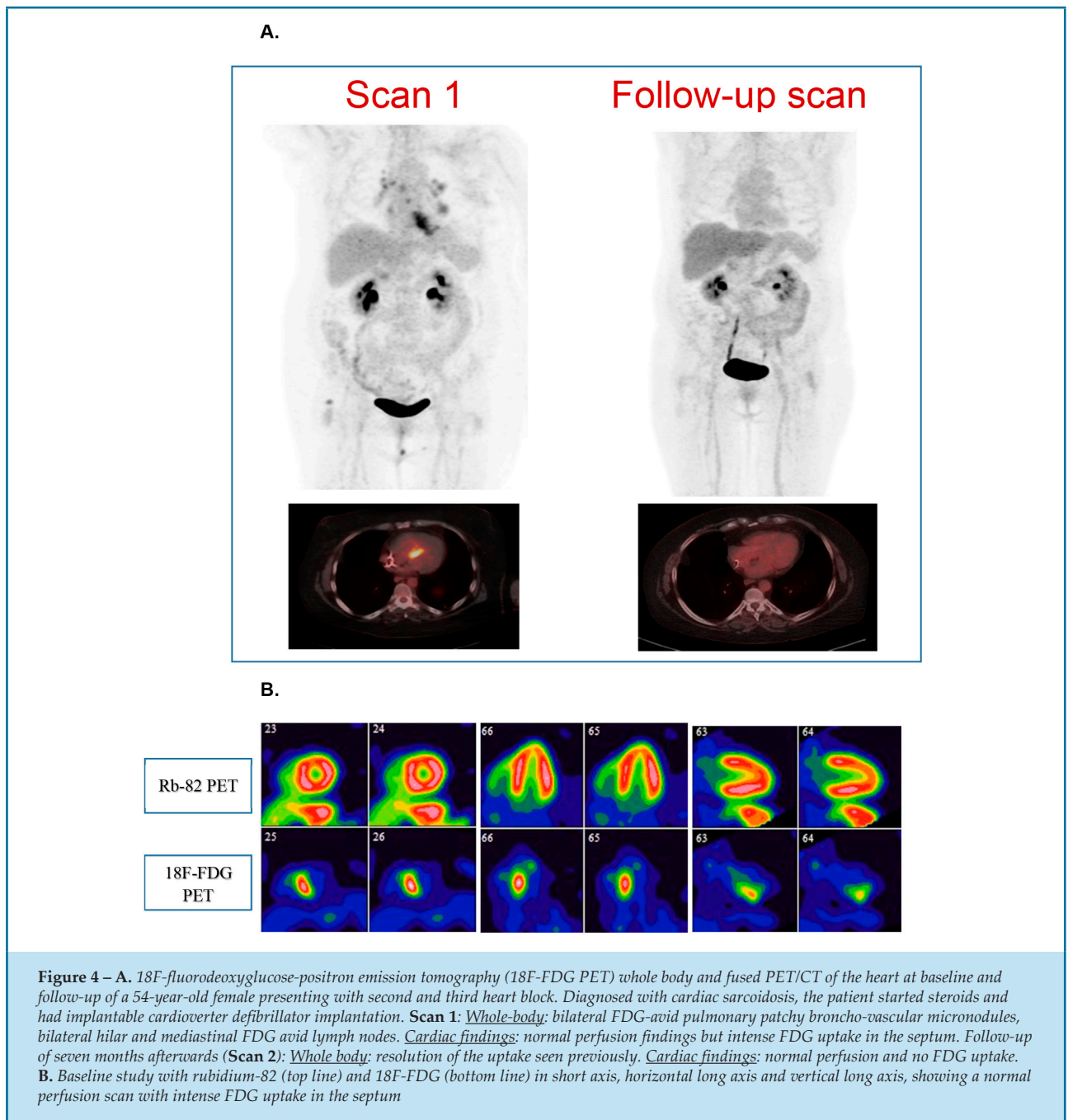
Prognosis

Cardiac PET can help in the diagnosis and assessment of treatment response in CS. Given the risk of sudden cardiac death and the potential side effects of ICD, some studies have tried to identify how cardiac PET findings could be related to adverse cardiac events in a population with CS. Blankstein et al.,⁵² studied 118 patients who underwent PET with 18F-FDG and Rb-82 to assess inflammation and perfusion defect, and categorized them according to the imaging findings as (a) normal; (b) positive perfusion defect or glucose uptake; or (c) positive perfusion defect and glucose uptake.⁵² They followed the patient for an average of 1.5 year to identify the outcomes of death and sustained ventricular tachycardia (VT). Among the patients, 47 (40%) had normal and 71 (60%) abnormal cardiac PET findings. During the follow-up, there were 31 (26%) adverse events, with 27 VT and 8 deaths. Cardiac PET was able to predict adverse event with the presence of both perfusion defect and abnormal FDG (findings present in 29% of the patients), with a hazard ratio of 3.9 (p<0.01). However, based on current knowledge, PET cannot rule in or out the need for ICD in CS patients.



PET imaging has proven to be useful in predicting treatment response, not only by reduction of inflammation but also by improvement of LV function. Osborne et al.⁵⁴ evaluated the relationship between the reduction in myocardial inflammation measured by FDG uptake and the improvement in LV ejection fraction.⁵⁴ They assessed 23 patients with serial PET scans (median of four per patient) and quantified the maximum SUV and volume of tissue with inflammation to assess the extension and

intensity of FDG uptake for each study performed. The median time between the first and the last scan was two years. Most of the patients (91%) were treated with corticosteroids, and 83% had ICDs. There was a significant inverse linear relationship between maximum SUV and ejection fraction (EF) with an expected increase in EF of 7.9% per SUV reduction of 10g/mL by longitudinal regression model ($p=0.008$). On the volume-based analysis, EF increased 2.1% per 100 cm³ decrease in volume of



inflamed tissue using a threshold of 2.7g/mL, and when using a threshold of 4.1g/mL, there was an increase in EF of 3.8% per 100cm³ decrease. These findings showed a correlation between the reduction of the intensity and extension of 18F-FDG uptake due to myocardial inflammation in patients with CS and improvement in LVEF. Based on this small study, serial PET scanning could be useful in guiding the immunosuppressive therapy, preventing the development of heart failure in

patients with CS. **Table 4** summarizes the use of 18F-FDG PET in the management of CS.

PET/MRI

The combination of PET with MRI in a single acquisition is now possible with the use of advanced hybrid cameras. Despite the elevated price of the equipment, hybrid scanners can offer great benefit

Table 4 – Use of 18F-FDG PET in the management of Cardiac Sarcoidosis

Indication	Significant findings	Technical aspects	References
Diagnosis	Normal or decreased perfusion in the involved region of the myocardium, with increased 18F-FDG uptake	Inadequate preparation can severely impair the accuracy for the diagnosis of CS	58
Prognosis	Perfusion defect or focal 18F-FDG uptake in left ventricle, increased uptake in right ventricle, extensive and severe uptake in the myocardium	Up to 25% of qualitative 18F-FDG PET exams may not be reproducible (90-120 minutes of 18F-FDG uptake improves reproducibility)	42, 52, 59
Assessment of Treatment Response	Decreased or resolved 18F-FDG uptake in the myocardium can support the decision to wean prednisone	Increased costs and radiation exposure. Limit to 3-4 scans in a year. Caution should be taken concerning the effect of steroid on false-positive 18F-FDG-PET results	60
Diagnosis of extra-cardiac sarcoid disease activity or findings to guide a biopsy from an extracardiac location of 18F-FDG uptake	18F-FDG avid lymph nodes or other accessible area to guided biopsy can provide a definitive diagnosis or exclude malignancy in uncertain cases	The whole body 18F-FDG PET as well as the CT transmission (on hybrid scanners) images need to be reviewed and reported in conjunction with a physician credentialed to supervise and interpret body PET/CT	47

CS: cardiac sarcoidosis; PET: positron emission tomography; CT: computed tomography; 18F-FDG: 18F-fluorodeoxyglucose

because of the reduced cost of personnel and reduced risk of complications.⁵⁵ For the patient, it would mean a single visit to the imaging department, and less time spent in the hospital. The MRI would play the role of the CT for attenuation correction, anatomic reference and evaluation of extracardiac findings and will add value of tissue characterization, mainly for scar and edema.⁵⁶ The combination of both imaging techniques improves spatial relationship between the findings of scar and inflammation, making it useful to patient's management and understanding of the phases of the disease (mismatching, scarring or inflammation alone).

CHASM CS-RCT

Due to the lack of previous clinical trials to evaluate treatment strategies in CS, the Cardiac Sarcoidosis Multi-Center Randomized Controlled Trial (CHASM CS-RCT; NCT-03593759) is an ongoing multicenter randomized controlled trial aiming to evaluate the optimal initial treatment strategy for patient with active CS.⁵⁷ The inclusion criteria are: patients with clinically manifest CS with at least one finding such as advanced conduction system disease, significant node dysfunction,

non-sustained or sustained ventricular arrhythmia, LV dysfunction or RV dysfunction. The primary hypothesis is that a low dose prednisone/ methotrexate combination will have non-inferior efficacy to standard dose prednisone and will result in a significantly better quality of life due to less side-effects when compared to the standard therapy. The subject are randomized in a 1:1 ratio to high dose prednisone (0.5mg/kg/day for six months, with maximum dose of 30mg/day) or to prednisone 20mg/day for one month, 10mg/day for one month, then 5mg/day for one month, followed by discontinuation of prednisone and initiation of methotrexate 15-20mg once weekly for six months. This study uses PET imaging (perfusion and metabolism with FDG) to evaluate the presence of scar and inflammation. Showing the non-inferiority of the low-dose steroid will be enough to guide therapy toward a highly-effective treatment with less adverse effects and better quality of life for the patient.

Conclusion

CS can be difficult to diagnose and often requires multiple tools to reach timely diagnosis. Cardiac MR and FDG PET are advanced imaging techniques that can be used a complementary fashion for diagnosis,

monitoring treatment response and progression over time. Those modalities demonstrate distinct distribution and patterns of the disease at different stages, such as perfusion defects due to fibrosis, FDG uptake or elevation of T2 signal caused by inflammation as well as impairment of the ventricular function. Prospective randomized controlled trials as CHASM CS-RCT are needed to validate not only the role of imaging in diagnosis but also in order to assess therapy management to guide the best treatment for each individual, taking into consideration not only the response but also patient's quality of life.

Author contributions

Conception and design of the research: Wiefels C. Writing of the manuscript: Wiefels C, Lamai O, Kandolin R, Birnie D, Leung, E, Mesquita CT, Beanlands R. Critical revision of the manuscript for intellectual content: Wiefels

C, Lamai O, Kandolin R, Birnie D, Leung, E, Mesquita CT, Beanlands R.

Potential Conflict of Interest

No potential conflict of interest relevant to this article was reported.

Sources of Funding

There were no external funding sources for this study.

Study Association

This article is part of the thesis of Doctoral submitted by Christiane Wiefels, from *Universidade Federal Fluminense*.

Ethics approval and consent to participate

This article does not contain any studies with human participants or animals performed by any of the authors.

References

- Boeck C. Multiple benign sarkoid of the skin. *Arch Dermatol*. 1982;118(10):710-20.
- Valeyre D, Prasse A, Nunes H, Uzunhan Y, Brillet PY, Müller-Quernheim J. Sarcoidosis. *Lancet*. 2014;383(9923):1155-67.
- Dumas O, Abramovitz L, Wiley AS, Cozier YC, Camargo CA. Epidemiology of sarcoidosis in a prospective cohort study of U.S. Women. *Ann Am Thorac Soc*. 2016;13(1):67-71.
- Erdal BS, Clymer BD, Yildiz VO, Julian MW, Crouser ED. Unexpectedly high prevalence of sarcoidosis in a representative U.S. Metropolitan population. *Respir Med*. 2012;106(6):893-9.
- Chareonthaitawee P, Blankstein R. Reply: Role of 18 F-FDG PET/CT in cardiac sarcoid detection and therapy monitoring: Addition to the expert consensus. *J Nucl Med*. 2019; 60: 293-4.
- Kandolin R, Lehtonen J, Airaksinen J, Vihinen T, Miettinen H, Ylitalo K, et al. Cardiac sarcoidosis: Epidemiology, characteristics, and outcome over 25 years in a nationwide study. *Circulation*. 2015;131(7):624-32.
- Iwai K, Sekiguti M, Hosoda Y, DeRemee RA, Tazelaar HD, Sharma OP, et al. Racial difference in cardiac sarcoidosis incidence observed at autopsy. *Sarcoidosis*. 1994;11(1):26-31.
- Baughman RP, Teirstein AS, Judson MA, Rossman MD, Yeager H, Bresnitz EA, et al. Clinical characteristics of patients in a case control study of sarcoidosis. *Am J Respir Crit Care Med*. 2001;164(10):1885-9.
- Milman N, Selroos O. Pulmonary sarcoidosis in the Nordic countries 1950-1982. Epidemiology and clinical picture. *Sarcoidosis*. 1990;7(1):50-7.
- Rybicki BA, Major M, Popovich J, Maliarik MJ, Iannuzzi MC. Racial differences in sarcoidosis incidence: A 5-year study in a health maintenance organization. *Am J Epidemiol*. 1997;145(3):234-41.
- Blauwet LA, Cooper LT. Idiopathic giant cell myocarditis and cardiac sarcoidosis. *Heart Fail Rev*. 2013;18(6):733-46.
- Greulich S, Deluigi CC, Gloekler S, Wahl A, Zürn C, Kramer U, et al. CMR imaging predicts death and other adverse events in suspected cardiac sarcoidosis. *JACC Cardiovasc Imaging*. 2013;6(4):501-11.
- Dubrey SW, Falk RH. Diagnosis and Management of Cardiac Sarcoidosis. *Prog Cardiovasc Dis*. 2010;52(4):336-46.
- Zhou Y, Faber TL, Patel Z, Folks RD, Cheung AA, Garcia E V, et al. An automatic alignment tool to improve repeatability of left ventricular function and dyssynchrony parameters in serial gated myocardial perfusion SPECT studies. *Nucl Med Commun*. 2013;34(2):124-9.
- Silverman KJ, Hutchins GM, Bulkley BH. Cardiac sarcoid: A clinicopathologic study of 84 unselected patients with systemic sarcoidosis. *Circulation*. 1978;58(6):1204-11.
- Tavora F, Cresswell N, Li L, Ripple M, Solomon C, Burke A. Comparison of Necropsy Findings in Patients With Sarcoidosis Dying Suddenly from Cardiac Sarcoidosis Versus Dying Suddenly from Other Causes. *Am J Cardiol*. 2009;104(4):571-7.
- Uemura A, Morimoto SI, Hiramitsu S, Kato Y, Ito T, Hishida H. Histologic diagnostic rate of cardiac sarcoidosis: Evaluation of endomyocardial biopsies. *Am Heart J*. 1999;138(2):299-302.
- Matsui Y, Iwai K, Tachibana T, Fruie T, Shigematsu N, Izumi T, et al. Clinicopathological study on fatal myocardial sarcoidosis. *Ann N Y Acad Sci*. 1976;278(1):455-69.
- Silverman KJ, Hutchins GM, Bulkley BH. Cardiac sarcoid: A clinicopathologic study of 84 unselected patients with systemic sarcoidosis. *Circulation*. 1978;58(6):1204-11.
- Tavora F, Cresswell N, Li L, Ripple M, Solomon C, Burke A. Comparison of Necropsy Findings in Patients With Sarcoidosis Dying Suddenly from Cardiac Sarcoidosis Versus Dying Suddenly from Other Causes. *Am J Cardiol*. 2009;104(4):571-7.
- Roberts WC, McAllister HA, Ferrans VJ. Sarcoidosis of the heart. *Am J Med*. 1977;63(1):86-108.
- Wyplosz B, Marijon E, Dougados J, Pouchot J. Sarcoidosis: An unusual cause of acute pericarditis. *Acta Cardiol*. 2010;65(1):83-4.
- Yazaki Y, Isobe M, Hiroe M, Morimoto SI, Hiramitsu S, Nakano T, et al. Prognostic determinants of long-term survival in Japanese patients with cardiac sarcoidosis treated with prednisone. *Am J Cardiol*. 2001;88(9):1006-10.

24. Birnie DH. Comparing and Contrasting Guidelines for the Diagnosis of Cardiac Sarcoidosis. *Ann Nucl Cardiol*. 2017;3(1):46-7.
25. Birnie DH, Sauer WH, Bogun F, Cooper JM, Culver DA, Duvernoy CS, et al. HRS expert consensus statement on the diagnosis and management of arrhythmias associated with cardiac sarcoidosis. *Heart Rhythm*. 2014; 11(7):1304-23.
26. Sharma A, Okada DR, Yacoub H, Chrispin J, Bokhari S. Diagnosis of cardiac sarcoidosis: an era of paradigm shift. *Ann Nucl Med*. 2019; 1-7.
27. Kawakatsu N, Suzuki A, Serizawa N, Suzuki T, Ejima K, Shiga T, et al. Isolated cardiac sarcoidosis diagnosed by electroanatomic voltage mapping-guided endomyocardial biopsy combined with magnetic resonance imaging and positron emission tomography. *J Cardiol Cases*. 2016;14(4):107-10.
28. Judson MA, Costabel U, Drent M, Wells A, Maier L, Koth L, et al. The WASOG sarcoidosis organ assessment instrument: An update of a previous clinical tool. *Sarcoidosis Vasc Diffus Lung Dis*. 2014;31(1):19-27.
29. Kouranos V, Tzelepis GE, Rapti A, Mavrogeni S, Aggeli K, Douskou M, et al. Complementary Role of CMR to Conventional Screening in the Diagnosis and Prognosis of Cardiac Sarcoidosis. *JACC Cardiovasc Imaging*. 2017;10(12):1437-47.
30. Silberstein EB, DeVries DF. Reverse redistribution phenomenon in thallium-201 stress tests: Angiographic correlation and clinical significance. *J Nucl Med*. 1985;26(7):707-10.
31. Hirose Y, Ishida Y, Hayashida K, Maeno M, Takamiya M, Ohmori F, et al. Myocardial involvement in patients with sarcoidosis: An analysis of 75 patients. *Clin Nucl Med*. 1994;19(6):522-6.
32. Ramirez R, Trivieri M, Fayad ZA, Ahmadi A, Narula J, Argulian E. Advanced imaging in cardiac sarcoidosis. *J Nucl Med*. 2019;60(7):892-8.
33. Smedema JP, Snoep G, Van Kroonenburgh MPG, Van Geuns RJ, Dassen WRM, Gorgels APM, et al. Evaluation of the accuracy of gadolinium-enhanced cardiovascular magnetic resonance in the diagnosis of cardiac sarcoidosis. *J Am Coll Cardiol*. 2005;45(10):1683-90.
34. Ichinose A, Otani H, Oikawa M, Takase K, Saito H, Shimokawa H, et al. MRI of cardiac sarcoidosis: Basal and subepicardial localization of myocardial lesions and their effect on left ventricular function. *Am J Roentgenol*. 2008;191(3):862-9.
35. Bravo PE, Singh A, Di Carli MF, Blankstein R. Advanced cardiovascular imaging for the evaluation of cardiac sarcoidosis. *J Nucl Cardiol*. 2019; 26(1):188-99.
36. Juneau D, Erthal F, Ohira H, Mc Ardle B, Hessian R, de Kemp RA, et al. Clinical PET Myocardial Perfusion Imaging and Flow Quantification. *Cardiol Clin*. 2016;34:69-85.
37. Keida T, Ohira H, Fujita M, Chinen T, Nakamura K, Kato T, et al. Quantitative assessment of dyssynchrony using ECG-gated SPECT myocardial perfusion imaging prior to and following cardiac resynchronization therapy. *Circ J*. 2009;73(8):1550-3.
38. Ise T, Hasegawa T, Morita Y, Yamada N, Funada A, Takahama H, et al. Extensive late gadolinium enhancement on cardiovascular magnetic resonance predicts adverse outcomes and lack of improvement in LV function after steroid therapy in cardiac sarcoidosis. *Heart*. 2014;100(15): 1165-72.
39. Schieda N, Blachman JJ, Costa AF, Glikstein R, Hurrell C, James M, et al. Gadolinium-Based Contrast Agents in Kidney Disease: Comprehensive Review and Clinical Practice Guideline Issued by the Canadian Association of Radiologists. *Canad Assoc Radiol J*. 2018;69(2):136-50.
40. Ishimaru S, Tsujino I, Takei T, Tsukamoto E, Sakaue S, Kamigaki M, et al. Focal uptake on 18F-fluoro-2-deoxyglucose positron emission tomography images indicates cardiac involvement of sarcoidosis. *Eur Heart J*. 2005;26(15):1538-43.
41. Okumura W, Iwasaki T, Toyama T, Iso T, Arai M, Oriuchi N, et al. Usefulness of fasting 18 F-FDG PET in identification of cardiac sarcoidosis. *J Nucl Med*. 2004;45(12):1989-98.
42. Mehta D, Lubitz SA, Frankel Z, Wisnivesky JP, Einstein AJ, Goldman M, et al. Cardiac involvement in patients with sarcoidosis: Diagnostic and prognostic value of outpatient testing. *Chest*. 2008;133(6):1426-35.
43. Newsholme P, Newsholme EA. Rates of utilization of glucose, glutamine and oleate and formation of end-products by mouse peritoneal macrophages in culture. *Biochem J*. 1989;261(1):211-8.
44. Isiguzo M, Brunken R, Tchou P, Xu M, Culver DA. Metabolism-perfusion imaging to predict disease activity in cardiac sarcoidosis. *Sarcoidosis Vasc Diffus Lung Dis*. 2011;28(1):50-5.
45. Treglia G, Taralli S, Mattoli MV, Giordano A. Utility of whole-body Fluorine-18-fluorodeoxyglucose positron emission tomography in patients with sarcoidosis. In: *Medical Imaging: Procedures, Techniques and Applications*, 2012. p.39-50.
46. Chareonthaitawee P, Beanlands RS, Chen W, Dorbala S, Miller EJ, Murthy VL, et al. Joint SNMMI-ASNC expert consensus document on the role of 18F-FDG PET/CT in cardiac sarcoid detection and therapy monitoring writing group. *J Nucl Med*. 2017;58(8):1341-53.
47. Skali H, Schulman AR, Dorbala S. 18 F-FDG PET/CT for the assessment of myocardial sarcoidosis. *Curr Cardiol Rep*. 2013;15(5):352.
48. Youssef G, Leung E, Mylonas I, Nery P, Williams K, Wisenberg G, et al. The use of 18F-FDG PET in the diagnosis of cardiac sarcoidosis: A systematic review and metaanalysis including the Ontario experience. *J Nucl Med*. 2012;53(2):241-8.
49. Kim SJ, Pak K, Kim K. Diagnostic performance of F-18 FDG PET for detection of cardiac sarcoidosis; A systematic review and meta-analysis. *J Nucl Cardiol*. 2019 Jan 2. doi: 10.1007/s12350-018-01582-y online ahead of print.
50. Sgard B, Brillet PY, Bouvry D, Djelbani S, Nunes H, Meune C, et al. Evaluation of FDG PET combined with cardiac MRI for the diagnosis and therapeutic monitoring of cardiac sarcoidosis. *Clinical radiology*. 2019; 74(1):81-e9.
51. Ahmadian A, Brogan A, Berman J, Sverdllov AL, Mercier G, Mazzini M, et al. Quantitative interpretation of FDG PET/CT with myocardial perfusion imaging increases diagnostic information in the evaluation of cardiac sarcoidosis. *J Nucl Cardiol*. 2014;21(5):925-39.
52. Blankstein R, Osborne M, Naya M, Waller A, Kim CK, Murthy VL, et al. Cardiac positron emission tomography enhances prognostic assessments of patients with suspected cardiac sarcoidosis. *J Am Coll Cardiol*. 2014; 63(4):329-36.
53. Osborne MT, Hulten EA, Murthy VL, Skali H, Taqueti VR, Dorbala S, et al. Patient preparation for cardiac fluorine-18 fluorodeoxyglucose positron emission tomography imaging of inflammation. *J Nucl Cardiol*. 2017; 24(1):86-99.
54. Osborne MT, Hulten EA, Singh A, Waller AH, Bittencourt MS, Stewart GC, et al. Reduction in 18F-fluorodeoxyglucose uptake on serial cardiac positron emission tomography is associated with improved left ventricular ejection fraction in patients with cardiac sarcoidosis. *J Nucl Cardiol*. 2014; 21(1):166-74.
55. Farber G, Boczar K, Wiefels C, Zelt J, Guler EC, DeKemp RA, et al. The future of cardiac molecular imaging. *Semin Nucl Med*. 2020.00:1-19.
56. Wisenberg G, Thiessen JD, Pavlovsky W, Butler J, Wilk B, Prato FS. Same day comparison of PET/CT and PET/MR in patients with cardiac sarcoidosis. *J Nucl Cardiol*. 2019. <https://doi.org/10.1007/s12350-018-01578-8>.
57. Birnie D, Beanlands RSB, Nery P, Aaron SD, Culver DA, DeKemp RA, et al. Cardiac Sarcoidosis multi-center randomized controlled trial (CHASM CS- RCT). *Am Heart J*. 2019;220():246-52
58. Blankstein R, Waller AH. Evaluation of Known or Suspected Cardiac Sarcoidosis. *Circ Cardiovasc Imaging*. 2016;9(3):e000867.
59. Alvi RM, Young BD, Shahab Z, Pan H, Winkler J, Herzog E, et al. Repeatability and Optimization of FDG Positron Emission Tomography for Evaluation of Cardiac Sarcoidosis. *JACC Cardiovasc Imaging*. 2019;12(7 Pt1):124-7.
60. Ning N, Guo HH, Iagaru A, Mittra E, Fowler M, Witteles R. Serial Cardiac FDG-PET for the Diagnosis and Therapeutic Guidance of Patients With Cardiac Sarcoidosis. *J Card Fail*. 2019;25(4):307-11.

