

CASE REPORT

Entrapment of Broken Guidewire in the Coronary Artery: A Rare Percutaneous Coronary Intervention Complication Requiring Urgent Revascularization

Elif Coskun,¹ Levent Altınay,² Anil Tekin,³ Ufuk Tutun⁴

Bulent Ecevit University Training and Research Hospital, Kozlu, Zonguldak - Turkey

Introduction

Entrapment and fracture of the coronary guidewire is a rare complication of percutaneous coronary interventions (PCIs). The incidence of such complication in PCI is reported to be between 0.2 and 0.8%.^{1,2} Despite technical improvements and development of more flexible and high-quality guidewires, the incidence of these complications is increasing.³

There are many management strategies for entrapped guidewires reported in the literature. In a report including 67 patients, surgery was performed in 43.4%, percutaneous interventions were performed in 41.8% and conservative therapies were chosen for 14.9% of the patients.⁴

Herein, we reported a case of broken and entrapped guidewire in a coronary vessel during PCI which was removed by open heart surgery.

Case report

A 53-year old male patient was referred to our center with the diagnosis of non-ST elevated myocardial infarction (NSTEMI). He had a history of chest pain which lasted for approximately six hours. He had chronic coronary artery disease and had been using acetylsalicylic acid (ASA) and metoprolol for seven years. He also had a history of PCI performed in another health center two years before. Coronary angiography and PCI were

planned for the patient after primary evaluation in the emergency room. Laboratory results showed a troponin T level of 0.166 ng/mL, total cholesterol of 213 mg/dL and low-density lipoprotein (LDL) of 150 mg/dL. There was no sign of myocardial ischemia in the electrocardiogram (ECG). The left ventricular ejection fraction (LVEF) was 60% and concentric left ventricle hypertrophy was observed by echocardiograph.

A diagnostic coronary angiography revealed a plaque in the middle segment of the left anterior descending (LAD) artery, and PCI was then performed. A 182 cm x 0.014" floppy guidewire was introduced into the LAD artery and another guidewire of the same size was introduced into the diagonal artery for prevention of the diagonal artery occlusion through the right femoral arterial access sheath. A coronary stent (Coroflex® ISAR NEO 3.0 mm X 16 mm, B. BRAUN, Germany) was implanted into the lesion in the middle segment of the LAD artery at 16 atm pressure. Unfortunately, the distal piece of the guidewire in the diagonal artery broke and was entrapped in the coronary artery (Figure 1). Although the remaining piece of the guidewire was easily removed, the piece entrapped in the coronary artery could not be removed with the loop snare or an angioplasty balloon (3.5 x 15 mm, NC Boston Scientific). After failure of these measures, an urgent coronary bypass operation was planned. The patient had no chest pain or arrhythmias during or after the PCI procedure.

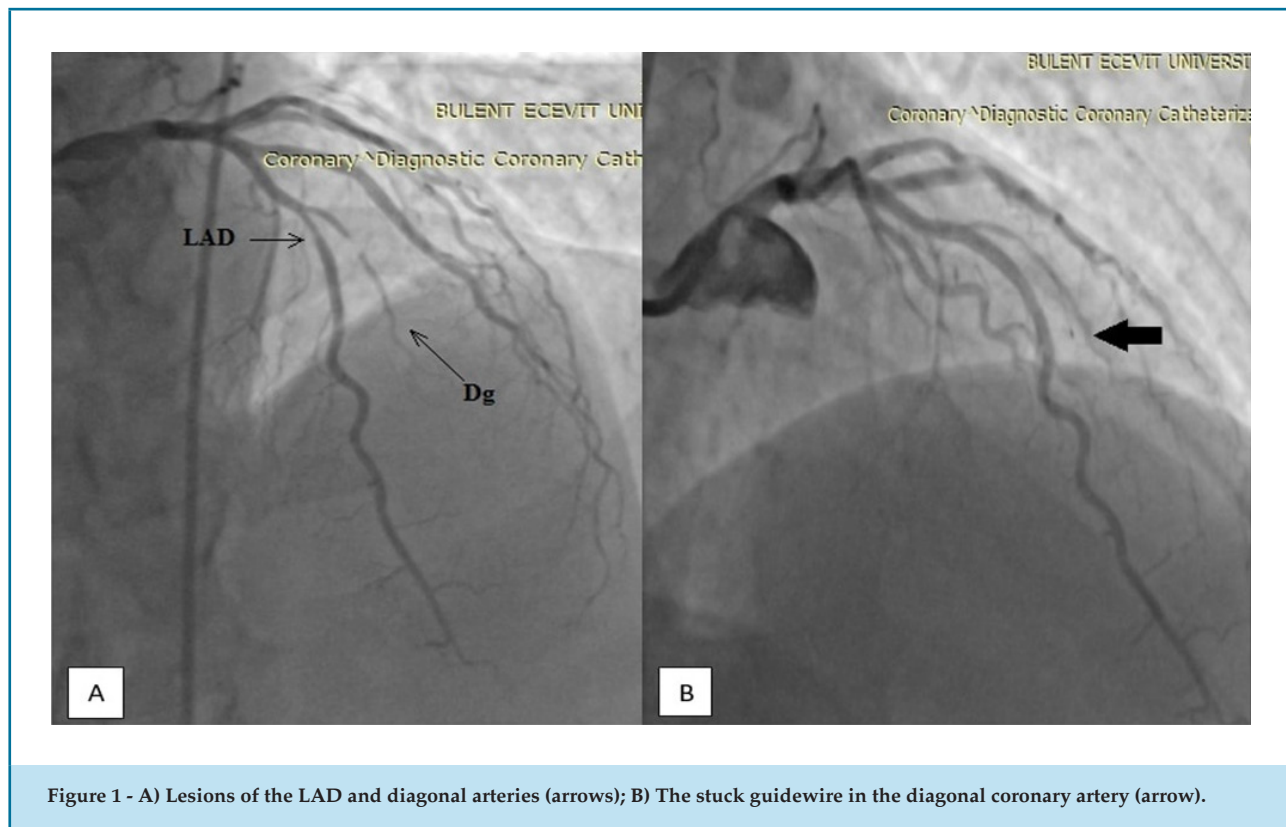
After preparation for the coronary artery bypass graft surgery (CABG), the patient was transferred to the operating room. Cardiopulmonary bypass was initiated after standard median sternotomy and cavoatrial cannulation. The left internal mammary artery (LIMA) graft and the saphenous vein graft (SVG) were harvested. The coronary arteries were exposed. The retained piece of guidewire in the coronary artery could not be removed

Keywords

Coronary Artery Disease; Myocardial Infarction; Angiography, Coronary; Percutaneous Coronary Intervention/complications, Device Removal; Myocardial Revascularization.

Mailing Address: Elif Coskun

Bulent Ecevit University Faculty of Medicine - Eski Kozlu Yolu, Postal Code: 67000, Zonguldak - Turkey
E-mail: drelco@gmail.com



by arteriotomy of the diagonal artery. Then aortotomy was performed and the 12 cm piece of guidewire was successfully retrieved (Figure 2). Then an aorta-LAD artery to the LIMA graft bypass and an aorta-diagonal artery to the SVG bypass were performed. There were no complications in the postoperative period and the patient was discharged after four days.

Discussion

Complex and bifurcation lesions of the coronary arteries, multiple usages of the same guidewire lead to structural deterioration of the wire, which increases the risk of guidewire entrapment in the coronary vessel.³ Over-rotation or entrapment of the distal tip of the guidewire in a coronary vessel can also lead to the wire fracture.³

The guidewire fragments retained in the coronary artery can cause arterial embolism, thrombosis, dissection, and rupture of the vessels.³ Treatment options of entrapped guidewire are percutaneous intervention techniques, conservative therapies, and open surgery.^{1,4} Percutaneous intervention techniques are recommended as the treatment of choice. The most commonly used

percutaneous technique in this complication is the snare loop and its modifications. Small pieces of guidewire can remain in the distal segments of the coronary arteries or in chronically occluded or thrombosed vessels if they do not cause any adverse effects. If percutaneous techniques fail and signs of ischemia are observed, then the patient should be urgently transferred to open surgery.³ Surgical treatment consists of removal of the retained piece of guidewire and revascularization of the affected coronary arteries.⁵

In the present case, guidewire entrapment was probably caused use of a reused guidewire, which was entrapped in a calcified coronary plaque and broke in the femoral region after forceful attempts to remove it. The distal part of the guidewire extended to the ascending aorta from the diagonal artery. Urgent surgery was preferred in this case after failure of percutaneous intervention techniques and because the conventional method was not applicable.

Conclusion

The number of studies about surgical removal of fractured guidewire entrapped in a coronary artery is

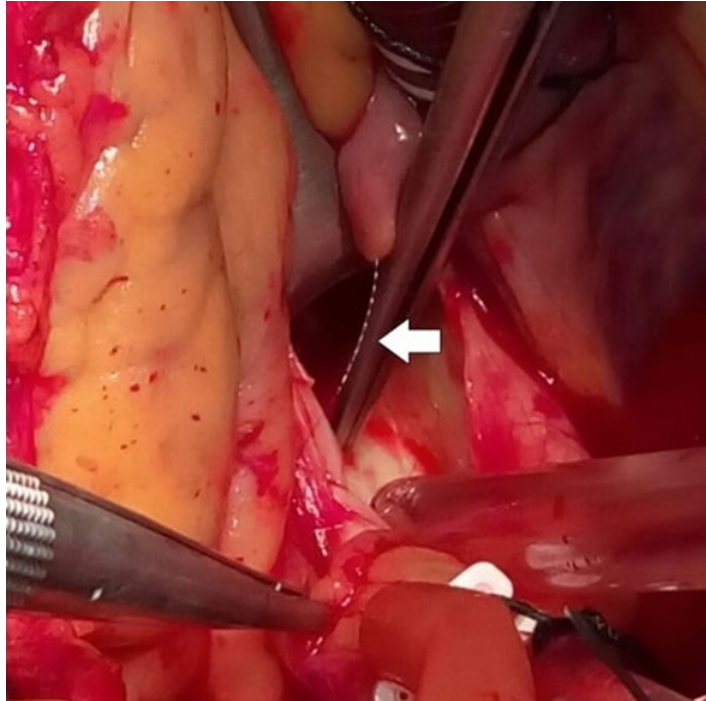


Figure 2 - Intraoperative image of the guidewire piece in the aorta.

very limited in the literature. The most recommended treatment is the urgent surgical removal of the extraneous material from the coronary circulation. We believe that new percutaneous techniques should be developed for the treatment of calcified plaques to reduce the risk of guidewire entrapment.

Author contributions

Conception and design of the research: Coskun E; Acquisition of data: Coskun E, Tekin A; Analysis and interpretation of the data: Altınay L; Statistical analysis: Altınay L, Coskun E; Obtaining financing: No; Writing of the manuscript: Coskun E, Altınay L; Critical revision of the manuscript for intellectual content: Tutun U; Supervision / as the major investigator: Coskun E, Altınay L, Tutun U.

Potential Conflict of Interest

No potential conflict of interest relevant to this article was reported.

Sources of Funding

There were no external funding sources for this study.

Study Association

This study is not associated with any thesis or dissertation work.

Ethics approval and consent to participate

This article does not contain any studies with human participants or animals performed by any of the authors.

References

1. Kaplan S, Kaplan ST, Kutlu M. An unusual case of guide wire fractured during primary percutaneous coronary intervention and two year follow up. *Kardiol Pol.* 2010;68(11):1291-3.
2. Balbi M, Bezante GP, Brunelli C, Rollando D. Guide wire fracture during percutaneous transluminal coronary angioplasty: possible causes and management. *Interact Cardiovasc Thorac Surg.* 2010;10(6):992-4.
3. Singh D, Darbari A. Retrieval of trapped and broken guide wire with immediate rescue off-pump coronary bypass surgery. *Interact Cardiovasc Thorac Surg.* 2014;19(3):529-31.
4. Al-Moghairi MA, Al-Amri SH. Management of Retained Intervention Guide-wire: A Literature Review. *Curr Cardiol Rev.* 2013;9(3):260-6.
5. Iturbe JM, Abdel-Karim AR, Papayannis A, Mahmood A, Rangan BV, Banerjee S, et al. Frequency, treatment, and consequences of device loss and entrapment in contemporary percutaneous coronary interventions. *J Invasive Cardiol.* 2012;24(5):215-21.

