

## Isolated Left Ventricular Apical Hypoplasia without Lamin A/C Gene Mutation

Paulo Henrique Manso,<sup>1</sup> Veridiana Kiill Suazo,<sup>2</sup> Fernando Tadeu Vasconcelos Amaral,<sup>3</sup> Mauro Cruz Jurca,<sup>4</sup> Henrique Simão Trad<sup>5</sup>

Universidade de São Paulo – Faculdade de Medicina de Ribeirão Preto, Ribeirão Preto, SP – Brazil

### Abstract

Isolated left ventricular apical hypoplasia is a rare cardiomyopathy, with a broad range of clinical presentations. Since this entity was already described in association with osteomuscular diseases, mutation in the Lamin A/C gene has been regarded as a possible cause of this disease. This study describes the case of an asymptomatic teenager with isolated left ventricular apical hypoplasia and arthrogriposis but with no mutations in the entire Lamin A/C gene.

### Introduction

Isolated left ventricular apical hypoplasia is a very rare anomaly with a broad range of clinical presentations. Mutation in the Lamin A/C gene has been regarded as a possible cause of this heart disease. The present study describes the case of an adolescent with isolated left ventricular apical hypoplasia and arthrogriposis without mutation in the Lamin A/C gene and conducts a review of the literature on this cardiomyopathy.

### Case presentation

An asymptomatic 13-year-old boy was diagnosed with a mild systolic murmur during a routine evaluation. He also presented arthrogriposis multiplex congenita with mild spine deviation, as well as scapular and wrist deformities. He had been previously submitted to three right foot procedures due to clubfoot. ECG showed

sinus bradycardia (HR = 50 bpm) with no conduction disturbances or left ventricular hypertrophy. Although our patient presented sinus bradycardia, he did perform well in a cardiopulmonary test. A transthoracic echocardiogram identified a mild left ventricular systolic dysfunction and an abnormal papillary muscle resembling a parachute mitral valve with no obstruction to left ventricular inflow. The patient was then started on enalapril.

One year later, a new routine echocardiogram identified a spherical left ventricle with an ejection fraction of 51%, with no signals of diastolic dysfunction, parachute mitral valve without dysfunction, and banana-shaped right ventricle (Figure 1A). Therefore, a cardiac MRI was performed.

The cardiac MRI identified an isolated left ventricular apical hypoplasia. It demonstrated the diagnostic aspects of the disease: spherical left ventricle configuration, fatty material at its apex, right ventricle elongation wrapping the deficient left ventricle apex, and both mitral papillary muscles originating in the flattened anterior apex (Figure 1B); however, it failed to confirm the presence of a parachute mitral valve. At his last medical visit, after a five-year follow-up or six years after initial diagnosis, the patient was asymptomatic and had sinus rhythm (Figure 2). However, a 24-hour Holter showed one episode of atrial tachycardia and two episodes of non-sustained ventricular tachycardia. The ejection fraction remained about 54% without diastolic dysfunction.

Because the patient presented arthrogriposis and cardiomyopathy, it was believed that this could be due to a laminopathy phenotype. Therefore, Sanger sequencing was performed for all 12 Lamin A/C gene exons in the proband and his parents, but no mutations were detected.

### Keywords

Isolated Left Ventricular/abnormalities; Cardiomyopathies/ physiopathology; Lamin Type A/C/genetics.

#### Mailing Address: Paulo Manso

Av. Bandeirantes, 3900. Postal Code: 14040-900, Ribeirão Preto, SP – Brazil.  
E-mail: phmanso@fmrp.usp.br

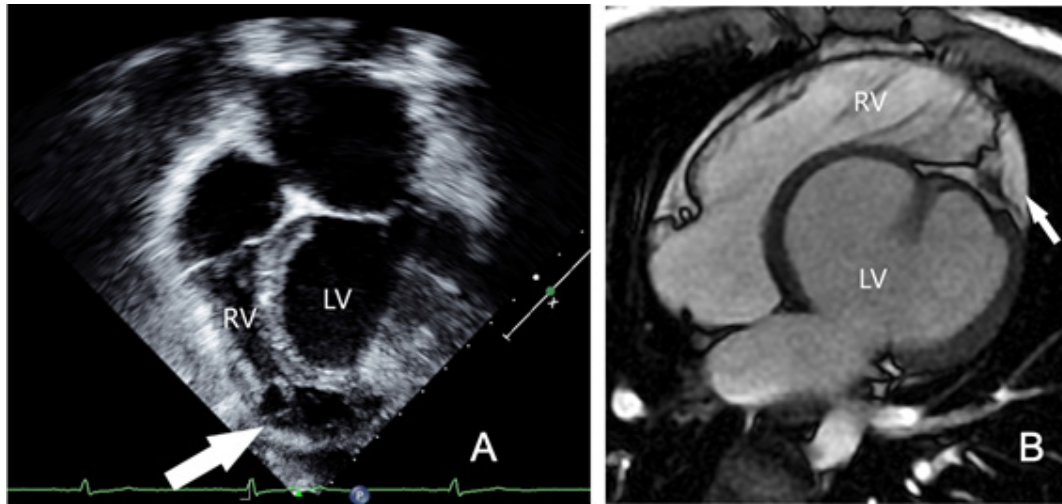


Figure 1 – A-Echocardiogram (four-chamber view) showing the right ventricle (RV) (arrow) wrapping the left ventricle (LV). B-Cardiac MRI (four-chamber view) showing spherical LV configuration, fatty material at LV apex (arrow), RV elongation wrapping the deficient LV apex.

## Discussion

Isolated left ventricular apical hypoplasia is a very rare disease. There have been no more than 50 reports since its first description in 2004.<sup>1</sup> Diagnosis age ranges from three months to 66 years.<sup>2</sup>

In most patients, including our case, the condition is discovered incidentally. Because isolated left ventricular apical hypoplasia is very rare, initial echocardiographic diagnosis may appear as a dilated cardiomyopathy.<sup>1</sup> A wrapping right ventricle, a bulging ventricular septum toward the right ventricle, and an abnormal papillary muscle aroused the suspicion of this diagnosis and showed the need for a cardiac MRI.

There is no report in the literature of a single pattern regarding the ECG of patients with isolated left ventricular apical hypoplasia: the ECG may present right or left deviation. Poor R progression across the chest leads and left bundle block have also been described. In addition, non-sustained ventricular tachycardia and atrial tachycardia have been reported in these patients,<sup>3</sup> as was also detected in our patient during a recent 24-hour Holter.

Clinical evolution may also vary from asymptomatic or mild clinical impairment to fatal arrhythmia. Therefore, the patient should be followed up to monitor the emergence of heart failure and arrhythmias.

To date, no clear cause for this disease has been established. The apical trabecular component, which is

most universally present in normal and in malformed and incomplete ventricles, and which most readily differentiates right from left ventricles from a morphological standpoint, is notably lacking in this disease. In most congenital left ventricle heart diseases, the apical component exists as an incomplete ventricle, even when the left ventricle sometimes lacks both the inlet and outlet components.<sup>4</sup>

We are not sure if this disease is part of some kind of genetic syndrome, but our patient also has arthrogryposis, as described by others.<sup>5</sup> This association of cardiopathy and muscular dystrophy led us to hypothesize that this entity may be related to the Lamin A/C gene, which underlies the so-called laminopathies. One study has described a specific mutation in the Lamin A/C gene (p.Arg644Cys) associated with this cardiopathy.<sup>6</sup> Mutations may be present in up to 40% of cases previously classified as idiopathic dilated cardiomyopathy.<sup>7</sup> In this picture, geneticists and cardiologists have been working together and establishing more accurate diagnoses.

The Lamin A/C gene encodes Lamin A and Lamin C. Mutations in this gene may lead to cell and tissue fragility, mainly in tissues submitted to mechanical stress, like heart and muscle.<sup>8</sup> A previous case report has described an association of arthrogryposis with this cardiomyopathy,<sup>5</sup> with a mutation in the Lamin A/C gene (p.Arg644Cys), which is considered to be the potential genetic cause.<sup>6</sup> This mutation is found not only in patients

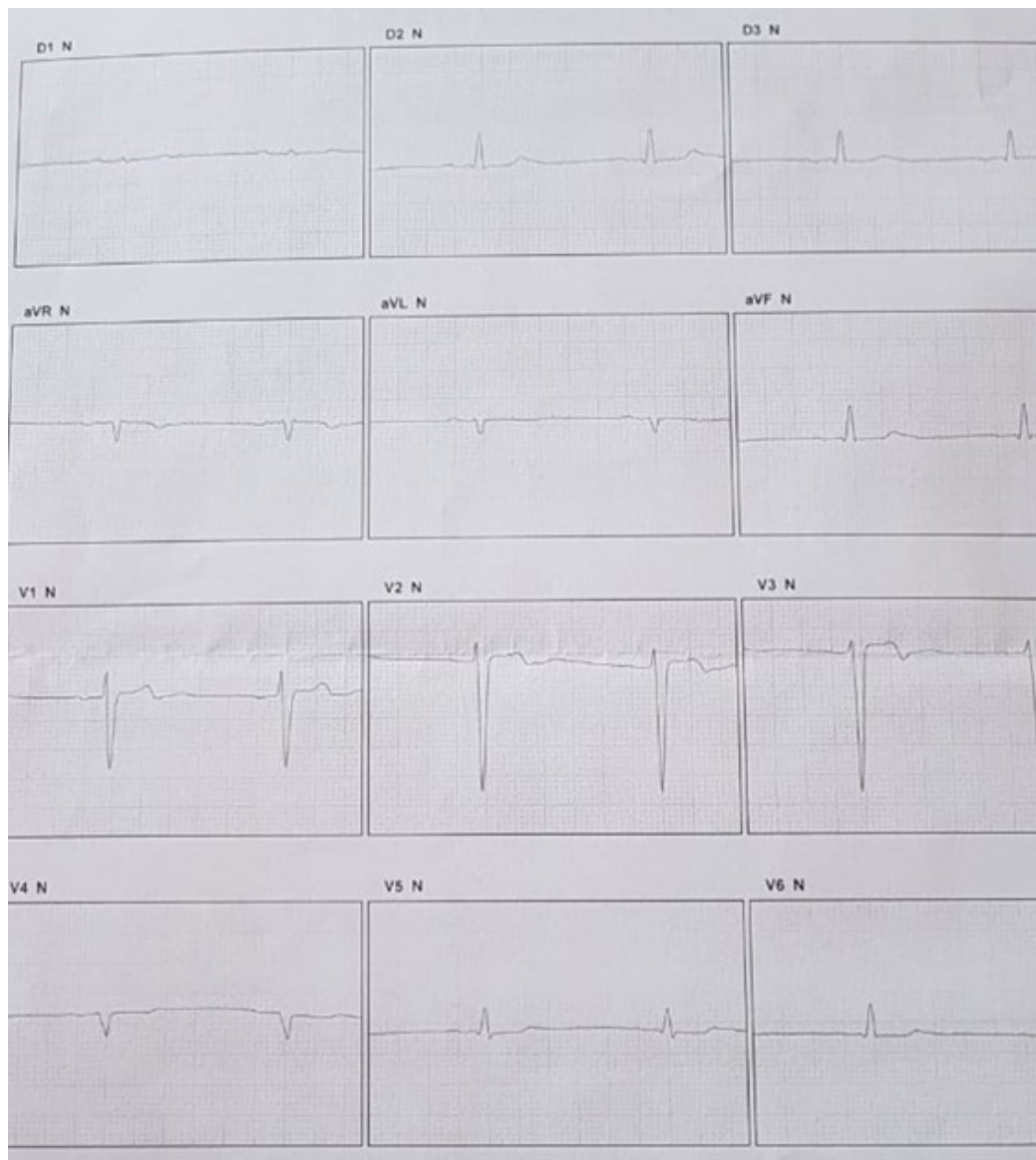


Figure 2 – 12-Lead Electrocardiogram showing sinus bradycardia

with cardiomyopathy, but also in patients with muscular and osteoarticular diseases<sup>9</sup>.

In the present case, no mutation in the Lamin A/C gene could be found; it is not surprising that, much like with most cardiomyopathies, more than one gene mutation may well be involved in causing this phenotype.

## Conclusion

Isolated left ventricular apical hypoplasia is a very rare disease, with multiple clinical and

electrocardiographic presentations. Close surveillance regarding heart failure and arrhythmias seems desirable. Although echocardiography may diagnose this entity, cardiac MRI is an invaluable tool in this diagnosis. Lamin A/C gene mutations alone may not account for this presentation.

## Acknowledgments

To Cynthia Manso for reviewing the English language.

## Author contributions

Conception and design of the research: Manso PH, Jurca MC, Trad HS. Acquisition of data: Manso PH, Suazo VK, Jurca MC, Trad HS. Analysis and interpretation of the data: Manso PH, Suazo VK, Jurca MC. Writing of the manuscript: Manso PH, Amaral FTV, Trad HS. Critical revision of the manuscript for intellectual content: Manso PH, Amaral FTV.

## Potential Conflict of Interest

No potential conflict of interest relevant to this article was reported.

## Sources of Funding

There were no external funding sources for this study.

## Study Association

This study is not associated with any thesis or dissertation work.

## Ethics approval and consent to participate

This study was approved by the Ethics Committee of the *Hospital das Clínicas* FMRP-USP under the protocol number 05001218600005440. All the procedures in this study were in accordance with the 1975 Helsinki Declaration, updated in 2013. Informed consent was obtained from all participants included in the study.

## References

1. Fernandez-Valls M, Srichai MB, Stillman AE, White RD. Isolated left ventricular apical hypoplasia: a new congenital anomaly described with cardiac tomography. *Heart*. 2004;90(5):552–5.
2. Vanhecke TE, Decker J, Leonowicz N, Chinnaiyan KM. CASE REPORT Isolated Left Ventricular Apical Hypoplasia. *Congenit Heart Dis*. Nov-Dec 2011;6(6):646–9.
3. Sani ZA, Vojdanparast M, Rezaeian N, Seifi A, Tehrani SO, Nezafati P. Left ventricular apical hypoplasia: Case report on cardiomyopathy and a history of sudden cardiac death. *ARYA Atheroscler*. 2016;12(1):50–4.
4. Anderson RH, Shirali G. Sequential segmental analysis. *Ann Pediatr Cardiol*. 2009;2(1):24.
5. Baroni M, Pedrotti P, Nava S, Giannattasio C, Roghi A. Cardiac Magnetic Resonance Imaging of Left Ventricular Apical Hypoplasia in Two Complex Congenital Clinical Syndromes. *Circ J*. 2014;78(6):1507–9.
6. Pica S, Ghio S, Raineri C, Scelsi L, Turco A, Visconti LO, et al. Mutazione del gene per la lamina A / C associata a ipoplasia apicale del ventricolo sinistro : un nuovo fenotipo di laminopatia ? *G Ital Cardiol*. 2014;15(12):717–9.
7. Júnior AL, Ferrari F, Max R, Ritt LEF, Stein R. Importance of genetic testing in dilated cardiomyopathy: Applications and challenges in clinical practice. *Arq Bras Cardiol*. 2019;113(2):274–81.
8. Taylor MR, Fain PR, Sinagra G, Robinson ML, Robertson AD, Carniel E, et al. Natural history of dilated cardiomyopathy due to lamin A/C gene mutations. *J Am Coll Cardiol*. 2003;41(5):771–80.
9. Rankin J, Auer-Grumbach M, Bagg W, Colclough K, Duong NT, Fenton-May J, et al. Extreme phenotypic diversity and nonpenetrance in families with the LMNA gene mutation R644C. *Am J Med Genet Part A*. 2008;146(12):1530–42.

