

Balloon Atrial Septostomy Guided by Echocardiography in a Neonatal Intensive Care Unit

Lilian M Lopes, Christiane Kawano, Salvador André Bavaresco Cristóvão, Célia Toshie Nagamatsu, Luciana da Fonseca, Beatriz Helena Sanchez Furlanetto, Gláucio Furlanetto, José Pedro da Silva, José Armando Mangione
Hospital Beneficência Portuguesa de São Paulo, São Paulo, SP - Brazil

Abstract

Background: The bedside two-dimensional echocardiography (2-D ECHO) has been successfully used to guide the balloon atrial septostomy, speeding up the procedure and preventing the risks of transportation to the hemodynamics laboratory.

Objective: To assess the results of the bedside balloon atrial septostomy in cyanotic neonates.

Methods: Between January/1997 and July/2008, 102 atrioseptostomies by balloon catheter guided by echocardiography were carried out and saturation levels, defect diameter, oxygen saturation, clinical-laboratory response and complications related to the procedure were evaluated.

Results: Of 102 cases of bedside Rashkind septostomy, 98 met the inclusion criteria, with 90 neonates in Group A (Rashkind procedure in the preoperative phase) and 8 in Group B (procedure at the postoperative phase). There was a predominance of the male sex (75%), mean age was 8.3 ± 9.3 days and the mean weight was $3,100 \pm 1,100$ g; the transposition of the great arteries was the most frequent congenital heart disease ($n = 74$). When comparing the levels of saturation pre and post-procedure ($65.9 \pm 19.5\%$ and $86 \pm 9.7\%$) and the diameter of the interatrial septal defect pre and post-procedure (2.3 ± 1.0 mm and 5.5 ± 1.3 mm) there was a statistically significant difference ($p < 0.001$). When comparing the levels of saturation and the diameter of the interatrial septal defect between the group of survivors vs non-survivor, there was no statistically significant difference ($p > 0.05$).

Conclusion: The balloon atrial septostomy guided by the echocardiography reduces the risks by allowing the effective palliative procedure to be carried out promptly in cyanotic neonates, in addition to presenting lower hospital costs. (Arq Bras Cardiol 2010; 95(2): 153-158)

Key words: Heart defects, congenital; echocardiography; heart atria; balloon dilatation.

Introduction

Some forms of cyanotic congenital heart disease (CHD), classically represented by the transposition of great arteries (TGA), are not compatible with survival in the absence of an adequate intercavitary mix.

The literature reports that the first hemodynamic therapeutic procedure by catheterism in CHD was the balloon atrial septostomy, described in 1966 by Rashkind and Miller¹, with the objective of increasing the existing interatrial communications, but which were functionally restrictive. Years later, in 1975, Park et al² proposed a technique that coupled a blade to catheter tip, in order to create an opening in intact or thick interatrial septum, common in infants older than 30 days

of age or in certain CHD where the septum is abnormally thick, such as in mitral atresia, in spite of the higher risk of mortality.

Traditionally, the procedure was carried out in Laboratories of Hemodynamics assisted by uniplanar fluoroscopy, which made it difficult to identify the balloon position and resulted in a higher risk of cardiac perforation, atrioventricular valve injury and laceration of pulmonary and systemic veins, among other complications³. These risks decreased with the use of biplanar fluoroscopy; however, in this case, there was a significant increase of exposure to ionizing radiation.

During the 80s it was published the first studies describing the advantages of echocardiography to guide the catheter position at the laboratory of hemodynamics during the invasive procedure⁴⁻⁶. These advantages were: 1) a faster procedure; 2) decrease in the risk of injury and trauma to the atrioventricular valves and vital structures and 3) decreased time of exposure to ionizing radiation⁷.

The performance of the procedure at a Neonatal Intensive Care Unit (NICU) guided only by echocardiography was first reported by Baker et al⁸, in 1984, in 8 children with complete transposition of the great arteries.

Mailing address: Lilian Maria Lopes •

Al. Santos, 211, conj 704 - Cerqueira César - 01419-000 - São Paulo, SP - Brazil

E-mail: lilianlopes@cardiol.br, lilianlopes@ecokid.com.br

Manuscript received April 01, 2009; revised manuscript received November 09, 2009; accepted November 18, 2009.

Since our first report⁹, we have performed a large number of atrioseptostomies by balloon catheter at the NICU of *Hospital Beneficência Portuguesa de São Paulo*, and the objective of the present study is to report such experience.

Methods

From January 1997 to July 2008, 102 Rashkind procedures guided by echocardiography were performed in patients with cyanotic CHD, who needed the presence of an adequate interatrial shunt to guarantee the survival until the moment when the palliative or definitive surgical treatment could be carried out. Patient selection was carried out according to the following inclusion criteria: 1) Rashkind procedure guided by echocardiography, performed at the Intensive Care Unit of *Hospital Beneficência Portuguesa de São Paulo*; 2) protocol data collection form filled out after the retrospective analysis of the patient's file.

Data was obtained through the analysis of hospital files and databases of the cardiac surgical teams of Dr. José Pedro da Silva and Dr. Gláucio Furlanetto. The medical reports, the recordings and the video clips of the echocardiograms were revised to confirm the foramen restriction. Loss of follow-up was considered when it was not possible to fill out all data in the protocol after the analysis of the medical files.

The variables analyzed as part of the protocol were: age at the moment of the Rashkind procedure, weight, sex, type of CHD, diameter of the septal defect pre and post-procedure, oxygen saturation pre and post-procedure, efficacy of the procedure based on the degree of the opening of the defect and clinical-laboratory improvement and procedure-related complications.

During these years, the dynamics at our service has been characterized by the mobilization of the echocardiography and hemodynamics teams as soon as a bed is confirmed to be available and the cyanotic neonate is transferred to our service. In case of patients with transposition of the great arteries, the teams remained alert and waiting for the arrival of the neonate at the Intensive Care Unit. Immediately after admission, and considering it an emergency procedure, the echocardiography team performed the bedside echocardiogram. After the clinical and echocardiographic confirmation of the restrictive foramen ovale, the hemodynamicist, who was already aware of the case, was always asked to perform the balloon atrial septostomy.

All patients were submitted to a bedside two-dimensional echocardiogram (2-D ECHO) and the intracardiac flow was evaluated by continuous pulsed Doppler and color-flow mapping Doppler for diagnostic confirmation. The equipment used for the echocardiographic assessment was: Phillips 7500 (Philips Medical Systems, Andover, Mass, USA), HDI 5000 (Advanced Technology Laboratories, Bothell, WA, USA) and Toshiba 140 and Nemio (Toshiba, Tokyo, Japan) with transducers of 2.5, 3.0 and 5.0 MHz, as they were being acquired by our service. When necessary, sedation was carried out with 10% chloral hydrate at doses recommended for the patient's weight.

The decision to perform the balloon atrial septostomy was made based on the clinical findings of hypoxia, followed by

the echocardiographic confirmation of restrictive atrial septal defect, characterized by the absence of visible communication or small-size communication, that is, < 2.0 mm or less than 1/4 of the total measurement of the interatrial septum measured in the subcostal position.

The invasive balloon atrial septostomy procedure was carried out according to the following phases: 1) puncture of the right or left femoral vein with #22 Jelco™, with the catheterization of the vein being carried out with a 0.021 inch guidewire; 2) under the echocardiographic assurance of the presence to the wire in the femoral vein, a 6F sheath was maintained in the venous site; 3) advance the Fogarty 5F atrial septostomy catheter up to the left atrium (Edwards-Baxter Healthcare); 4) graded insufflations of the balloon catheter, starting with 1 ml of saline solution and 5) abrupt traction, albeit controlled, with the objective of rupturing the interatrial septum.

Additional insufflations with higher volumes in the balloon (up to 4 ml) were performed until an adequate communication was obtained, confirmed by the improvement in O₂ saturation. The echocardiographic transducer guided the procedure through the subcostal echocardiographic approach, disclosing at the longitudinal subcostal view the vena cava draining into the right atrium, through which the balloon catheter proceeded.

The success criterion of the procedure was the increase in the peripheral oxygen saturation, the increase in the atrial septal defect diameter > 1/3 of the total septal diameter measured at the subcostal view or around 5 mm with ample border motility and clinical improvement. The transatrial gradient at the pulsed Doppler, both pre and post-procedure, was not considered a criterion of success, as it presented a wide interobserver variation related to the angle of insonation.

The descriptive statistical analysis of the quantitative variables was carried by calculating the median, means, standard deviations and minimum and maximum values. The qualitative variables were presented as absolute frequency (n) and relative frequency (%). Student's *t* test was used to compare the values of oxygen saturation and atrial septal defect diameter, before and after the Rashkind procedure, as well as to compare these results in survivors and non-survivors. Statistical significance was set at $p < 0.05$.

Results

Of a total of 102 cases of Rashkind procedure performed at the bedside at the NICU of this hospital, 90 patients were submitted to the Rashkind procedure at the preoperative phase (Group A), 8 patients were submitted to the procedure at the postoperative phase (Group B) and 4 were excluded because they did not meet the inclusion criteria (incomplete protocol data collection form).

Of the 98 cases that met the inclusion criteria, 73 (75%) were males and 25 (25%) were females. The mean age was 8.3 ± 9.3 days and the median was 4 days, ranging from 1 to 46 days. Mean weight was $3,100 \pm 1,100$ g and the median was 3,300 g, with a minimum weight of 2,300 g and a maximum weight of 6,500 g. Of the 90 patients from group A, the transposition of the great arteries was the most

Original Article

frequent congenital heart disease, diagnosed in 74 patients (82.2%). In one case of hypoplastic left heart syndrome, the fetal echocardiography had shown a severely restrictive foramen ovale and the Rashkind procedure was successfully performed at the Obstetric Unit immediately after the birth, after catheterization of the right femoral artery followed by a saturation increase from 70% to 92% (Figure 1). In the 8

patients from group B, the tricuspid atresia was the most frequent defect (62%) (Table 1).

The mean time between the Rashkind procedure and the surgical intervention in group A was 3.5 ± 4 days and the mean time between the surgery and the indication for the Rashkind procedure in group B was 1.7 ± 3.4 . There was a statistically significant difference when comparing the pre and

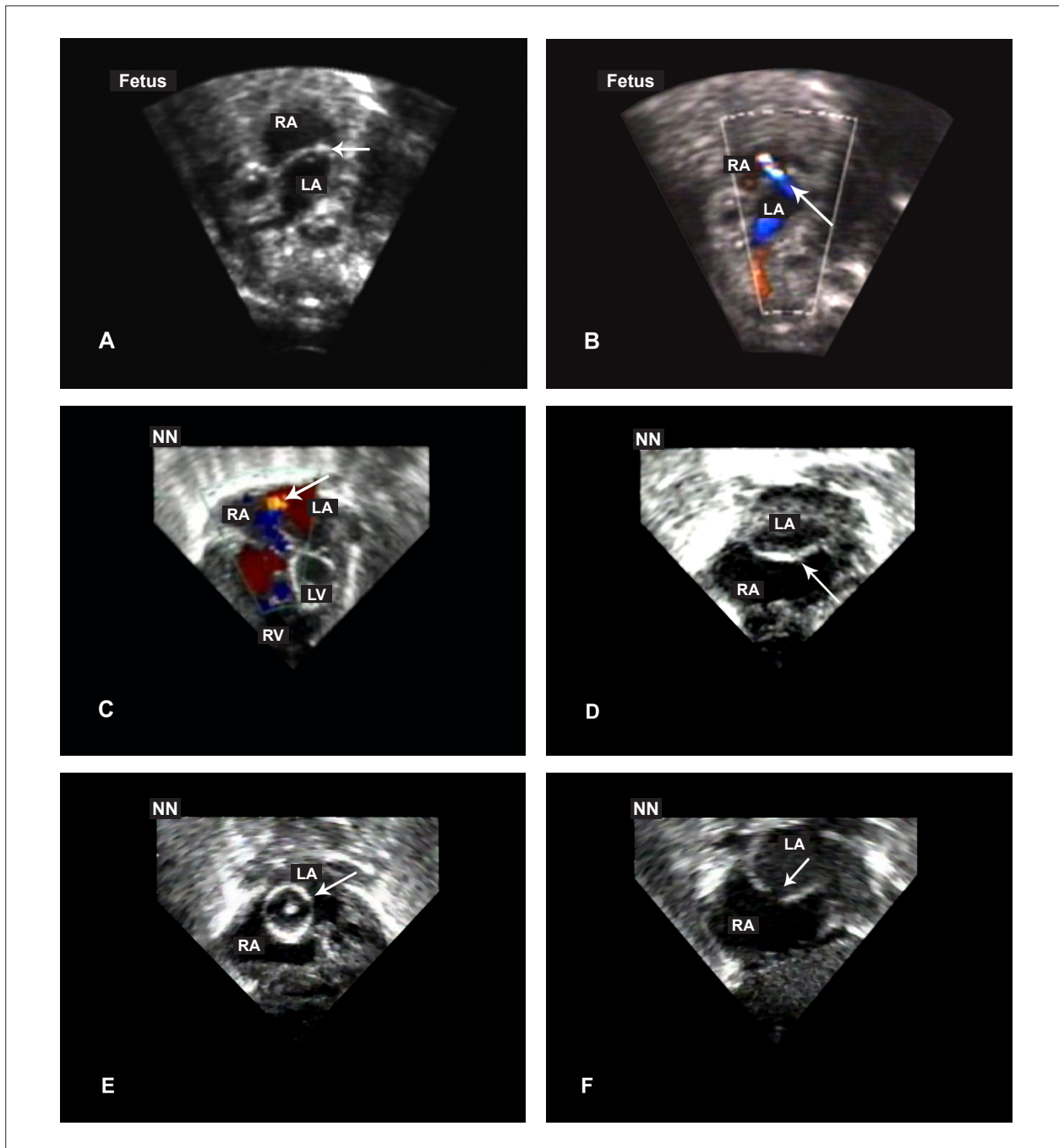


Figure 1 - Balloon atrial septostomy monitored by echocardiography in hypoplastic left heart syndrome with severely restrictive foramen ovale. A and D) Fetal and pediatric echocardiogram showing a practically closed interatrial septum, with no visible foramen at the two-dimensional echocardiogram. B and C) Color-flow mapping confirming the extremely restrictive foramen ovale through a thin and high-velocity flow. E) Inflated balloon in the LA. F) Atrial septal defect created after balloon septostomy. RA - right atrium; LA - left atrium; RV - right ventricle; LV - left ventricle.

Table 1 - Types of congenital heart diseases in neonates submitted to an atrial septostomy guided by echocardiography

Type of cardiopathy	Number of patients
Group A	90
TGA	43
TGA + VSD	17
TGA + VSD + PS	8
TGA + AoC	2
TGA + PS	4
TA	8
PA + intact IVS	5
HLHS	1
TAPVR	1
Isolated ventricular inversion	1
Group B	8
TA	5
PA+ intact IVS	3

TGA - transposition of great arteries; AoC - aortic coarctation; VSD - ventricular septal defect; PS - pulmonary stenosis; PA + intact SIV - pulmonary atresia with intact interventricular septum; TA - tricuspid atresia; HLHS - hypoplastic left heart syndrome; TAPVR - Total Anomalous Pulmonary Venous Return.

post-procedure saturation levels and the diameters of the atrial septal defect ($p < 0.001$).

Table 2 shows the individual characteristics of the patients in groups A and B submitted to the balloon atrial septostomy.

The procedure was effective in 95 of 98 of the cases. Procedure failures were explained respectively by the impossibility to advance the catheter into the inferior vena cava ($n = 1$), the impossibility to reach the left atrium ($n = 1$) and the difficulty to achieve an adequate position of the balloon into a small left atrium ($n = 1$).

There were two complications related to the procedure, both in neonates with transposition of the great arteries: one case of atrial fibrillation followed by ventricular tachycardia and tamponade due to probable right atrium injury in a six-day old neonate and another case of bradycardia in a 46-day-old infant. There were 8 deaths before surgery and one patient was discharged without surgery.

When comparing the group of survivors with the non-survivors regarding the pre-procedure saturation levels (67%

± 20 versus $64\% \pm 19$, $p = 0.50$), post-procedure saturation ($85.8\% \pm 9$ versus 85.1 ± 11 , $p = 0.69$), pre-procedure diameter of the atrial septal defect (2.3 ± 0.9 versus 2.4 ± 1.2 , $p = 0.65$) and post-procedure diameter of the atrial septal defect (5.4 ± 1.4 versus 5.5 ± 1.2 , $p = 0.81$), there was no statistically significant difference ($p > 0.05$). The most common cause of death was cardiogenic shock (65%), followed by septic shock (21%), which was unrelated to the success criteria of the procedure.

Discussion

The balloon atrial septostomy using fluoroscopy or 2D-ECHO is an acknowledged technique in the palliative treatment of cyanotic CHD in hypoxemic neonates due to inadequate intracardiac mix. With the passing time and the consequent technological advancements, this procedure stopped to be carried out exclusively in Laboratories of Hemodynamics and started to be performed inside the intensive care units at the bedside⁷⁻¹⁰.

During the 80s, Allan et al⁷ described as advantages of the bedside procedure the faster performance of the procedure, the decrease in the time of exposure to ionizing radiation, the decrease in the risk of injury and trauma to the atrioventricular valves and vital structures and the fact that the technique prevented the manipulation and probable destabilization of neonates in unstable metabolic situation. Moreover, there is the important economic factor to be considered, as the echocardiographic monitoring of the bedside balloon atrial septostomy presents a 50% decrease in cost when compared to the procedure performed at the Laboratory of Hemodynamics.

Zellers et al¹¹ compared the hospital costs of 21 neonates submitted to balloon atrial septostomy at the Laboratory of Hemodynamics with the costs of 17 neonates that underwent the same intervention at bedside. These calculations took into account the costs of cardiac catheterism and atrial septostomy, disposable material, transportation costs, medication and medical fees. The costs with echocardiography were not included in the analysis, as all the patients were submitted to a complete echocardiographic assessment, regardless of the fact whether the atrial septostomy was carried out at the Laboratory of Hemodynamics or at the bedside. Similarly to what was observed in our service there was no additional medical or hospital cost when the echocardiography was used to guide the atrial septostomy. The authors concluded that the total cost of the bedside procedure was statistically lower when compared to the procedure performed at the

Table 2 - Individual characteristics and variables of the neonates submitted to balloon atrial septostomy guided by two-dimensional echocardiography

Lesion	n	Age days	Weight kg	ASDPre	ASD Post	Sat Pre %	Sat Post %	Effectiveness %	Surgery -Rashkind interval*	Death %
Group A	90	9.6 ± 9.8	3.4 ± 0.6	2.2 ± 1.0	5.5 ± 1.3	65.8 ± 19.5	85.5 ± 9.5	96.6% (87/90)	3.5 ± 4	41.1% (37/90)
Group B	8	6.2 ± 4.7	3.0 ± 0.4	3.8 ± 0.9	6.0 ± 1.1	67 ± 20.8	85.1 ± 12.1	100% (8/8)	1.7 ± 3.4*	75% (6/8)
Total	98	8.3 ± 9.3	3.1 ± 1.1	2.3 ± 1.0	5.5 ± 1.3	65.9 ± 19.5	86 ± 9.7	96.9 (95/98)	-	42% (43/98)

*Interval between the surgery and the indication for the Rashkind procedure.

Original Article

Laboratory of Hemodynamics (US\$ 5,285 ± 123 vs US\$ 10,089 ± 382; $p < 0.001$).

Although in Brazil the first report of bedside balloon atrial septostomy guided by echocardiography was published in 1988¹², it is known that large referral hospitals in the country are still reluctant to adopt this approach. Following the initial experience of Serra et al¹² in 9 neonates, other national authors reported their experience^{13,14}, with the most recent and largest of them being that of de Marchi et al¹⁵ carried out at the Hospital of the School of Medicine of São José do Rio Preto, in 31 neonates with CHD with a low number of complications.

After our first report, published in 2001⁹, we have acquired a large experience in performing bedside balloon atrial septostomy guided by two-dimensional echocardiography. As our experience grew, we were able to give up the use of radioscopy and the bedside performance of this procedure became a routine at our service. The large numbers of patients presented in this study shows an effectiveness rate of 96.9% and a low rate of complications (2.0%), represented mainly by arrhythmias associated with the catheter manipulation and that have been previously reported by other authors^{14,15}.

Although these data in the literature point out to a more guarded prognosis in cases of hypoplastic left heart syndrome with restrictive foramen ovale¹⁶, in our only case diagnosed through the fetal echocardiography at 20 weeks of gestation and a practically closed foramen ovale (less than 1 mm-diameter), the delivery was successfully planned and the Rashkind procedure was successfully performed inside the obstetric unit. The child is alive and well at two years of age

after the third stage of Norwood surgery.

In conclusion, the balloon atrial septostomy guided by two-dimensional echocardiography in a neonatal ICU allows effective and prompt palliation in severely ill neonates, decreasing the risk of injury and trauma to the atrioventricular valves and vital structures, in addition to presenting lower hospital costs. In a country such as Brazil, which has serious economic difficulties in the healthcare area, this information is very important.

Acknowledgements

To the pediatric echocardiography team of *Hospital Beneficência Portuguesa* of São Paulo for their support in performing the echocardiograms.

To Mr. Carlos E. S. Cateb for editing and preparing the photographic material.

Potential Conflict of Interest

No potential conflict of interest relevant to this article was reported.

Sources of Funding

There were no external funding sources for this study.

Study Association

This study is not associated with any post-graduation program.

References

1. Rashkind WJ, Miller WW. Creation of an atrial septal defect without thoracotomy: a palliative approach to complete transposition of the great arteries. *JAMA*. 1966; 196 (11): 991-2.
2. Park SC, Zuberbuhler JR, Neches WH, Lenox CC, Zoltun RA. A new atrial septostomy technique. *Cathet Cardiovasc Diagn*. 1975; 1 (2): 195-201.
3. Rashkind WJ. The complications of balloon atrioseptostomy. *J Pediatrics*. 1970; 76 (4): 649-50.
4. Perry LW, Galioto FM Jr, Blair T, Shapiro SR, Ruckman RN, Scott LP. Two-dimensional echocardiography for catheter location and placement in infants and children. *Pediatrics*. 1981; 67 (4): 541-7.
5. Matsunaga S, Suzuki K, Ichinose E, Takeuchi S, Yoshioka F, Yokochi K, et al. Application of two dimensional echocardiography for the intracardiac manipulation: the evaluation of atrial septal movement before and after balloon atrial septostomy. *J Cardiol*. 1981; 11 (1): 217-24.
6. Perry LW, Ruckman RN, Galioto FM Jr, Shapiro SR, Potter BM, Scott LP. Echocardiographically assisted balloon atrial septostomy. *Pediatrics*. 1982; 70 (3): 403-8.
7. Allan LD, Leavage R, Wainwright R, Joseph MC, Tynan M. Balloon atrial septostomy under two dimensional echocardiographic control. *Br Heart J*. 1982; 47 (1): 41-3.
8. Baker EJ, Allan LD, Tynan MJ, Jones OD, Joseph MC, Deverall PB. Balloon atrial septostomy in the neonatal intensive care unit. *Br Heart J*. 1984; 51 (4): 377-8.
9. Nagamatsu CT, Cristóvão AS, Tavares GMP, Lopes LM. Atrioseptostomia por cateter balão guiado por ecocardiograma à beira do leito. *Rev Bras Ecocardiogr*. 2001; 5: 55.
10. Jamjureeruk V, Sangtawesin C, Layangool T. Balloon atrial septostomy under two-dimensional echocardiographic control: a new outlook. *Pediatr Cardiol*. 1997; 18 (3): 197-200.
11. Zellers TM, Dixon K, Moake L, Wright J, Ramaciotti C. Bedside balloon atrial septostomy is safe, efficacious, and cost-effective compared with septostomy performed in the cardiac catheterization laboratory. *Am J Cardiol*. 2002; 89 (5): 613-5.
12. Serra A, Chamiê F, Paupério H, Sbaifi F, Lopes JM, De Carvalho M, et al. Atrioseptostomia com balão através da ecocardiografia bidimensional. *Arq Bras Cardiol*. 1988; 50: 179-82.
13. Mattos SS, Severi R, Marques DL, Parpinelli RC, Mabesoone PA, Francisco S F², et al. Atrioseptostomia em unidade de terapia intensiva sob monitorização ecocardiográfica: experiência inicial do Instituto do Coração de Pernambuco. *Arq Bras Cardiol*. 1993; 61 (1): 33-6.
14. Silva CMC, Matos RP, Abujamra PA, Gomes LFH, Belo PP, Carvalho ACC. Atrioseptostomia por balão à beira do leito. *Arq Bras Cardiol*. 1999; 73: 68.
15. Marchi CH, Godoy MF, Santos MA, Moscardini AC, Sobrinho SH, Croti UA. Monitoração ecocardiográfica da atrioseptostomia com balão. *Arq Bras Cardiol*. 2005; 84 (3): 245-50.
16. Glatz JA, Tabbutt S, Gaynor JW, Rome JJ, Montenegro L, Spray TL, Rychik J. Hypoplastic left heart syndrome with atrial level restriction in the era of prenatal diagnosis. *Ann Thorac Surg*. 2007; 84 (5): 1633-9.