

## Endovascular Stent-Graft Treatment of Penetrating Aortic Ulcer

Rogério Tadeu Tumelero, Norberto Toazza Duda, Alexandre Pereira Tognon, Luciano Panata, Júlio Cesar Canfield Teixeira, João Batista Machado Giongo

Hospital São Vicente de Paulo, Faculdade de Medicina da Universidade de Passo Fundo, passo Fundo, RS - Brazil

Penetrating aortic atherosclerotic ulcer is an underdiagnosed condition that presents high rates of morbidity and mortality. We report two cases of patients with severe chest pain, with no ischemic features, who underwent chest angiotomography and showed an ulceration of the aortic wall, with contrast penetration into the middle layer. Due to the failure of the medical treatment, the patients underwent percutaneous aortic stent implantation with complete resolution of symptoms.

### Introduction

Penetrating atherosclerotic ulcer of the aorta was first defined in modern literature by Shennan in 1934<sup>1</sup> and in modern literature by Stanson<sup>2</sup>, in 1986 as an ulceration of an aortic atherosclerotic lesion that penetrates the internal elastic lamina and allows for hematoma formation in the aortic wall<sup>2</sup>. Deep ulceration of atherosclerotic plaques in the aorta can lead to the formation of an intramural hematoma, a classic aortic dissection, or a perforation<sup>3</sup>. This disease occurs mostly in elderly patients between the sixth and the eighth decades of life, and is associated with hypertension (approximately 94% of cases) and smoking habit. Most patients have other atherosclerotic disease manifestations, and half of these have a history of thoracic or abdominal aortic aneurysm. The clinical picture mimics the classic aortic dissection, with anterior chest pain in ulcers of the ascending aorta, and interscapular or back pain in lesions of the descending aorta. Unlike classical dissection, aortic ulcers produce no ischemic events in limbs or organ systems. These cases have greater risk of rupture and mortality in one year when compared with classic aortic dissection<sup>3-5</sup>.

### Case reports

A 58-year-old male patient was admitted to the emergency room referring retrosternal pain, described as

### Keywords

Prosthesis implantation; heart valve prosthesis; ulcer/therapy aorta, thoracic.

squeezing, and a high-intensity “stab” radiating to his left arm, jaw, and interscapular region, with sudden onset six hours before admission. The pain was intense and sustained from the beginning, with no relieving or aggravating factor. Associated with the pain, the patient had nausea, dizziness, and profuse diaphoresis.

The patient had had a history of hypertension two years before admission, but did not use medication. He denied other comorbidities, alcohol consumption, or current smoking habit. He had a family history of hypertension. On physical examination, the patient had good coloring and was alert, oriented, and coherent, but anxious. The blood pressure was 160/100 mmHg in the right upper limb, and 140/80 mmHg in the left upper limb, with a heart rate of 88 bpm. Heart auscultation revealed a 2/6 holosystolic murmur in the mitral valve area that radiated to the armpit. The patient had warm extremities, full and symmetric pulses, normal chest auscultation, nontender abdomen without murmurs, and normal findings on neurological examination. His electrocardiogram showed no ischemic changes.

He then underwent chest computed tomography angiography (Fig. 1A), which revealed an ulcer of the left lateral wall of the aorta, after the origin of the left subclavian artery, with contrast penetration into the middle layer. The transesophageal echocardiography showed an image suggestive of ulcer of the aorta. Initially the patient was treated with angiotensin I-converting enzyme inhibitors, beta-blockers, and non-opioid analgesics.

Despite blood pressure and heart rate control, the patient continued to present pain episodes. After the drug treatment, there was significant worsening of the pain, requiring the use of opioids, without adequate relief of the symptoms.

A coronary angiography was performed, which revealed no coronary artery disease, and the chest aortography showed an irregular image after the left subclavian artery origin. An urgent percutaneous treatment was indicated with an aortic endoprosthesis implantation. Under general anesthesia, the right femoral artery was dissected: an Amplatzer 0.35” x 260 cm guide was introduced in the ascending aorta, and an APOLLO 34 mm x 125 mm stent was placed after the origin of the left subclavian artery (Fig. 1B).

Since no proper identification of the image was achieved by aortography, the stent positioning was defined by the previously described angiotomographic images. The total procedure time was 110 minutes. After the procedure, still in the catheterization laboratory, the anesthesia was reversed, and the patient remained asymptomatic. He was discharged on the ninth day after the stent implantation.

**Mailing address: Rogério Tadeu Tumelero •**

Rua Teixeira Soares, 777/705 - Centro - 99010-080 - Passo Fundo, RS - Brazil  
E-mail: rttumelero@cardiol.br, rttumelero@terra.com.br

Manuscript received March 13, 2009; revised manuscript received December 28, 2009; accepted March 18, 2010.

Sixteen months after the intervention, an aortography was performed showing occlusion of the left subclavian artery, which filled through the circle of Willis after selective contrast injection in the right vertebral artery. The aortography also showed proper positioning of the stent (Fig. 1C and 1D), and the CT scan of the thoracic aorta showed no image suggestive of ulcer (Fig. 1E). In the 20-month outpatient follow-up period, the subject remained event free.

The second case is that of an 85 year old female patient, who was admitted to the emergency room referring high intensity interscapular chest pain without radiation, which had begun suddenly at home two hours before admission. Associated with the pain, the patient had nausea, vomiting, and pallor.

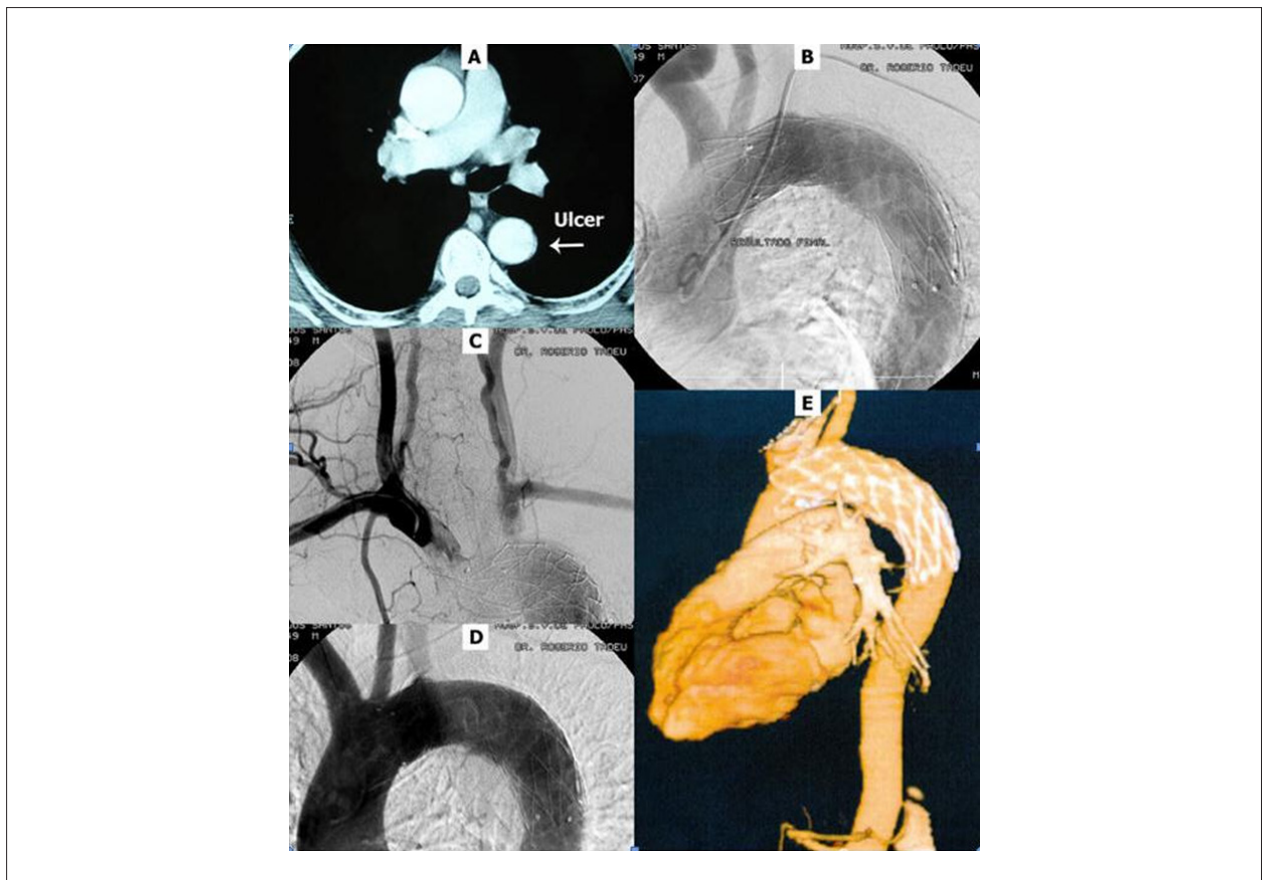The patient reported having had hypertension and smoking habit for a long time, and she used 10 mg nitrendipine and 100 mg ASS once a day. She reported no other comorbidities or personal and family history. On physical examination she was pale, prostrate, but oriented and coherent. The blood pressure was 180/110 mmHg in both upper limbs, and the heart rate was 68 bpm. The heart auscultation revealed diminished heart sounds and a 2/6 ejection murmur in the aortic area that radiated to the cervical region. The patient had warm extremities, 3/4 full and symmetrical pulses, normal pulmonary

auscultation, nontender abdomen without murmurs, and normal findings on neurological examination.

The electrocardiogram performed in the emergency room showed right bundle branch block and secondary alterations of ventricular repolarization. A transthoracic echocardiogram was performed, revealing a transmural hematoma in the descending aorta, LV hypertrophy, and a moderate double aortic lesion. She then underwent a chest angiotomography, which revealed a penetrating ulcer with contrast extravasation into the middle layer, a transmural hematoma immediately after the origin of the left subclavian artery, and a mild left pleural effusion (Fig. 2A).

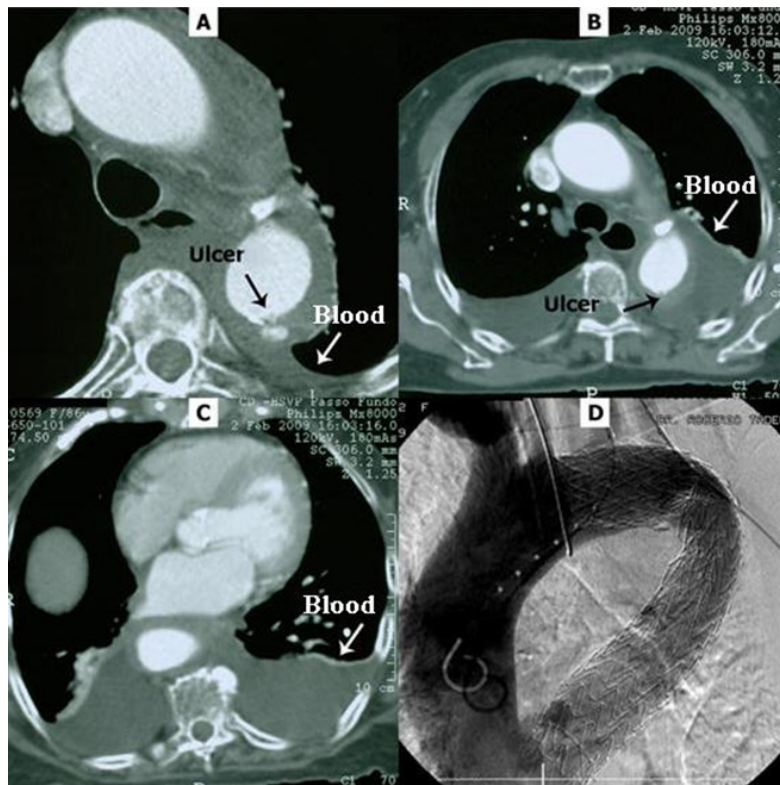
After the diagnosis of ulcer of the descending aorta was established, the patient was treated medically with intravenous sodium nitroprusside and beta blockers. After a 10-day hospitalization period in medical treatment, she had a recurrence of the pain with a 10-point drop in hematocrit. A new angiotomography of the chest showed progression of the hematoma and extensive bilateral pleural effusion (Fig. 2B and 2C).

A cineangiogram and an aortography were performed, aiming at a percutaneous aortic endoprosthesis implantation. The coronary angiography showed severe stenosis (80%) in the distal third of the anterior descending coronary artery with no other significant injuries in other coronary



**Figure 1** - A - chest CT showing a penetrating ulcer in the aorta; B - aortography after stent implantation showing occlusion of the left subclavian artery; C - aortography after 16 months showing filling of the left subclavian artery from the right vertebral artery; D and E - aortography and angiography after 16 months demonstrating proper positioning of the stent.

## Case Report



**Figure 2** - A - chest CT on admission revealing a penetrating ulcer and left pleural effusion; B and C - chest CT on the 10th day after admission demonstrating progression of the hematoma and extensive bilateral pleural effusion; and D - aortography after stent implantation.

arteries, and left ventricle with normal function. The thoracic and abdominal aortography showed significant atherosclerosis and tortuosity, with no visible contrast extravasation. In the following day, under general anesthesia, the right femoral artery was dissected, and an Amplatzer 0.35" x 260 cm guide was introduced in the ascending aorta, and a Tag/Gore 34 mm x 200 mm stent was positioned after the origin of the left subclavian artery (the endoprosthesis placement was based on 3D tomographic images). The total procedure time was 110 minutes. After the procedure the patient had complete resolution of symptoms and improvement in hematocrit. She remained hospitalized for 10 days and was discharged asymptomatic.

### Discussion

In recent decades there have been increasing development and advancement in cardiac imaging methods, especially marked by the emergence and refinement of the computed tomography and the magnetic resonance imaging. These advances have given us, among other things, knowledge of classic aortic dissection variations. Therefore, this allowed for the diagnosis of intramural hematoma and penetrating atherosclerotic aortic ulcer, which were described by Shennan, in 1934<sup>1</sup>, and more recently characterized by Stanson, in 1986<sup>2,5</sup>. Today we recognize these variants as precursors of classic aortic dissection; moreover, deep ulcers of the aorta can lead to hematoma formation and even

rupture of the aorta<sup>6</sup>. The risk of rupture and mortality in one year is higher for these patients when compared to that of classic dissection<sup>4</sup>. In addition, ulcers of the aorta can cause intractable chronic chest pain, which is an independent factor for disease progression and an indication for an aggressive initial approach<sup>3,6</sup>.

Therefore, this is a situation in which the treatment should be instituted as soon as the diagnosis is confirmed by imaging studies, because there is high risk of rupture and mortality.

Among the therapeutic options, percutaneous treatment with stent implantation via the femoral artery is preferred over traditional surgery, due to its higher safety and lower rates of complications, especially considering the high risk for surgery in most patients, due to their advanced age, and the associated comorbidities<sup>4-8</sup>. It is suggested, then, that the percutaneous approach should be the preferred approach in centers with experience in treating diseases of the aorta.

In the reported cases, we observed the usual extremes of age for the manifestation of the disease in patients of both genders presenting with an initial diagnosis of ischemic heart disease, which reinforced the need for constant clinical suspicion of acute aortic diseases.

In these cases, the initial approach, with blood pressure control and treatment of pain with opioid painkillers, was not effective for the resolution of the symptoms presented by the patients. So we opted for a percutaneous aortic stent implantation

and achieved symptomatic resolution and maintenance of the clinical outcome for a 20-month follow-up period, in the first case, and a 30-day follow-up period, in the second case.

#### Potential Conflict of Interest

No potential conflict of interest relevant to this article was reported.

#### Sources of Funding

There were no external funding sources for this study.

#### Study Association

This study is not associated with any post-graduation program.

## References

1. Shennan T. Dissecting aneurysms. London: HM Stationery Office; 1934. (M.R.C.Special Report Series, n.193).
2. Stanson AW, Kazmier FJ, Hollier LH, Edwards WD, Pairolero PC, Sheedy PF, et al. Penetrating atherosclerotic ulcers of the thoracic aorta: natural history and clinicopathologic correlations. *Ann Vasc Surg.* 1986; 1 (1): 15-23.
3. Ganaha F, Miller DC, Sugimoto K, Do YS, Minamiguchi H, Saito H, et al. Prognosis of aortic intramural hematoma with and without penetrating atherosclerotic ulcer: a clinical and radiological analysis. *Circulation.* 2002; 106 (3): 342-8.
4. Coady MA, Rizzo JA, Hammond GL, Pierce JG, Kopf GS, Elefteriades JA. Penetrating ulcer of the thoracic aorta: what is it?. How do we recognize it? How do we manage it? *J Vasc Surg.* 1998; 27 (6): 1006-15.
5. Buffolo E, Pessa CJN. Variantes da disseção aórtica: úlcera penetrante de aorta e hematoma intramural de aorta - uma análise contemporânea. *Rev Soc Cardiol Estado de São Paulo.* 2001; 11 (6): 1053-9.
6. Tsai TT, Nienaber CA, Eagle KA. Acute aortic syndromes. *Circulation.* 2005; 112 (24): 3802-13.
7. Brinster DR, Wheatley GH 3rd, Williams J, Ramaiah VG, Diethrich EB, Rodriguez-Lopez JA. Are penetrating aortic ulcers best treated using an endovascular approach? *Ann Thorac Surg.* 2006; 82 (5): 1688-91.
8. Botta L, Buttazzi K, Russo V, Parlapiano M, Gostoli V, Bartolomeo RD, et al. Endovascular repair for penetrating atherosclerotic ulcers of the descending thoracic aorta: early and mid-term results. *Ann Thorac Surg.* 2008; 85 (3): 987-92.