

Clinicopathologic Session

Case 6/2001 – The patient is an 11-year-old girl with Takayasu's arteritis and heart failure (Instituto do Coração do Hospital das Clínicas – FMUSP - São Paulo)

Fabio Gazelato de Mello Franco, Dante Marcelo Artigas Giorgi, Maria Clementina Pinto Giorgi,
Paulo Sampaio Gutierrez

São Paulo, SP - Brazil

The patient is an 11-year-old girl who sought medical assistance due to lumbar pain, nausea, and dyspnea.

One year earlier, this patient had been diagnosed with Takayasu's arteritis, hypertension of renovascular origin, and marked left ventricular dysfunction. At that time, the patient underwent renal revascularization with a saphenous vein bypass graft between the aorta and both renal arteries; a postoperative occlusion of the graft occurred, requiring a new revascularization. Acute renal failure, elevation in urea levels up to 160mg/dL and creatinine levels up to 6.8mg/dL, which decreased later, complicated the interventions. On that occasion, the chest X-ray showed cardiomegaly and pulmonary congestion. The echocardiogram showed diffuse hypokinesia and marked left ventricular dilation, a diastolic diameter of 69mm, a systolic diameter of 60mm, and a shortening fraction of 13%.

The patient was discharged on the 21st postoperative day, in good clinical condition, and with no complaints. Her heart rate was 104bpm, her blood pressure 90/60mmHg, and no other abnormalities were found on physical examination. Her creatinine level was 0.8mg/dL. The patient received the following prescription: 100mg of acetylsalicylic acid, 20mg of furosemide, 0.25mg of digoxin, and 18.5mg of captopril.

For 3 months the patient evolved with dyspnea on strenuous exertion and lumbar pain attributed to urolithiasis, which was documented on ultrasonography. A few days later, complaining of nausea, dyspnea, lumbar pain, and malaise, the patient sought medical assistance.

On physical examination, the patient was in regular condition; her heart rate was 100bpm and blood pressure 120/80mmHg. Rhonchi and wheezings could be heard in both hemithoraces. Her cardiac rhythm was regular. The 2nd cardiac sound was loud in the pulmonary area, and a systolic murmur (+/4+) could be heard in the mitral area. Her liver was palpated 2cm from the xiphoid process, and edema (+/+4+) was present in her lower limbs.

The laboratory tests revealed anemia, neutrophilia with a high percentage of immature cells, and circulating antibodies of the IgG class for hepatitis A and cytomegalovirus. Serology was negative for hepatitis B and C, and mononucleosis (tab. I). After undergoing X-rays of the facial sinuses (frontal and submental views), which showed no alterations, the patient was prescribed cefaclor and admitted to the hospital for diagnostic investigation and heart failure compensation.

The electrocardiogram revealed sinus rhythm, hypertrophy of both atria and of the left ventricle, and secondary alterations in ventricular repolarization (fig. 1).

The echocardiogram showed marked left ventricular dilation and hypokinesia (diastolic diameter of 68mm, systolic diameter of 59mm, and shortening fraction of 13%), distance between the mitral valve E point to the septum of 31mm, and low aortic flow (0.4m/s). The aortic valve showed signs of early closing. No anomaly was observed in the cardiac valves.

On hospital persisted heart failure and appeared pain in the anterior and posterior portions of the thorax. A few days later, severe dyspnea, hemoptysis, and worsening of the edema of the lower limbs occurred.

The electrocardiogram revealed sinus rhythm, a heart rate of 137bpm, reduction in voltage in the frontal plane (as compared with that in the previous electrocardiogram), left ventricular hypertrophy, and secondary alterations in ventricular repolarization (fig. 2). The chest X-ray showed pulmonary congestion.

A reduction in diuresis occurred, and the patient

Session editor: Alfredo José Mansur (ajmansur@incor.usp.br)

Associate editors: Desiderio Favarato (dcfavarato@incor.usp.br)

Vera Demarchi Aiello (anpvera@incor.usp.br)

Mailing address: Dante Marcelo Artigas Giorgi – InCor – Av. Dr. Enéas C. Aguiar, 44
05403-000 – São Paulo, SP, Brazil – E-mail: hipdante@incor.usp.br

English version by Stela Maris C. e Gandour

Table I – Laboratory tests				
	6/13/97	6/25/97	7/11/97	7/17/97
Red blood cells/mm ³	4,900,000	5,300,000	4,500,000	4,700,000
Hemoglobin (g/dL)	11.1	11.8	11	11.5
Hematocrit (%)	35	37.2	34	35
MCV (µm ³)	71	70.2	76	74
MCH (pg)	23	31.6	24	24
Leukocytes/mm ³	7,800	14,400	18,400	20,000
Band neutrophils (%)	24	63.8	4	4
Segmented neutrophils (%)	49		84	84
Eosinophils (%)	0	1.3	0	0
Lymphocytes (%)	23	26.9	8	10
Monocytes (%)	4	7.5	4	2
Platelets/mm ³	345,000	495,000	324,000	240,000
Creatinine (mg/dL)	0.8	0.8	1.2	1.8
Urea (mg/dL)	68	54	73	111
Sodium (mEq/L)	132		122	121
Potassium (mEq/L)	5.1		4.9	4.3
Chlorine (mEq/L)			79	101
Glucose (mg/dL)			94	71
Urine (EAS)				
Density	1015		1011	
pH	6.5		5	
Proteins (g/L)	0.62		0.29	
Leukocytes/mL	13,000		*	
Red blood cells/mL	11,000		Covered field	
Electrophoresis of blood proteins (g/dL)				
Total		7.4		
Albumin		3.5		2.8
Alpha-1 globulin		0.27		} 3.1
Alpha-2 globulin		0.7		
Beta globulin		0.91		
Gamma globulin		1.89		
Prothrombin time (INR)		1.41	1.61	2.42
APTT (time ratio)		1.24	1.14	1.09
Factor V activity (%)		74		
Fibrinogen (mg/dL)		383		
Amylase				1.693
AST (U/L)		44		105
Lactic dehydrogenase U/L			500	1680
Blood gas analysis			Mask 5L O ₂	Venous
pH			7.48	7.18
pCO ₂ (mmHg)			31	54
pO ₂ (mmHg)			68	50
O ₂ saturation (%)			93	74.6
HCO ₃ (mEq/L)			22.5	19.3
Base excess (mEq/L)			-0.2	-8.8

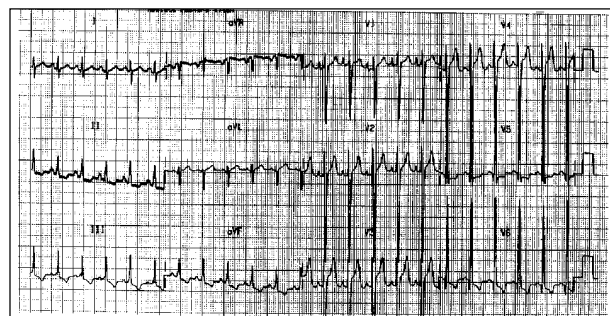


Fig. 1 – Electrocardiogram – hypertrophy of the right and left atria, and of the left ventricle.

required intravenous dobutamine (20µg/kg/min) and furosemide (160mg). Because she did not improve, the patient was referred to the intensive care unit.

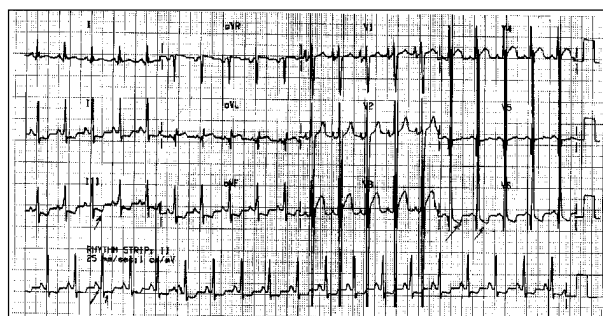


Fig. 2 - Electrocardiogram – reduction in the voltage of the QRS complex in the frontal plane, and left ventricular hypertrophy.

Pulmonary scintigraphy revealed a heterogeneous perfusion pattern, with hyperperfusion of the upper segment of the right lower lobe. During inhalation, a reduced uptake in the same area was also observed. Low probability of acute thromboembolism existed and the findings were compatible with a parenchymal process, which did not exclude the possibility of pulmonary infarction (fig. 3).

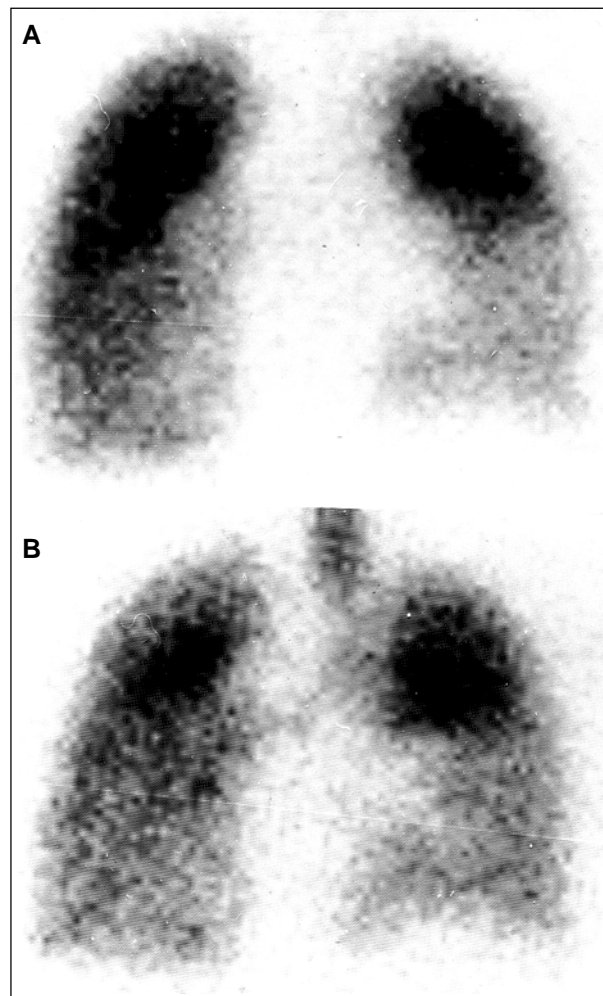


Fig. 3 - Pulmonary perfusion scintigraphy (fig. 3A) showing hypoperfusion in the right lung lower lobe similar to the pattern found in ventilation scan (fig. 3B), where hypoventilation of the same region may be seen.

Dynamic renal scintigraphy with ⁹⁹Tc-DTPA enhanced with furosemide showed low aortic flow with slightly decreased renal flow. The kidneys were enlarged, with bilateral dilation of the pyelocaliceal system. After the use of furosemide, an increase in excretion in the right kidney occurred, but no adequate response was observed in the left kidney. The differential renal (semiquantitative) function was 52% in the right kidney and 48% in the left kidney.

The abdominal ultrasound revealed a markedly enlarged liver. The gallbladder was not identified. The spleen was normal. The kidneys measured 10cm, had a normal corticomedullary ratio and parenchymal echogenicity, and showed signs of left pyelocaliceal duplication. The urinary bladder was normal.

The thorax radiography revealed apical infiltration in the right lower lobe.

The patient evolved with shock, requiring the administration of high doses of catecholamines. On the following day, she developed acute pulmonary edema with reduction in her consciousness level. The patient required orotracheal intubation. Hemofiltration was considered to reduce excessive blood volume, due to oliguria, but it was not performed because of hypotensive episodes. Leukocytosis persisted, being attributed to infection or to the inflammatory activity of arteritis. The patient received 500 mg of methylprednisolone.

Clinical deterioration was refractory to treatment, and the patient underwent a cardiopulmonary arrest preceded by bradycardia, which was reversed with resuscitation maneuvers. Sodium bicarbonate was administered because of marked metabolic acidosis (Tab. I). Shock persisted, as did the metabolic acidosis, despite the frequent corrections with NaHCO₃, and the patient died the following morning.

Discussion

Pulmonary perfusion and ventilation scintigraphy -

Pulmonary perfusion scintigraphy performed with macroaggregated albumin (MAA) labeled with technetium-99m showed hypoperfusion in the right inferior lobe (fig. 3A). The study of pulmonary ventilation (fig. 3B) was performed with an aerosol saline solution and diethylenetriamine pentaacetic acid (DTPA) labeled with technetium-99m and showed a radiopharmaceutical distribution pattern similar to that observed in the perfusion study (match pattern). This pattern is found in several pulmonary parenchymal processes, such as pneumonia, tumors, and pulmonary infarctions; however, it does not occur in acute embolism, except when the latter is accompanied by bronchospasm.

(Dr. Maria Clementina Pinto Giorgi)

Renogram – A relevant point in patients suspected of having Takayasu's arteritis is the time elapsed until the aorta is filled with contrast medium. In regard to our patient, this time was very long, suggesting marked obstruction to flow due to an aortic lesion.

(Dr. Dante M. A. Giorgi)

Clinical features – Takayasu's arteritis is a chronic inflammatory disease, probably with an autoimmune cause, involving medium- and large-caliber arteries, mainly the aorta and its branches in their proximal portions. The most commonly involved vessels are the subclavian arteries, followed by the aortic arch, the ascending aorta, the carotid arteries, and the femoral arteries. The pulmonary and coronary arteries may also be affected.

Women are most frequently affected in a proportion of 8:1, and the mean age at diagnosis is around 29 years. In ¾ of the patients, the diagnosis is established during adolescence.

An association of the disease and certain subtypes of HLA has been reported, even though its significance has not yet been clarified.

The lesions are purely stenotic in 85% of the cases, purely dilated in 2%, and mixed in 13%.

Morphological alterations are characterized by irregular thickening of the aortic wall with intimal wrinkling. When the aortic arch is affected, the orifices of the major arteries to the upper portion of the body may be markedly narrowed or even occluded, which is why it is referred to as a "pulseless disease."

In the acute phase, the symptoms may be unspecific, such as fever, anorexia, malaise, arthralgias, in addition to those related to ischemia in the area irrigated by the affected artery. Hypertension usually has a renovascular cause, complicating this disease in 50-60% of the cases. Congestive heart failure occurs in 28% of the patients, and results from hypertension, or, more rarely, from aortic regurgitation. Usually, death is caused by cerebral strokes or heart failure.

Our patient had already been diagnosed with Takayasu's arteritis, with renal involvement (renovascular hypertension) and marked left ventricular dysfunction. She sought emergency medical assistance with clinical findings suggestive of cardiac decompensation. During hospitalization, she experienced chest pain, hemoptysis, and worsening of the dyspnea and of the edema of the lower limbs. She evolved with refractory cardiogenic shock and death.

The clinical and laboratory findings of our patient suggest active disease. In some patients, involvement of the pulmonary artery may occur, leading to its occlusion and consequent pulmonary infarction¹⁻³. The presence of hemoptysis and dyspnea, in addition to hypoperfusion of the upper segment of the right lower lobe reinforce this idea. The previous ventricular dysfunction aggravated with the inflammatory activity and pulmonary infarction may have led to worsening of the ventricular function with refractory cardiogenic shock.

We cannot overlook the possibility of an associated infectious process, contributing to hemodynamic decompensation and death.

In some patients with Takayasu's arteritis, left ventricular dysfunction may be secondary to myocarditis⁴. The inflammatory involvement of the myocardium is associated with inflammatory laboratory signs and inflammatory arterial lesions. Diagnosis is made by myocardial biopsy and pulmonary and renal arterial impairment. A literature review

shows that myocarditis is a very rare condition confirmed only in a few cases on autopsy.

We should still consider the possibility of myocardial ischemia due to coronary artery involvement, which may occur in as many as 10% of the patients with Takayasu's arteritis.

(Dr. Fábio Gazelato de Mello Franco)

Diagnostic hypothesis – Active Takayasu's arteritis, pulmonary thromboembolism, ventricular dysfunction aggravated by pulmonary embolism, and, less probably, myocardial ischemia.

(Dr. Fábio Gazelato de Mello Franco)

Autopsy

The major alterations on postmortem examination were found in the aorta, whose wall was very thickened from its beginning down to its abdominal portion, below the emergence of the renal arteries. Even though diffuse, the involvement was not regular; therefore, areas of important narrowing of the arterial lumen and other more preserved areas existed. The histologic sections showed chronic aortitis (fig. 4), with destruction of the elastic fibers (fig. 5). The search for bacteria and fungi was negative. The diagnosis of Takayasu's arteritis was established.

The branches of the aortic arch and the renal arteries were markedly compromised. The patient had undergone surgical renal revascularization because of the involvement of the renal arteries; the grafts were partially obstructed, and renal cortical necrosis existed. Signs of congestive heart failure were also present, with chronic passive congestion of the lungs and liver, and thromboembolism with infarct in the middle and upper lobes of the right lung, with no inflammatory lesions in the pulmonary arterial tree. Finally, systemic signs of shock were present, such as centrilobular hepatic necrosis and pancreatic

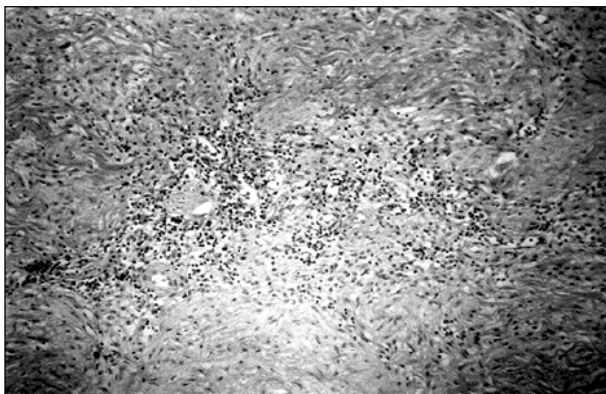


Fig. 4 – Histological section of the middle layer of the aorta. Note the dense and diffuse inflammatory infiltrate with mononuclear cells. The elastic fibers present in the middle layer stain in black and are partially destroyed and fragmented (HE, 16x magnification).

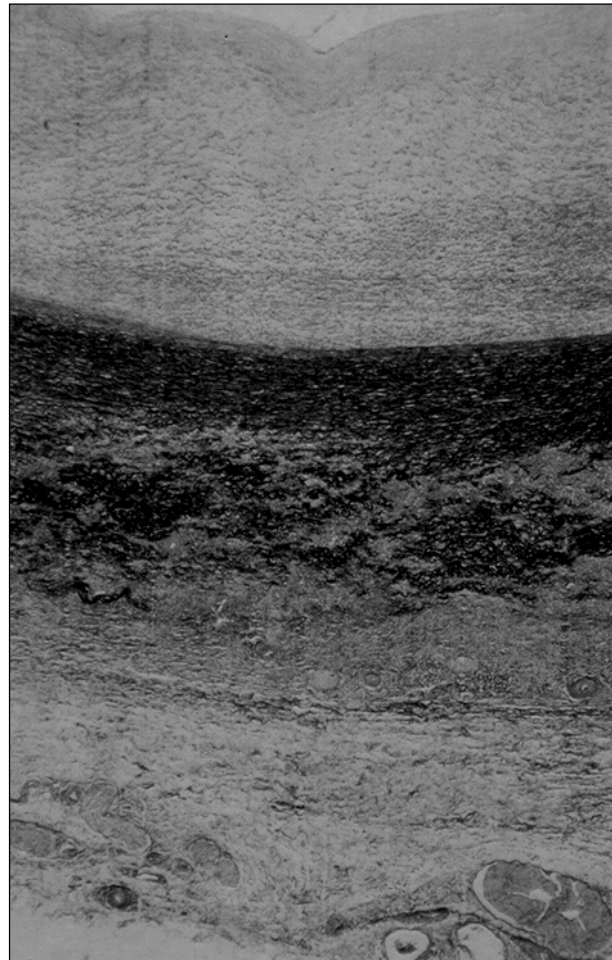


Fig. 5 – Histological section of the aorta stained according to the Movat's technique. The elastic fibers present in the middle layer stain in black and are partially destroyed and fragmented (2.5x magnification).

steatonecrosis. Multisystem organ failure was considered the cause of death.

Even though occurring in an age bracket a little lower than the usual, this patient's disease was well characterized as Takayasu's arteritis, from both the clinical and morphological points of view.

The final part of the patient's evolution was not very well understood while she was still alive. Myocardial infarction was suspected, but it was not confirmed on autopsy, which revealed the existence of another factor, pulmonary thromboembolism, which triggered the patient's decompensation.

The factors that might account for heart failure as a complication of Takayasu's arteritis⁵⁻⁷ are the following: impairment of the cardiac muscle, caused either by cardiomyopathy, reported in some patients, or by myocardial infarction secondary to inflammation of the coronary arteries; valvar or supra-valvar aortic stenosis; and decompensation of systemic arterial hypertension or hypervolemia, or both, when the renal arteries are involved. In the present case, because the coronary arteries and the myocardium were

preserved, a combination of the remaining causes should have accounted for the functional alteration. It is worth noting that, even though all above-cited factors, isolated or in association, may have been involved in the pathogenesis of heart failure, this disorder appears most of the time in hypertensive patients, and with a greater incidence in younger patients. In a study carried out in Mexico with 12 children, hypertension was found in 11 patients and dyspnea on exertion in 9⁵. Talwar et al⁶ detected the disorder in 17 out of

31 individuals with Takayasu's arteritis and heart failure below the age of 15 years.

(Dr. Paulo Sampaio Gutierrez)

Pathological diagnoses – Takayasu's arteritis and pulmonary infarct due to thromboembolism.

(Dr. Paulo Sampaio Gutierrez)

References

1. Bletry O. Severe pulmonary artery involvement of Takayasu arteritis. 3 cases and review of the literature. Arch Mal Coeur Vaiss 1991; 84: 817-22.
2. Nunes H. Pulmonary artery involvement in Takayasu arteritis. A case of right ventricular failure as presentation form. Rev Port Cardiol 1992; 11: 775-80.
3. Lupi E. Pulmonary artery involvement in Takayasu's arteritis. Chest 1975; 67: 69-74.
4. Gay J. Myocardopathy and Takayasu's disease. Apropos of a case. Ann Cardiol Angeiol (Paris) 1985; 34: 489-92.
5. Lupi Herrera E, Contreras R, Vela JE, Torres GS, Horwitz S. Arteritis inespecifica en la niñez. Observaciones clinicas y anatomopatologicas. Arch Inst Cardiol Mex 1972; 42: 477-93.
6. Talwar KK, Kumar K, Chopra P, et al. Cardiac involvement in nonspecific aortoarteritis (Takayasu's arteritis). Am Heart J 1991; 122: 1666-70.
7. Panja M, Kar AK, Dutta AL, Chhetri M, Kumar S, Panja S. Cardiac involvement in non-specific aorto-arteritis. Int J Cardiol 1992; 34: 289-95.



Ouro Preto - MG

Patrícia M. Cury - SP