

Myocardial Involvement in Sweet Syndrome: A Rare Finding in a Rare Condition

Luís Graça-Santos,¹ Katarina Kieselova,² Fernando Montenegro-Sá,¹ Joana Guardado,² João Morais²

Department of Cardiology, Leiria Hospital Centre,¹ Leiria - Portugal

Department of Dermatology, Leiria Hospital Centre,² Leiria - Portugal

Introduction

Sweet Syndrome is an acute febrile neutrophilic dermatosis characterized by an association of fever, neutrophilia, tender erythematous skin lesions (papules, nodules, and plaques), as well as pathologic findings consisting predominantly of mature neutrophils typically located in the upper dermis.¹ It is a rare condition with a worldwide distribution which can present as one of three main clinical types: idiopathic, malignancy-associated, or drug-induced.¹⁻³ Extracutaneous manifestations may occur but cardiovascular involvement is extremely rare.^{1,2}

Case presentation

A previously healthy 41-year-old male presents to the emergency department with a 48-hour history of mild fever and worsening widespread skin lesions. He denied recent drug intake, known allergies, relevant personal or familial diseases, as well as suspicious epidemiological context.

The patient was febrile (38.3°C) and heart rate, blood pressure, and oxygen saturation were all normal. The chest and abdominal examination were both unremarkable. Skin examination revealed painful pseudovesiculate, erythematous papules, and plaques on the nape, neck, shoulders, and arms, as well as painful hyperpigmented subcutaneous nodules (*erythema nodosum*-like) on the legs (Figure 1). Blood tests showed slight leucocytosis (10800/uL) with 81.4% of neutrophils, erythrocyte sedimentation rate was 89mm/h (normal value (NV) <10) and C-reactive protein (CRP) 128.5mg/L (NV<5.0). Electrolytes, renal and hepatic profiles were normal.

A few hours later, the patient complained of transient chest discomfort at rest. The electrocardiogram showed sinus rhythm at 58 per minute with first-degree atrioventricular block plus incomplete right bundle branch block. Troponin I (TnI) was 1.89ng/mL (NV<0.05) and raised up to 10.82ng/mL six hours later. The repeated electrocardiogram was identical to the previous one. Transthoracic echocardiogram (TTE) was

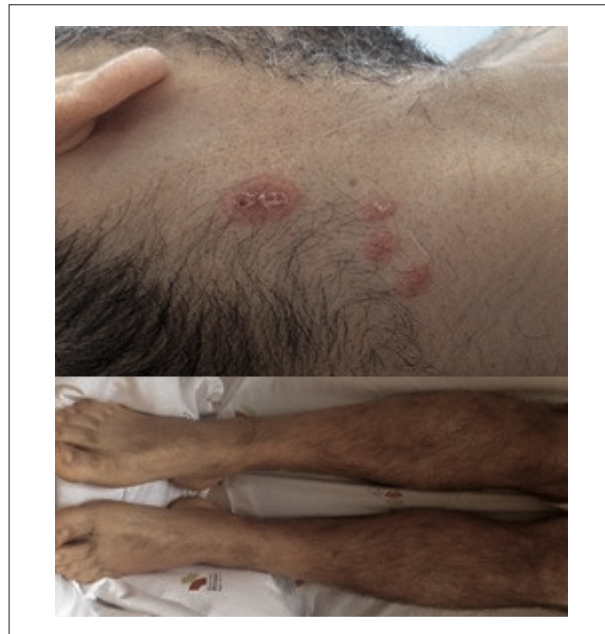

Figure 1 – Skin examination. Pseudovesiculate, erythematous papules and plaques on the nape (top); hyperpigmented subcutaneous nodules on the legs (bottom).

normal, demonstrating preserved left ventricular ejection fraction (LVEF; 53% Simpson's biplane method) with no major wall motion abnormalities. However, global longitudinal peak systolic strain (GLPSS) was reduced, especially at the expense of the mid-basal segments being the apex relatively spared (Figure 2.A). Coronary angiogram excluded obstructive coronary artery disease (CAD).

The patient was admitted to the internal medicine ward with the presumptive diagnosis of acute febrile neutrophilic dermatosis. On the second day (D2), skin biopsy was performed and oral prednisolone (PDN) 1mg/Kg/day was initiated, taking into consideration the persistence of both fever and skin lesions as well as the increase of the CRP value (242mg/L). Despite no chest discomfort relapse, TnI reached a peak level of 15.01ng/mL on D2. After initiating PDN, the patient remained afebrile, and both systemic inflammatory and myocardial injury biomarkers started to decrease. Complementary laboratorial tests (such as electrophoretic proteinogram, autoimmunity screening, thyroid hormones, blood cultures and serology tests) were normal. The histological skin analysis revealed subepithelial oedema, dermal inflammatory infiltrate with polymorphonuclear predominance and absence of vasculitis (Figure 3). Based on this information, diagnostic criteria

Keywords

Sweet Syndrome/physiopathology; Erythema Multiforme; Neutrophils; Myocarditis; Adrenal Cortex Hormones/therapeutic use.

Mailing Address: Luís Graça Santos •

Leiria Hospital Centre - Rua Santo Andre Pousos. 2410-196, Leiria – Portugal

E-mail: luismscp1@gmail.com

Manuscript received April 13, 2019, revised manuscript July 27, 2019, accepted August 18, 2019.

DOI: <https://doi.org/10.36660/abc.20190249>

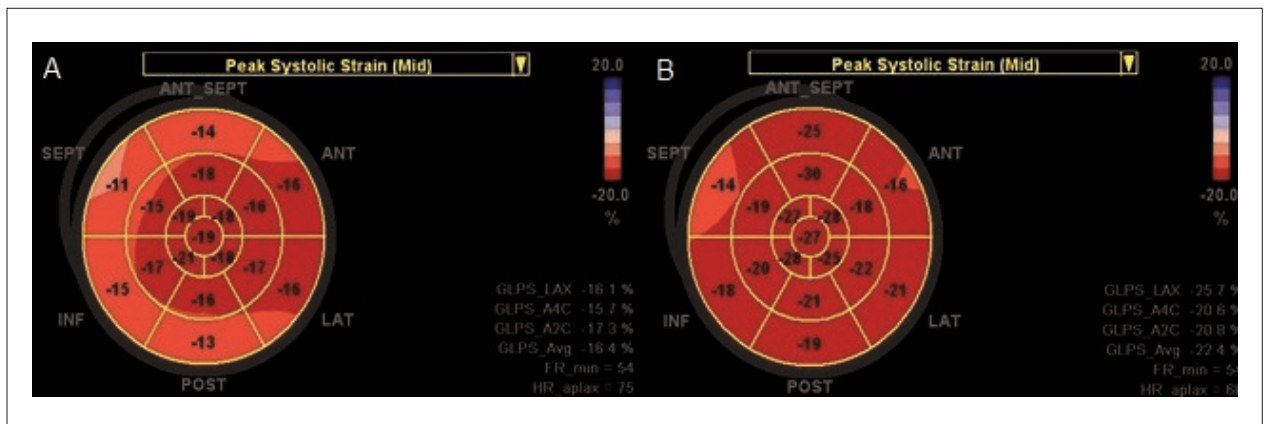


Figure 2 – Global and segmental longitudinal strain analysis; “bull-eye” plot (General Electric®). (A) Global strain is reduced (-16.4%) at admission; (B) and normalized (-22.4%) three months after corticosteroid treatment.

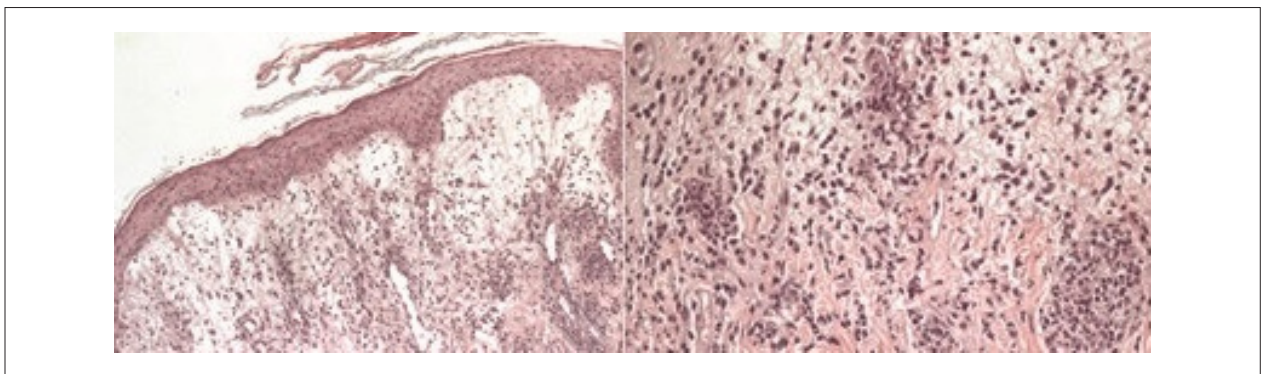


Figure 3 – Histology of the cervical skin lesion (haematoxylin-eosin stain). Predominant neutrophilic dermal infiltrate and oedema (left). Zoom over the dermal area showing some lymphocytes, histiocytes, and absence of vasculitis (right).

were fulfilled for SS³ and a high likelihood for cardiovascular involvement presenting as acute myocarditis (AM)³ was considered. On D9, there had been no fever relapse, skin lesions were mostly healed, and CRP and TnI levels almost normalized (9.9mg/L and 0.32ng/dL respectively). The patient was discharged on a tapering corticosteroid regimen.

Four days later, the patient presented completely asymptomatic with no skin lesions and both systemic inflammatory and myocardial injury biomarkers have normalized. A cardiovascular magnetic resonance (CMR) was scheduled six days after discharge and showed findings suggestive of myocarditis (Figure 4). Both LVEF and GLPSS improved up to 63% and -22.4%, respectively, three months after the initial assessment (Figure 2.B). The patient did not wish to undergo a second CMR study.

During a two-year follow-up, the patient remained completely asymptomatic with no signs or symptoms of cardiovascular or malignant disease.

Discussion

We present a case where the diagnosis of SS was established as two major and three minor Driesch criteria were identified.⁴

The idiopathic type was assumed since no recent drug intake was reported and no signs of malignant disease were present. Extracutaneous manifestations may occur, particularly in association with malignancy.^{1,2} Cardiovascular involvement is extremely rare and up to this date, only two cases of myocarditis have been reported in the idiopathic type, to our best knowledge.^{2,5,6} Both manifestations typically respond well to corticosteroids.¹

In this patient, the presence of transient chest discomfort associated with TnI elevation raised the suspicion of cardiovascular involvement. Both AM and acute myocardial infarction have been previously described as cardiovascular manifestations.² Coronary angiogram remains the gold standard for the diagnosis of CAD⁷ or for its exclusion in case of suspected AM⁸ and was normal in this case. There is some evidence that two-dimensional speckle tracking echocardiography (2D-STE) may help support the diagnosis of AM since GLPSS correlates with the presence of fibrosis and oedema on CMR and with lymphocytic infiltrates on endomyocardial biopsy (EMB).⁹⁻¹² In our case, the presence of GLPSS reduction mainly at the expense of the mid-basal segments, instead of the mid-apical segments (typical

Case Report

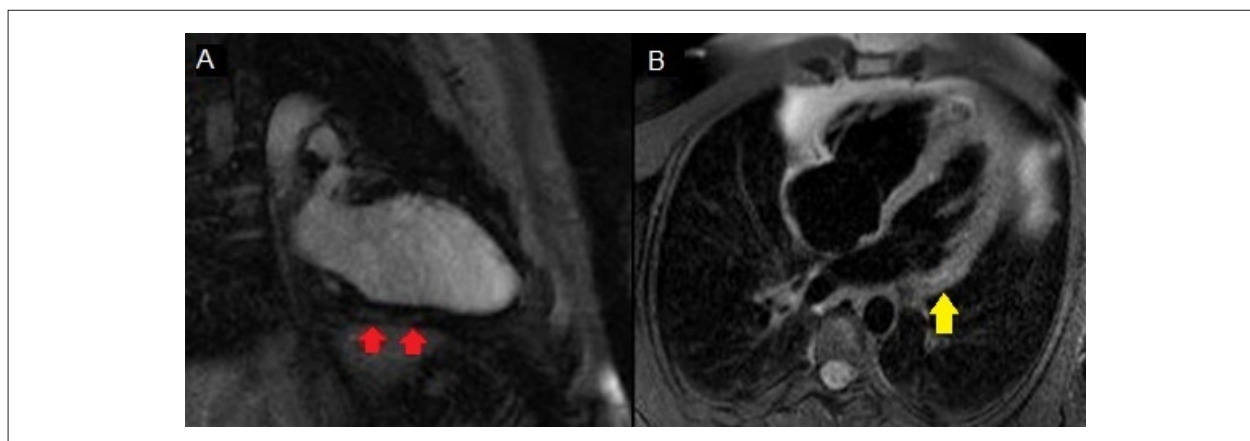


Figure 4 – Cardiovascular magnetic resonance imaging. (A) T1-weighted image demonstrating patchy subepicardial late gadolinium enhancement (red arrows) in the basal portion of the inferior wall; (B) T2-weighted image presenting focal regions of increased signal intensity (yellow arrow) suggestive of slight oedema in the inferolateral wall.

pattern of significant CAD),¹³ and the prompt response to corticosteroids raised the likelihood of AM. Due to clinical stability and the well-known limitations of EMB, a CMR was later performed and suggested this diagnosis according to the Lake-Louise criteria.^{8,12} In fact, CMR has emerged as a useful non-invasive diagnostic tool and there is growing evidence that novel techniques, such as T1 and T2 mapping, may improve its diagnostic accuracy for myocarditis and help monitor disease evolution.^{8,14,15} Additionally, GLPSS normalized three months after treatment, while the patient remained asymptomatic.

Final messages

The case we present emphasizes the importance of acknowledging SS as a rare yet plausible cause of cardiovascular disease, and one that should be early recognized in order to start adequate treatment.

In this case, the diagnosis of AM was highly suggested by the combination of non-invasive imaging modalities after CAD exclusion. To our best knowledge, this was the first time CMR was used to assess myocardial involvement in a patient with SS and also the first to report the use of 2D-STE for evolution

monitoring. Both cutaneous and cardiovascular manifestations completely regressed after corticosteroid treatment.

Author contributions

Conception and design of the research and Data acquisition: Santos LG, Kieselova K; Analysis and interpretation of the data: Santos LG, Kieselova K, Sá FM, Guardado J; Writing of the manuscript: Santos LG, Sá FM, Morais JA; Critical revision of the manuscript for intellectual content: Guardado J, Morais JA.

Potential Conflict of Interest

The authors report no conflict of interest concerning the materials and methods used in this study or the findings specified in this paper.

Sources of Funding

There was no external funding source for this study.

Study Association

This study is not associated with any thesis or dissertation.

References

1. Cohen PR. Sweet's syndrome - a comprehensive review of an acute febrile neutrophilic dermatosis. *Orphanet J Rare Dis.* 2007 Jul 26;2:34.
2. Villarreal-Villarreal CD, Ocampo-Candiani J, Villarreal-Martínez A. Sweet Syndrome: A Review and Update. *Actas Dermosifiliogr.* 2015;107(5):369-78.
3. Cohen PR, Kurzrock R. Sweet's syndrome revisited: a review of disease concepts. *Int J Dermatol.* 2003;42(10):761-78.
4. Von den Driesch P. Sweet's syndrome (acute febrile neutrophilic dermatosis). *J Am Acad Dermatol.* 1994;31(4):535-56.
5. Dorenkamp M, Weikert U, Meyer R, Schwimbeck PL, Morguet AJ. Heart failure in acute febrile neutrophilic dermatosis. *Lancet.* 2003;362(9393):1374.
6. Yu WY, Manriquez E, Bhutani T, Chaganti RK, Ruben BS, Schwartz BS, et al. Sweet heart: A case of pregnancy-associated acute febrile neutrophilic dermatosis with myopericarditis. *JAAD Case Rep.* 2014;1(1):12-4.
7. Montalescot G, Sechtem U, Achenbach S, Sechtem U, Andreotti F, Arden C, et al. 2013 ESC guidelines on the management of stable coronary artery disease: the Task Force on the management of stable coronary artery disease of the European Society of Cardiology. *Eur Heart J.* 2013;34(38):2949-3003.
8. Caforio AL, Pankuweit S, Arbustini E, Basso C, Gimeno-Blanes J, Felix SB, et al. Current state of knowledge on aetiology, diagnosis, management, and therapy of myocarditis: a position statement of the European Society of Cardiology Working Group on Myocardial and Pericardial Diseases. *Eur Heart J.* 2013;34(33):2636-48.

9. Leitman M, Vered Z, Tyomkin V, Macogon B, Peleg E, Copel L. Speckle tracking imaging in inflammatory heart diseases. *Int J Cardiovasc Imaging*. 2018;34(5):787-92.
10. Kostakou PM, Kostopoulos VS, Tryfou ES, Giannaris VD, Rodis IE, Olympios CD, et al. Subclinical left ventricular dysfunction and correlation with regional strain analysis in myocarditis with normal ejection fraction. A new diagnostic criterion. *Int J Cardiol*. 2018;259:116-21.
11. Løgstrup BB, Nielsen JM, Kim WY, Poulsen SH. Myocardial oedema in acute myocarditis detected by echocardiographic 2D myocardial deformation analysis. *Eur Heart J Cardiovasc Imaging*. 2016;17(9):1018-26.
12. Escher F, Kasner M, Kühl U, Heymer J, Wilkeshoff U, Tschöpe C, et al. New echocardiographic findings correlate with intramyocardial inflammation in endomyocardial biopsies of patients with acute myocarditis and inflammatory cardiomyopathy. *Mediators Inflamm*. 2013;2013:875420.
13. Carstensen HC, Larsen LH, Hassager C, Kofoed KF, Jensen JS, Mogelvang R. Association of ischemic heart disease to global and regional longitudinal strain in asymptomatic aortic stenosis. *Int J Cardiovasc Imaging*. 2015;31(3):485-95.
14. André F, Stock FT, Riffel J, Giannitsis E, Steen H, Scharhag J, et al. Incremental value of cardiac deformation analysis in acute myocarditis: a cardiovascular magnetic resonance imaging study. *Int J Cardiovasc Imaging*. 2016;32(7):1093-101.
15. Roller FC, Harth S, Schneider C, Krombach GA. T1, T2 Mapping and Extracellular Volume Fraction (ECV): Application, Value and Further Perspectives in Myocardial Inflammation and Cardiomyopathies. *Rofo*. 2015 Sep;187(9):760-70.

