

## Primary Percutaneous Coronary Intervention through Transulnar Approach: Safety and Effectiveness

Pedro Beraldo de Andrade<sup>1,2</sup>, Marden André Tebet<sup>1,2</sup>, Mônica Vieira Athanazio de Andrade<sup>1</sup>, André Labrunie<sup>1,2</sup>, Luiz Alberto Piva e Mattos<sup>1,3</sup>

Irmãdade da Santa Casa de Misericórdia de Marília, Marília, SP<sup>1</sup>; Hospital do Coração de Londrina, Londrina, PR<sup>2</sup>; Instituto Dante Pazzanese de Cardiologia, São Paulo, SP<sup>3</sup> - Brazil

The transradial approach is safe and effective for coronary procedures. However, its use may be compromised in cases of variations in radial artery anatomy, spasms, and negative Allen's test. The transulnar approach emerges as a viable alternative to transradial approach. We report on a patient who underwent primary angioplasty via ulnar artery without ischemic hand complications despite prior occlusion of the ipsilateral radial artery.

### Introduction

The safety and effectiveness of the transradial approach for coronary interventions are well established. This route has been proven to reduce vascular complications at the puncture site, costs, and length of hospital stay, in addition to providing greater comfort for patients and allowing early ambulation, as compared with femoral and brachial approaches<sup>1,2</sup>. Nevertheless, some factors such as anatomic variations of the radial artery, vasospasm, and inadequate blood supply to the hand via the palmar arch may limit its use<sup>3</sup>.

Since the transulnar approach was first reported by Terashima et al<sup>4</sup> in 2001, the ulnar artery has been shown to be an alternative approach when the radial artery cannot be used. We report on a patient with angiographically documented occlusion of the right radial artery who underwent primary angioplasty through the right ulnar artery.

### Case Report

A 63-year old male patient with diabetes mellitus, dyslipidemia, and a three-year history of acute myocardial infarction of the lateral wall underwent primary angioplasty with stenting of the first diagonal artery. In September 2007, he was referred for coronary angiography for investigation of typical, severe chest pain of four hour's duration accompanied by cold sweat and pallor.

### Key Words

Primary percutaneous coronary intervention; transradial approach; transulnar approach.

#### Mailing Address: Pedro Beraldo de Andrade •

Avenida Vicente Ferreira, 828 - Cascata - 17515-900, Marília - São Paulo, SP - Brazil

E-mail: pedroberaldo@gmail.com

Manuscript received December 18, 2007; revised manuscript received January 18, 2008; accepted January 25, 2008

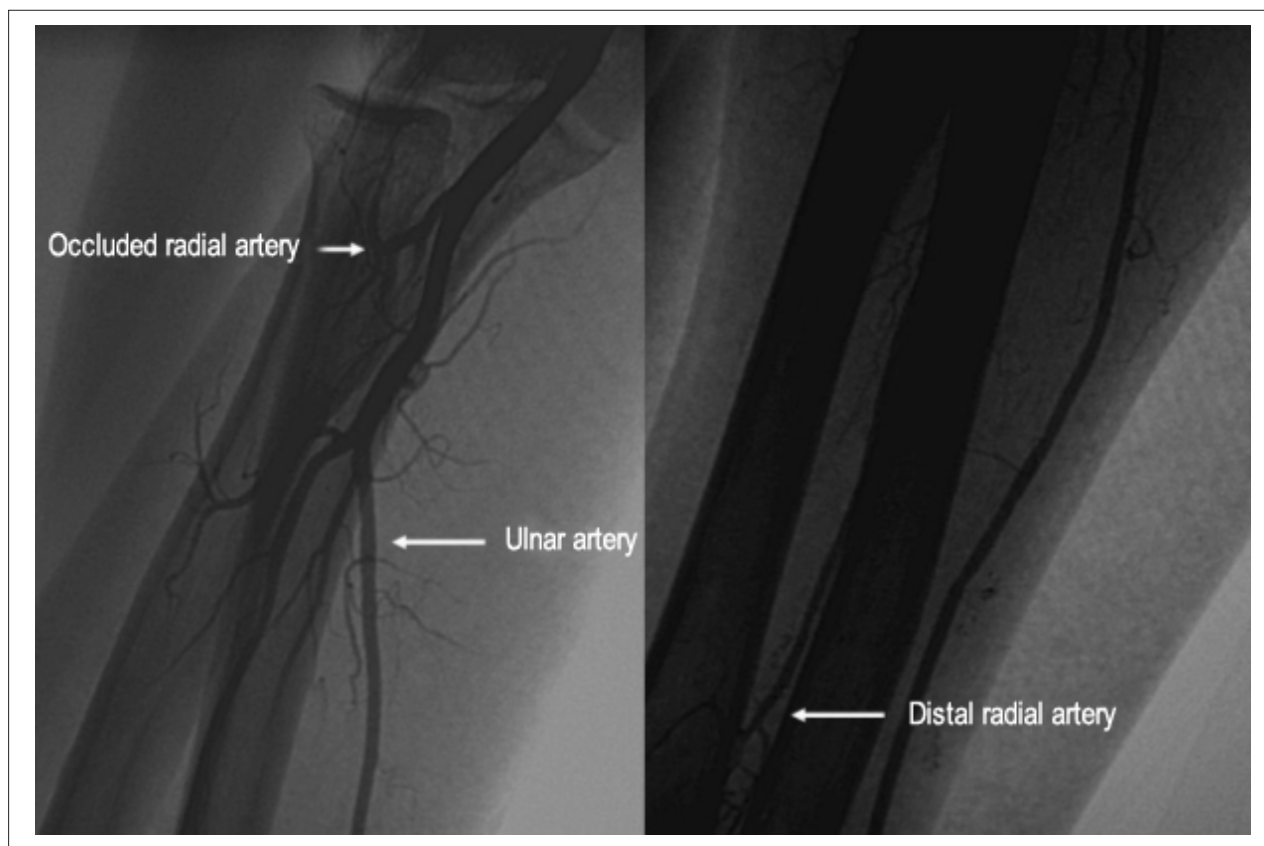
On physical examination he was normotensive but tachycardic. Auscultation of the lungs and heart was unremarkable. The right radial pulse was absent, but the others were palpable and symmetric. The electrocardiogram showed ST segment elevation of 2 mm in leads II, III, and aVf.

With a history of three prior procedures performed using the right radial approach, this artery was occluded (figure 1). However, physical examination revealed a 3+/4+ ulnar pulse, with a positive reverse Allen's test, suggesting adequate blood flow through the deep palmar arch. The right transulnar approach was then chosen.

With the wrist hyperextended, the ulnar artery was punctured 1 cm proximal to the pisiform bone, using a needle with a 20-gauge Jelco polyethylene catheter. Subsequently, a 0.021-inch guidewire was advanced, followed by a small skin incision performed with a No. 11 scalpel, through which a short 6-French (10 cm) introducer sheath (Terumo Corporation, Tokyo, Japan) was inserted. A solution containing 5000 IU of heparin and 10 mg of isosorbide mononitrate was injected through the introducer sheath.

There was a stent in the 1st diagonal branch of the left coronary artery, which was patent. The right coronary artery was 90% blocked in its distal third, involving the origin of the posterior descending branch, with ostial occlusion of the posterior interventricular artery. Mechanical recanalization was performed under intravenous infusion of tirofiban (a bolus of 25µg/kg/min followed by 0.15µg/kg/min for 12 hours), unfractionated heparin 100 U/kg, ASA 300 mg, and a 300-mg clopidogrel loading dose, with implantation of a 3.0x20 mm Liberté stent (Boston Scientific, Massachusetts, USA) in the distal third of the right coronary artery and ostium of the posterior descending artery. As the result achieved in the ostium of the posterior interventricular artery was suboptimal (TIMI-1 flow), an additional Liberté stent (2,75x12mm) was implanted using the T-stenting technique with final kissing balloon inflation. The final result was satisfactory (Figure 2), with TIMI-3 flow, total pain relief, and resolution of ST-segment elevation. Despite the long procedure time (120 minutes, 34 minutes under fluoroscopy), there was only a mild spasm at the puncture site, but the patient experienced no pain. Once the procedure ended, the introducer sheath was removed and hemostasis was achieved by using a compressive dressing with a porous elastic adhesive bandage (Tensoplast®) during 4 hours.

Seventy two hours after admission, a transthoracic



**Figura 1 - Occlusion of the right radial artery with distal reconstitution by collateral circulation.**

Doppler echocardiogram showed mild hypokinesis of the left ventricular inferolateral wall, with preserved ejection fraction, allowing early hospital discharge. The examination of the wrist revealed a 3+/4+ ulnar artery pulse, positive modified and reverse Allen's tests, and absence of hematoma, murmur, or thrill. In a follow-up telephone interview 30 days later, the patient remained asymptomatic, with no changes or complaints related to the puncture site.

## Discussion

The ulnar artery is the largest and least tortuous branch of the brachial artery, which makes it less prone to spasms<sup>5</sup>. However, it is deeper and therefore less palpable than the radial artery. In addition, since the ulnar artery runs parallel to the corresponding nerve and vein, its use has not been favored for percutaneous interventions. As the transradial technique has become more widely accepted, many institutions that perform it routinely are faced with the need to switch to the transfemoral approach in circumstances in which the radial artery cannot be used.

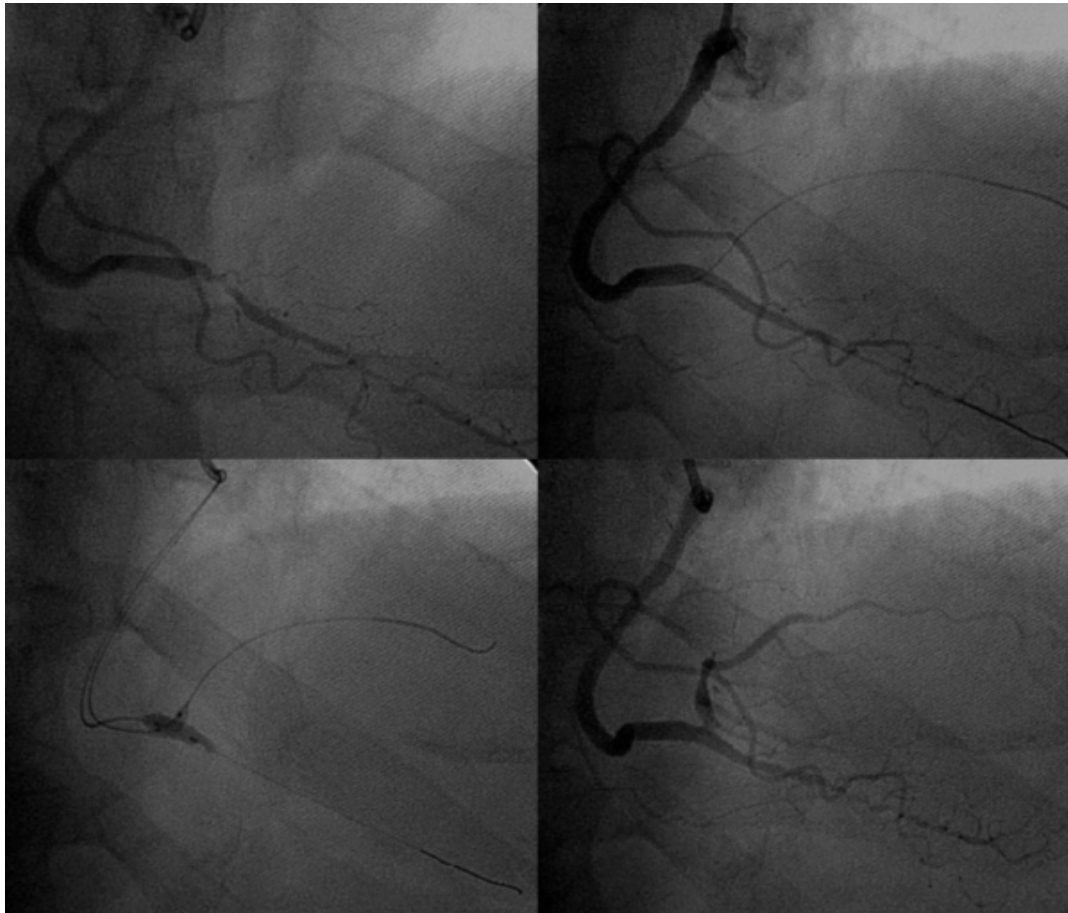Case series with varying number of patients<sup>4,5-7</sup> followed-up with ultrasound examinations, the largest of which involved 172 patients<sup>8</sup>, have shown that the transulnar approach is an additional option when the radial artery access is not available. This technique is associated with low incidence of major vascular complications: hematomas are usually minor, affecting only subcutaneous tissue, the ulnar nerve is not

injured, asymptomatic occlusion of the ulnar artery is less than 5%, there is no hand ischemia, and cases of arteriovenous fistula and pseudoaneurysm are rare. Similar findings were reported for transulnar primary angioplasty<sup>9</sup>. In a randomized study comparing both routes in patients undergoing coronary angioplasty, no differences were found regarding access-related complications, success rate, procedure time, and fluoroscopy time<sup>10</sup>.

Therefore, the use of the transulnar approach emerges as a safe and feasible alternative for coronary interventions. We report on a patient with right radial artery blockade caused by multiple previous interventions, but with distal filling of the artery by a wide range of collaterals, providing adequate blood supply through the deep palmar arch, as verified by a clearly positive reverse Allen's test. The right ulnar artery was then used as an access route, without any ischemic or hemorrhagic complications, despite prolonged manipulation, long procedure time, aggressive antithrombotic therapy, and the use of a 6-French sheath, providing greater comfort for both the patient during the recovery period and medical team during the intervention.

Lanspa et al<sup>6</sup> reported a similar case of coronary angiography via the ulnar artery with occlusion of the ipsilateral radial artery without procedure-related complications. However, it was a diagnostic coronary angiography lasting 10 minutes and using a 5-French introducer.

## Case Report



**Figure 2 - Successful primary angioplasty.**

Although most published studies were not randomized trials but rather case reports, the available evidence suggests that the transulnar approach is feasible, effective, and probably as safe as the transradial approach for coronary interventions. It is an attractive option for institutions that use the radial approach routinely, when performed by experienced operators who are skilled in this technique, particularly in cases of anatomic variations of the radial artery, thin radial pulse, vasospasm, and negative modified Allen test.

## References

1. Kiemeneij F, Laarman GJ, Odekerken D, Slagboom T, van der Wieken R. A randomized comparison of percutaneous transluminal coronary angioplasty by the radial, brachial and femoral approaches: the ACCESS study. *J Am Coll Cardiol.* 1997; 29: 1269-75.
2. Louvard Y, Lefevre T, Allain A, Morice M. Coronary angiography through the radial or the femoral approach: the CARAFE study. *Cathet Cardiovasc Interv.* 2001; 52: 181-7.
3. Valsecchi O, Vassileva A, Musumeci C, Rossini R, Tespili M, Guagliumi G, et al. Failure of transradial approach during coronary interventions: anatomic

## Potential Conflict of Interest

No potential conflict of interest relevant to this article was reported.

## Sources of Funding

There were no external funding sources for this study.

## Study Association

This study is not associated with any graduation program.

considerations. *Cathet Cardiovasc Interv.* 2006; 67: 870-8.

4. Terashima M, Meguro T, Takeda H, Endoh N. Percutaneous ulnar artery approach for coronary angiography: a preliminary report in nine patients. *Cathet Cardiovasc Interv.* 2001; 53: 410-4.
5. Dashkoff N, Dashkoff PB, Zizzi JA, Wadhvani J. Ulnar artery cannulation for coronary angiography and percutaneous coronary intervention: case reports and anatomic considerations. *Cathet Cardiovasc Interv.* 2002; 55: 93-6.
6. Lanspa TJ, Reyes AP, Oldemeyer JB, Williams MA. Ulnar artery catheterization

- with occlusion of corresponding radial artery. *Cathet Cardiovasc Interv.* 2004; 61: 211-3.
7. Mangin L, Bertrand OF, De La Rochelière R, Proulx G, Lemay R, Barbeau G, et al. The transulnar approach for coronary intervention: a safe alternative to transradial approach in selected patients. *J Invasive Cardiol.* 2005; 17: 77-9.
  8. Aptecar E, Dupouy P, Chabane-Chaouch M, Bussy N, Catarino G, Shahmir A, et al. Percutaneous transulnar artery approach for diagnostic and therapeutic coronary intervention. *J Invasive Cardiol.* 2005; 17: 312-7.
  9. Limbruno U, Rossini R, De Carlo M, Amoroso G, Ciabatti N, Petronio AS, et al. Percutaneous ulnar artery approach for primary coronary angioplasty: safety and feasibility. *Cathet Cardiovasc Interv.* 2004; 61: 56-9.
  10. Aptecar E, Pernes JM, Chabane-Chaouch M, Bussy N, Catarino G, Shahmir A, et al. Transulnar versus transradial artery approach for coronary angioplasty: the PCVI-CUBA Study. *Cathet Cardiovasc Interv.* 2006; 67: 711-20.