

## Late Spontaneous Regression of Obstructive Tumor in the Mitral Valve

Edmar Atik

InCor-FMUSP, São Paulo, SP – Brazil

Cardiac rhabdomyoma is uncommonly found in the mitral valve. However, in the case reported, although the tumor was large (15x14 mm) and even caused obstruction at this level in the first months of life, its complete and spontaneous regression was observed as from 68 months of age, with progressive reduction until the patient was 14 years old.

### Introduction

Among the cardiac tumors, complete and spontaneous regression is observed in rhabdomyomas in 54% to 100% of the cases<sup>1-7</sup>, even in those causing blood flow obstruction. This phenomenon occurs especially throughout the first year, extending up to 5 years of age<sup>5</sup>.

Less frequently, however, this tumor affects fibrous structures of the heart, with onset later in life, beyond 10 years of age<sup>6,7</sup>. This is why a case of late spontaneous regression of obstructive rhabdomyoma in mitral valve at 14 years of age is worth reporting.

### Case report

A male infant presented with dyspnea with feeding since birth. The symptom improved with diuretics and the patient became asymptomatic as from nine months of age. At two years of age, the patient began to experience repeated episodes of transitory paroxysmal supraventricular tachycardia, which were controlled with the use of amiodarone until 11 years of age, when regression of the electrical signals of the Wolf-Parkinson-White syndrome through the left lateral bundle branch was observed.

Today, the patient is 14 years old and his physical and mental activities are unrestricted; his physical examination is normal. The previous presence of a mild systolic murmur on the left sternal border and mitral area in the first months of life, with normal heart sounds and no signs of heart failure is worth mentioning.

Usual ancillary tests (ECG and chest radiography) show no abnormalities. The mild heart enlargement due to increased left atrium observed when the patient was an infant resolved with time. The baseline echocardiogram performed at 2 months of age, and those repeated at 6, 9, 12, 18 and 28

months, showed a hyperechoic mass in the atrial side of the anterior mitral leaflet, measuring 15x14mm. At 68 months and 8 years of age, the mass had decreased to 14x11 mm and 12x10 mm, respectively, and completely disappeared in the last echocardiogram performed at 14 years of age (Figures 1 and 2). In the last echocardiogram, a slightly thicker than usual mitral valve could be observed. Two other masses could be seen, one of them in the right portion of the interventricular septum, initially measuring 17x11 mm, and currently measuring 13x9 mm, and the other one in the anterior papillary muscle of the left ventricle, measuring 9x6 mm, which became too small with time.

The diagnosis of rhabdomyoma in the case reported was not histologically confirmed, but was presumed in light of the presence of known evidences, in particular the occurrence of other tumor masses in the right and left ventricles and the observation of their progressive regression, especially of those located in the mitral valve and in the left papillary muscle.

### Discussion

The mechanism through which rhabdomyomas resolve is unknown<sup>5</sup>, although this is frequently observed. This phenomenon is estimated to occur in 54% to 100% of the cases, even in larger tumors<sup>1-7</sup>. Thus, complete resolution was observed in 20 out of 24 rhabdomyomas studied in a 20-year follow-up period since the diagnosis made in infants up to 8 months old according to Smythe et al<sup>3</sup>, and in 31 out of 33 cases studied by Bosi et al<sup>2</sup>. Regression is observed up to the age of 5 to 6 years<sup>6,7</sup>.

This fact makes the indication of surgical resection of these tumors unnecessary, except in life-threatening situations, as in the case of inflow tract obstruction and, mainly, ventricular outflow tract obstruction<sup>8,9</sup>. Thus, surgical correction is not indicated in all rhabdomyomas thanks to their benign outcome, as demonstrated by the spontaneous tumor regression, and because no other types of risks such as dysrhythmias or heart failure are involved. As such, surgical resection of rhabdomyoma was necessary in only 9 out of 56 of these tumors according to Beghetti et al<sup>1</sup>; in 2 out of 33 cases reported by Bosi et al<sup>2</sup>; and in 1 out of 9 cases described by Smythe et al<sup>3</sup>. It has been observed that most of the obstructive rhabdomyomas found in neonates and infants are also subject to regression, and this makes the surgical resection of these tumors necessary only under life-threatening conditions<sup>7-10</sup>.

However, the regression of these tumors is hard to understand, especially in the case of those located in fibrous regions of the heart, as for example in heart valves, as occurred in the unusual case reported here. Other similar cases have also been infrequently reported in the atrioventricular junction region, in atria, and in venae cavae. Thus, of the 91 cases of rhabdomyomas reported<sup>1-4</sup>, 9 (9.89%) were located in these

### Key Words

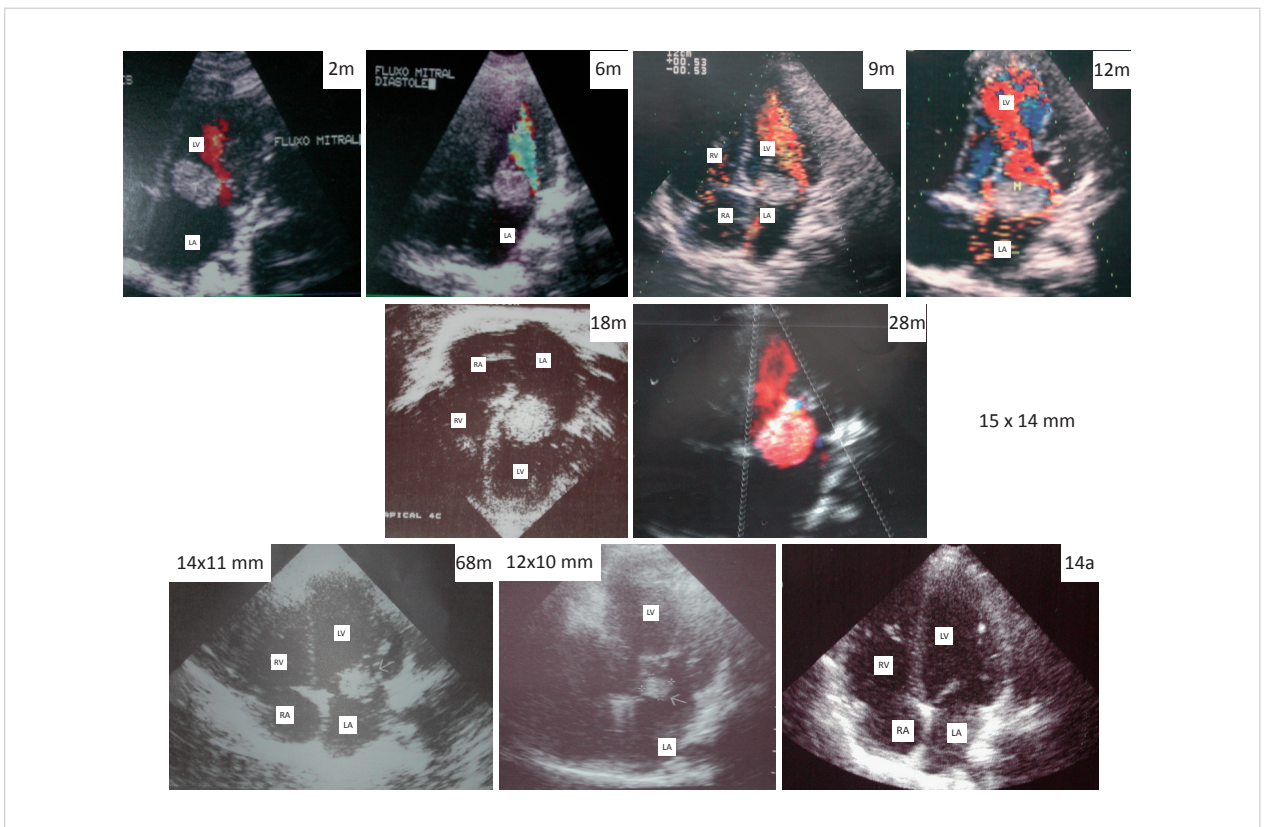
Rhabdomyoma; Heart Defects, Congenital; Mitral Valve.

#### Mailing Address: Edmar Atik •

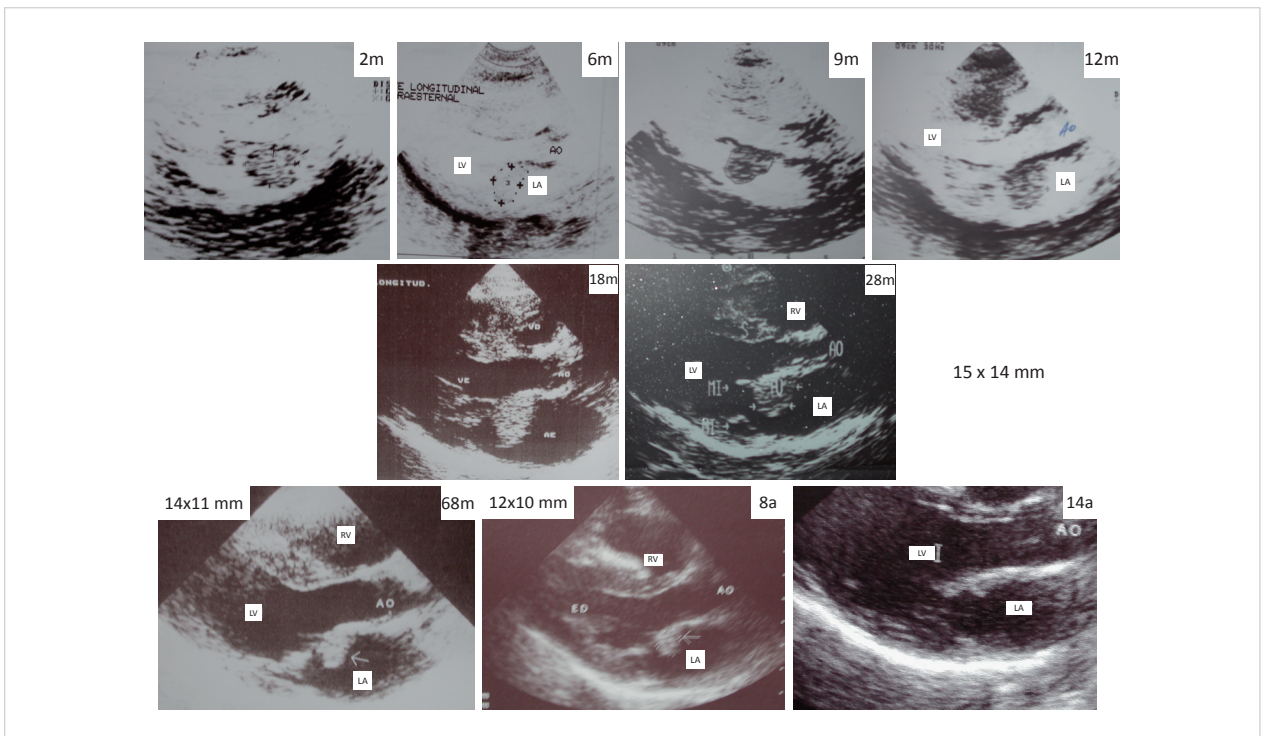
Rua Dona Adma Jafet, 74 cj 73 - 01308-050 - São Paulo, SP, Brazil

E-mail: edmaratik@uol.com.br

Manuscript received October 06, 2008; revised manuscript received December 09, 2008; accepted February 16, 2009.



**Figure 1** - Echocardiograms in apical 4-chamber view showing persistence of the tumor in the atrial face of the anterior mitral valve up to 28 months of age, with progressive decrease as from 68 months of age until complete regression at 14 years of age. mo – months; yr - years



**Figure 2** - Echocardiograms in left parasternal position in longitudinal views showing persistence of the tumor in the atrial face of the anterior mitral valve up to 28 months of age, with progressive reduction as from 68 months of age until complete regression at 14 years of age. mo – months; yr - years

## Case Report

regions, one in the right atrium, 2 in the left atrium, and 6 in the junction of the superior vena cava (5) and inferior vena cava (1) with the right atrium.

In the majority of these cases, and also in other cases with obstruction<sup>8-10</sup>, when the tumor is located in these fibrous regions, surgical intervention is required for the resection of right<sup>10</sup> and left<sup>9</sup> intra-atrial tumor masses.

In the case reported, the late and progressive regression is an uncommon outcome and makes one even more curious as to the pathogenesis of this phenomenon, which is still uncertain.

Thereby, we should be aware of inappropriate surgical indications in similar situations, which are potentially harmful for the patients themselves. Thus, in a retrospective analysis, if we supposed that this patient had undergone an early operation, as was incidentally considered at some moments of the follow-up while he has still an infant, he would probably have been dependent on a mechanical valve prosthesis until today, in addition to being subject to other possible comorbidities.

Therefore, it is necessary to establish more strict and careful criteria for the management of rhabdomyomas,

even in obstructive cases, as corroborated by the present report.

The occurrence of rhabdomyomas in fibrous regions of the heart is unheard of, except for one case described in the mitral annulus<sup>7</sup>. Overall, this case report is relevant not only for demonstrating the regression of rhabdomyoma in a fibrous region, but also because this phenomenon occurred much later than usual, having started as from 68 months of age and ended at 14 years of age.

### Potential Conflict of Interest

No potential conflict of interest relevant to this article was reported.

### Sources of Funding

There were no external funding sources for this study.

### Study Association

This study is not associated with any post-graduation program.

## References

1. Beghetti M, Gow RM, Haney I, Mawson J, Williams WG, Freedom RM. Pediatric primary benign cardiac tumors: a 15-year review. *Am Heart J*. 1997; 134: 1107-14.
2. Bosi G, Lintermans JP, Pellegrino PA, Svaluto-Moreolo G, Vliers A. The natural history of cardiac rhabdomyoma with and without tuberous sclerosis. *Acta Paediatr*. 1996; 85: 928-31.
3. Smythe JF, Dyck JD, Smallhorn JF, Freedom RM. Natural history of cardiac rhabdomyoma in infancy and childhood. *Am J Cardiol*. 1990; 66: 1247-9.
4. Farooki ZQ, Ross RD, Paridon SM, Humes RA, Karpawich PP, Pinsky WW. Spontaneous regression of cardiac rhabdomyoma. *Am J Cardiol*. 1991; 67: 897-9.
5. Isaacs H Jr. Fetal and neonatal cardiac tumors. *Pediatr Cardiol*. 2004; 25: 252-73.
6. Sánchez Andrés A, Insa Albert B, Carrasco Moreno JI, Cano Sánchez A, Moya Bonora A, Sáez Palacios JM. **Tumores cardíacos primarios en la infancia.** *An Pediatr (Barc)*. 2008; 69: 15-22.
7. Pilar Arnaiz G, Toledo IG, Borzutzky AS, Urcelay GM, Heusser FR, Garey FG, et al. Comportamiento clínico de los tumores cardíacos desde el feto hasta el adulto: serie multicéntrica de 38 pacientes. *Rev Méd Chile*. 2006; 134: 1135-45.
8. Dyamenahalli U, Black MD, Boutin C, Gow RM, Freedom RM. Obstructive rhabdomyoma and univentricular physiology: a rare combination. *Ann Thorac Surg*. 1998; 65: 835-7.
9. Abdel-Rahman U, Ozaslan F, Esmaili A, Moritz A. A giant rhabdomyoma with left ventricular inflow occlusion and univentricular physiology. *Thorac Cardiovasc Surg*. 2005; 53: 259-60.
10. Savino JS, Weiss SJ. Images in clinical medicine: right atrial tumor. *N Engl J Med*. 1995; 333: 1608.