

## Cardiac Syncope Induced by Glossopharyngeal “Neuralgia”: a Rare Presentation

Helio Korkes, Eduardo Mesquita de Oliveira, Luigi Brollo, Denise Tessariol Hachul, José Carlos da Silva Andrade, Mario Fernando Prieto Peres, Victor Schubsky

Hospital Israelita Albert Einstein, São Paulo, SP, Brazil

The first description of severe pain in the distribution of the glossopharyngeal nerve is credited to Weisenberg, in 1910<sup>1</sup>, in a patient with cerebellopontine angle tumor. However, it was Harris, in 1926<sup>2</sup>, who coined the term glossopharyngeal neuralgia to describe this rare condition characterized by paroxysms of excruciating pain located laterally at the back of the tongue, soft palate, throat, and lateral and posterior pharynx, radiating to the ear. Swallowing, coughing, yawning or chewing may trigger pain, which usually lasts from seconds to minutes.

The association between glossopharyngeal neuralgia and syncope is very rare, being identified by brief episodes of bradycardia, asystole, and hypotension. Such an association, with this same pathophysiology, was first described by Riley et al<sup>3</sup> in 1942.

Patient with fainting spells related to liquid intake without pain on swallowing over a period of several months. He underwent loop event monitoring, which demonstrated prolonged sinus pause with asystole during swallowing. Syncopal episodes were therefore justified by low cerebral blood flow associated with glossopharyngeal nerve stimulation, even in the absence of pain that characterizes this condition. In cases of glossopharyngeal “neuralgia” without severe pain, permanent cardiac pacing is suggested as early treatment. To our knowledge, this is the first such case reported in Brazilian literature.

### Case report

A 71-year-old white male patient complaining of sporadic syncopal episodes lasting for a few seconds upon drinking liquids. When questioned, he reported mild, ill-characterized “spasms” in the throat on these occasions.

In one of these episodes, he fell and broke a lumbar vertebra. The patient was taking antiparkinsonian drugs regularly.

• *Physical examination:* BP – 140 x 80 mmHg; HR – 72 bpm; Heart – RRR, S1 S2; Lungs – clear; Pulse – symmetrical. NS unremarkable.

• *Supplementary examination:* ECG – Left anterior fascicular block (LAFB); Gastrointestinal endoscopy - distal esophagitis and erosive gastritis; Videofluoroscopic swallowing studies – stasis of residual food in the vallecular region.

• *Loop event monitoring* – sinus arrest and asystole lasting 4.4 seconds, associated with reporting of presyncope during lunch (Fig 1)

Following the diagnosis of swallow-induced syncope with cardiac asystole, the patient underwent permanent pacemaker implantation, and since that time has remained free of syncopal episodes (thirty-five months of follow-up).

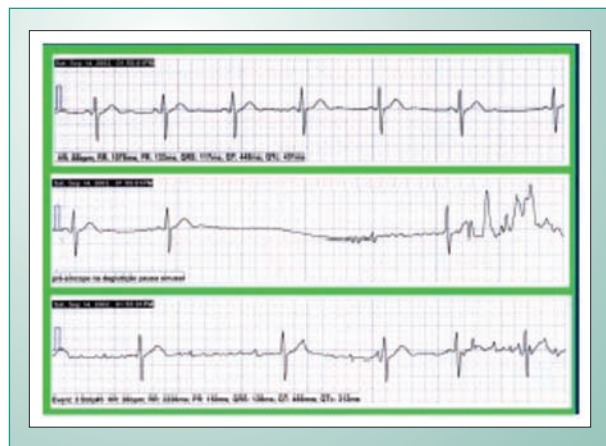


Fig. 1 - Loop event recording.

### Discussion

Glossopharyngeal neuralgia (GPN) is a rare form of pain (0.2 to 1.3% of the cases of facial pain)<sup>4</sup> that occurs approximately one hundred times less frequently than trigeminal neuralgia<sup>5</sup>.

Regarding its etiology, although most cases are idiopathic, it may be secondary to intracranial vascular compression, cerebellopontine angle tumors, laryngeal and nasopharyngeal tumors, trauma, and carotid puncture, among other causes<sup>6-9</sup>.

### Key word

Glossopharyngeal syncope.

Mailing Address: Helio Korkes •

Rua Pirapora, 167 - 04008-060 – São Paulo, SP

E-mail: clinimed@ig.com.br

Manuscript received September 20, 2005; revised manuscript November 29, 2005; accepted on December 8, 2005.

## Case Report

The disease is more common in patients older than 50 years of age, but there is no consensus regarding which sex is most affected<sup>10,11</sup>. Onset is sudden and is usually characterized by severe, unilateral, paroxysmal pain along the glossopharyngeal nerve course.

The most common pain-triggering factor is swallowing, especially liquids, as in the case of this report, in addition to chewing, coughing, and speaking<sup>12</sup>. The association between glossopharyngeal neuralgia and syncope is even rarer, and was first reported by Harris, in 1921<sup>2</sup>.

In a review of 217 GPN patients conducted at the Mayo Clinic in 1981, only four were found to have associated syncope. This association, however, was confirmed in only one patient, whose first symptom was pain<sup>10</sup>.

Although there has been considerable speculation in regard to the syncope mechanism, the most accepted theory was that proposed by Gardner, in 1963<sup>13</sup>. According to Gardner's theory, synapses formed between glossopharyngeal and vagus nerves, in their ganglia, are activated by a sensory irritation phenomenon resulting in lower heart rate, as well as vascular peripheral resistance, possibly mediated, respectively, by the vagus nerve and carotid baroreceptors (Fig. 2).

It has been suggested that only intense neuralgic pain could activate the glossopharyngeal-vagal reflex arc causing bradycardia, hypotension and syncope, and that there is a latent period between neuralgia onset and syncope in these patients<sup>14</sup>.

Based on this theory, considered the most plausible, it is

difficult to explain the syncope experienced by the patient herein reported, as it is also difficult to explain the sole report on painless glossopharyngeal neuralgia published in literature<sup>15</sup>. Nevertheless, other authors agree that this may be possible<sup>11</sup>.

The use of a loop event recorder should be emphasized because this new diagnostic tool is more sensitive and practical than standard Holter ECG in these cases, since it allows the patient to be monitored for several consecutive days, thus improving the likelihood of identifying these usually sporadic and brief changes.

It is noteworthy that no reports were found in literature describing the use of this method (cardiac event recording) in the diagnosis of glossopharyngeal or swallow syncope.

As far as treatment is concerned, the medical literature supports the use of carbamazepine in the management of idiopathic neuralgia<sup>5,10,14</sup>. Temporary pacemaker implantation to treat the reflex cardiac syncope until therapeutic levels of carbamazepine are reached was first described by Khero in 1971<sup>16</sup>.

Regarding permanent pacemaker implantation, the available literature is quite controversial<sup>12</sup>. Neither the pharmacological approach to idiopathic neuralgia nor the surgical approach to other types requires pacemaker implantation because, by controlling the pain, they also control or abolish syncopal episodes.

Swallow syncope should be considered in the differential diagnosis of these patients. This condition is caused by vasovagal reflex and has a similar presentation. It is often accompanied by arterial hypotension, which may even precede the chronotropic effect and be precipitated by esophageal distension or spasms (as uncharacteristically referred by the patient)<sup>17</sup>. However, in this also rare etiology of neurocardiogenic syncope patients often have esophageal abnormalities, such as diverticula and, occasionally, major changes in heart structure or rhythm<sup>18</sup> but without pain or sensory changes upon swallowing.

In the present report, owing to the lack of pain associated with glossopharyngeal neuralgia and the severity of syncopal episodes (in one of the them the patient sustained vertebral fracture and was disabled for months), permanent pacemaker implantation was the treatment of choice, even without previous pharmacological therapy. The same approach was used in the sole report of painless glossopharyngeal nerve syncope published in literature<sup>15</sup>, and it is the formal indication for swallow syncope.

Thirty-five months after pacemaker implantation, the patient remains free of syncopal events.

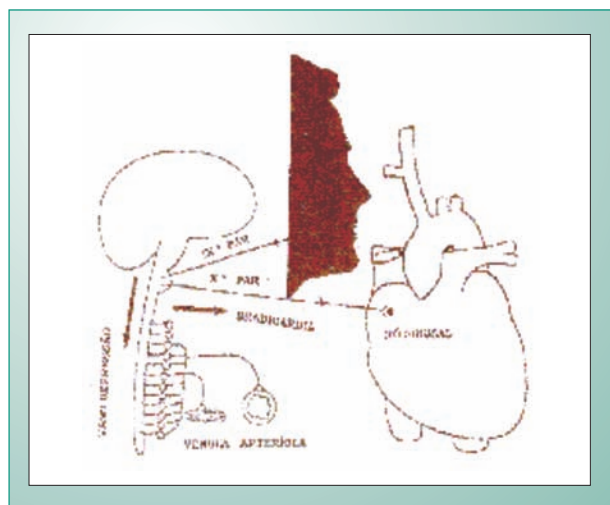


Fig. 2 - Glossopharyngeal reflex arc syncope.

## References

1. Weisenberg TH. Cerebellopontile tumor diagnosed for six years as tic douloureux: The symptoms of irritation of the 9th and 12th nerves. *JAMA* 1910; 54: 1600-4.
2. Harris W. *Neuritis and Neuralgia*. New York: Oxford University Press; 1926.
3. Riley HA, Greenan WJ, Wortis H. Glossopharyngeal neuralgia initiating or associated with cardiac arrest. *Trans Am Neurol Assoc* 1942; 18: 28-9.
4. Chawla JC, Falconer MA. Glossopharyngeal and vagal neuralgia. *Br Med J* 1967; 3: 529-31.
5. Cowley AW, Liard JF, Guyton AC. Role of the baroreceptor reflex in daily control of arterial blood pressure and other variables in the dog. *Circ Res* 1973; 32: 564-76.

6. Brihaye J, Perier O, Smulders J, Franken L. Glossopharyngeal neuralgia caused by compression of the nerve by an atheromatous vertebral artery. *J Neurol Surg* 1956; 13: 299-302.
7. Jannetta PJ. Cranial nerve vascular compression syndromes (other than tic douloureux and hemifacial spasm). *Clin Neurosurg* 1980; 28: 445-56.
8. Waga S, Kojima T. Glossopharyngeal neuralgia of traumatic origin. *Surg Neurol* 1982; 17: 77-9.
9. Weinstein RE, Herec D, Friedman JH. Hypotension due to glossopharyngeal neuralgia. *Arch Neurol* 1986; 43: 90-2.
10. Rushton JG, Stevens C, Miller RH. Glossopharyngeal (Vagoglossopharyngeal) neuralgia. *Arch Neurol* 1981; 38: 201-5.
11. Ferrante L, Artico M, Nardacci B, Fraioli B, Consentino F, Fortuna A. Glossopharyngeal neuralgia with cardiac syncope. *Neurosurgery* 1995; 36: 58-63.
12. Elias J, Kuniyoshi R, Valadão W, Carloni H, Borges MR, Peixoto CA, et al. Neuralgia do Glossofaríngeo associada à síncope cardíaca reflexa. *Arq Bras Cardiol* 2002; 78: 510-14.
13. Gardner WJ. Concerning the mechanism of trigeminal neuralgia and hemifacial spasm. *J Neurosurg* 1963; 19: 947-58.
14. Johnston RT, Redding VJ. Glossopharyngeal neuralgia associated with cardiac syncope: long term treatment with permanent pacing and carbamazepine. *Br Heart J* 1990; 60: 403-5.
15. Reddy K, Hobson DE, Gomori A, Sutherland GR. Painless glossopharyngeal "Neuralgia" with syncope: A case report and literature review. *Neurosurgery* 1987; 21: 916-19.
16. Khero BA, Mullins CB. Cardiac syncope due to glossopharyngeal neuralgia – treatment with transvenous pacemaker. *Arch Intern Med* 1971; 128: 806-8.
17. Deguchi K, Mathias CJ. Continuous hemodynamic monitoring in an unusual case of swallow induced syncope. *J Neurol Neurosurg Psychiatry* 1999; 67: 220-2.
18. Levin B, Posner JB. Swallow syncope. *Neurology* 1972; 22: 1086-93.