

Case 3/2013 - A Newborn with Aortic Valve Stenosis Mimicking Hypoplastic Left Heart

Edmar Atik

Instituto do Coração do Hospital das Clínicas da Faculdade de Medicina da Universidade de São Paulo, São Paulo, SP – Brazil

Medical history: Immediately following cesarean delivery, a well-nourished neonate presented with apnea. After manual ventilation, the patient developed diffuse pulmonary interstitial emphysema with respiratory failure, requiring tracheal intubation. A previously known diagnosis of aortic valve stenosis had been established on the fifth month of gestation. The neonate was transferred to our service where he showed normal saturation and severe heart failure.

Physical examination: On assisted ventilation, he presented no cyanosis; his extremities were cold, and the pulses were decreased in the four limbs. Weight: 2,800g. Height: 48 cm. Right arm blood pressure (RABP): 78/52-61 mmHg. Left arm blood pressure (LABP): 73/40-51 mmHg. Right leg blood pressure (RLBP): 56/25-35 mmHg. Heart rate (HR): 132 bpm. Respiratory rate (RR): 30 rpm. O₂ saturation = 96%. The aorta was not palpable in the suprasternal notch.

In the precordium, the apical impulse was not palpable and there were clear systolic impulses on the left sternal border and epigastrium. The heart sounds were accentuated and a mild grade 1-2/6 coarse systolic murmur was heard over the aortic area and left sternal border, with no thrill. A soft grade 1-2/6 systolic murmur could be heard over the mitral area, radiating to the axilla. The liver was palpable at 3 cm from the right costal margin.

Laboratory tests

Electrocardiography (Figure 1) showed junctional rhythm and signs of left chamber overload; RS complexes in V1 and rsR' in V6, with positive T waves in V1 and negative P waves in precordial leads; P wave axis (AP): +200°; QRS axis (AQRS): +70°; T wave axis (AT): +80°.

Chest radiograph showed increased cardiac silhouette at the expense of the left ventricular arch and right atrial arch with increased pulmonary vascular network due to pulmonary capillary congestion (Figure 1).

Keywords

Heart Defects, Congenital; Aortic Valve Stenosis; Heart / abnormalities.

Mailing Address: Edmar Atik •

Av. Dr. Enéas Carvalho de Aguiar, 44 - Postal Code 05403-000, São Paulo, SP - Brazil

E-mail: conatik@incor.usp.br

DOI: 10.5935/abc.20130117

Echocardiogram (Figure 2) showed severe aortic valve annulus stenosis (3.7 mm); hypoplastic ascending aorta (3.6 mm); very dilated left chambers with endocardial fibroelastosis and severe left ventricular dysfunction (EF = 25%); and severe mitral regurgitation with thickened leaflets, and anterior leaflet prolapse. A large ductus arteriosus (6.4 mm) allowed right-to-left blood flow mainly towards the descending aorta, with mild backward flow into the aortic arch. Measurements were as follows: right ventricle (RV) = 9, left ventricle (LV) = 24, left atrium (LA) = 17, aorta (Ao) = 3.6, tricuspid heart valve (TV) = 9, mitral heart valve (MV) = 11.5, pulmonary heart valve (PV) = 9, aortic heart valve (AoV) = 3.7, PT = 11, PA = 3.7 delta D = 16%. The atrial and ventricular septae were normal. The LV-Ao pressure gradient was 18 mmHg, arch = 6, DescAo = 9 mm.

Clinical diagnosis: critical aortic valve annulus stenosis, hypoplastic ascending aorta, severe mitral valve regurgitation with left ventricular dysfunction, endocardial fibroelastosis, ductus arteriosus with backflow with a hemodynamic pattern similar to that of hypoplastic left heart.

Clinical reasoning: The clinical findings were consistent with the diagnosis of a congestive disorder similar to that found in hypoplastic left heart, with the cardiac output maintained by a reverse flow through the large ductus arteriosus, due to the pulmonary hypertension resulting from mitral valve regurgitation. The critical aortic valve stenosis was responsible for the mild heart murmur heard in the aortic area. Left ventricular overload on electrocardiogram and cardiomegaly completed the presentation. These diagnostic findings were confirmed by echocardiographic imaging.

Differential diagnosis: Early clinical decompensation is also found in other congenital obstructive heart defects such as mitral valve stenosis, interrupted aortic arch, and in hypoplastic left heart itself.

Management: Due to the effects caused by the aortic valve and ascending aorta obstruction, with resulting left ventricular dysfunction, accompanied by endocardial fibroelastosis, severe mitral valve regurgitation and no septal defect, we considered that the severe heart failure could worsen even further with any type of surgical or percutaneous intervention, given the severe clinical instability. Thus, we chose to keep the patient on vasoactive drugs with prostaglandin E1, diuretics, and respiratory support until a cardiac transplantation could be performed. However, the prolonged clinical course precipitated the performance of the opening of the atrial septum and pulmonary artery banding, with immediate death.

Comments: Severe aortic valve stenosis in the fetal life may progress to further worsening of the condition, with fetal death,

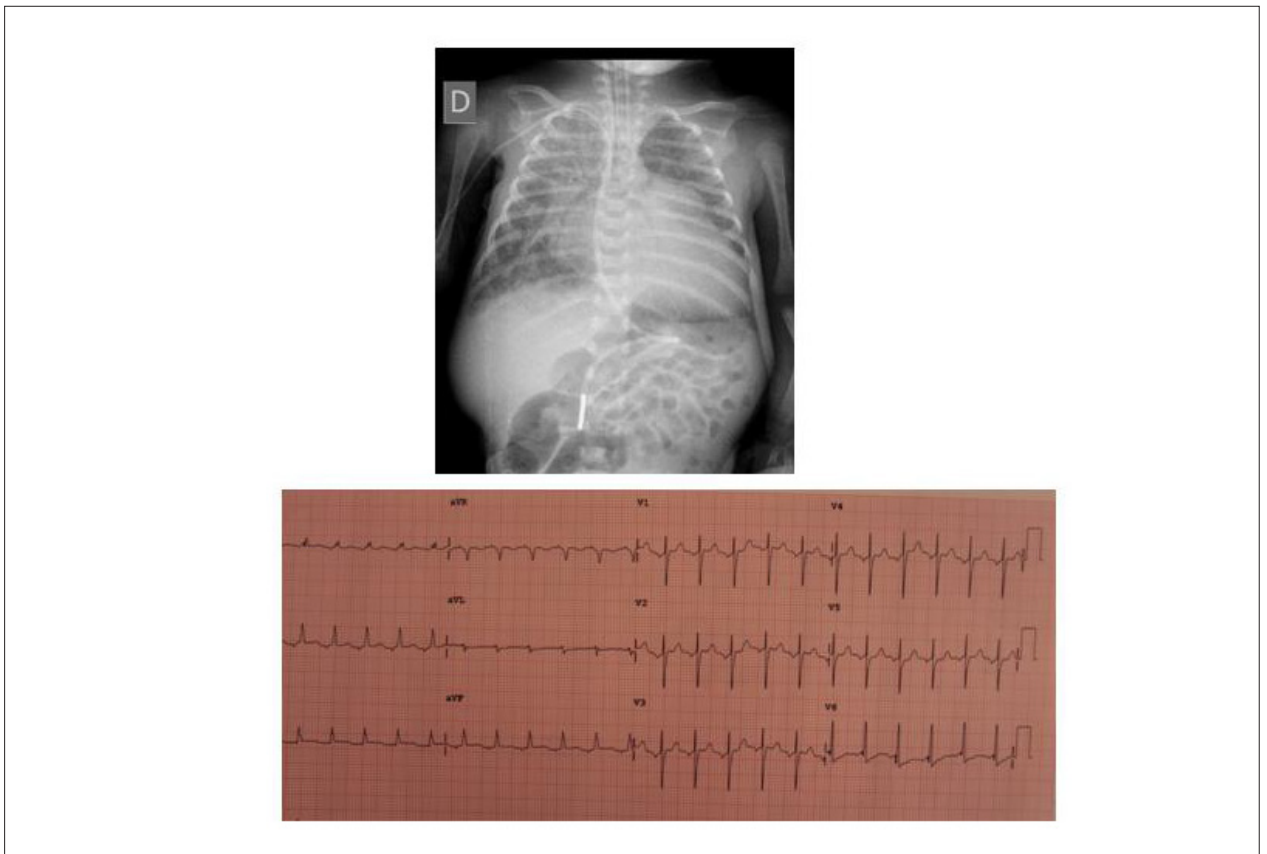


Figure 1 - Electrocardiogram shows junctional rhythm and severe left chamber overload; chest radiograph shows enlarged cardiac silhouette and pulmonary vascular network.

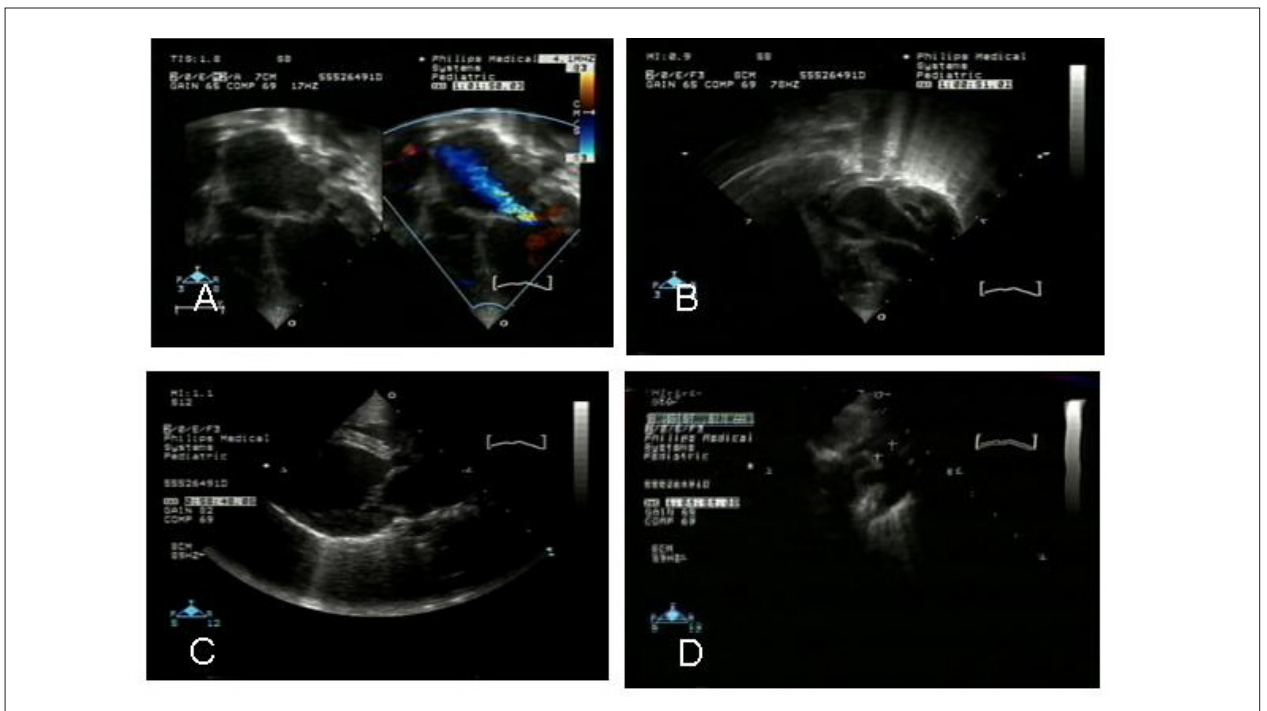


Figure 2 - Echocardiogram shows severely enlarged left chambers, with atrial and ventricular septae deviated to the left, in A and B. Severe mitral valve regurgitation, in A. Small aortic annulus and ascending aorta, in B and C. Large ductus arteriosus communicating with the descending aorta, in D.

Clinicoradiological Session

or trigger anatomical aspects usually found in hypoplastic left heart or, also, low neonatal output due to aortic obstruction. In both situations the condition, which depends on pulmonary hypertension for the cardiac output to be maintained through the ductus arteriosus, is extremely susceptible to sudden worsening. A more conservative approach, with stent implantation in the ductus arteriosus and pulmonary artery banding could be ineffective in this case, due to the severe left ventricular dysfunction, with mitral regurgitation and consequent perpetuation of the pulmonary congestion. Another approach, such as the opening of the interatrial

septal communication, could cause a reduction in pulmonary hypertension with subsequent low cardiac output; hence the need for the concomitant performance of pulmonary artery banding. Correction of the mitral valve regurgitation would not improve the ventricular dysfunction, and the opening of the aortic valve would not provide an adequate backward flow, also because of the ventricular dysfunction. Because of this anatomical-functional characteristic, we chose a more radical approach with cardiac transplantation, which was not performed due to the difficulty in obtaining a donor of such young age.