

Giant Left Ventricle Outflow Tract Pseudoaneurysm after Ross Procedure

Sílvia Leão, Sofia Carvalho, Hélder Ribeiro, Paulo Fontes, J. Ilídio Moreira

Centro Hospitalar de Trás-Os-Montes e Alto Douro, Hospital de Vila Real, Portugal

A 33-year-old woman was admitted to our hospital because of dyspnea on exertion, orthopnea, cough and pedal edema for the past six months. Six years earlier she had been submitted to Ross procedure for correction of a bicuspid aortic valve.

Physical exam was unremarkable except by a grade 3 systolic murmur on left sternal border.

A chest X-ray revealed an opacity on left border of cardiac silhouette (Figure 1A). Transthoracic echocardiography presented a giant saccular structure, adjacent and connected to the left ventricular outflow tract through a neck located at 2 o'clock position, compatible with a pseudoaneurysm. This structure caused compression of the right ventricle outflow tract (RVOT) and pulmonary artery, causing mild obstruction (Figure 1 B and C).

Cardiac magnetic resonance imaging identified its origin on left ventricle outflow tract (LVOT), in close relation to left and non-coronary sinus. There were small thrombi inside the pseudoaneurysm, tapering the wall adjacent to the left ventricle (Figures 1D and E).

Patient was surgically treated. The pseudoaneurysm sack was opened through a transpleural access and the communication between the LVOT and the pseudoaneurysmal cavity was closed with a Teflon patch. Patient's post-operative recovery and follow-up were uneventful.

After 3 months of follow-up she is asymptomatic. The pseudoaneurysm is completely excluded from

arterial circulation, without significant obstruction of RVOT (Figure 1F).

LVOT pseudoaneurysm is an uncommon but potentially life-threatening complication of Ross procedure. Follow-up with imaging techniques allows early identification and prompt intervention.

Author contributions

Conception and design of the research and Writing of the manuscript: Leão S; Acquisition of data: Leão S, Carvalho S; Analysis and interpretation of the data: Leão S, Carvalho S, Ribeiro H; Critical revision of the manuscript for intellectual content: Carvalho S, Ribeiro H, Fontes P, Moreira JI.

Potential Conflict of Interest

No potential conflict of interest relevant to this article was reported.

Sources of Funding

There were no external funding sources for this study.

Study Association

This study is not associated with any thesis or dissertation work.

Keywords

Ventricular Outflow Obstruction / surgery; Cardiac Surgical Procedures / complications; Echocardiography.

Mailing Address: Sílvia Leão •

Av. da Noruega. Postal Code 5000-508. Vila Real – Portugal

E-mail: silvia.carneiro.leao@gmail.com

Manuscript received August 03, 2016, revised manuscript September 13, 2016, accepted September 13, 2016

DOI: 10.5935/abc.20170008

Image

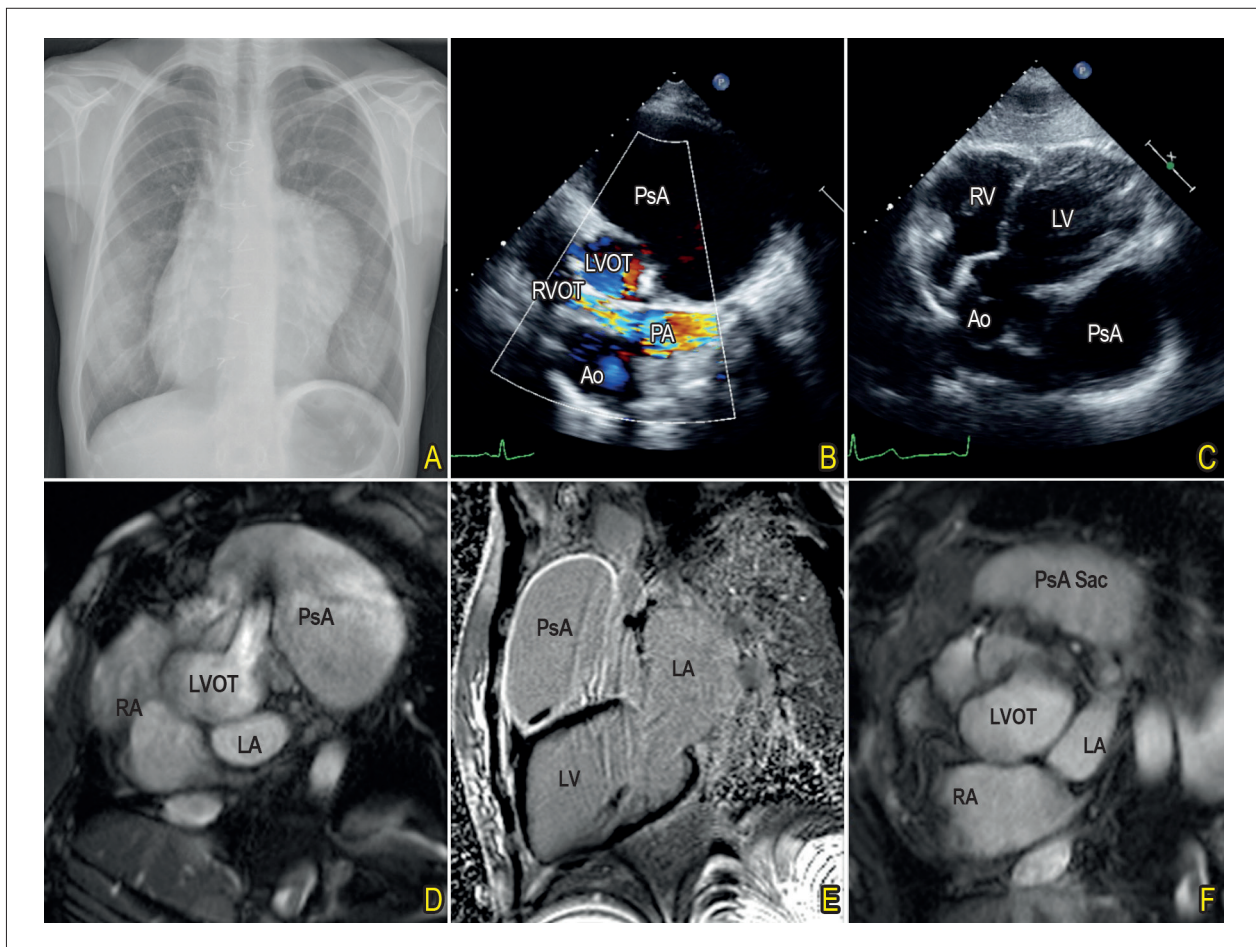


Figure 1 - A) Chest radiograph; B and C) Preoperative transthoracic echocardiography, modified short axis and subcostal views; D and E) Preoperative magnetic resonance imaging; F) Follow-up magnetic resonance imaging. Ao: aorta; LA: left atrium; LVOT: left ventricle outflow tract; LV: left ventricle; RA: right atrium; RV: right ventricle; PA: pulmonary artery; PsA: Pseudoaneurysm; RVOT: right ventricle outflow tract.