

GASTRIC SLEEVE FIXATION STRATEGY IN LAPAROSCOPIC VERTICAL SLEEVE GASTRECTOMY

Estratégia de fixação do sleeve gástrico na gastrectomia vertical laparoscópica

Eudes Paiva de **GODOY**, Daniel **COELHO**

From the Department of Surgery of Obesity and Related Diseases - SCODE, Onofre Lopes University Hospital, Federal University of Rio Grande do Norte, Natal, RN, Brazil.

HEADINGS - Sleeve gastrectomy. Laparoscopy. Gastroesophageal reflux. Gastric malpositioning. Gastric fixation

Correspondence:

Eudes Paiva de Godoy
E-mail: godoy@equipeunicad.com

Financial source: none
Conflicts of interest: none

Received for publication: 14/05/2013
Accepted for publication: 16/07/2013

DESCRITORES - Gastrectomia vertical. Laparoscopia. Refluxo gastroesofágico. Mau posicionamento gástrico. Fixação gástrica

ABSTRACT: Introduction: Initially conceived as the first of two stages in operations such as gastric bypass or duodenal switch in high-risk patients, laparoscopic vertical sleeve gastrectomy has increasingly become the definitive procedure for treating obesity and its comorbidities. Although it is associated with excellent results and postoperative quality of life, a number of complications related to improper position and/or gastric tube deformities, resulting from loss of natural fixation, may be associated to symptoms of persistent food intolerance and/or gastroesophageal reflux. **Aim:** To present the gastric fixation strategy in vertical sleeve gastrectomy for the treatment of obesity and related diseases. **Technique:** The gastric suture line along the "new greater curvature" is divided into two parts. Using non-absorbable 2.0 polyester thread, a continuous suture fixation is made in the proximal part attaching it to the free edge of the gastrocolic ligament with invagination. Separate sutures were applied to the distal part, including the transverse mesocolon near the lower edge of the pancreas. **Conclusion:** The stomach fixation strategy is easy to use, safe and can reduce complications arising from improper positioning and gastric tube alterations in laparoscopic vertical sleeve gastrectomy, particularly symptoms related to food intolerance and gastroesophageal reflux.

RESUMO - Introdução: Inicialmente idealizada como primeira de duas etapas em operações como bypass gástrico ou switch duodenal em pacientes de alto risco, a gastrectomia vertical laparoscópica vem se sedimentando como procedimento definitivo no tratamento da obesidade e suas comorbidades. Embora associada a bons resultados e qualidade de vida pós-operatória, algumas complicações relacionadas ao mau posicionamento e/ou deformidades do tubo gástrico, decorrentes da perda de suas relações de fixação naturais, podem estar associadas aos sintomas de intolerância alimentar persistente e/ou refluxo gastroesofágico. **Objetivo:** Apresentar estratégia de fixação do sleeve gástrico na gastrectomia vertical laparoscópica. **Técnica:** A linha de sutura do estômago ao longo da "nova grande curvatura" é dividida em duas partes. Na sua metade proximal, realiza-se uma sutura contínua na forma de pexia com a borda liberada do ligamento gastrocólico, invaginando-a com fio não absorvível de poliéster 2-0. Na metade distal, aplicam-se pontos separados que incluem também o mesocólon transverso próximo à borda inferior do pâncreas. **Conclusão:** A estratégia de fixação do estômago apresentada mostra-se de fácil execução, segura e pode reduzir complicações decorrentes de mau posicionamento e alterações de conformação do tubo gástrico na gastrectomia vertical laparoscópica, particularmente sintomas relacionados à intolerância alimentar e refluxo gastroesofágico.

INTRODUCTION

Vertical sleeve gastrectomy is increasing and has become the first option for many surgeons worldwide in treating obesity and its associated diseases^{30,25,14}. Better knowledge of the mechanisms involved and good results have driven this growth and awoken interest. Despite the relative technical simplicity and minimal impact on digestive physiology, with fewer risks of nutritional complications, a number of early, potentially serious postoperative problems - such as bleeding and difficult to resolve fistulae -, are still a point of concern for surgeons and patients^{30,9,21}. Symptoms of persistent food intolerance are not common, because the operation does not

result in narrowed areas such as calibrated anastomoses or prostheses. Gastroesophageal reflux has been one of the main postoperative complications^{11,12,17}. Although the mechanisms are not fully understood, worsening symptoms or their emergence after the procedure may significantly compromise quality of life and require prolonged treatment or even further surgery¹⁸. The persistent presence of hiatal hernia, impairment of lower sphincter function, loss of gastric complacency and mechanical or functional obstructions along the gastric tube have been suggested as causes^{12,8,20}. It has recently been reported that loss of abdominal ligament fixations along the greater curvature of the stomach may result in improper gastric pouch positioning, causing food intolerance and persistent reflux^{6,22}. Cases of gastric volvulus and twisting have been described, with the possibility of more subtle positioning situations occurring and leading to problems¹³.

In light of the above, and owing to the current inability to identify the factors responsible for the problems of improper positioning discussed, this strategy is offered and consisting of systematically fixing the gastric pouch along its new greater curvature, reestablishing its natural relationships in order to provide better postoperative anatomic and functional conditions.

TECHNIQUE

The suture line is divided into two halves. In the proximal half, is made a continuous suture with 2.0 polyester non-absorbable thread between the free edge of the gastrocolic ligament and the gastric suture line, invaginating it from its extremity near the gastroesophageal junction (Figures 1 and 2).

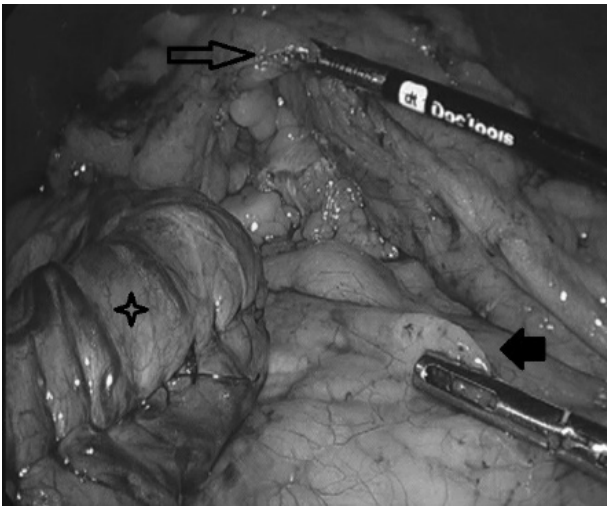


FIGURE 1 – Well exposed gastrocolic ligament (outlined arrow), mesocolon delimiting the pelvic floor along with the lower edge of the pancreas (solid arrow) and the gastric pouch (star) with over-sewing of the staple line where fixation will be applied

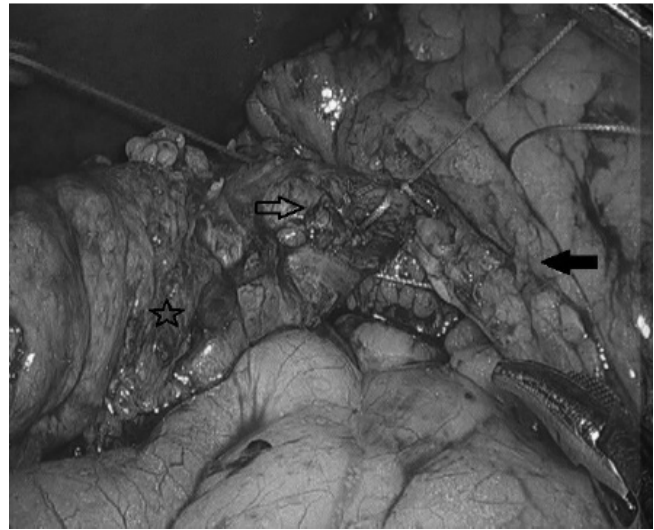


FIGURE 2 - Fixation under construction, where the suture runs over the gastrocolic ligament (solid arrow) and then the suture line of the gastric pouch (star) with its invagination (outlined arrow)

In the distal half, the sutures are separate and also include the transverse mesocolon near the lower edge of the pancreas (Figure 3).

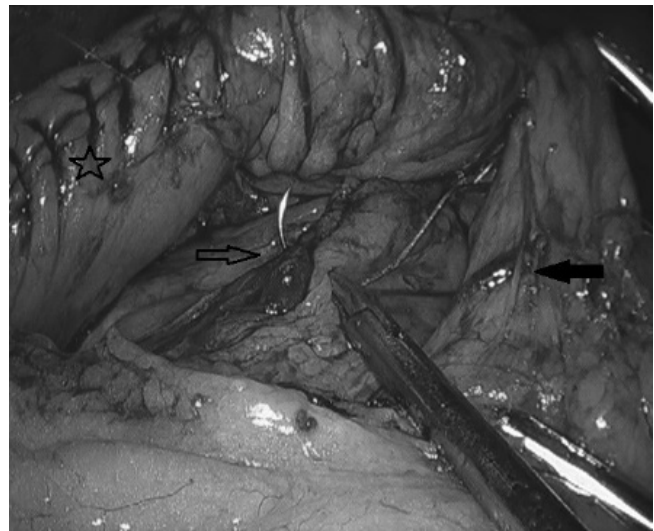


FIGURE 3 - Details of inferior fixation to the lower edge of the pancreas: after the suture is passed over the gastrocolic ligament including the gastroepiploic vessels (solid arrow), attachment to the transverse mesocolon is made beneath the lower edge of the pancreas (outlined arrow) and then to the staple line (star).

Those on the gastrocolic ligament envelop a sufficient amount of tissue and gastroepiploic vessels to support and cover the entire gastric suture line. The stitches applied to the transverse mesocolon are carefully positioned to avoid vascular or pancreatic lesions. Figure 4 shows the final appearance of the stomach.

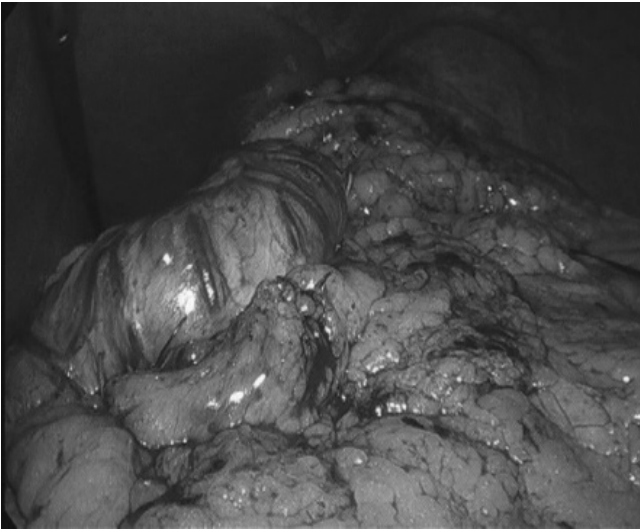


FIGURE 4 - Final aspect of the gastric pouch: gastric pouch exhibiting a "C" shape with separate sutures fixing the mesocolon and lower edge of the pancreas with over-sewing of the gastrocolic ligament to the staple line, providing protection.

DISCUSSION

Here is proposed stomach fixation in VSG aimed to reduce the occurrence of improper gastric tube positioning and symptoms of food intolerance and gastroesophageal reflux. This technique can help prevent these problems by keeping the stomach fixed in a physiological position, which would allow better gastric emptying.

Recent studies show significant changes in gastric emptying after vertical sleeve gastrectomy^{23,10}. Although emptying time for liquids is generally shorter, the peristaltic capacity of the sleeve seems to be considerably compromised⁷. Thus, areas of narrowing or functional stenosis, mainly at the level of the angular incisure, and/or proximal dilations may be associated to emptying difficulties and result in persistent postoperative food intolerance and gastroesophageal reflux^{19,16,33}.

Furthermore, growing evidence leads to believe that alterations in gastric tube shape or improper placement are important in this context^{22,29,31}. Parikh et al. underscore the role of functional stenosis associated to twisting of the gastric sleeve, which hinders passage of the intraluminal content, despite the easy passage of the endoscope or dilating balloon through the narrowed area, but resulting in recurring stenosis after their removal²⁴.

The stomach normally remains fixed in its position by gastrohepatic, gastrosplenic and gastrocolic ligaments⁴. Distension caused by the presence of food in the absence of one of these ligaments may lead to primary rotation^{32,27}. Del Castillo et al. recently described a case of gastric volvulus after vertical

gastrectomy¹³. The patient was treated by antrectomy of the gastric sleeve and gastroileal anastomosis evolving to major morbidity due to a duodenal fistula. The authors underscored that since they were not aware of other case reports on gastric volvulus after vertical gastrectomy, they could not recommend any fixation procedure involving a tubulized stomach.

Santoro suggests that losses of natural fixation of the stomach along the greater curvature could result in altered shape and placement associated to postoperative emptying disorders. It is recommended that in certain cases the surgeon may observe the tendency of the gastric tube to form a coil shape and that fixation sutures be applied to the greater omentum to correct the deformity and maintain it in the proper position²⁶. The impression of the authors of this paper is that the use of the greater omentum for this purpose would not promote sufficient fixation in light of its natural mobility. This proposal is based on the application of sutures that encompass the free edge of the gastrocolic ligament, the primary natural fixation point of the greater gastric curvature, enveloping the gastroepiploic vessels, and the root of the transverse mesocolon near the lower edge of the pancreas, which seems to be a more efficient strategy for promoting suitable fixation with greater stability.

More subtle placement changes may be associated to postoperative symptoms. Baumann et al. emphasized the importance of proximal migration of the gastric pouch in the emergence of gastroesophageal reflux after vertical sleeve gastrectomy. Using three-dimensional analysis with computed tomography, they observed that 36% of patients operated on exhibited intrathoracic migration⁶. The exact frequency of this complication and its real impact on postoperative symptoms as well as the mechanisms for its prevention are yet unknown.

Given the absence of evidence allowing to safely predict which patient will present with problems related to postoperative gastric placement, was carried out and recommend the previously described fixation strategy.

Although it remains a controversial issue, a number of authors have recommended over-sewing the staple line, as well as reinforcing it with biological materials as a means of protection against fistulae and bleeding^{18,3,28,2,15}. Baltasar suggested fixation with the greater omentum in order to provide more protection on the suture line in vertical sleeve gastrectomy⁵. This proposal accomplishes this protection through fixation, not with the greater omentum, but with the gastrocolic ligament and invaginating stitches on the gastric suture line. An additional advantage of this strategy would be the ability to adjust the caliber of the pouch, avoiding areas of proximal dilation.

It can therefore be concluded that several short and long term adverse symptoms may be related to alterations in gastric tube positioning after vertical gastrectomy. The stomach fixation with this strategy, which has proven to

be easy to apply, has a non-significant effect on surgery time, is safe and seems to provide suitable and reliable re-fixation of the stomach after the procedure. This may promote enhanced postoperative esophageal and gastric emptying, reducing the occurrence of symptoms related to reflux and/or persistent food intolerance, in addition to being useful in protecting the staple line, thereby providing greater resistance against fistulae and hemorrhagic complications. Further studies are needed to assess the real mechanisms responsible for these complications and the effectiveness of this and other preventive measures.

CONCLUSION

The stomach fixation strategy is easy to use, safe and can reduce complications arising from improper positioning and gastric tube alterations in laparoscopic vertical sleeve gastrectomy, particularly symptoms related to food intolerance and gastroesophageal reflux.

REFERENCES

1. Abdemur A, Fendrich I, Rosenthal R. Laparoscopic conversion of laparoscopic sleeve gastrectomy to gastric bypass for intractable gastroesophageal reflux disease. *Surg Obes Relat Dis.* 2012;8(5):654. Epub 2011/09/06.
2. Albanopoulos K, Alevizos L, Flessas J, Menenakos E, Stamou KM, Papailiou J, et al. Reinforcing the staple line during laparoscopic sleeve gastrectomy: prospective randomized clinical study comparing two different techniques. Preliminary results. *Obes Surg.* 2012;22(1):42-6. Epub 2011/05/03.
3. Alley JB, Fenton SJ, Harnisch MC, Angeletti MN, Peterson RM. Integrated bioabsorbable tissue reinforcement in laparoscopic sleeve gastrectomy. *Obes Surg.* 2011;21(8):1311-5. Epub 2010/11/20.
4. Askew AR. Treatment of acute and chronic gastric volvulus. *Ann R Coll Surg Engl.* 1978;60(4):326-8. Epub 1978/07/01. PubMed PMID: 666240; PubMed Central PMCID: PMC2492115.
5. Baltasar A. Laparoscopic sleeve gastrectomy with partial antrectomy and omental patch. *BMI.* 2011;1(1).
6. Baumann T, Grueneberger J, Pache G, Kuesters S, Marjanovic G, Kulemann B, et al. Three-dimensional stomach analysis with computed tomography after laparoscopic sleeve gastrectomy: sleeve dilation and thoracic migration. *Surg Endosc.* 2011;25(7):2323-9. Epub 2011/02/08.
7. Baumann T, Kuesters S, Grueneberger J, Marjanovic G, Zimmermann L, Schaefer AO, et al. Time-resolved MRI after ingestion of liquids reveals motility changes after laparoscopic sleeve gastrectomy--preliminary results. *Obes Surg.* 2011;21(1):95-101. Epub 2010/11/23.
8. Braghetto I, Csendes A, Korn O, Valladares H, Gonzalez P, Henriquez A. Gastroesophageal reflux disease after sleeve gastrectomy. *Surgical laparoscopy, endoscopy & percutaneous techniques.* 2010;20(3):148-53. Epub 2010/06/17.
9. Campanile FC, Boru CE, Rizzello M, Puzziello A, Copaescu C, Cavallaro G, et al. Acute complications after laparoscopic bariatric procedures: update for the general surgeon. *Langenbecks Arch Surg.* 2013;398(5):669-86. Epub 2013/03/23.
10. Carbone SF, Di Cosmo L, Tirone A, Bancheri A, Vuolo G, Volterrani L. Evaluation of motility changes after laparoscopic sleeve gastrectomy using magnetic resonance imaging. *Obes Surg.* 2011;21(11):1806-7; author reply 8-9. Epub 2011/07/26.
11. Carter PR, LeBlanc KA, Hausmann MG, Kleinpeter KP, deBarros SN, Jones SM. Association between gastroesophageal reflux disease and laparoscopic sleeve gastrectomy. *Surg Obes Relat Dis.* 2011;7(5):569-72. Epub 2011/03/25. PubMed PMID: 21429818.
12. Chiu S, Birch DW, Shi X, Sharma AM, Karmali S. Effect of sleeve gastrectomy on gastroesophageal reflux disease: a systematic review. *Surg Obes Relat Dis.* 2011;7(4):510-5. Epub 2010/12/07.
13. Del Castillo DeJardin D, Sabench Pereferrer F, Hernandez Gonzalez M, Blanco Blasco S, Cabrera Vilanova A. Gastric volvulus after sleeve gastrectomy for morbid obesity. *Surgery.* 2013;153(3):431-3. Epub 2012/02/10.
14. Frezza EE. Laparoscopic vertical sleeve gastrectomy for morbid obesity. The future procedure of choice? *Surg Today.* 2007;37(4):275-81. Epub 2007/03/28.
15. Gill RS, Switzer N, Driedger M, Shi X, Vizhul A, Sharma AM, et al. Laparoscopic sleeve gastrectomy with staple line buttress reinforcement in 116 consecutive morbidly obese patients. *Obes Surg.* 2012;22(4):560-4. Epub 2012/01/20.
16. Goitein D, Goitein O, Feigin A, Zippel D, Papa M. Sleeve gastrectomy: radiologic patterns after surgery. *Surg Endosc.* 2009;23(7):1559-63. Epub 2009/02/28.
17. Howard DD, Caban AM, Cendan JC, Ben-David K. Gastroesophageal reflux after sleeve gastrectomy in morbidly obese patients. *Surg Obes Relat Dis.* 2011;7(6):709-13. Epub 2011/10/01.
18. Kasalicky M, Michalsky D, Housova J, Haluzik M, Housa D, Haluzikova D, et al. Laparoscopic sleeve gastrectomy without an over-sewing of the staple line. *Obes Surg.* 2008;18(10):1257-62. Epub 2008/07/24.
19. Keidar A, Appelbaum L, Schweiger C, Elazary R, Baltasar A. Dilated upper sleeve can be associated with severe postoperative gastroesophageal dysmotility and reflux. *Obes Surg.* 2010;20(2):140-7. Epub 2009/12/02.
20. Kuper MA, Kramer KM, Kirschniak A, Zdichavsky M, Schneider JH, Stuker D, et al. Dysfunction of the lower esophageal sphincter and dysmotility of the tubular esophagus in morbidly obese patients. *Obes Surg.* 2009;19(8):1143-9. Epub 2009/06/11.
21. Lalor PF, Tucker ON, Szomstein S, Rosenthal RJ. Complications after laparoscopic sleeve gastrectomy. *Surg Obes Relat Dis.* 2008;4(1):33-8. Epub 2007/11/06.
22. Lazoura O, Zacharoulis D, Triantafyllidis G, Fanariotis M, Sioka E, Papamargaritis D, et al. Symptoms of gastroesophageal reflux following laparoscopic sleeve gastrectomy are related to the final shape of the sleeve as depicted by radiology. *Obes Surg.* 2011;21(3):295-9. Epub 2010/12/18.
23. Melissas J, Koukouraki S, Askoxyllakis J, Stathaki M, Daskalakis M, Perisinakis K, et al. Sleeve gastrectomy: a restrictive procedure? *Obes Surg.* 2007;17(1):57-62. Epub 2007/03/16.
24. Parikh A, Alley JB, Peterson RM, Harnisch MC, Pfluke JM, Tapper DM, et al. Management options for symptomatic stenosis after laparoscopic vertical sleeve gastrectomy in the morbidly obese. *Surg Endosc.* 2012;26(3):738-46. Epub 2011/11/03.
25. Rosenthal RJ. International Sleeve Gastrectomy Expert P, Diaz AA, Arvidsson D, Baker RS, Basso N, et al. International Sleeve Gastrectomy Expert Panel Consensus Statement: best practice guidelines based on experience of >12,000 cases. *Surg Obes Relat Dis.* 2012;8(1):8-19. Epub 2012/01/18.
26. Santoro S. Technical aspects in sleeve gastrectomy. *Obes Surg.* 2007;17(11):1534-5. Epub 2008/01/26.
27. Sevcik WE, Steiner IP. Acute gastric volvulus: case report and review of the literature. *Cjem.* 1999;1(3):200-3. Epub 2007/07/31.
28. Stamou KM, Menenakos E, Dardamanis D, Arabatzis C, Alevizos L, Albanopoulos K, et al. Prospective comparative study of the efficacy of staple-line reinforcement in laparoscopic sleeve gastrectomy. *Surg Endosc.* 2011;25(11):3526-30. Epub 2011/06/04.
29. Triantafyllidis G, Lazoura O, Sioka E, Tzovaras G, Antoniou A, Vassiou K, et al. Anatomy and complications following laparoscopic sleeve gastrectomy: radiological evaluation and imaging pitfalls. *Obes Surg.* 2011;21(4):473-8. Epub 2010/07/24.
30. Trelles NG, Michel. Updated Review of Sleeve Gastrectomy. *The Open Gastroenterology Journal.* 2008;2:41-9.
31. Tutuian R. Obesity and GERD: pathophysiology and effect of bariatric surgery. *Current gastroenterology reports.* 2011;13(3):205-12. Epub 2011/03/23.
32. Wastell C, Ellis H. Volvulus of the stomach. A review with a report of 8 cases. *Br J Surg.* 1971;58(8):557-62. Epub 1971/08/01.
33. Zundel N, Hernandez JD, Galvao Neto M, Campos J. Strictures after laparoscopic sleeve gastrectomy. *Surgical laparoscopy, endoscopy & percutaneous techniques.* 2010;20(3):154-8. Epub 2010/06/17.