

**FIRST SINGLE-PORT LAPAROSCOPIC LIVER RESECTION IN BRAZIL***Hepatectomia laparoscópica com portal único: experiência pioneira no Brasil*Marcel Autran Cesar **MACHADO**, Rodrigo Cañada Trofo **SURJAN**, Fábio Ferrari **MAKDISSI**

From Syrio-Libanese Hospital, São Paulo, SP, Brazil.

**ABSTRACT – Introduction** - Since the past decade, minimal access surgery is moving towards minimizing the surgical trauma by reducing numbers and size of the laparoscopic ports. A novel technique with a single-incision laparoscopic approach has been recently described. **Aim** - To describe the single-port technique for laparoscopic liver resection. **Technique** - A transumbilical 3-cm skin incision is performed and a single-incision advanced access platform is introduced. Operation began with exploration of the abdominal cavity and ultrasound examination of the liver. Intrahepatic Glissonian access for retrieval of portal pedicles from segments 2 and 3 is performed. Vascular endoscopic stapler is used to divide segments 2 and 3 Glissonian pedicle. Liver is transected with harmonic scalpel and left hepatic vein is divided with stapler. Procedure is completed. Surgical specimen is retrieved through the single umbilical incision. No drains are left in place. **Conclusion** - Single port laparoscopic left lateral segmentectomy is feasible and can be safely performed in specialized centers by skilled laparoscopic surgeons.

**HEADINGS** - Liver. Techniques. Laparoscopy. Hepatectomy. Single-port.**Correspondence:**Marcel Autran Cesar Machado  
E-mail: dr@drmarcel.com.brFinancial source: none  
Conflicts of interest: noneReceived for publication: 04/02/2013  
Accepted for publication: 11/03/2013**DESCRITORES** - Fígado. Técnicas. Laparosopia. Hepatectomia. Portal único.

**RESUMO – Introdução** - Na última década, a cirurgia laparoscópica evoluiu e hoje produz menor trauma graças à redução do número e tamanho dos trocâteres. Recentemente nova técnica com uso de portal único foi descrita. **Objetivo** - Descrever os detalhes de uma segmentectomia lateral esquerda (segmentos 2 e 3) laparoscópica com portal único. **Técnica** - Portal único com cobertura de gel é introduzido por meio de incisão de 3 cm periumbilical. O procedimento inicia-se com exploração da cavidade com laparoscópio e exame ultra-sonográfico do fígado. É realizado Acesso intra-hepático ao pedículo Glissoniano dos segmentos 2 e 3. O pedículo é seccionado com grampeador com carga vascular. O fígado é seccionado com bisturi harmônico e a veia hepática esquerda é dividida com grampeador. A peça é retirada pelo portal único. A cavidade é revista mas não é deixado dreno. **Conclusão** - Segmentectomia lateral esquerda laparoscópica com portal único é procedimento seguro desde que realizado em centros especializados e por equipes com experiência em cirurgia hepática e laparoscopia avançada.

**INTRODUCTION**

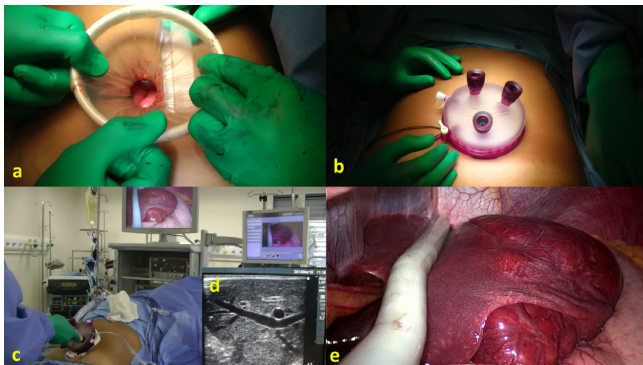
In the past decade, minimal access surgery is moving towards minimizing the surgical trauma by reducing numbers and size of the port. In the last few years, a novel technique with a single-incision laparoscopic approach has been described<sup>5</sup>. This technique is especially used in young female patients due to the splendid cosmetic results. In Brazil and also in some other countries, this technique has been mainly used for laparoscopic cholecystectomy<sup>12</sup>.

Liver surgery is an extremely challenging field, and surgical management of liver diseases continues to evolve. Laparoscopic liver resection is a reality and has been used by our group since 2007 with more than one hundred cases, including major liver resections<sup>8-11</sup>. The aim of this technical report is to describe our initial experience with single-port technique for laparoscopic liver resection. We present a single-port laparoscopic left lateral segmentectomy. To the best of our knowledge, this is the first single-port laparoscopic liver resection in Brazil and Latin America.

## TECHNIC

The patient is placed in a supine and reverse Trendelenburg position with surgeon between patient's legs. First assistant was on the right side of the patient with the monitor placed on the patient's cranial side. With the patient under general anesthesia, a transumbilical 3-cm skin incision was performed. A single-incision advanced access platform with gelatin cap, self-retaining sleeve and wound protector (GelPoint, Applied Med. R.S. Margarita, CA, USA) is introduced through this incision (Figure 1a). Three 5-10 mm were introduced through the single-port device. Due to the gel cap and sleeves, no articulated instruments are necessary. CO<sub>2</sub> pneumoperitoneum is established at 12-mm Hg. A rigid 30 degree 10mm laparoscope is introduced. This single port platform is able to accommodate at the same time three or four instruments with no triangulation prejudice depending on the configuration needed (Figure 1b). Two large instruments, such as a 10-mm laparoscope, a 12-mm flexible stapler can be used with a 5mm instrument. If only one large instrument, such as camera is needed this platform can accommodate four more 5 mm instruments. This is because our initial skin and aponeurosis opening are a 30 mm large.

Operation began with exploration of the abdominal cavity with the laparoscope. Intraoperative laparoscopic ultrasound probe (SonoSite, Inc., Bothell, WA, USA) is introduced and liver is examined for other lesions and to ascertain liver anatomy (Figures 1c, 1d, 1e). Once accomplished if that is no change in the initial

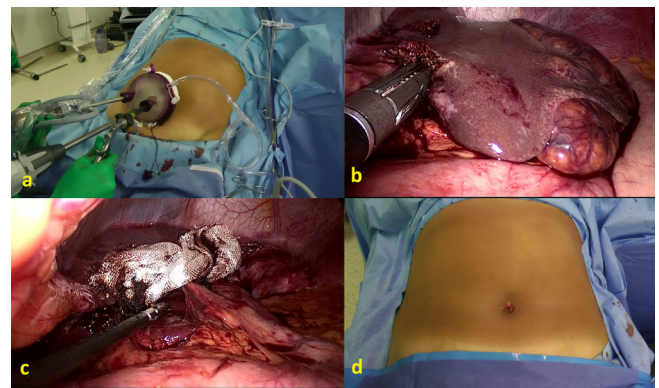


**FIGURE 1** - Single port platform set up. a) After 3cm skin incision at the level of umbilicus, self-retained sleeve and wound protector is inserted. b) Gelatin cap with three working ports are attached to the platform with three working (5 to 11mm) ports. c) Intraoperative ultrasound is performed through single port. A 30 degree 10 mm high definition laparoscope is used together with ultrasound probe. Note that there is no need for the use of a 5 mm laparoscope or flexible instruments. d) Intraoperative ultrasound shows the liver tumor and anatomy. e) Intraoperative view of liver and ultrasound probe.

planning, operation resumes. The left liver is mobilized by sectioning the falciform, left triangular, and coronary ligaments with harmonic scalpel (Ultracision, Ethicon Endo Surgery, Cincinnati, OH). Left lobe is pulled upward, and the lesser omentum is divided.

Next step is to perform intrahepatic Glissonian access for retrieval of portal pedicles from segments 2 and 3. Two incisions are needed. First incision is performed above proximal part of Arantius ligament and second incision at the basis of round ligament on its left side. This technique description was published elsewhere<sup>11</sup>. A large vascular clamp is introduced through these incisions and closed. After few moments ischemic delineation of segments 2 and 3 are obtained. Future line of transection is marked with cautery. Clamp is replaced by vascular endoscopic stapler (Figure 2a). Stapler is fired and portal pedicle from segments 2 and 3 are divided (Figure 2b). Liver transection progresses with harmonic scalpel. Last step is to divide left hepatic vein with stapler. Procedure is completed. Surgical specimen is put inside a plastic bag and retrieved through single port. Depending on the size of specimen, incision needs to be enlarged but usually left lateral segment can be retrieved through the 3-cm umbilical incision. Single-port platform is reattached and liver raw area is checked for bleeding and bile leaks. Hemostatic tissue is applied in the liver raw surface and procedure is finished (Figure 2c). No drains are left in place.

We have performed this procedure in one 33-year-old woman with liver adenoma. Duration of the procedure was 54 minutes. Bleeding was minimal with no need for transfusion. Patient was discharged in the first postoperative day. Cosmetic aspect of incision was excellent after procedure (Figure 2d).



**FIGURE 2** - Single-port laparoscopic left lateral segmentectomy: a) External view showing single port platform with 10 mm laparoscope, 10 mm vascular clamp and 12 mm endoscopic stapler. b) Internal view shows Glissonian pedicle occluded by the stapler resulting in ischemic delineation of the left liver (segments 2 and 3). c) Internal view after completion of single port laparoscopic left lateral segmentectomy. d) Final view of umbilical wound.

## DISCUSSION

Laparoscopy has become a less invasive alternative to liver surgery, and preoperative and intraoperative imaging advances resulted in better anatomic evaluation and thus better surgical planning.

Laparoscopic liver surgery has experienced significant development in the last years. Our experience with laparoscopic liver resections began in 2007<sup>8</sup>. Similarly as occurred in other centers, improvement of our expertise in advanced laparoscopic surgery has allowed us to perform more complex operations such as extended right hepatectomy, two-stage liver resection and even ALPPS procedure totally laparoscopic<sup>8-11</sup>.

However, only few centers, including ours, are performing laparoscopic liver resection on routine basis<sup>13</sup>. For several authors, only laparoscopic left lateral segmentectomy is considered a gold standard<sup>3</sup>. For us, any anatomical liver surgery can be done by laparoscopy, but we agree that it should be done by experts only<sup>8,13</sup>.

Single-incision laparoscopic procedure is less invasive than standard multiport laparoscopy but may have unique difficulties for the laparoscopic surgeon<sup>14,15</sup>. First, retraction is significantly limited. The introduction of a camera and several instruments parallel to each other may result in decreased range of motion and collision of instruments<sup>1,2,4</sup>. The single-incision platform used in our case allows the use of standard instruments with no loss of triangulation due to the presence of self-retaining sleeves which maximizes internal working diameter. We were able to use a high definition 10-mm laparoscope during all steps of the operation.

We have chosen to perform a laparoscopic left lateral segmentectomy by single port because this procedure is the easiest to perform laparoscopically and its technique is already standardized<sup>3</sup>.

In the English literature there are only few papers dealing with single-port liver resection<sup>6,7,14,15</sup>. The main reason is that the majority of systems available for single site laparoscopic surgery need special articulating instruments, use of small laparoscopes with poor triangulation. We believe that this new system may offer a better platform for single-incision surgery reducing learning curve for skill acquisition. Our initial experience with single port laparoscopic left lateral segmentectomy showed no exposure or triangulation difficulties and operative time was not superior to our other laparoscopic cases.

Although several issues such as costs and learning curve of this technique remain to be studied, the cosmetic benefits of single-incision approach are obvious<sup>15</sup>. In conclusion, single port laparoscopic left lateral segmentectomy is feasible and can be safely performed in specialized centers by skilled laparoscopic surgeons.

## REFERENCES

1. Aikawa M, Miyazawa M, Okamoto K, Toshimitsu Y, Okada K, Ueno Y, Yamaguchi S, Koyama I. Single-port laparoscopic hepatectomy: technique, safety, and feasibility in a clinical case series. *Surg Endosc* 2012; 26:1696-1701.
2. Aldrighetti L, Guzzetti E, Ferla G. Laparoscopic hepatic left lateral sectionectomy using the LaparoEndoscopic Single Site approach: evolution of minimally invasive liver surgery. *J Hepatobiliary Pancreat Sci.* 2011;18:103-5.
3. Azagra JS, Goergen M, Brondello S, Calmes MO, Philippe P, Schmitz B. Laparoscopic liver sectionectomy 2 and 3 (LLS 2 and 3): towards the "gold standard". *J Hepatobiliary Pancreat Surg* 2009;16:422-6.
4. Chang SK, Mayasari M, Ganpathi IS, Wen VL, Madhavan K. Single port laparoscopic liver resection for hepatocellular carcinoma: a preliminary report. *Int J Hepatol* 2011;2011:579203.
5. Canes D, Desai MM, Aron M, Haber GP, Goel RK, Stein RJ, Kaouk JH, Gill IS. Transumbilical single-port surgery: evolution and current status. *Eur Urol* 2008;54(5):1020-9
6. Dapri G, Dimarco L, Cadière GB, Donckier V. Initial experience in single-incision transumbilical laparoscopic liver resection: indications, potential benefits, and limitations. *HPB Surg* 2012;2012:921973.
7. Gaujoux S, Kingham TP, Jarnagin WR, D'Angelica MI, Allen PJ, Fong Single-incision laparoscopic liver resection. *Surg Endosc* 2011;25:1489-94. Y.
8. Machado MA, Makdissi FF, Surjan RC. Laparoscopic liver resection: personal experience with 107 cases. *Rev Col Bras Cir* 2012;39:483-8.
9. Machado MA, Makdissi FF, Surjan RC. Intrahepatic Glissonian approach for pure laparoscopic right hemihepatectomy. *Surg Endosc.* 2011; 25(12):3930-3.
10. Machado MA, Makdissi FF, Surjan RC. Totally laparoscopic ALPPS is feasible and may be worthwhile. *Ann Surg* 2012;256:e13.
11. Machado MA, Makdissi FF, Surjan RC, Herman P, Teixeira AR, C Machado MC. Laparoscopic resection of left liver segments using the intrahepatic Glissonian approach. *Surg Endosc.* 2009; 23:2615-2619.
12. Madureira FA, Manso JE, Madureira Fo D, Iglesias AC. Randomized clinical study for assessment of incision characteristics and pain associated with LESS versus laparoscopic cholecystectomy. *Surg Endosc* 2013;27:1009-15.
13. Nguyen KT, Gamblin TC, Geller DA. World review of laparoscopic liver resection-2,804 patients. *Ann Surg.* 2009;250:831-41.
14. Patel AG, Belgaumkar AP, James J, Singh UP, Carswell KA, Murgatroyd B. Single-incision laparoscopic left lateral segmentectomy of colorectal liver metastasis. *Surg Endosc* 2011;25:649-50.
15. Shetty GS, You YK, Choi HJ, Na GH, Hong TH, Kim DG. Extending the limitations of liver surgery: outcomes of initial human experience in a high-volume center performing single-port laparoscopic liver resection for hepatocellular carcinoma. *Surg Endosc* 2012;26:1602-8.