

## GIANT HEPATIC ADENOMA ASSOCIATED WITH ANABOLIC-ANDROGENIC STEROID ABUSE: CASE REPORT

*Adenoma hepático gigante associado com uso abusivo de esteróide androgênico anabolizante: relato de caso*

Sergio Renato **PAIS-COSTA**, Olímpia Alves Teixeira **LIMA**, Aloisio Fernandes **SOARES**

From Regional Hospital of the Northern Zone (HRAN), Brasília, Federal District, Brazil

### Correspondence:

Sergio Renato Pais-Costa,  
e-mail srenatopaiscosta@hotmail.com

Financial source: none  
Conflicts of interest: none

Received for publication: 09/04/2012  
Accepted for publication: 27/04/2012

## INTRODUCTION

**H**epatic adenoma (HA) is an uncommon primary benign neoplasm of hepatocellular origin that most frequently affects young women. It has generally been associated with use of oral contraceptives. Glycogen storage disease has also been associated with development of HA and in such cases, it is also more likely to be multiple and to undergo malignant transformation. HA may be also found in association with other conditions such as diabetes mellitus, pregnancy, Fanconi anemia, Hurler disease, familial adenomatous polyposis and tyrosinemia<sup>3,5,6,9,13</sup>. More rarely, HA has been associated with abusive use of anabolic-androgenic steroids (AAS), mainly among bodybuilders<sup>8,11,12</sup>.

Most of these tumors are detected incidentally by means of imaging examinations such as ultrasound or other scanning techniques. Others because of hepatomegaly, right upper quadrant discomfort, pain, compression of neighboring organs, or intraperitoneal hemorrhage. The diagnosis is sometimes established only during intraoperative exploration<sup>3,5,6,9,13</sup>. Tumor rupture is frequently observed in bulky tumors, and this occurrence presents high mortality<sup>9,13</sup>. HA has also been associated with malignant transformation. This association has also been observed in large tumors<sup>6,9</sup>.

The preferred treatment is surgical resection by means of guided hepatectomy or enucleation. This is the approach of choice for symptomatic patients or even for large tumors > 5 cm<sup>13</sup>. Today, the laparoscopic approach has become the gold standard because it

provides low morbidity, fast recovery and cosmetic advantages<sup>1,4,7</sup>. However, for treating large lesions, especially when they are close to major vascular structures, an open approach is safer<sup>4,7</sup>.

## CASE REPORT

A 28-year-old male bodybuilder was referred because of the appearance of abdominal pain in the right upper quadrant over the preceding three months. The patient reported that he had been taking AAS for the last six years (oral androstenedione and intramuscular nandrolone). Clinical examination of the abdomen revealed a painful, palpable mass with regular margins of about 6-8 cm in diameter located in the upper right quadrant. This mass was seen to be mobile as the patient breathed.

Laboratory functional tests were within normal limits. Tests for hepatitis B surface, anti-HBs and anti-hepatitis C antibodies were negative. Tests for serum tumor markers (CEA, CA 19-9 and alpha-fetoprotein) were also negative. Moreover, the laboratory and serological tests ruled out the presence of liver abscesses, amebae or hydatid cysts.

Abdominal computed tomography (CT) showed a voluminous lesion measuring 101x81x56 mm that was located in hepatic segment VII, very close to the right hepatic vein, and extending to hepatic segments VI and VIII (Figure 1). The lesion was well defined, showing dyshomogenous density with irregular enhancement in the arterial phase and washout in the late phase. The CT findings suggested that the lesion was a giant hepatic adenoma. This diagnostic hypothesis was confirmed by means of fine-needle biopsy.

The patient underwent open resection. Bilateral subcostal incision with median upper prolongation ("Mercedes-Benz" incision) was performed. A voluminous hepatic lesion involving segments VI-VII and extended a little into hepatic segment VII was found.

Intraoperative examination also showed another similar lesion of 2 cm in diameter in hepatic segment IV (Figure 2). There was an attempt to enucleate the mass from the surrounding liver parenchyma. However, since the mass was very soft and bleeding readily, and it

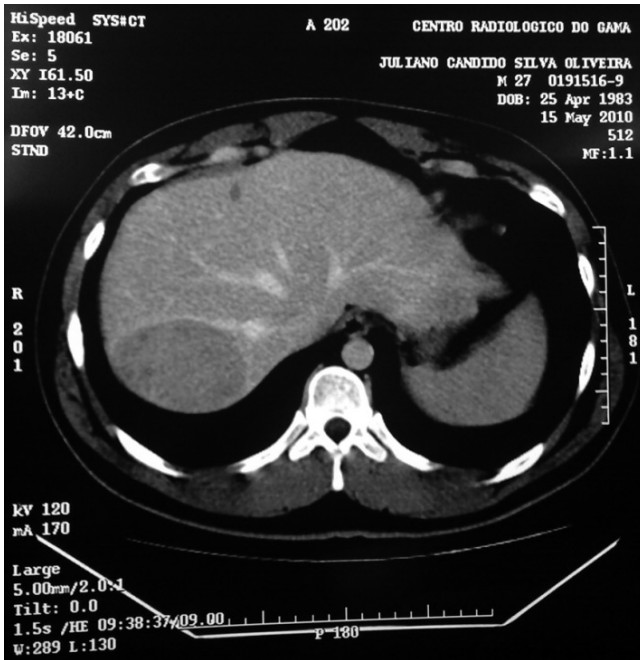


FIGURE 1 - CT scan showing large solid lesion in posterior sector of right hepatic lobe

was still closely adhering to the right diaphragm, right hepatic vein and voluminous tributary of the middle hepatic vein, guided right hepatectomy was carried out. Since total mobilization of right lobe seemed hazardous, was preferred to perform right hepatectomy by means of an anterior approach as described by Capussotti et al.<sup>2</sup>. To treat the lesion in segment IV, simple enucleation was performed.

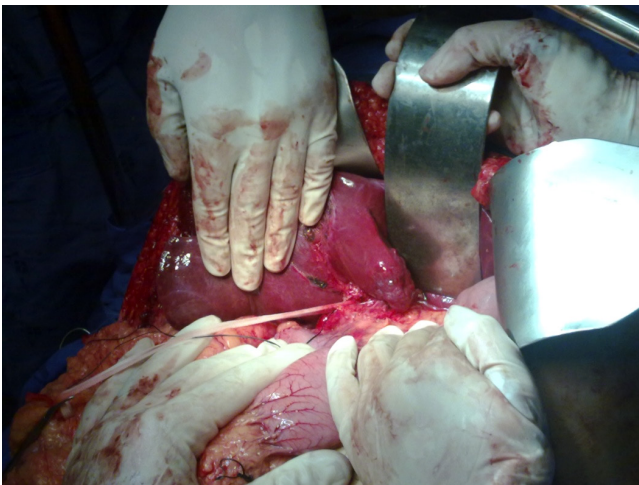


FIGURE 2 – Small hepatic adenoma in segment IV

The main specimen measured 10x7x5 cm, while the secondary specimen measured 2x1x1 cm. The mass presented well circumscribed margins and a smooth external surface. It was a green-brown colored tumor with hemorrhagic areas. The surrounding liver tissue was normal.

Microscopic examination showed the presence of mature vacuolated hepatocytes. No portal or biliary structures were present, which confirmed that both lesions were HA. The bigger one presented hemorrhagic foci, but neither of them presented any signs of malignant transformation. The patient was kept in the intensive care unit for one day. He did not receive any blood transfusions. No signs of liver failure were recorded, and the patient was discharged on the eighth day after the operation, after removing the J-P drains. Following the surgery, the patient stopped taking AAS and an ultrasound follow-up examination six months after the operation did not show any presence of further focal lesions.

## DISCUSSION

HA pathogenesis seems obscure, but has been associated with the use of both oral contraceptives and AAS<sup>3,5,6,8,9,10,11,12,13</sup>. In recent times, AAS has frequently been used both recreationally and professionally. Although more than 750 cases of oral contraceptive-induced HA have been reported, it seems that AAS-induced HA is relatively rare. It may be that cases of AAS-induced HA have been underreported. However, the possibility that oral AAS such as stanozolol may induce liver cell proliferation must be taken into account<sup>12</sup>.

More often than not, patients with HA have no symptoms and therefore are only incidentally diagnosed by radiological methods. However, large tumors like in the present case may cause anemia because of tumor bleeding or abdominal distress due to pain in the upper abdominal quadrants<sup>3,5,6,9,13</sup>. Sometimes, large HA may lead to spontaneous rupture or hemorrhage and, in certain cases, even death. The chance of rupture is far from negligible (15-33%) and may be associated with high mortality, especially in cases of emergency surgery (5-10%). Although malignant transformation is uncommon, it has been associated with large or multiple HA<sup>3,6,9,13</sup>.

The tumor markers are generally not elevated, as shown in the case reported here. However, if malignant transformation occurs, the alpha-fetoprotein levels may rise. In cases of rupture, GGT and alkaline phosphatase levels may rise. Therefore, radiological diagnosis is the most important method. Ultrasound, CT and magnetic resonance imaging (MRI) of the abdomen are usually important for making the diagnosis. HA is a vascular tumor with predominant arterial supply in classic cases. The findings consist of well-vascularized and well-defined solid lesions that are predominantly in an arterial phase on CT or MRI. The lesions are sometimes dyshomogeneous, as in the present case, especially if hemorrhage is present. Cystic areas are also found, and there may even be free liquid in the abdominal cavity, due to rupture<sup>3,5,13</sup>.

One of the problems that HA presents is the

differential diagnosis with hepatocellular carcinoma (HCC) or even with vascularized metastasis. In fact, the radiological findings from patients with HA are often similar to those from patients with HCC. In cases in which clinical, radiological and histological distinctions between HA and HCC are difficult to determine, surgical resection has been advised, whenever possible<sup>3,5,6,9,11,12,13</sup>. Cytological evaluations may be performed using material obtained by means of fine-needle puncture-aspiration (FNPA), in order to confirm the diagnosis. This procedure has been recommended by some authors. However, there is a risk of hemorrhage<sup>3,5,6,8,9,10,11,12,13</sup>. In the present case, FNPA was important for confirming the HA diagnosis.

Conservative management may be generally used in cases of small HA, especially those relating to the use of oral contraceptives or AAS<sup>13</sup>. In cases of AAS-induced HA, ceasing to use the AAS may sometimes reduce the lesion. Rigorous follow-up by means of radiological examinations (ultrasound or CT) every six months is absolutely necessary<sup>12</sup>. However, when the lesion is large (> 5 cm) or symptomatic like in the present case, surgical treatment has been recommended because of the high risk of hemorrhage and malignant transformation<sup>3,5,6,8,9,10,11,12,13</sup>. The surgical option depends on case-by-case assessment. For small superficial lesions, as observed in the present case in segment IV, tumor enucleation is enough. However, for deep lesions that are close to large vascular structures, and for voluminous lesions like the one observed in the present case in segments VII-VI, straightforward hepatectomy with vascular control is advised, in order to avoid severe intraoperative bleeding<sup>2,3,5,6,9,13</sup>. Although laparoscopic hepatectomy is a good option for benign tumors like HA, an open approach is safer for large difficult-to-deal-with posterior lesions, especially those that are very close to important vascular structures, as seen in the present case<sup>1,4,7</sup>.

Whenever possible, some authors have used liver-sparing parenchymal resection, particularly for benign tumors like HA.<sup>4</sup> Right posterior sectionectomy may be performed on small posterior lesions of the right lobe, with the aim of preserving the liver parenchyma. However, in the present case, because the lesion was very large and difficult to deal with, with a high risk of severe intraoperative hemorrhage, was preferred an open approach with guided right hepatectomy.

When AAS-induced HA is well managed by means of resection, the overall prognosis is good. However, when conservative management is chosen, rigorous monitoring using radiological methods is advisable because of both the risk of rupture and the risk of malignant transformation. Recurrence is possible, especially if patients keep on using or go back to using AAS. Even for operated patients, there needs to be follow-up through regular medical visits and radiological examinations<sup>3,5,6,8,9,10,11,12,13</sup>.

## REFERENCES

1. Ardito F, Tayar C, Laurent A, Karoui M, Loriau J, Cherqui D. Laparoscopic Liver Resection for Benign Disease. *Arch Surg* 2007; 142 (12): 1188-93.
2. Capussotti L, Ferrero A, Sgotto E, Vigano L, Muratore A, Polastri R. Right hepatectomy with anterior approach for ruptured liver cell adenoma. *Hepatogastroenterology* 2007; 54(77): 1557-9.
3. Choi BY, Nguyen MH. The Diagnosis and Management of Benign Hepatic Tumors. *J Clin Gastroenterol* 2005; 39(5): 401-12.
4. Costa SRP, Araujo SM, Lima AOT, Chartuni ATP. Laparoscopic Right Posterior Sectionectomy for Treating Hepatic Tumors. *ABCD Arq Bras Cir Dig* 2010; 23(4): 275-9.
5. Grazioli L, Federle MP, Brancatelli G, Ichikawa T, Olivetti L, Blachar A. Hepatic adenomas: imaging and pathologic findings. *Radiographics*. 2001; 21: 877-92.
6. Herman P, Pugliese V, Machado MAC, Montagnini AL, Salem MZ, Bachella T et al. Hepatic Adenoma and Focal Nodular Hyperplasia: Differential Diagnosis and Treatment. *World J Surg* 2000; 24(5): 372-76.
7. Herman H, Coelho FF, Lupinacci RM, Perini MV, Machado MAC, D'Albuquerque LAC, Ceconello I. Ressecções Hepáticas por Videolaparoscopia. *ABCD Arq Bras Cir Dig* 2009; 22(4): 226-32.
8. Martin NM, Dayeh BKA, Chung RT. Anabolic abuse causing recurrent hepatic adenomas and hemorrhage. *World J Gastroenterol* 2008; 14(28): 4573-5.
9. Ribeiro Junior MAF, Chaib E, Saad WA, D'Albuquerque LAC, Ceconello I. Surgical management of spontaneous ruptured hepatocellular adenoma. *Clinics*. 2009; 64(8): 775-9.
10. Sandonato L, Cipolla C, Graceffa G, Bartolotta TV, Petri SL, Ciaccio O et al. Giant hepatocellular adenoma as cause of severe abdominal pain: a case report. *Journal of Medical Case Reports* 2007; 1(57): 1-4.
11. Soe KI, Soe M, Gluud S. Liver pathology associated with the use of anabolic-androgenic steroids. *Liver* 1992; 12: 73-79.
12. Socas L, Zumbado M, Pérez-Luzardo O, Ramos A, Pérez C, Hernández JR et al. Hepatocellular adenomas associated with anabolic androgenic steroid abuse in bodybuilders: a report of two cases and a review of the literature. *Br J Sports Med* 2005; 39: 1-4.
13. Tervikatan T, de Wilt JH, de Man RA. Indications and Long-term outcome of treatment for benign hepatic tumors: a critical appraisal. *Arch Surg* 2001; 136: 1033-38.