

DISCUSSION

HA is a rare condition, and is commonly associated with oral contraceptive use⁶. The longer women uses oral contraceptives with increased estrogen level, the higher is the chance to develop hepatocellular adenomas. It's frequently seen in woman in childbearing age, as well as in men and diseases like hemochromatosis and type 1 glycogen storage disease⁴. It has clinical importance because of the risk of complications. Spontaneous rupture is the most important complication and usually happens in adenomas greater than 5 cm, in 20-40% of the cases⁴.

Approximately 10% of patients with HA present with acute abdominal pain due to rupture and hemoperitoneum, in some cases followed by hipovolemic shock. Patients might also refer nausea, vomiting, anorexia and fever. Mortality in ruptured HA has been associated with late diagnosis, coagulopathy and post-operative complications⁸.

Conservative treatment is used to small adenomas, mainly the ones related to oral contraceptives and anabolic steroids. The follow up in these cases includes abdominal TC or ultrasound each six months. Although, when the adenoma is higher than 5cm or show symptoms, the surgical treatment is recommended because of the increased risk of hemorrhage and malignant transformation⁶.

The surgical treatment vary on the case, as well as the different approaches of liver resection. The standard treatment for ruptured HA must be local or segmental resections, to spare as much liver parenchyma as possible. Laparoscopic hepatectomy is a feasible option for benign liver lesions in elective cases^{1,2}, but when it comes to ruptured, the open laparotomy is preferred due to bleeding and close contact to important liver vessels. Patients with ruptured HA must have elective resections when possible. There are several procedures to avoid emergency treatment but surgery still remains the main approach. If patient is stable and the tumor is localized in one segment, partial hepatectomy should be promptly made, but if there is important blood loss, volemic reposition with fluids and transfusions of hemocomponents should be attempted as well as arterial embolization¹⁰, with late resection when patient is stable. The selective arterial embolization have been playing an important role in the treatment of ruptured and non-ruptured HA, with low complication rates when compared with emergency surgery⁷. Arterial embolization is a very expensive procedure and is not available in most centers.

REFERENCES

1. Ardito F, Tayar C, Laurent A, Karoui M, Loriau J, Cherqui D. Laparoscopic Liver Resection for Benign Disease. Arch Surg 2007; 142 (12): 1188-93
2. Costa SRP, Araujo SM, Lima AOT, Chartuni ATP. Laparoscopic Right Posterior Sectionectomy for Treating Hepatic Tumors. ABCD Arq Bras Cir Dig 2010; 23(4): 275-9.
3. Deodhar A, Brody LA, Covey AM, Brown KT, Getrajdman GI. (2011) Bland embolization in the treatment of hepatic adenomas: preliminary experience. J VascIntervRadiol22:795-799;
4. Dokmak et al, 2009. Dokmak S, et al: A single center surgical experience of 122 patients with single and multiple hepatocellular adenomas. Gastroenterology 2009; 137:1698-1705.
5. Eckhauser FE, Knol JA, Raper SE, Thompson NW. Enucleation combined with hepatic vascular exclusion is a safe and effective alternative to hepatic resection for liver cell adenoma. Am Surg. 1994;60:466-71.

6. Herman P, Pugliese V, Machado MAC, Montagnini AL, Salem MZ, Bachella T et al. Hepatic Adenoma and Focal Nodular Hyperplasia: Differential Diagnosis and Treatment. World J Surg 2000; 24(5): 372-76
7. Huurman VA, Stoot JH, van der Linden E, Terpstra OT, Schaapherder AF. Necrosis of a large hepatic tumor after hemorrhage and subsequent selective arterial embolization. World J Gastroenterol. 2006;12:6059-61.
8. Marini et al, 2002. Marini P, et al: Management of spontaneous rupture of liver tumours. Dig Surg 2002; 19:109-113.
9. Puech A, Pages A, Dermenghem M, Seignalet J. (1964) Multinodular Adenoma of the Liver. Montp Med 65:114-119. Ad'enomemultinodulaire du foie.
10. Terkivatan et al, 2001. Terkivatan T, et al: Treatment of ruptured hepatocellular adenoma. Br J Surg 2001; 88:207-209.

ABCDDV/1154

ABCD Arq Bras Cir Dig Letter to the Editor
2015;28(4):299

DOI: /10.1590/S0102-6720201500030023

RIGHT-SIDED BOCHDALEK HERNIA IN ADULT ASSOCIATED WITH CHOLESTATIC SYNDROME: CASE REPORT

*Hérnia de Bochdalek à direita em adulto, associada à
síndrome colestática: relato de caso*

José Moreira dos **SANTOS-NETTO**, Cássio Virgílio
Cavalcante **OLIVEIRA**, Marcelo Gonçalves **SOUSA**

From the Departamento de Cirurgia, Centro de Ciências Médicas, Universidade Federal da Paraíba, Hospital Universitário Lauro Wanderley (Department of Surgery, Lauro Wanderley University Hospital), João Pessoa, PB, Brazil.

Financial source: none
Conflicts of interest: none

Correspondence:

José Moreira dos Santos Netto
Email: moreira_netto@hotmail.com

Received for publication: 22/01/2015
Accepted for publication: 16/06/2015

INTRODUCTION

The congenital diaphragmatic hernia (CDH) is defined as an anatomical defect on diaphragm, which permits the herniation of abdominal viscera into the thorax⁴. The hernia occurs due to an incomplete occlusion of the pleuroperitoneal channel during the embryonic period. The main cause of the incomplete closure can be a genetic mutation, a teratogen or both.

In terms of anatomic location, the CDH can be classified as Bochdalek type when an incomplete pleuroperitoneal channel occlusion is found posterolaterally; as Morgagni type, while the defect is seen retrosternally; and yet as a congenital transhiatal esophageic type hernia. Among them, the Bochdalek type is the most common, found in 78-90% of patients; the Morgagni type, in 1,5-6% of cases; and transhiatal, 14-24%¹¹.

In most cases, the clinical impact occurs in the neonatal period, since only 10% of hernias are diagnosed after this period⁷. In neonates, the clinical presentation is acute, providing a higher morbidity and mortality. In adulthood, symptoms, if any, are more insidious, vague and intermittent, affecting not

only the pulmonary dynamics, but also the gastrointestinal function⁵.

Chest X-ray and CT scan may be used^{2,8,12}. Nevertheless, CDH findings are incidental when performing radiological examinations for other reasons, with the right-sided Bochdalek hernia accounting for 68% of cases.^{9,13}

In elective situations, the minimally invasive surgery, either via laparoscopic or thoracoscopic can be used, but with limited application in cases of right-sided hernia^{3,8}. Minor defects, technically easier to fix, can be sutured normally; in the case of larger apertures, or even hemidiaphragmatic agenesis, the use of nonabsorbable polypropylene mesh is the only solution.

CASE REPORT

A forty-five-year-old woman, caucasian, married, admitted into our service, complains of insidious jaundice in the previous five months, associated with itching, choloria and abdominal distension. Eight months before, the patient had a spontaneous abortion during the fourth month of pregnancy. Reported history of cranial malformation at birth, duly corrected surgically.

The patient was underwent to serological laboratory tests for viral hepatitis, resulting all negative. The serum total bilirubin was 4.3 mg/dl due to direct fraction, and creatinine was 1.7 mg/dl. During ultrasound exam, it was shown dilatation of intrahepatic bile ducts and liver enlargement, mainly of the right hepatic lobe. Computed tomography with contrast revealed the partial absence of diaphragmatic dome in the right posterolateral portion, showing an herniation of the right hepatic lobe, the right kidney and right adrenal gland, associated with marked atrophy of the left hepatic lobe and right pulmonary hypoplasia.

The patient was initially submitted to laparotomy which showed massive hepatomegaly due to the right lobe, whose edge was at the level of the umbilicus scar. Due to the great technical difficulties, thoracophrenolaparotomy was conducted, which showed failure at right diaphragm dome of approximately 10 cm (Figure 1), herniation of the hepatic lobe, kidney, right adrenal, colon, associated to a partial twist of the common bile duct and dilatation of the biliary tract upstream and excessive lateral traction of first and second portions of duodenum, and of the head of the pancreas.

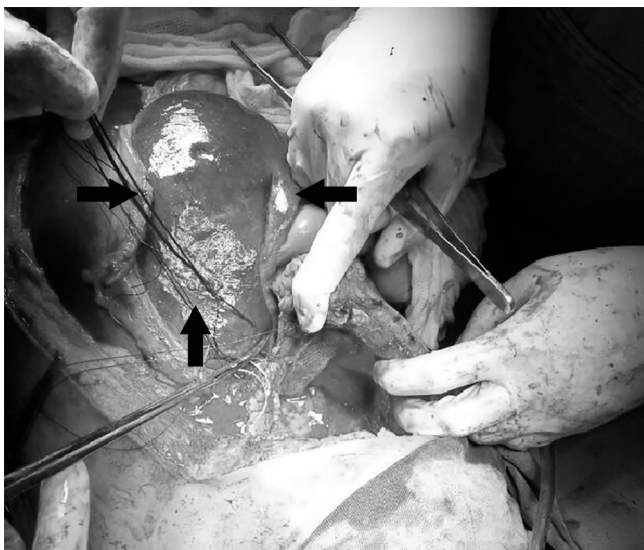


FIGURE 1 - Intraoperative registry of the diaphragmatic opening (among black arrows)

Posteriorly, the reduction of the hernia contents back into the abdominal cavity was done, with subsequent apposition of polypropylene mesh over the hernia defect and drainage of the chest. Intraoperative cholangiography was performed demonstrating recanalization of the bile duct and satisfying contrast escape into the duodenum.

The postoperative period went on with normalization of bilirubin and renal function. The patient died weeks later due to nosocomial pneumonia and sepsis during hospitalization in intensive care unit.

DISCUSSION

The CDH incidence in general population varies between 2.5-3.8 cases per 10,000 births. There is some difficulty in establishing the prevalence of herniated Bochdalek in adults. A retrospective study of more than 13,000 CT scans of the abdomen showed a prevalence of about 0.17%. Other studies, however, agree with a greater prevalence, at about 6-12%, when computed tomography multislice is used^{9,13}.

Studies have found that there is a lower risk of afrodescendent population being CDH carrier, compared to non-hispanic caucasians. There is a relative risk of 50% higher in children of mothers aged over 35, compared to maternal age between 20-24 years⁴. In this case, the patient is a caucasian descendent; however, maternal age at birth was 23 years.

Retrospective study of 116 cases between 1991 and 2002 in Australia, found a prevalence of 46.6% of clinically significant abnormalities, and 38.8% minimum clinically significant abnormalities, being the most frequent neurological, musculoskeletal, dysmorphic, genitourinary and gastrointestinal¹. In this report above, it was mentioned history of cranial malformation, unspecified by the patient.

The left-sided Bochdalek hernia is more prevalent than the right one, because the right-sided dome develops earlier and the liver avoids abdominal viscera protrusion^{2,11}. However, hernias during the adulthood through the right dome are more frequent, appearing incidentally in 68% of diagnoses and affects mostly the females¹³.

The herniary defect varies from 1 cm of diameter until the complete absence of hemidiaphragm⁸. It was shown during the surgical procedure a diaphragmatic defect of approximately 10 cm in its largest diameter in the right posterolateral portion. In 20% of cases there is an hernial sac, in contrast to the majority of cases where there is a direct communication between the thoracic and abdominal cavities⁸. In 73% of cases, diaphragmatic hernia contains only visceral fat or omentum⁷. In the discussed case, it was not found an intraoperatively evidence of hernial sac.

Most CDH are diagnosed during the neonatal period, with only 10% of them discovered after this period⁷. The symptoms in adults are usually insidious and undefined. They can be not only gastrointestinal symptoms, such as nausea, postprandial vomiting, abdominal pain, back pain, post-prandial bloating; but also respiratory complaints, such as dyspnea, chest pain, shoulder referred pain^{5,8}. On physical examination, auscultation of typical bowel sounds of peristalsis is a specific signal for diaphragmatic hernia². Specifically in this related case, the patient denied any symptoms throughout the life, looking for medical care because of a recent jaundice.

In distinction to the reality presented in this case, the most common acute complication, and the most feared, is the hernial incarceration and/or strangulation. The risk of strangulation in the right side is smaller, since the hernial orifice is generally larger than the contralateral side⁵. Some factors that increase intra-abdominal pressure, such as pregnancy, labor, coughing, sneezing and trauma may increase the risk

REFERENCES

of hernial content strangulation^{5,13}. During the anamnesis of this patient, there are reports of pregnancy, with subsequent abortion three months before the beginning of cholestatic syndrome, a process that may have influenced the increase of the intra-abdominal pressure, twisting of the bile duct and appearance of jaundice.

Different modalities of diagnostic imaging can be used, among which chest x-ray, ultrasound, computerized tomography, magnetic resonance. The sensitivity of chest x-ray is 70% and is not specific enough to exclude the diagnosis of Bochdalek hernia in case of negative result^{2,8}. The gold standard for diagnosing is the double contrast tomography². During the investigation of jaundice of the case in discussion, it was decided to request ultrasound and abdominal CT with contrast; after diagnosis, there was a complementation with chest tomography.

In urgent cases, the recommended treatment is open surgery with initial abdominal approach, applying for the thoracic via in cases of technical difficulty^{5,8}. In elective situations, minimally invasive surgery, either via laparoscopic and/or videothoroscopic can be used, but with limited application in cases of right-sided hernia^{3,8}.

Minor defects, technically easier to fix, can be normally sutured; in situations of larger apertures, or even hemidiaphragmatic agenesis, the use of nonabsorbable mesh is the only way². If large hernia has been reduced, the intra-abdominal pressure should be intensively monitored postoperatively in order to prevent the appearing of abdominal compartment syndrome⁸. The postoperative recurrence rate is considered rare⁴.

1. Colvin J, Bower C, Dickinson JE, Sokol J. Outcomes of congenital diaphragmatic hernia: a population-based study in Western Australia. *Pediatrics* 2005; 116: e356-63
2. Esmer D, Alvarez Tostado J, Alfaro A, Carmona R, Salas M. Thoracoscopic and laparoscopic repair of complicated Bochdalek hernia in adult. *Hernia*
3. Fraser JD, Craft RO, Harold KL, Jaroszewski DE. Minimally invasive repair of a congenital right-sided diaphragmatic hernia in an adult. *Surg Laparosc Endosc Percutan Tech* 2009;19:5-7
4. Gaxiola A, Varon J, Valladolid G. Congenital diaphragmatic hernia: an overview of the etiology and current management. *Acta Paediatr*. 2009, Apr. 98(4):621-7.
5. Kanazawa A, Yoshioka Y, Inoi O, Murase J, Kinoshita H. Acute respiratory failure caused by an incarcerated right-sided adult Bochdalek hernia: report of a case. *Surg Today* 2002;32:812-15
6. Laaksonen E, Silvasti S, Hakal T. Right-sided Bochdalek hernia in an adult: a case report. *J Med Case Reports*. 2009;3:92912
7. Lee EJ, Lee SY. Fluid shift on chest radiography: Bochdalek hernia. *CMAJ* 2010; 182: E311-2.
8. Losanoff JE, Sauter ER. Congenital posterolateral diaphragmatic hernia in an adult. *Hernia* 2004;8:83-5
9. Mullins ME, Stein J, Saini SS, Mueller PR. Prevalence of incidental Bochdalek's hernia in a large adult population. *AJR Am J Roentgenol* 2001;177:363-6
10. Owen ME, Rowley GC, Tighe MJ, Wake PN. Delayed diagnosis of infarcted small bowel due to right-sided Bochdalek hernia. *Ann R Coll Surg Engl* 2007;89:W1-2
11. Robinson PD, Fitzgerald DA. Congenital diaphragmatic hernia. *Paediatr Respir Rev* 2007;8:323-35.
12. Rout S, Foo FJ, Hayden JD, Guthrie A, Smith AM. Right-sided Bochdalek hernia obstructing in an adult: case report and review of the literature. *Hernia* 2007;11:359-62
13. Rout S, Foo FJ, Hayden JD, Guthrie A, Smith AM. Right-sided Bochdalek hernia obstructing in an adult: case report and review of the literature. *Hernia* 2007;11:359-62
14. Temizoz O, Genc, hellac, H, Yekeler E, et al. Prevalence and MDCT characteristics of asymptomatic Bochdalek hernia in adult population. *Diagn Interv Radiol* 2010;16:52-5.
15. Yang W, Carmichael SL, Harris JA, Shaw GM. Epidemiologic characteristics of congenital diaphragmatic hernia among 2.5 million California births, 1989-1997. *Birth Defects Res A Clin Mol Teratol* 2006; 76: 170-4