

ANGIOGRÁFIC AND PRESSORIC CHANGES DETERMINED BY SPLENECTOMY WITH LEFT GASTRIC VEIN LIGATURE IN MANSONI SCHISTOSOMIASIS

Alterações angiográficas e pressóricas determinadas pela esplenectomia e ligadura da veia gástrica esquerda em portadores de esquistossomose mansônica

Fernanda Maria Fernández **PEREIRA**, João **EVANGELISTA-NETO**, Norma **BRITO**,
Fernando **AMARAL**, Olival Cirilo Lucena da **FONSECA-NETO**, Cláudio Moura **LACERDA**

From the Serviço de Cirurgia Geral e Transplante Hepático, Hospital Universitário Oswaldo Cruz, Universidade de Pernambuco, Recife, PE, Brazil

ABSTRACT - Background: In hepatosplenic schistosomiasis occurs diffuse hepatic fibrosis associated with venous congestion of the portal system resulting in hepatosplenomegaly. It can produce digestive hemorrhage caused by rupture of esophageal and stomach varices or peptic gastroduodenal mucosal lesions. **Aim:** To study the effects of splenectomy and ligature of the left gastric vein on portohepatic hemodynamics. **Method:** Twenty-three patients with hepatosplenic schistosomiasis mansoni were studied before and about two weeks after operation through angiographic diameter of the common and proper hepatic artery, splenic artery, superior mesenteric artery, portal vein, superior mesenteric vein and left gastric vein. The pressures of the inferior vena cava and central venous pressure, free hepatic vein, the hepatic sinusoidal and occluded vein were measured. **Results:** The splenectomy and ligature of the left gastric vein determined low morbidity and null mortality. It determined significant addition to the following variables: diameters of the common and proper hepatic artery; diameter of the superior mesenteric vein. It determined non significant increase on the following measurements: right atrial pressure and diameter of the superior mesenteric artery. It determined non significant decrease to the following variables: inferior vena cava pressure; free hepatic vein pressure; occluded hepatic vein pressure; sinusoidal pressure, diameter of the portal vein. **Conclusion:** Splenectomy and ligature of the left gastric vein do not determine portal hemodynamic changes capable of breaking the functional hemodynamic balance that characterizes the hepatosplenic mansoni schistosomiasis.

HEADINGS - Mansoní Schistosomiasis. Portal hypertension. Portal hemodynamics. Esplenectomy. Left gastric vein.

Correspondence:

Olival Cirilo Lucena da Fonseca Neto
E-mail: olivalneto@globo.com

Financial source: none
Conflicts of interest: none

Received for publication: 06/05/2013
Accepted for publication: 08/08/2013

DESCRIPTORES - Esquistossomose mansônica. Hipertensão porta. Hemodinâmica portal. Esplenectomia. Veia gástrica esquerda.

RESUMO - Racional: Na esquistossomose mansônica na forma hepatoesplênica ocorre fibrose hepática difusa que associada à congestão venosa do sistema porta resulta em hepatoesplenomegalia. Pode produzir hemorragia digestiva alta por rotura das varizes de esôfago e do estômago ou lesões pépticas da mucosa gastroduodenal. **Objetivo:** Estudar os efeitos da esplenectomia e ligadura da veia gástrica esquerda sobre a hemodinâmica portohepática. **Método:** Vinte e três portadores de esquistossomose mansônica na forma hepatoesplênica foram estudados prospectivamente, antes e cerca de duas semanas após a operação, através de estudos angiográficos dos diâmetros da artéria hepática comum e própria, artéria esplênica, artéria mesentérica superior, veia porta, veia mesentérica superior e veia gástrica esquerda. Foram aferidas as pressões da veia cava inferior, venosa central, da veia hepática livre, da veia hepática ocluída e sinusoidal. **Resultados:** A ligadura da veia gástrica esquerda determinou acréscimo significativo nas seguintes variáveis: diâmetros da artéria hepática comum e própria; diâmetro da veia mesentérica superior; o acréscimo não foi significativo nas seguintes medidas: pressão venosa central e diâmetro da artéria mesentérica superior. Ela promoveu decréscimo não significativo nas variáveis: pressão da veia cava inferior; pressão da veia hepática livre; pressão da veia hepática ocluída; pressão sinusoidal; diâmetro da veia porta. **Conclusão:** A ligadura da veia gástrica esquerda, na maioria dos casos, não determina alterações hemodinâmicas significantes do sistema porta capazes de quebrar o equilíbrio hemodinâmico funcional, que caracteriza a esquistossomose mansônica na forma hepatoesplênica.

INTRODUCTION

The prevalence of schistosomiasis in Brazil is a controversial issue. Recent data suggest a decline in serious forms of the disease, but Pernambuco is one of the States in Brazil with a medium to high prevalence of the infection. City-dwellers have been found to have been contaminated in the swamplands surrounding big cities and in even in summer holiday resorts. Mansonic schistosomiasis therefore remains a public health problem in Brazil. In the hepatosplenic mansoni schistosomiasis (HSS) diffuse Symmers hepatic fibrosis occurs, which, when combined with congestion of the portal system veins, leads to hepatosplenomegaly. These patients have hemorrhage of the upper digestive tract due to varices rupture on the esophagus and stomach or peptic ulcers in the gastroduodenal mucosa²⁻¹²

In HSS, presinusoidal blockage and hyperflow resulting from splenomegaly are the determining causes of portal hypertension. This model is characterized by functional-hemodynamic equilibrium with preservation of the flow of blood to the liver⁶.

Splenectomy and ligation of the esophageal varices (SLEV) reduces the caliber of the portal vein, increases the caliber of the hepatic artery and causes slightly heightened sinusoidal pressure. In 15% of cases, after surgery, portal blood is diverted through the left gastric vein causing arterialization of the liver and sinusoidal pressure, with a pattern of hemodynamics similar to that of late poorly diagnosed portosystemic anastomosis¹³.

Without surgery, the splenoportal hyperflow ensures that liver function is preserved, and is sufficient to overcome increased intra-hepatic resistance. The blood diverted through collaterals is part of the excess and thus not needed by the liver. After surgery, the portal flow decreases, but is still sufficient in most cases. However, in patients who have a high-caliber left gastric vein (LGV), intrahepatic resistance prevails and the portal blood is partially or totally diverted through this collateral. This blood is rich in hepatotrophic factors and neurotoxic nitrogenated products. The liver becomes arterialized and the sinusoidal pressure very high, leading to ascytis, atrophy of the liver and hepatocellular insufficiency. This may explain the hepatic decompensation in some schistosomiasis patients undergoing SLEV¹⁶.

In SLEV, apart from the reduction of hyperflow, the splenectomy may serve other purposes, such as curing hypersplenism, correction of infantilism, reversion of hemolysis, decompression of neighboring organs and interruption of venovenous diversions. On the other hand, it preserves the hepatopetal flow and reduces the pressure in the varices of the esophagus. The main aim of interrupting the flow through the LGV may be to interrupt hepatofugal circulation, through

this vein, preserving the functional hemodynamic equilibrium, which may be broken by splenectomy^{9,5}.

The aim of the present study was to assess the effects of splenectomy and ligation of the left gastric vein on the portal hemodynamics of patients with HSS with early signs of hemorrhage of the upper digestive tract, using angiographic and pressure studies prior to surgery and between the 7th and 15th day after surgery.

METHODS

The research project was approved by the Ethics Committee of the Institution.

Were included 23 patients with hepatosplenic schistosomiasis with early signs of hemorrhage of the upper digestive tract, admitted to the General Surgery and Liver Transplant Service of the Oswaldo Cruz University Hospital of the University of Pernambuco, PE, Brazil, between 1999 and 2002. Their ages varied from 19 to 68 year, with a mean age of 47.4+/-15.0 years. Fourteen patients were female and nine male. Patients were included if they presented simultaneously with early signs of hemorrhage of the upper digestive tract for more than eight days; esophageal varices; a negative or negated test for parasites in feces; a liver ultrasound suggesting hepatosplenic mansoni schistosomiasis (HSS); hematocrits over 22%; and Symmers fibrosis.

Patients were excluded if they had any of the following conditions: prior surgical treatment for esophageal varices; treatment with beta-blockers on admission to hospital; recent endoscopic treatment for esophageal varices; a current history of moderate or severe alcoholism; significant thrombosis of the portal, splenic or upper mesenteric vein on ultrasound examination or arteriography; active non-schistosomiasis-related cirrhosis or liver pathology; blood tests indicating the presence of the hepatitis B or C virus; kidney or heart failure.

The angiographic examinations were carried out when patients had been fasting for eight hours or more, using a digital angiographic apparatus. The pressure measurements were recorded on a TEB brand SP12 polygraph, and expressed in mmHg. The contrast injector pump was an LF brand, angiomat 6000 model. The iodate contrast was Optiray 320 (68% injectable loversol - 320 mg/ml of organic iodine). The catheters were n° 5 cobra type, with a terminal orifice to measure pressure, and another lateral or terminal orifice of the same kind for the angiographic examination.

The patients were placed lying on their backs, antiseptic was applied to the right inguocrural region using polyvinylpyrrolidone, and subsequently the sterilized fields were put in place, marking off the puncture area. The patients were anesthetized using 2% lidocaine hydrochloride, and the femoral vein punctured around 2 cm below the right inguinal fold and 1.5 cm along the artery.

The catheter was inserted using the Seldinger technique. A 2 mm incision was made in the chosen site and the femoral vein punctured using a 16 caliber needlestick. After confirming the correct position had been located, the metallic part of the needle was withdrawn and around 40 cm of flexible metal conduit "j", nº 35 was inserted. Then the needle was withdrawn and a 5 caliber dilator inserted up to around 10 cm. Following this, the dilator was withdrawn and a "cobra" type nº 5 catheter inserted without the lateral orifice, into the inferior vena cava. The outer end of the catheter was attached to a system of taps, allowing simultaneous connection to saline solution, radiological contrast solution and a system to continuously measure pressure, by way of an electronic monitor that expressed the measurements in millimeters of mercury. For the reading of pressure, the medium axillary line was considered to be the zero level. The film focus distance was maintained at a constant 100 cm and all the radiographs were taken in the anteroposterior position.

Inferior vena cava - Under radioscopy, the end of the catheter was positioned at a level corresponding to the L1-L2 intervertebral space, pressure was allowed to stabilize and the reading was taken.

Central vein pressure - The catheter proceeded to the right atrium and the characteristic wave registered on the monitor and the mean pressure was recorded.

Free hepatic vein - The catheter was maneuvered out of the right atrium and its point positioned in the right hepatic vein, after its outlet into the inferior vena cava, where the pressure was read.

Wedged hepatic vein - The catheter was inserted through increasingly finer branches of the hepatic vein until it met with resistance. At this point, around 2 ml of contrast was injected to confirm the wedged position by way of the characteristic image blurring of the hepatic sinusoid. After washing the catheter in physiological solution, the pressure was read. Then it was pushed up to the level of the inferior vena cava, where it remained until the end of the angiographic examination.

The "sinusoidal pressure" was calculated as the difference between the pressure in the wedged hepatic vein and that in the free hepatic vein.

The arterial catheter was inserted into the femoral artery using a technique identical to that described for the vein. The correct puncture position was confirmed by way of arterial blood jet reflux. The outer end of the catheter was connected to the infusion pump. The movements of the catheter were followed by contrast infusion tests, which served to confirm the correct positioning of the point of the catheter.

Hepatic artery - Once the end of the catheter had been positioned in the common or accessory hepatic artery, 30 ml of contrast was injected at a flow of 10 ml/sec. At the same time, a series of 10 radiographs were taken, one per second.

Splenic artery - The end of the catheter was

positioned in the splenic artery and 50 ml of contrast injected at a flow of 10 ml/sec. At the same time a series of 12 radiographs were taken, as follows: one per second for the first three seconds, followed by two per second for one second, a 5-second pause, and then seven two per second.

Upper mesenteric artery - With the end of the catheter placed around 4 cm from the beginning of the upper mesenteric artery, 40 ml of contrast was injected at a flow of 10 ml/sec. and a series of radiographs taken in a scheme identical to that used for the splenic artery.

A 0.05X150 mm Vernier Galiper precision pachymeter was used to measure the diameter of the vessels. The common hepatic artery, the hepatic artery itself, the upper mesenteric artery and the splenic artery were measured for the length of their proximal third, and the portal, upper mesenteric, splenic and left gastric veins for the length of their middle third, at the points of widest diameter. The diameter of the vessels was measured three times and the arithmetical mean recorded as the result.

The patients underwent splenectomy and ligation of the left gastric vein (SLLGV) according to the standard technique used by the service. The postoperative study was carried out between the 8th and 39th day after surgery (a mean of 14.3 days).

The results were expressed in terms of the mean, median, standard deviation and minimum and maximum. Student's t-test for paired samples was applied. When Student's t-test could not be employed, the medians were compared using the Wilcoxon test for paired samples. For all tests, a level of significance of 0.05 was adopted. Confidence intervals of 95% were obtained for the differences between means or medians.

RESULTS

In all patients, laparotomy revealed a macroscopic appearance compatible with hepatosplenic Mansonian schistosomiasis. The results of the histopathological examinations of the spleen revealed sclerocongestive splenomegaly in all cases, with a weight varying from 215 to 2.650 g, a mean of 924.8+/-556.3. The liver biopsy revealed Symmers fibrosis in all patients. The duration of surgery varied from 105 to 240 minutes, with a mean duration of 156 minutes. Eight patients received transoperative hemoderivatives. One presented transoperative bleeding in the splenic bed, requiring further surgery for hemoperitoneum on the 1st day after surgery, to place surgical dressings on the site of the bleeding. A further operation was carried out 48 hours later to remove the compresses; the patient followed-up satisfactorily. One patient developed a respiratory infection and 12 presented with fever following surgery, which diminished up to the point when they were discharged from hospital. Thirteen patients (59%)

of the 22 examined using ultrasonographic-Doppler presented with partial portal thrombosis, although without clinical implications. No patient died during surgery.

TABLE 1 - Free hepatic venous pressure before and after splenectomy and ligature of the left gastric vein (SLLGV)

FHVP	Descriptive statistics					
	N	Mean	Median	Standard deviation	Minimum	Maximum
Before	23	7.07	7.00	3.31	-2	13.84
After	23	6.90	7.00	4.13	0	15.00
After - Before	23	-0.2	0.0	3.7	-7.0	8.0

Student's t-test p = 0.820 FHVP= Free hepatic venous pressure

TABLE 2 - Wedged hepatic venous pressure before and after splenectomy and ligature of the left gastric vein (SLLGV)

WHVP	Descriptive statistics					
	N	Mean	Median	Standard deviation	Minimum	Maximum
Before	23	13.4	14.5	5.6	2.0	25.0
After	23	11.9	11.0	6.2	4.0	25.0
After - Before	23	-1.5	-2.0	6.4	-15.0	12.0

Student's t-test p = 0.220 WHVP= Wedged hepatic venous pressure

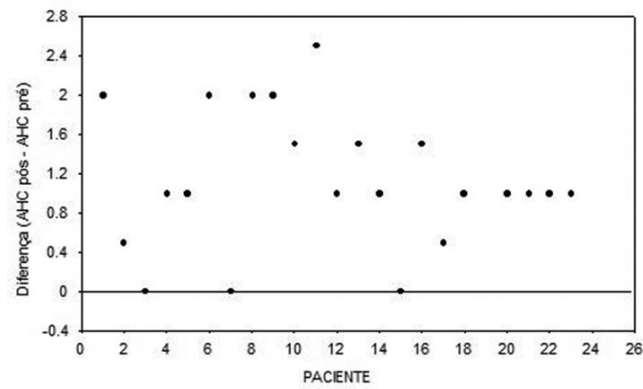


FIGURE 1 - Difference of individual values of the diameters of the common hepatic artery (HCA) before and after ELGE

TABLE 3 - Diameter of the portal vein before and after splenectomy and ligature of the left gastric vein (SLLGV)

PV	Descriptive statistics					
	N	Mean	Median	Standard deviation	Minimum	Maximum
Before	21	13.8	14.0	2.67	6.0	18.0
After	21	13.0	13.5	2.97	6.0	18.0
After - Before	21	- 0.8	-1.0	2.05	-6.5	4.0

Student's t-test p = 0.100; PV= portal vein

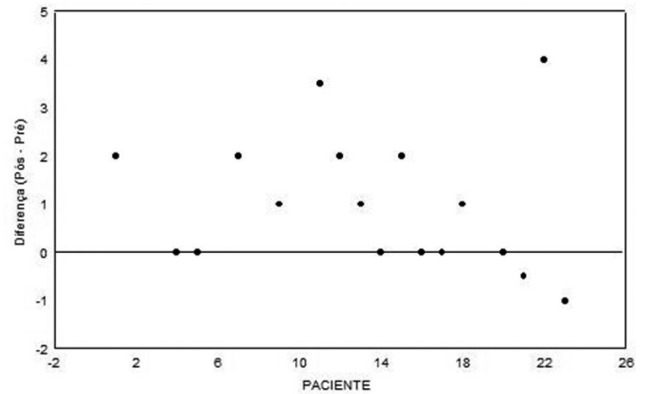


FIGURE 2 - Differences in individual values of the diameters of the superior mesenteric vein (VMS) before and after ELGE

TABLE 4 - Diameter of the upper mesenteric artery before and after splenectomy and ligature of the left gastric vein (SLLGV)

UMA	Descriptive statistics					
	N	Mean	Median	Standard deviation	Minimum	Maximum
Before	21	5.45	5.50	1.13	3.50	7.50
After	21	5.83	6.00	1.14	4.50	9.50
After - Before	21	0.4	0.0	0.85	-1.5	2.0

Wilcoxon Test p = 0.078; UMA= upper mesenteric artery

DISCUSSION

The subjects in the present study were predominantly female, as in other case samples^{3,7,9,15}. The sagittal diameter of the spleen, as evaluated by ultrasound, was 20.6+/-6.5 cm. The minimum interval between the latest episode of hemorrhage of the digestive tract and admission to hospital to commence research was eight days, as a way of avoiding changes in hemodynamics or metabolism occasioned by the hemorrhage.

Normally inferior vena cava pressure is higher than that of the central vein, by an average of 2 mmHg. In this case sample, the median pressure in the inferior vena cava (IVC) before surgery was 8.0±3.5 mmHg, 3.0 mmHg above the median for central vein pressure, at this point. After surgery, the pressure in the inferior vena cava was found to have decreased by 1 mmHg, which represents 3.1% of the median prior to surgery, and is not statistically significant, in accordance with the findings for patients undergoing splenectomy and ligature esofagics veins (SLEV) and esplenectomy and azigoportal disconexion (EAPD)^{16,18}.

There was a tendency for the mean pressure in the central vein to increase 14.4% in relation to the median before surgery, but this too was not statistically significant. This finding has also been reported in patients undergoing splenectomy and ligature esofagics veins (SLEV)¹⁵. An increase in cardiac deficiency was

observed in patients undergoing esplenectomy and azigoportal disconnection (EAPD), seven to 10 days after the procedure¹⁸.

The hepatic vein exhibited an appearance that is characteristic of hepatosplenic mansoni schistosomiasis (HSS): "arching of branches", with a change in normal course to one that is semicircular or oval, a reduction in dichotomization, "sun's rays"- like images and increased bifurcation angles. This pattern is distinct from that of other chronic diffuse hepatopathies. The free hepatic venous (FHV) pressure is very similar to that of the cava vein in normal individuals and even in the case of a wide range of liver disorders, being on average 3 mmHg higher than the pressure in the cava vein^{16,21} (Table 1).

Sinusoidal pressure in hepatosplenic mansoni schistosomiasis (HSS) patients does not appear to change after splenectomy and ligation of the esophageic veins (SLEV) or esplenectomy and azigoportal disconnection (EAPD), or with the use of propranolol²⁰. In the present study, sinusoidal pressure was found to be within the normal range before and after splenectomy and ligation of the left gastric vein (SLLGV)

indicating that it is a procedure that preserves sinusoidal pressure (Table 2).

It has been observed in patients with hepatosplenic mansoni schistosomiasis (HSS) that in hepatic arterialization the arterial branches "are not diverted, twisted, amputated or compressed" with the portal vascular system newly formed exclusively of veins. In order to maintain the total flow and sinusoidal pressure without great variations, the organism uses a regulatory mechanism through which the flow of blood in the hepatic artery increases or decreases in inverse proportion to the flow in the portal. This regulation has been attributed to chemical mediators, such as glucagon, biliary salts and, above all, adenosine, a potent arterial vasodilator. It has thus been dubbed the "adenosine wash-out" theory. The reduction in portal flow after a splenectomy leads to an increase in the concentration of adenosine, with vasodilation of the hepatic artery and an increase in arterial blood supply to the liver after surgery^{17, 25}.

In the present study, a significant increase was found in the diameter of the common and proper hepatic artery. Prior to surgery, the median diameter of the common hepatic artery was 4.00±0.99 mm, but rose to 5.75±0.99 mm after surgery, an increase of 25%. The hepatic artery proper increased 36.4% from 3.3±0.78 mm prior to surgery to 4.5±1.03 mm after (Figure 1). There are a number of changes that are characteristic of hepatosplenic mansoni schistosomiasis (HSS), such as: vascular flow voids, an increase in bifurcation angles, and a reduction in dichotomization, indicating poor arterialization in the liver, probably as a result of hyperflow from the portal⁸ (Table 4).

Lacerda, in a 1991 study of hepatosplenic mansoni schistosomiasis (HSS) patients, before and

after splenectomy and ligation of the esophageic veins (SLEV), has suggested that, in patients with large shunts who have not undergone surgery, the hyperflow may explain the lack of increase in hepatic arterialization and encephalopathy, since only 'excess' portal blood is diverted and this is not needed by the liver¹⁶.

An interesting and hitherto unnoticed feature of the hepatic artery in the late stages after splenectomy and ligation of the left gastric vein (SLLGV) has recently been observed by Evangelista Neto⁷. This researcher found that, six months after surgery, there was a reduction in the caliber of the hepatic artery, as observed using ultrasonographic-Doppler, probably as a result of the tendency for the portal flow to increase, caused by the reorganization of the partial thrombosis of the portal vein⁷.

In this case sample, it was found that the average diameter of the upper mesenteric artery increased slightly from 5.5±1.1 mm prior to surgery to 6.0±1.1 mm after, representing an insignificant increase of 4.5%. This small increase in diameter following surgery may occur because of the greater flow of blood through this artery after splenectomy, occasioned by the reduced supply of blood through the splenic artery.

In hepatosplenic mansoni schistosomiasis (HSS) patients, with or without hemorrhage of the upper digestive tract, the portal vein and its intra-hepatic ramifications assume a variable angiographic appearance and the diameter is frequently increased. In the liver, ramification of the portal vein is a characteristic feature, with images showing the amputation and blurring of more distal branches – the Bogliolo sign⁴.

In this case sample, the portal vein was viewed in 21 patients (91.3%) and in these there was a reduction of 5.8% after splenectomy and ligation of the left gastric vein (SLLGV), although this was not statistically significant (Table 3). This finding differs from those of other studies that have found a greater difference. These studies were of patients who had undergone splenectomy and ligation of the esophageic veins (SLEV), splenectomy and ligation of the left gastric vein (SLLGV) or esplenectomy and azigoportal disconnection (EAPD)^{16,15,26}. It is possible that, in some cases, the reduction in diameter, was partly caused by the formation of intramural thrombi.

The diameter of the splenic vein varies and can increase considerably, winding erratically in patients with portal hypertension caused by schistosomiasis. The splenic vein was measured prior to surgery and the average diameter was 12.4±2.6 mm, which is lower than the figure of 18.16±9.74 mm reported by Lacerda in 1991, or that of 19.89 mm reported by Mies in 1980, using the same methodology^{16,20,21}.

The left gastric vein was examined in 18 of the 23 patients studied (78.26%), which is a higher percentage than that of Lacerda's patients of 55%, or of Mies's, which was 62%¹⁶⁻²⁰. The diameter ranged from 3.5 to 10 mm. The average caliber after surgery was 7.5±

1.6 mm. Other studies, using splenoportography or transoperative portography have been able to examine this vein in a larger percentage of patients²¹.

Following surgery, this vein should not theoretically be visible in patients on the control angiographic examination. It was, however, identified in seven patients (30,4%) and in two the diameter had increased (from 6 to 7 mm and 10 to 13 mm).

In the present study, the diameter of the upper mesenteric vein was found to have increased by 10% after splenectomy and ligation of the left gastric vein (SLLGV) (from 9.6+/-1.26mm to 10.6+/-1.6mm), which is statistically significant. This finding may be explained by the increase in blood flow through the upper mesenteric vein, which may take on a vicarious role after splenectomy, with the portal flow depending primarily on blood from this vein (Figure 2).

In 1997, Mies observed a decreased flow of blood from the upper mesenteric vein in cases of hepatosplenic mansoni schistosomiasis (HSS)²⁰. Menezes, in 2001, using ultrasonographic-Doppler to measure the diameter of the upper mesenteric vein in patients who had undergone splenectomy and ligation of the left gastric vein (SLLGV), did not find any significant alteration following surgery^{19,20,29}.

So far as study methodology is concerned, examinations of angiography and pressure have mainly used the Seldinger technique to evaluate various surgical procedures used to treat hepatosplenic mansoni schistosomiasis (HSS)^{22,23,24}.

These patients should be followed up after surgery. Ideally, those that continue to hemorrhage or present with pressure in the esophageal varices higher than 20 mmHg should subsequently undergo sclerosis or endoscopic ligation of the esophageal varices with or without the administration of propranolol. Endoscopic treatment alone or in combination with propranolol is recommended by various authors for treatment of hepatosplenic mansoni schistosomiasis (HSS), in cases where hemorrhaging persists and liver damage is present, as a way of bring down mortality caused by the hemorrhages. This has been shown to be effective when carried out subsequent to surgery^{15,27,14}.

During the period studied, splenectomy and ligation of the left gastric vein (SLLGV) proved to be a procedure that can be carried out by trainee surgeons, owing to the low incidence of complications and the fact that, in most patients, the intended objective was achieved: the risk of re-occurrence of hemorrhage was reduced and there were changes in hemodynamic variables compatible with maintaining a functional hemodynamic equilibrium in the liver. Patients undergoing this surgery need to be followed up for a longer period to confirm whether the short-term results indicated by the present study persist into the long-term.

CONCLUSION

Splenectomy and ligation of the left gastric vein do not determine portal hemodynamic changes capable of breaking the functional hemodynamic balance that characterizes the hepatosplenic mansoni schistosomiasis.

REFERENCES

1. Arruda SMB, Barreto VST, Amaral FJ; Duplex Sonography Study in schistosomiasis portal hypertension: characterization of patients with and without a history of variceal bleeding. *Arq Gastroenterol* 2008; 45: Jan/mar. Access: www.scielo.br in 10/25/2012 – DOI: 10.1590/ 50004- 2803200800100003.
2. Barbosa CS, Da Silva CB, Barbosa FS. Esquistossomose: reprodução e expansão no estado de Pernambuco no Brasil. *Rev Saúde Pública* 1996;30: 609-16.
3. Batista-Neto J, Tognetti LB, Ribeiro LT, Balwani MC, Muritiba T, Alves EC; Evolutional profile of the esophageal varices after splenectomy associated with ligation of the left gastric vein and sclerotherapy in schistosomal portal hypertension. *ABCD Arq Bras Cir Dig* 2013; 26 (1): 49-53.
4. Bogliolo LO. O portograma post-mortem na esquistossomose mansônica hepato-esplênica. *Rev Assoc Med Brasil* 1956: 4: 379-85
5. Conceição MJ, Argento CA, Vieira OM, Takiya CM, Chagas VL. A. Surgical indication in schistosomiasis mansoni portal hypertension – follow-up from 1985 to 2001. *Mem Inst Oswaldo Cruz* 2002; 97:165-6.
6. Coutinho A. Hemodynamic studies of portal hypertension in schistosomiasis. *Am J Med* 1968; 44; 547-56.
7. Evangelista – Neto J, Pereira FF, França ST, Amaral FJ, Brandt CT, Fonseca- Neto OCL, Lacerda CM. Splenectomy and gastric vein ligation in hepatosplenic schistosomiasis: effects upon esophageal variceal pressure and endoscopic risk of esophageal variceal bleeding. *ABCD Arq Bras Cir Dig* 2012; 25(1) : 41-48.
8. Ferraz AA., Bacelar TS, Silveira MJ, Coelho AR., Câmara Neto RD, De Araújo Júnior JG, Ferraz EM. Surgical treatment of schistosomal portal hypertension. *Int Surg* 2001; 86 : 1-8.
9. Ferraz AAB, Lopes EPA, Bacelar TS, Silveira MJC, Silva LMM, Ferraz EM. Tratamento cirúrgico da hipertensão portal esquistossomótica no HC/UFPE – análise de 131 casos. *Rev Col Bras Cir* 2000; 27: 232-7.
10. Ferreira F, Ribeiro M, Santos MF, Anef J, Szutan c Doppler ultrasound could predict varices progression and rebleeding after portar hypertension surgery: lessons from 146 EGDS and 10 years of follow-up. *World J surg* 2009;33: 2136-2143.
11. Goldenberg S, Oliveira E, Figueira A, Haddad CM, Herani Filho B. Nova técnica para a interrupção intragástrica de varizes gastroesofágicas (Técnica de Skinner modificada) associada a esplenectomia. *Rev Assoc Med Bras* 1972; 18: 429-34.
12. Katz N, Peixoto SV. Análise crítica da estimativa do número de portadores de esquistossomose mansoni no Brasil. *Rev Soc Bras Med Trop.* 2000; 33: 303-8.
13. Kelner S. Avaliação crítica da cirurgia da hipertensão portal esquistossomótica. *Mem Inst Oswaldo Cruz* 1992; 87: 357-68.
14. Kelner S, Ferreira PF, Dantas A., Lima Filho JF, Souza, AP, Carreiro Jr. JCP, Ferraz EM, Silveira M, Coelho, ARB, Câmara Neto RD, Domingues LAW. Ligadura de varizes esôfago-gástricas na hipertensão porta esquistossomótica: Avaliação de 25 Anos. *Rev Col Bras Cirurg* 1982; 9: 146-74.
15. Lacerda CM, Freire W, Melo PSV, Lacerda HR, Carvalho G. Splenectomy and ligation of the left gastric vein in schistosomiasis mansoni : the effect on esophageal variceal pressure measured by a non-invasive technique. *Keio J Med.* 2002; 51: 89-92.
16. Lacerda CM, Ramos H., Raia S, Kelner S. Fisiopatologia da hipertensão portal esquistossomótica e efeitos da esplenectomia

- com ligadura de varizes de esôfago. *Acta Cir Bras.* 1993;8: 113-17.
17. Lauth WW, Greenway CV. Conceptual review of the hepatic vascular bed. *Hepatology* 1987; 7: 952-3.
 18. Makdissi FF, Herman P, Pugliese V, De Cleve R, Saad WA, Cecconello I, D'Albuquerque LAC.
 19. Loug-Term results of esophagogastric devascularization and splenectomy associated with endoscopic treatment in schistosomal portal hypertension.
 20. *World J surg* 2010; 34: 2682-2688. DOI: 10.1007/ 500268 010-0717-8.
 21. Menezes HL, Jucá MJ, Brandt CT, Gomes EGA, Patrício AR, Maior PMS. Dopplerfluxometria de sistema porta em portadores de esquistossomose submetidos à esplenectomia e ligadura da veia gástrica esquerda. *An Fac Med Univ Fed Pernamb* 2001; 46: 23-7
 22. Mies S, Braghirolli Neto O, Beer Jr A, Baía CES, Alfieri Jr F, Pereira LMMB, Sette MJA, Raia S. Systemic and hepatic hemodynamics in hepatosplenic Manson's schistosomiasis with and without propranolol. *Digestive Diseases and Sciences* 1997; 42: 751-61.
 23. Mies S, Mori T, Larsson E, Rosa P, Jara JG, Santos LF, Löscher W, Raia S. A veia cava inferior e as veias supra-hepáticas na esquistossomose hepatoesplênica. Estudo angiográfico. *Rev Hosp Clin Fac São Paulo* 1980; 35: 136-42.
 24. Raia S, Da Silva LC, Gayoto LCC, Forster SC, Fukushima J, Strauss E. Portal hypertension in schistosomiasis : A long-term follow-up of a randomizes trial comparing three types of surgery. *Hepatology* 1994; 20: 398-403.
 25. Raia S, Mies S, Macedo AL. Surgical treatment of portal hypertension in schistosomiasis. *World J. Surg* 1984; 8: 738-52.
 26. Saad WA., Yamin H, Freday U, Velard G, Chaib S, Parra O M, Berman A, Vasconcelos E. Descompressão seletiva do sistema portal no tratamento da hipertensão portal associada a varizes sangrantes do esôfago. *Rev Assoc Med Bras* 1977;23:165-68.
 27. Silva LC., Carrilho FJ. Hepatosplenic schistosomiasis.: Pathophysiology and treatment. *Gastroenterol Clin North Am* 1992; 21: 163-77.
 28. Silva LC, Strauss E, Gayotto LCC, Mies S, Macedo AL, Silva AT, Silva EF, Lacet CMC, Antonelli RH, Fermanian J, Foster S, Raia A., Raia S. A randomized trial for the study of the elective surgical treatment of portal hypertension in mansonic schistosomiasis. *Ann Surg* 1986; 204; .149-53.
 29. Strauss ED. Hipertensão portal esquistossomótica: análise evolutiva de intercorrências clínicas, dados endoscópicos e laboratoriais em estudo randomizado comparando três tipos de cirurgia. *Rev Pat Trop* 1992; 21: 37-188.
 30. Voietta I, Queiroz LC, Andrade LM, Silva LCS, Fontes VF, Barbosa A Jr, Rezende V, Petroniana A, Andrade Z, Antunes CM, Lambertucci Jr. Imaging Techniques and histology in the evolution of liver fibrosis in hepatosplenic schistosomiasis mansoni in Brazil: a comparative study. *Mem Inst Oswaldo Cruz* 2010: 105(4) July. Access: www.scielo.br in 10/25/2012 – DOI: 10.1590/ 50074-02762010000400011.