



# PROTOCOL FOR LIVER TRANSPLANTATION IN HILAR CHOLANGIOCARCINOMA

## PROTOCOLO DE TRANSPLANTE HEPÁTICO PARA COLANGIOCARCINOMA HILAR

Lucas **ERNANI**<sup>1</sup>®, Rodrigo Bronze de **MARTINO**<sup>1</sup>®, Wellington **ANDRAUS**<sup>1</sup>®, Eduardo de Souza Martins **FERNANDES**<sup>2,3</sup>®, Felipe Pedreira Tavares de **MELLO**<sup>2,3</sup>®, Ronaldo **ANDRADE**<sup>2,3</sup>®, Leandro Savattoni **PIMENTEL**<sup>2,3</sup>®, Luciana Bertocco de Paiva **HADDAD**<sup>1</sup>®, Fabricio Ferreira **COELHO**<sup>1</sup>®, Paulo **HERMAN**<sup>1</sup>®, Luiz Augusto Carneiro **D'ALBUQUERQUE**<sup>1</sup>®

**ABSTRACT - BACKGROUND:** Hilar cholangiocarcinoma represents more than half of all cholangiocarcinoma cases, having poor prognosis and presenting a median overall survival after diagnosis of 12-24 months. In patients who have unresectable tumors with a better prognosis, the proposal to perform liver transplantation emerged for expanding the possibility of free margins by performing total hepatectomy. **AIM:** To provide a Brazilian protocol for liver transplantation in patients with hilar cholangiocarcinoma. **METHOD:** The protocol was carried out by two Brazilian institutions which perform a large volume of resections and liver transplantations, based on the study carried out at the Mayo Clinic. The elaboration of the protocol was conducted in four stages. **RESULT:** A protocol proposal for this disease is presented, which needs to be validated for clinical use. **CONCLUSION:** The development of a liver transplantation protocol for cholangiocarcinoma aims not only to standardize the treatment, but also enable a better assessment of the surgical results in the future.

**HEADINGS:** Transplantation. Liver transplantation. Cholangiocarcinoma. Klatskin tumor.

**RESUMO – RACIONAL:** O colangiocarcinoma hilar representa mais da metade de todos os casos de colangiocarcinoma; tem prognóstico reservado e sobrevida global mediana de 12- 24 meses após o diagnóstico. A proposta de realizar transplante hepático surgiu para ampliar a possibilidade de margens livres através de hepatectomia total nos portadores de tumores irresssecáveis com melhor prognóstico. **OBJETIVO:** Apresentar protocolo brasileiro para realização de transplante hepático em pacientes com colangiocarcinoma hilar. **MÉTODO:** O protocolo foi realizado por duas instituições com grande volume de ressecções e transplantes hepáticos no Brasil, baseado no trabalho realizado pela MayoClinic. A elaboração foi dividida em quatro etapas. **RESULTADO:** É apresentada proposta de protocolo para esta doença a ser validada na aplicação clínica. **CONCLUSÃO:** Foi possível elaborar protocolo de transplante hepático para colangiocarcinoma a fim de uniformizar o tratamento e melhor avaliar os resultados cirúrgicos.

**DESCRIPTORIOS:** Transplante. Transplante de fígado. Colangiocarcinoma. Tumor de Klatskin.



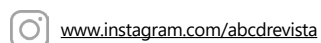
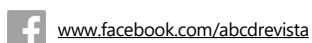Protocol for liver transplantation in hilar cholangiocarcinoma

### Main Message

Liver transplantation in patients with hilar cholangiocarcinoma achieves good results when a careful preoperative selection is carried out. This protocol aims to standardize the operating procedures for liver transplantation in patients with hilar cholangiocarcinoma.

### Perspective

This protocol aims to provide a standardized operating procedure for liver transplantation in patients with hilar cholangiocarcinoma, as well as enable a better assessment of surgical results, disease-free survival and overall survival. The regulation of this protocol is currently in progress in the National Transplant System (SNT - Sistema Nacional de Transplantes) of the Brazilian Ministry of Health.



<sup>1</sup>Department of Gastroenterology, Hospital de Clínicas, Medical School, University of São Paulo, São Paulo, SP, Brazil; <sup>2</sup>Department of General Surgery and Transplantation, Hospital Adventista Silvestre, Rio de Janeiro, RJ, Brazil; <sup>3</sup>Abdominal Transplant Surgery, Hospital São Lucas - Copacabana, Rio de Janeiro, RJ, Brazil.

How to cite this article: Ernani L, Martino RB, Andraus W, Fernandes ESM, Mello FPT, Andrade R, Pimentel LS, Haddad LBP, Coelho FF, Herman P, D'Albuquerque LAC. Arq Bras Cir Dig. 2021(3): e1618. <https://doi.org/10.1590/0102-672020210002e1618>.

**Correspondence:**  
Lucas Ernani  
Email: [lcsernani@gmail.com](mailto:lcsernani@gmail.com)

Financial support: none  
Conflict of interest: none  
Received 20/12/2020  
Accepted 25/04/2021

## INTRODUCTION

**C**holangiocarcinoma (CCA) is the second most common primary neoplasm of the liver after hepatocellular carcinoma, accounting for 10-15% of all hepatobiliary neoplasms<sup>1</sup>. CCA originates from the biliary epithelium, histologically consisting of an adenocarcinoma in 95% of the cases. Its classification, used in clinical practice, is based on the anatomical location of the tumor and is divided into intrahepatic and extrahepatic. The latter includes hilar and distal (inferior lower third of the choledochal) cholangiocarcinomas<sup>6</sup>.

Hilar cholangiocarcinoma (hCCA) - also known as Klatskin tumor - is the most frequent type of CCA, representing more than half of all CCA cases. It has a poor prognosis, with a median overall survival after diagnosis of 12-24 months<sup>6</sup>. The most important prognostic factor for this tumor is achieving free margins through surgical resection; however, it is only achieved in 25-40% of patients. Moreover, the overall survival in patients who underwent R0 resection is 40-45% in 5 years<sup>6,10,12</sup>.

The proposal of performing liver transplantation (LT) in this group of patients emerged in the late 1980s and early 1990s. The justification for this pioneering idea regarded an increase in the number of patients with free margins by performing total hepatectomy in tumors considered unresectable. Initial results were not promising, with a high rate of recurrence (51-53%) and overall survival of 23-30% in 5 years<sup>9,14,17</sup>. Organ scarcity combined with poor initial results justified the contraindication of hCCA for LT at that time. Based on the data currently available, it is possible to observe that there is benefit in performing LT for hCCA as long as careful candidate selection is carried out<sup>5,21</sup>. The current recommendation of the International Liver Transplant Society (ILTS) is to perform LT with a specific protocol for hCCA<sup>18</sup>.

Therefore, the aim of our study is to present a protocol proposal to guide the clinical use of LT in hCCA. This protocol needs to be validated in future studies.

## METHODS

This protocol was performed by two high-volume centers of liver transplantation (LT) and liver resection (LR) in Brazil: University Hospital of the Medical School of the University of São Paulo (HCFMUSP) and Hospital Adventista Silvestre/Hospital São Lucas. The elaboration of the protocol was conducted in four stages.

In the first stage, a search in the literature was performed in order to access the main studies regarding LT for hCCA up to date. In the second stage, an outline of the protocol was designed by the first two authors and the last author, based on the study conducted at the Mayo Clinic<sup>4,8,16</sup>. In the third stage, 10 experts elaborated the last version of the protocol, adapted to the Brazilian reality. The last stage consisted of the protocol submission for approval in the National Transplant System (SNT - Sistema Nacional de Transplantes) of the Brazilian Ministry of Health.

Brazilian centers will be selected for inclusion in the multicentric research project and a total of 30 patients will undergo transplantation according to the criteria of this protocol, and will be referred to these centers by the SNT. Preoperative, intraoperative and postoperative data will be prospectively recorded on the REDCap platform<sup>7</sup>. The following pre-transplantation data will be analysed: age, gender, diagnosis of hCCA, staging examinations, tumor size, neoadjuvant chemotherapy and radiotherapy, diagnostic laparoscopy or laparotomy, anatomopathological analysis of the lymph node chains assessed in the staging surgery, time between diagnosis

of hCCA and LT, and type of LT (deceased-donor or living-donor). The number of patients referred for LT evaluation, as well as the number of patients who effectively met the criteria and were included for undergoing LT and those who were excluded before the LT (due to not meeting the criteria or to contraindication after undergoing laparoscopy/laparotomy) will be assessed as well. After the LT, the following data will be analyzed: disease-free survival and overall survival in 1, 3 and 5 years; immunosuppression protocol; rejection episodes; and need for retransplantation.

## RESULTS

Figure 1 shows the LT protocol for hCCA proposed in this study by the authors (Figure 1). Figure 2 shows the document of SNT to be filled in to request a special situation for hCCA (Figure 2).

## DISCUSSION

In 1987 at the University of Nebraska, Sudan et al.<sup>19</sup> introduced the concept of neoadjuvant therapy with improvement in long term results. In 1993, the Mayo Clinic group initiated a pilot protocol of neoadjuvant therapy for patients with unresectable hCCA or hCCA with primary sclerosing cholangitis (PSC). This protocol consisted of external radiotherapy (4500 cGy in 30 sessions) associated with a 5-fluorouracil (5-FU) bolus infection in the first three days of irradiation. Brachytherapy with Iridium-192 (2000-3000 cGy) was started 2-3 weeks after the end of external radiotherapy. Finally, patients were maintained on a 5-FU infusion pump or capecitabine orally until transplantation. All patients were submitted to a staging laparotomy before LT. Preliminary results of 11 patients were published in 2000 and were promising<sup>4</sup>. Results of this cohort (n=28) were updated in 2004 and showed an overall survival of 82% in 5 years<sup>8</sup>. The final result of this Mayo Clinic protocol study was published in 2005: 38 patients with an overall survival of 92% in 1 year, 82% in 3 years and 82% in 5 years<sup>16</sup>.

Since the creation of the Mayo Clinic protocol, other centers have published their experience using the same or a similar protocol. In 2012, a multicenter study carried out in the USA (12 centers) published a cohort with 287 patients - in tumors smaller than 3cm and with neoadjuvant therapy, in agreement to the protocol, disease-free survival of 69% in 5 years<sup>3</sup> was achieved. In addition, an european multicenter study (21 centers) presented the results of LT in 159 patients selected according to the criteria of the Mayo Clinic, however without performing neoadjuvant therapy, having an overall survival of 59% in 5 years<sup>13</sup>.

Tan et al.<sup>20</sup> reviewed the current literature on the indication of LT for hCCA and emphasized that the waiting time before LT can be beneficial in selecting patients, consequently presenting superior results. In comparison to other LT indications, there is an increased risk of developing late artery and portal vein complications, probably due to irradiation. Neoadjuvant therapy combined with LT can achieve results comparable to resection in patients with unresectable hCCA at early stages and is the treatment of choice for patients with hCCA with primary sclerosing cholangitis.

It is important to assess locoregional lymph nodes in order to avoid LT in cases with positive lymph node disease<sup>11,15</sup>. Just as in the protocols performed at the Mayo Clinic<sup>16,20</sup>, there is the suggestion of performing laparoscopy or laparotomy with evaluation of the lymph node chains mentioned above (8a, 8p,

<b>PROTOCOL FOR LIVER TRANSPLANTATION IN HILAR CHOLANGIOCARCINOMA</b>	
<b>STEPS FOR LT IN hCCA</b>	
LT centers	Specialized centers selected by SNT
LT standardization	Performed based on a protocol under SNT supervision in order to evaluate the outcomes
LT approval	Approval in a multidisciplinary meeting at local institution with mandatory presence of a radiologist, clinical oncologist, hepatopancreatobiliary surgeon and transplantation surgeon
LT notification	All cases must be referred to the SNT for evaluation and final approval.
<b>LT INDICATION</b>	
Patient selection	Indication for hCCA with unlikely R0 resection and/or unresectable hCCA due to chronic liver disease (primary sclerosing cholangitis or other causes of chronic liver disease)
Official authorization	After SNT approval, patients will be included in the list for LT with a special MELD score (MELD 30)* Follow the same inclusion and exclusion criteria of DDLT
LDLT	They will only have coverage by the Brazilian Ministry of Health if meeting the established criteria
Neoadjuvant chemotherapy and radiotherapy	For tumors ≤ 3 cm, there is a recommendation of performing at least one type of neoadjuvant chemotherapy and one radiotherapy modality (external radiotherapy or brachytherapy). In such cases, DDLT and LDLT will be allowed.
	For tumors > 3 cm and < 4 cm, there is a recommendation of performing at least one type of neoadjuvant chemotherapy and one radiotherapy modality (external radiotherapy or brachytherapy). In such cases, only LDLT will be allowed.
<b>INCLUSION AND EXCLUSION CRITERIA</b>	
Inclusion criteria (all the described criteria must be met for inclusion):	Diagnosis of hCCA confirmed by intraluminal brush cytology and/or intraluminal biopsy and/or CA 19.9 level greater than 100 ng/m in the absence of cholangitis and with a radiographic imaging (CT and/or MRI) showing stricture of biliary tree in the hepatic hilum.
	Staging of disease with CT (chest, abdomen and pelvis), MRCP and endoscopic ultrasound (lymph node evaluation). A digital link must be attached with MRCP for validation by the radiology of SNT.
	Absence of metastatic disease (intrahepatic and extrahepatic) according to CT (chest, abdomen and pelvis) and MRCP within 3 months before the multidisciplinary meeting at local institution.
	Staging laparoscopy or staging laparotomy must be performed before LT. The routine sampling of lymph nodes 8a, 8p, 12a and 12p is mandatory in order to exclude tumor spread. Staging operation must be performed within 60 days before LT. *Patients can be included in the list for LT before this operation; however, the submission of anatomopathological analysis is mandatory in order to be active in the LT list.
Exclusion criteria (meeting one criteria is enough for exclusion):	Intrahepatic cholangiocarcinoma
	Distal cholangiocarcinoma
	Uncontrolled infection at the moment of LT
	Other malignant diseases in the last five years (except for skin and cervical neoplasm)
	Metastatic disease confirmed by staging exams and/or staging laparoscopy/laparotomy
	Positive locoregional lymph nodes confirmed by biopsy (endoscopic ultrasound and/or staging laparoscopy/laparotomy)
	Previous attempt of hepatic hilum lesion biopsy by invasive methods (percutaneous and/or surgical)
	Previous attempt of hepatic hilum lesion resection
Other diseases with clinical contraindication to perform LT	
<b>POSTOPERATIVE AND FOLLOW-UP</b>	
Clinical follow-up	Postoperative follow-up by means of outpatient appointments, with CT (chest, abdomen and pelvis) and measurement of CA19.9 levels every three months in the first year
	From the second year forward, perform the same postoperative follow-up described above every six months
<b>IMMUNOSUPPRESSION, REJECTION TREATMENT AND RETRANSPLANTATION</b>	
Immunosuppression	Immunosuppression will be performed according to the institutional protocol of each center There is the suggestion for using a mammalian target of rapamycin (mTOR) inhibitor (everolimus or sirolimus) 1 month after the LT or as soon as possible after this period, depending on postoperative complications
Rejection treatment	Performed according to the institutional protocol of each center
Retransplantation for recurrent hCCA	Not allowed
Retransplantation in other situations	Allowed on primary graft dysfunction, hepatic artery thrombosis, chronic rejection

LT=liver transplantation; DDLT=deceased-donor liver transplantation; LDLT=living-donor liver transplantation; hCCA=hilar cholangiocarcinoma; SNT=national system of transplants; CT= computed tomography; MRI= magnetic resonance imaging; MRCP= magnetic resonance cholangiopancreatography

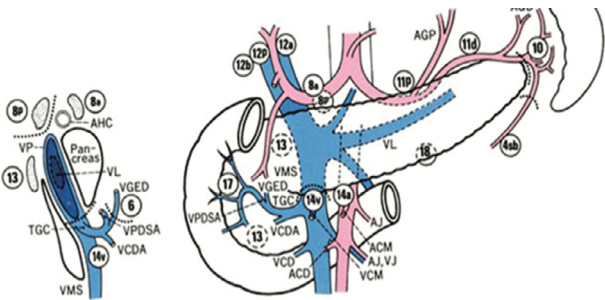
**Figure 1** - Protocol created by the authors for liver transplantation in hilar cholangiocarcinoma.

**SNT**

**NATIONAL SYSTEM OF TRANSPLANTS**

**SPECIAL SITUATION  
HILAR CHOLANGIOCARCINOMA**

Patient: _____ RGCT: (register number at the transplant center) _____ Center: _____ Hospital: _____	
<b>Special situation inclusion criteria:</b> hCCA with unlikely R0 resection and/or unresectable hCCA due to chronic liver disease (primary sclerosing cholangitis or other causes of chronic liver disease)	
Diagnosis:  <input type="checkbox"/> cytology criteria AND/OR  <input type="checkbox"/> pathology criteria AND/OR  <input type="checkbox"/> laboratory criteria (CA-19.9) + radiologic criteria	Diagnosis of hCCA confirmed by intraluminal brush cytology and/or intraluminal biopsy and/or CA 19.9 level greater than 100 ng/ml in the absence of cholangitis and with a radiographic imaging (CT and/or MRI) showing stricture of biliary tree in the hepatic hilum Attach the medical and examination reports.
<b>Staging:</b>  CT (C/A/P) Date: / /  MRCP Date: / / Digital link: _____  Endoscopic ultrasound Date: / /  Staging laparoscopy (laparotomy) Date: / /  Pathology: _____	Staging of disease with CT (chest, abdomen and pelvis), MRCP and endoscopic ultrasound (lymph node evaluation). A digital link must be attached with MRCP for validation by radiology of SNT.  Absence of metastatic disease (intrahepatic and extrahepatic) according to CT (chest, abdomen and pelvis) and MRCP within 3 months before the multidisciplinary meeting at local institution.  Staging laparoscopy or staging laparotomy must be performed before LT. The routine sampling of lymph nodes 8a, 8p, 12a and 12p is mandatory in order to exclude tumor spread Staging operation must be performed within 60 days before LT. * Patients can be included in the list for LT before this operation; however, the submission of anatomopathological analysis is mandatory in order to be active in the LT list  * Select in the figure on the left the lymph node samples taken for analysis  Attach the medical and examination reports.
<b>Previous treatment:</b>  <input type="checkbox"/> chemotherapy  <input type="checkbox"/> external radiotherapy  <input type="checkbox"/> brachytherapy	Tumors ≤ 3 cm: recommended to perform at least one type of neoadjuvant chemotherapy and one radiotherapy modality (external radiotherapy or brachytherapy). In such cases, DDLT and LDLT will be allowed.  Tumors > 3 cm and < 4 cm: recommended to perform at least one line of neoadjuvant chemotherapy and one radiotherapy modality (external radiotherapy or brachytherapy). In such cases, only LDLT will be allowed.  Attach the medical report of chemotherapy used, method of radiotherapy and number of cycles.
Medical report justifying unresectability. Please provide at least one of the reasons below:	
<input type="checkbox"/> Unlikely R0 resection	<input type="checkbox"/> Primary sclerosis cholangitis
MD signature and stamp: _____	Date: _____



LT=liver transplantation; DDLT=deceased-donor liver transplantation; LDLT=living-donor liver transplantation; hCCA=hilar cholangiocarcinoma; SNT=national system of transplants; CT= computed tomography; MRI=magnetic resonance imaging; MRCP=magnetic resonance cholangiopancreatography

**Figure 2** - Document of SNT to be filled in to request a special situation for hCCA.

12a and 12p). Finally, it is important to highlight the difficulty in determining the ideal time to perform this procedure, since the waiting list to receive an organ is very variable across the country.

The regulation of this protocol is now in progress in the SNT for validation in the Brazilian national territory<sup>2</sup>.

## CONCLUSION

A liver transplantation protocol for hilar cholangiocarcinoma was created in order to standardize the treatment, as well as enable a better assessment of surgical results, disease-free survival and overall survival of these patients.

## REFERENCES

- Bergquist A, von Seth E. Epidemiology of cholangiocarcinoma. *Best Pract Res Clin Gastroenterol.* 2015;29(2):221-32. doi: 10.1016/j.bpg.2015.02.003.
- Brasil. Decreto n. 2.268, de 30 de junho de 1997. Regulamenta a Lei n. 9.434, de 4 de fevereiro de 1997, que dispõe sobre a remoção de órgãos, tecidos e partes do corpo humano para fins de transplante e dá outras providências. Brasília: Diário Oficial da União 1 jul 1997; (1):13739.
- Darwish Murad S, Kim WR, Harnois DM, Douglas DD, Burton J, Kulik LM, Botha JF, Mezrich JD, Chapman WC, Schwartz JJ, Hong JC, Emond JC, Jeon H, Rosen CB, Gores GJ, Heimbach JK. Efficacy of neoadjuvant chemoradiation, followed by liver transplantation, for perihilar cholangiocarcinoma at 12 US centers. *Gastroenterology.* 2012;143(1):88-98.e3; quiz e14. doi: 10.1053/j.gastro.2012.04.008.
- De Vreede I, Steers JL, Burch PA, Rosen CB, Gunderson LL, Haddock MG, Burgart L, Gores GJ. Prolonged disease-free survival after orthotopic liver transplantation plus adjuvant chemoirradiation for cholangiocarcinoma. *Liver Transpl.* 2000; 6(3):309-16. doi: 10.1053/lv.2000.6143.
- Fonseca GM, Jeismann VB, Kruger JAP, Coelho FF, Montagnini AL, Herman P. Liver resection in Brazil: a national survey. *Arq Bras Cir Dig.* 2018;21;31(1):e1355. doi: 10.1590/0102-672020180001e1355.
- Goldaracena N, Gorgen A, Sapisochin G. Current status of liver transplantation for cholangiocarcinoma. *Liver Transpl.* 2018; 24(2):294-303. doi: 10.1002/lt.24955.
- Harris PA, Taylor R, Thielke R, Payne J, Gonzalez N, Conde JG. Research electronic data capture (REDCap)--a metadata-driven methodology and workflow process for providing translational research informatics support. *J Biomed Inform.* 2009;42(2):377-81. doi: 10.1016/j.jbi.2008.08.010.
- Heimbach JK, Gores GJ, Haddock MG, Alberts SR, Nyberg SL, Ishitani MB, Rosen CB. Liver transplantation for unresectable perihilar cholangiocarcinoma. *Semin Liver Dis.* 2004;24(2):201-7. doi: 10.1055/s-2004-828896.
- Iwatsuki S, Todo S, Marsh JW, Madariaga JR, Lee RG, Dvorchik I, Fung JJ, Starzl TE. Treatment of hilar cholangiocarcinoma (Klatskin tumors) with hepatic resection or transplantation. *J Am Coll Surg.* 1998;187(4):358-64. doi: 10.1016/s1072-7515(98)00207-5.
- Jarnagin WR, Fong Y, DeMatteo RP, Gonen M, Burke EC, Bodniewicz BS J, Youssef BA M, Klimstra D, Blumgart LH. Staging, resectability, and outcome in 225 patients with hilar cholangiocarcinoma. *Ann Surg.* 2001;234(4):507-17; discussion 517-9. doi:10.1097/0000658-200110000-00010.
- Lima AS, Pereira BB, Jungmann S, Machado CJ, Correia MITD. Risk factors for post-liver transplant biliary complications in the absence of arterial complications. *Arq Bras Cir Dig.* 2020;33(3):e1541. doi: 10.1590/0102-672020200003e1541.
- Mansour JC, Aloia TA, Crane CH, Heimbach JK, Nagino M, Vauthey JN. Hilar cholangiocarcinoma: expert consensus statement. *HPB (Oxford).* 2015;17(8):691-9. doi: 10.1111/hpb.12450.
- Mantel HT, Westerkamp AC, Adam R, Bennet WF, Seehofer D, Settmacher U, Sánchez-Bueno F, Fabregat Prous J, Boleslawski E, Friman S, Porte RJ. European Liver and Intestine Transplant Association (ELITA). Strict Selection Alone of Patients Undergoing Liver Transplantation for Hilar Cholangiocarcinoma Is Associated with Improved Survival. *PLoS One.* 2016;11(6):e0156127. doi: 10.1371/journal.pone.0156127.
- Meyer CG, Pennl, James L. Liver transplantation for cholangiocarcinoma: results in 207 patients. *Transplantation.* 2000;69(8):1633-7. doi: 10.1097/00007890-200004270-00019.
- Pinto LEV, Coelho GR, Coutinho MMS, Torres OJM, Leal PC, Vieira CB, Garcia JHP. Risk factors associated with hepatic artery thrombosis: analysis of 1050 liver transplants. *Arq Bras Cir Dig.* 2021;33(4):e1556. doi: 10.1590/0102-672020200004e1556.
- Rea DJ, Heimbach JK, Rosen CB, Haddock MG, Alberts SR, Kremers WK, Gores GJ, Nagorney DM. Liver transplantation with neoadjuvant chemoradiation is more effective than resection for hilar cholangiocarcinoma. *Ann Surg.* 2005;242(3):451-8; discussion 458-61. doi: 10.1097/01.sla.0000179678.13285.fa.
- Robles R, Figueras J, Turrion VS, Margarit C, Moya A, Varo E, Varo E, Calleja J, Valdivieso A, Valdecasas JC, López P, Gómez M, de Vicente E, Loínaz C, Santoyo J, Fleitas M, Bernardos A, Lladó L, Ramírez P, Bueno FS, Jaurrieta E, Parrilla P. Spanish experience in liver transplantation for hilar and peripheral cholangiocarcinoma. *Ann Surg.* 2004;239(2):265-71. doi:10.1097/01.sla.0000108702.45715.81.
- Sapisochin G, Javle M, Lerut J, Ohtsuka M, Ghobrial M, Hibi T, Kwan NM, Heimbach J. Liver Transplantation for Cholangiocarcinoma and Mixed Hepatocellular Cholangiocarcinoma: Working Group Report From the ILTS Transplant Oncology Consensus Conference. *Transplantation.* 2020;104(6):1125-1130. doi: 10.1097/TP.0000000000003212.
- Sudan D, DeRoover A, Chinnakotla S, Fox I, Shaw B Jr, McCashland T, Sorrell M, Tempero M, Langnas A. Radiochemotherapy and transplantation allow long-term survival for nonresectable hilar cholangiocarcinoma. *Am J Transplant.* 2002; 2(8):774-9. doi: 10.1034/j.1600-6143.2002.20812.x.
- Tan EK, Taner T, Heimbach JK, Gores GJ, Rosen CB. Liver Transplantation for Peri-hilar Cholangiocarcinoma. *J Gastrointest Surg.* 2020;24(11):2679-2685. doi: 10.1007/s11605-020-04721-4.
- Teixeira UF, Goldoni MB, Waechter FL, Sampaio JA, Mendes FF, Fontes PRO. Enhanced recovery (ERAS) after liver surgery: comparative study in a Brazilian tertiary center. *Arq Bras Cir Dig.* 2019;32(1):e1424. doi: 10.1590/0102-672020180001e1424.