

ABCDDV/1064

ABCD Arq Bras Cir Dig Letter to the Editor

2014;27(4):303

DOI: <http://dx.doi.org/10.1590/S0102-67202014000400018>

COLORECTAL CANCER AND SITUS INVERSUS TOTALIS: CASE REPORT

Câncer colorretal e situs inversus totalis: relato de caso

Marcelo Pandolfi **BASSO**, Adriana Borgonovi **CHRISTIANO**,
Francisco de Assis **GONÇALVES-FILHO**, Marcelo Maia
Caixeta de **MELO**, Luiz Sérgio **RONCHI**, João Gomes
NETINHO

From the Disciplina de Coloproctologia, Departamento de Cirurgia, Faculdade de Medicina de São José do Rio Preto (Coloproctology Service, Department of Surgery, São José do Rio Preto School of Medicine), São José do Rio Preto, SP, Brazil

Financial source: none
Conflicts of interest: none

Correspondence:

Marcelo Pandolfi Basso

E-mail: celinpb@hotmail.com

Received for publication: 08/10/2013

Accepted for publication: 21/08/2014

INTRODUCTION

Situs inversus totalis is a rare congenital condition that occurs in one out of 4000–20000 people, characterized by complete transposition of the thoracic and abdominal viscera¹⁻¹⁴. In contrast, situs solitus is a term that refers to the normal arrangement of body organs. Any disposition of organs between these two extremes is designated by situs ambiguous, situs transversus or situs inversus partialis⁸.

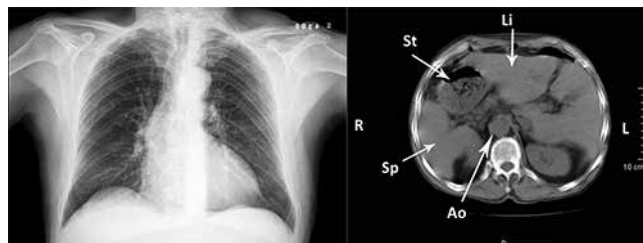The etiologic nature of this anomaly is not known. This condition is typically associated with normal life expectancy unless a gastrointestinal or cardiac anomaly is present^{2,8}. The typical cardiac anomaly has from 3–5% incidence, is transposition of the great vessels, and 80% of these patients have a right sided aortic arch⁵. Other vascular anomalies are variation of celiac trunk and superior mesenteric artery⁴. There are also anomalies of the gastrointestinal system to include biliary tree atresia, duodenal atresia, preduodenal portal vein, colonic aganglionosis, malrotation of the intestine, polysplenia/asplenia, anular pancreas, diaphragmatic hernia and others^{4,5}. Moreover, it may be associated with clinical syndromes, like Kartagener's (situs inversus, chronic rhinosinusitis and bronchiectasias)¹⁴.

This anomaly is not a premalignant condition. However, many cases of malignant neoplasms and situs inversus totalis have been reported, especially gastric cancer⁸. Association between colorectal cancer and situs inversus totalis is rare.

CASE REPORT

Man with 74 years-old, white, ex-alcoholic and smoker had family history essentially negative for either situs inversus totalis, familial and hereditary disease or colorectal cancer. The patient didn't know he had situs inversus totalis. He had a history of abdominal pain in left hemiabdome, asthenia and mucocutaneous pallor for the last two years. He had normal physical examination, except for pale mucous membranes, heart sounds audible in the right chest and slightly painful on palpation of the left abdomen. Abdominal ultrasound showed only abdominal situs inversus and colonoscopy demonstrated sub-occlusive lesion in hepatic angle of the colon, which

biopsy revealed moderately differentiated adenocarcinoma. His carcinoembryonic antigen was 1,8 ng/dL. ECG and chest radiography indicated dextrocardia. Computerized tomography showed complete transposition of abdominal viscera, confirming situs inversus totalis (Figure 1).



Li=liver; St=stomach; Sp=spleen; Ao=aorta

FIGURE 1 - Chest x-ray film shows dextrocardia and findings of inversion of the abdominal organs in abdominal computed tomography

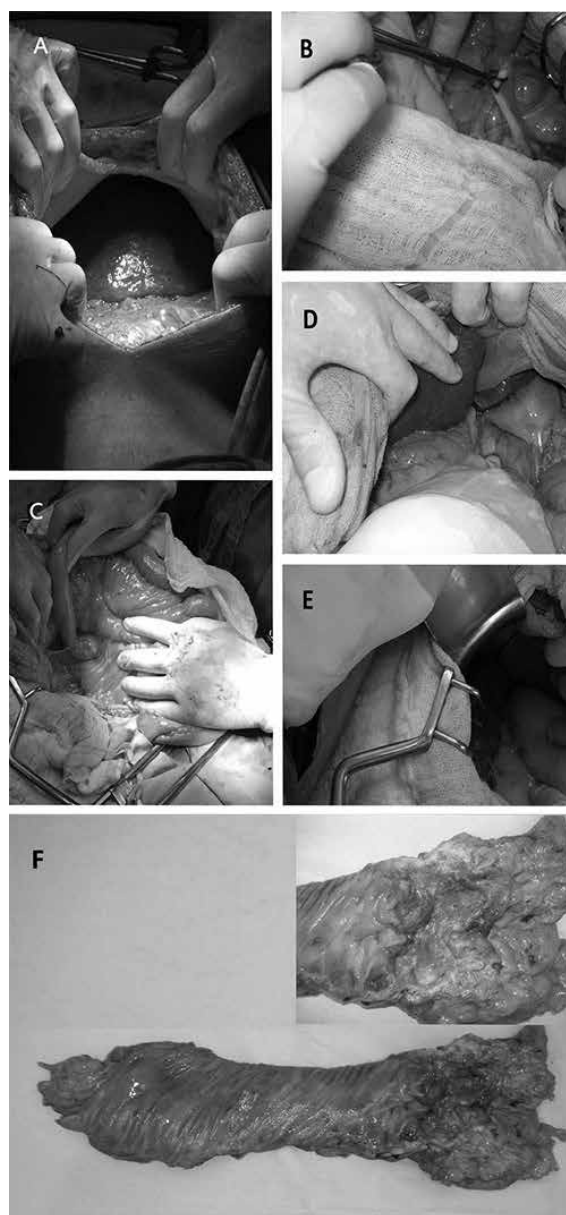


FIGURE 2 - Surgical abdominal findings: A) liver in the left upper part; B) appendix in lower left; C) duodenojejunal angle to the right; D) gallbladder in the left upper part; E) spleen and great curvature of the stomach in the right upper position; F) resected specimen showing an ulcerated mass in hepatic flexure of the colon.

According to these findings, a proximal hemicolectomy was carried out with lymph nodal dissection followed by ileocolic anastomosis. The cavity inventory at laparotomy showed situs inversus abdominal and presence of spherical and hard lesion in the hepatic flexure of colon (Figure 2) with absence of macroscopic metastatic involvement.

Anatomopathological evaluation (Figure 2) confirmed tubular adenocarcinoma, moderately differentiate; presence of perineural invasion; vascular and angiolymphatic involvement were absent. TNM staging was T3N0M0, stage IIA.

Postoperative course was uneventful and he was discharged from the hospital on the 4th day after operation. He began adjuvant Mayo Clinic regimen, but stopped in the 4th cycle due toxicity of the gastrointestinal tract. Up to the moment of this writing, no sign of recurrence or metastasis has been observed.

DISCUSSION

In the literature, there are 13 cases recognized about this issue, making a total of 14 cases, by adding this report. Enrolling all papers, colorectal cancer was more frequent in women (n= 9; 64%) than men (n=5; 36%). The age ranged from 41- 78 years, mean of 63,71 and median of 61,5 (SD=±10,40). Adenocarcinoma was the histological type present in all cases. Regarding the location of the tumor, there was a predominance of the transverse colon (n=6; 43%), with emphasis on hepatic flexure of the colon (n=5; 36%), followed by ascending colon (n=4; 29%), rectum (n=3; 21%) cecum and sigmoid colon (n=1; 7% in both topographies). Grouping the tumors in the right colon (proximal to splenic flexure of the colon) and left (from the splenic flexure of the colon), noted a prevalence of 79% and 21%, respectively, with statistical significance (p=0.029), according to an exact test for proportion and level of significance was $\alpha=0.05$. Regarding the surgical procedure, 10 (71%) patients underwent proximal hemicolectomy, and one case each (7%) of rectosigmoidectomy, abdomino-perineal amputation, transverse colectomy and decompression colostomy. Laparotomic surgical procedure accounted for 93% and only one case was operated by laparoscopic approach (7%)⁸.

Surgical procedures are considered more difficult in patients with situs inversus than other patients because of different anatomic position of organs, especially in laparoscopic surgery³.

The preoperative evaluation for situs inversus includes two main objectives: evaluation for gastrointestinal and cardiac anomalies and orientation of the viscera. The extent of evaluation should be based on the complexity of the procedure. Anomalies should be defined by using various imaging technologies to determine appropriate surgical treatment and decrease surgical difficulties and time^{4,5}. Furthermore, the risk of occurrence of intra-operative complications is higher in comparison with the procedures of patients without situs inversus totalis¹. Besides, incorrect surgical incision and a second operation are avoided².

REFERENCES

1. Bielecki K, Gregorczyk M, Baczuk L. Visceral situs inversus in three patients. *Wiad Lek.* 2006; 59(9-10): 707-9.
2. Blegen HM. Surgery in situs inversus. *Ann Surg.* 1949; 129:244-59.
3. Fujiwara Y, Fukunaga Y, Higashino M, Tanimura S, Takemura M, Tanaka Y and Osugi H. Laparoscopic hemicolectomy in a patient with situs inversus totalis. *World J Gastroenterol.* 2007; 13(37): 5035-37.
4. Goi T, Kawasaki M, Yamazaki T, Koneri K, Katayama K, Hirose K and Yamaguchi A. Ascending colon cancer with hepatic metastasis and cholelithiasis in a patient with situs inversus totalis without any expression of UVRAG mRNA: report of a case. *Surg Today.* 2003; 33:702-6.

5. Greene QJ, Cheadle WG. Ascending colon cancer in a patient with situs inversus. *Am Surg.* 2007; 73(8):831-2.
6. Grigorjew A, Andrzejczak L. Colonic cancer in situs inversus. *Wiad Lek.* 1982; 35:901-2.
7. Ikenaga M, Mishima H, Hirao M, Fujitani K and Tsujinaka T. A case of multiple colorectal cancer with situs inversus totalis. *J Jpn Coll Surg.* 2005; 30(1):52-6.
8. Iwamura T, Shibata N, Haraguchi Y, Hasashi Y, Nishikawa T, Yamada H, Hayashi T and Toyoda K. Synchronous double cancer of the stomach and rectum with situs inversus totalis and polysplenia syndrome. *J Clin Gastroenterol.* 2001; 33(2):148-153.
9. Nagase T, Adachi I, Yoshino Y, Morita K, Murakami N and Yamada T. A case of ascending colon cancer with total situs inversus and intestinal malrotation. *J Jpn Surg Assoc.* 2003; 64(7):1773-6.
10. Reiff PS, Mathias LR, Souza IES, Reif ABM. Surgery in situs inversus. A case report (acute cholecistitis and carcinoma of the colon). *Rev bras Cir.* 1992; 82(4):149-50.
11. Shibuya J, Nakakuma T, Oshima Y, Kakita A. A operation case of situs inversus totalis associated with a transverse colon cancer. *Nippon Gekakai Rengo Gakkaishi.* 2003; 28(2):271-4.
12. Takizawa Y, Maeda K, Shimizu J, Kawaura Y. A case of colonic cancer associated with situs inversus totalis. *Surgery.* 2002; 64(2):245-8.
13. Wright CB, Morton CB. Situs inversus totalis with adenocarcinoma of the cecum: case report. *Am Surg.* 1971; 37(2): 65-6.
14. Yoshida J, Tsuneyoshi M, Nakamura K, Murakami T, Akamine Y. Primary ciliary dyskinesia with transverse colon carcinoma. *Am J Clin Pathol.* 1986; 85:101-104.

ABCDDV/1065

ABCD Arq Bras Cir Dig Letter to the Editor
2014;27(4):304

DOI: <http://dx.doi.org/10.1590/S0102-67202014000400019>

ENDOMETRIOMA LOCALIZED IN THE RECTUS ABDOMINIS MUSCLE: A CASE REPORT AND REVIEW OF LITERATURE

Endometrioma localizado no músculo reto abdominal: relato de caso e revisão da literatura

Omer F. OZKAN¹, Oztekin CIKMAN¹, Hasan Ali KIRAZ², Emir C. ROACH, Mehmet Ali KARACAER¹, Muammer KARAAYVAZ¹

From ¹Canakkale 18 Mart University, Medical School, Department of General Surgery and ²Canakkale 18 Mart University, Medical School, Department of Anesthesiology, Canakkale, Turkey

Correspondence:
Omer Faruk Ozkan, MD
E-mail: ozkanfomer@gmail.com

Financial source: none
Conflicts of interest: none

Fianciamento: nenhum
Conflito interesse: enhum

Received for publication: 29/08/2013
Accepted for publication: 24/07/2014

INTRODUCTION

Endometrial tissue localized outside the uterine cavity is defined as endometriosis. It commonly has been demonstrated in the ovaries, peritoneal surfaces, vagina, scar tissues, cervix, fallopian tubes, rectum, urinary tract, pouch of Douglas and possibly any organ in the abdomen¹. The estimated prevalence reported in literature ranges from 8-15%². Extra-pelvic localization of endometriomas are relatively rare. Especially abdominal wall placements are very infrequent. Usually such cases are associated with surgical scars³. The proposed mechanisms that have been put include retrograde menstruation, venous or lymphatic dissemination or metastasis, and mechanical transplantation into scars at the time of surgery⁴.