

## ACTINIC TERMINAL ILEUM STENOSIS AFTER RADIOTHERAPY FOR ENDOMETRIUM TUMOR ASSOCIATED WITH SEVERE MALNUTRITION

*Estenose actínica de íleo terminal pós-radioterapia para tumor de endométrio associada à desnutrição severa*

Carlos Alberto da Silva **GOMES**, Larissa Cavalcanti **BARROS**, Larissa Soares Bezerra Santos Torres de **MELO**, Victor Cardoso **ROCHA**

From Surgery Unit, State General Hospital Osvaldo Brandão Vilela, Maceió, AL, Brazil

### Correspondence:

Carlos Alberto da Silva Gomes  
E-mail: carlosagomes@hotmail.com

Financial source: none  
Conflicts of interest: none

Received for publication: 26/04/2011  
Accepted for publication: 215/01/2012

solids in few minutes frequently had vomiting with impairment of nutrition.

On clinical examination she was eupneic, dehydrated (+ + + / 4 +), anicteric, normotensive, afebrile, pain with abdominal palpation and abdominal fluid sounds. Abdominal radiograph showed gas reduction and loop edema (Figure 1). Colonoscopy showed no change.

## INTRODUCTION

Radiotherapy is used as adjuvant therapy in endometrial cancer and is one of the most important therapeutic modalities in the treatment of this cancer<sup>3,4,5</sup>. Minimization of the exposure of healthy tissue adjacent to the radiation through the protection of intra-abdominal organs can avoid actinic injuries<sup>3</sup>.

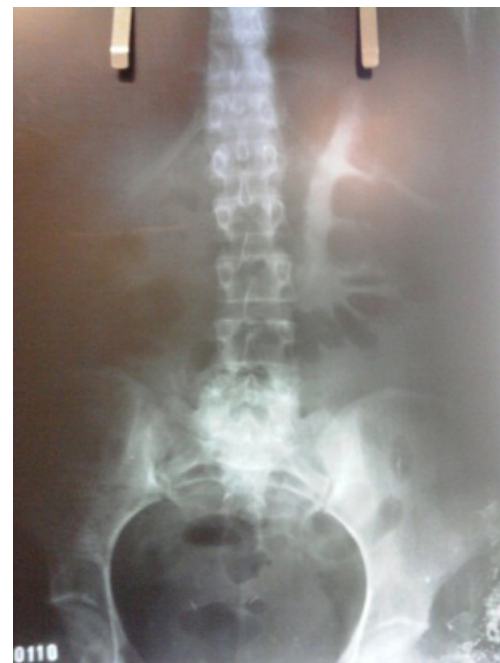With the use of pelvic radiotherapy there was an increase on the incidence of actinic lesions acute or chronic not only represented by mucositis, but also by functional disturbances, as erectile activity, bladder continence or rectal injury<sup>8</sup>.

About 75% of patients with pelvic radiation develop anorectal symptoms like urgency, rectal pain, tenesmus and bleeding<sup>10</sup>. However, more rarely may occur fistulas and strictures, which must be distinguished from Crohn's disease, due to similarity in signs and symptoms.

The objective of this paper is to report one case with tumor of endometrium treated by radiation that evolved six years later an actinic stenosis of the terminal ileum.

## CASE REPORT

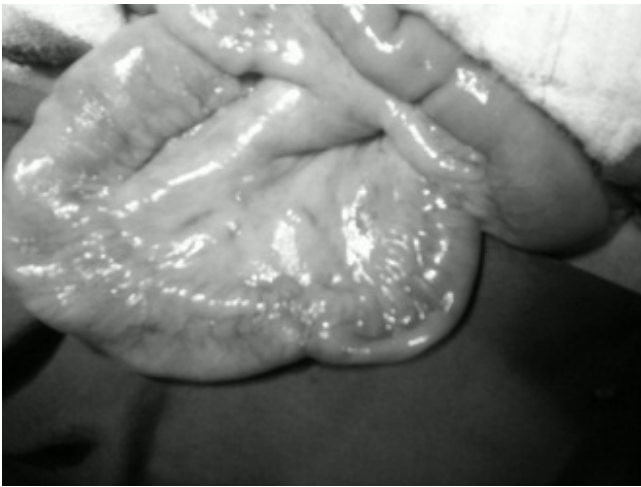Woman of 39 years, was admitted to the emergency department with a history of prior pelvic radiotherapy for tumor of the uterus about six years with loss of 15 kg in a month, cramping and abdominal pain. She reported that after drinking liquids and / or



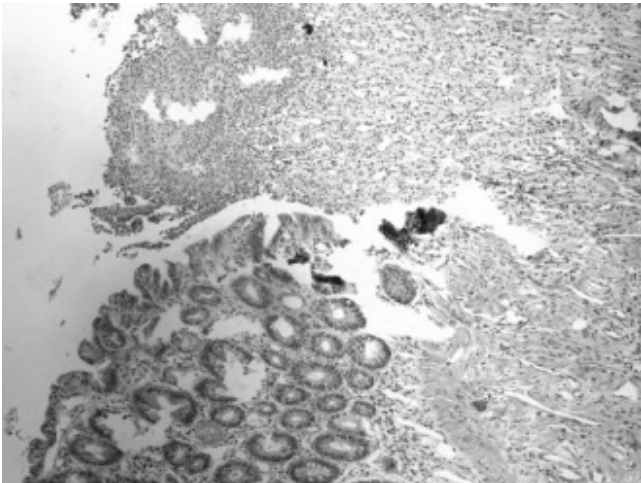
**FIGURE 1** - Radiological abdominal aspect with edema of small bowel loop

She underwent exploratory laparotomy with midline incision that showed partial stenosis of the ileum 20 cm from the ileocecal valve (Figure 2) with normal structures in cavity.

Bowel resection and anastomosis was performed in a single plane. The macroscopic examination of the surgical specimen showed brown external color and narrowing site. The mucosa exhibited brown staining without changes. At microscopic sections fragments of tissue and inflammatory reaction were present. Extensive areas of necrosis and inflammatory reaction,



**FIGURE 2** - Ileum stenosis 20 cm from ileocecal valve represented by lymphocytes, plasma cells, neutrophils, vascular congestion and interstitial edema, revealed necrotizing inflammatory process (Figure 3).



**FIGURE 3** - Microscopy of the small intestine shows necrotizing inflammation superiorly and, inferiorly, presence of unchanged glands

The patient was discharged five days after surgery.

## DISCUSSION

Decrease in the incidence of local complications of actinic nature occurred with the advancement in the techniques of pelvic radiotherapy. The newer techniques have better distribution of radiation, causing minor damage to adjacent structures to the target organ<sup>9</sup>.

This patient had a rare complication of radiotherapy and probably due to the dosing. It is known that radiotherapy treatments below 45 Gy rarely cause complications in pelvic organs<sup>1,3</sup>. Moreover, patients undergoing radiation around 75 Gy (maximum radiation dose prescribed to the pelvis) show more

severe complications in about 60% of the cases<sup>1</sup>. This fact possibly explains the extensive stenosis of the present case.

Acute injuries are common, compromise virtually all irradiated patients, depending on the radiation dose; the acute symptoms do not last long. The chronic lesions are rare and can take years to present symptoms<sup>7</sup>.

To mitigate complications, such as stenosis in distant organs, is used three-dimensional conformal radiotherapy. This is the method that is directed almost exclusively to the tumor; thus, is more effectively and has minimal side effects<sup>7</sup>.

Crohn's disease is characterized by chronic inflammation of transmural nature, persistent or relapsing, compromising not only the mucosa as well as the intestinal wall, mesentery and lymph nodes. Often results in stenosis, ulcers and / or fistula<sup>6</sup>. This patient had some peculiarities common to other intestinal lesions, complicating the diagnostic decision by either disease. In this report the signs and symptoms were similar to those of Crohn's disease, distinguished only by the history of radiotherapy. The differential diagnosis of actinic reaction was only confirmed by pathological examination.

## REFERENCES

- 1- Bem, MD; Bem, S; Singh, A. Use of Hyperbaric Oxygen Chamber in the Management of Radiation-Related Complications of the Anorectal Region. *Dis Colon Rectum* 2003; 43, (10): p 1435-1438.
- 2- Fundação Oncocentro de São Paulo (FOSP). Mortalidade por câncer no Estado de São Paulo no biênio 2001–2002. Disponível em: [http://www.fosp.saude.sp.gov.br/html/fr\\_dados.html](http://www.fosp.saude.sp.gov.br/html/fr_dados.html). Acessado em 5/4/2010.
- 3- Johnston, MJ; Robertson, GM; Frizelle, FA. Management of Late Complications of Pelvic Radiation in the rectum and Anus. *Dis Colon Rectum* 2003; 46, (2): p 247-256.
- 4- Kushwaha, RS; Hayne, D; Vaizey, CJ et al. Physiologic Changes of the Anorectum After Pelvic radiotherapy for the Treatment of Prostate and Bladder Cancer. *Dis Colon Rectum* 2004; 46, (9): p 1182-1188.
- 5- Lucarotti, ME; Mountford, RA; Bartolo, DCC. Surgical Management of Intestinal Radiation Injury. *Dis Colon Rectum* 1991; 34, (10): p 865-869.
- 6- Santos Jr, JCM. Doença de Crohn – Aspectos Clínicos e Diagnósticos. *Revista Brasileira de Coloproctologia*, 1999; 19(44): 276 – 285.
- 7- Santos JR., Júlio César Monteiro dos. Radioterapia: lesões inflamatórias e funcionais de órgãos pélvicos. *Rev bras. colo-proctol.* [online]. 2006, vol.26, n.3, pp. 348-355. ISSN 0101-9880. doi: 10.1590/S0101-8802006000300019.
- 8- Tagkalidis PP, Tjandra JJ. Chronic radiation proctitis. *ANZ J Surg* 2001;71:230-7.
- 9- Taussky, D; Schneider, U; Rousson, V; Pescia, R. Toxicity Correlated to Dose-Volume Histograms of the Rectum in Radiotherapy of the Prostate. *American Journal of Clinical Oncology* 2003; 26, (5): p 144-149.
- 10- Wingo PA, Cardinez CJ, Landis SH, et al. Long-term trends in cancer mortality in the United States, 1930-1998. *Cancer* 2003;97(12 Suppl):3133–3275.