

NEW TECHNICAL OPTION FOR INTRAOPERATIVE CHOLANGIOGRAPHY

Nova opção técnica para colangiografia transoperatória

Alcino Lázaro da **SILVA** e André Rossetti **PORTELA**

From Department of Surgery of the Federal University of Minas Gerais, Belo Horizonte, MG, Brasil.

ABSTRACT - Background - First described 70 years ago, intraoperative cholangiography is an effective method of study of the biliary tract. There are several ways of its realization. **Aim** – To add a new technique of cholangiography in relation to the classical one using only two radiographs for static and dynamic interpretation. **Methods** - Cholangiography is made with two X-rays, the first with overpressure and the second three minutes later, in emptying time. It was performed on 39 patients with gallstones undergoing cholecystectomy by laparotomy. The evaluation of the radiographs was based on a radiographic classification created by the authors, varying in degrees in the overpressure from 0 to 3 and emptying of 1 to 3. **Results** - The complete or almost complete filling of the biliary tree was found in 66.7% of patients in the phase of overpressure. In the emptying phase, 59% of patients had 1/3 or less contrast on biliary tree. There was a need to add additional radiographs in 5% of patients after seven minutes, with complete emptying. **Conclusion** - The proposed technique proved feasible, simple, fast and effective.

HEADINGS - Cholangiography. Colecistectomia. Gallstone.

Correspondence:

Alcino Lázaro da Silva,
e-mail: andrerossettiportela@gmail.com

Financial source: none
Conflicts of interest: none

Recived for publication: 24/01/2011
Accepted for publication: 10/05/2011

DESCRITORES - Colangiografia. Colecistectomia. Litíase biliar.

RESUMO – Racional - Descrita há mais de 70 anos, a colangiografia transoperatória é método eficaz de estudo da via biliar. Existem diversas formas de sua realização. **Objetivo** - Acrescentar uma nova forma de colangiografia em relação à técnica clássica usando somente duas radiografias para interpretação estática e dinâmica. **Métodos** - A colangiografia é feita com duas radiografias, a primeira em hiperpressão e a segunda três minutos após, em esvaziamento. Ela foi realizada em 39 pacientes portadores de colecistólitíase, submetidos à colecistectomia por laparotomia. A avaliação dos radiogramas foi feita com base em uma classificação radiográfica, criada pelos autores em graus que variam na hiperpressão de 0 a 3 e no esvaziamento de 1 a 3. **Resultados** - O enchimento total ou quase total da árvore biliar foi encontrado em 66,7% dos pacientes na fase de hiperpressão. Na fase de esvaziamento, 59% dos pacientes estavam com um terço ou menos de contraste. Houve a necessidade de acrescentar radiografia adicional em 5% dos pacientes após sete minutos, com esvaziamento completo. **Conclusão** - A proposta técnica mostrou-se exequível, simples, rápida e eficaz.

INTRODUCTION

The study of the biliary tract and their diseases is cause for concern among physicians. Dating back to 1341 (Gentile of Foligno) gallstones were first described in cadaver. On July 15, 1867, John S.Bobs, believing that the removal of the gallstone would be the treatment for biliary disease, performed the first successful cholecystostomy. With the idea that the withdrawal of the gallstones with the maintenance of the gallbladder would not be the definitive treatment, Carl Langenbuch made the first successful cholecystectomy on July 5, 1882¹. On June 18, 1931, Pablo Luis Mirizzi made the first intraoperative cholangiography (CT) and drew attention to it in articles published in several languages, motivating its use in routine management of biliary tree^{3,7,8,10}. Since then, CT has been motive for controversies about the technique, indication, time spent, the need to make it in all cases and additional costs.

After the report of Mirizzi, several catheters for intubation of the cystic duct as well as various techniques for making radiographs appeared on literature^{5,9}. The classic technique described by Le Quesne is achievement by three radiographs^{2,4}.

In the first, after intubation of the cystic duct, is injected 3 ml to 5 ml of contrast to highlight the presence of calculi in the common bile duct. After three minutes it is done another X-ray to assess the patency of the papilla. Finally, contrast injection of 10 ml to 15 ml under pressure is done to study the intra and extrahepatic biliary tree².

Thinking to simplify the method, without losing effectiveness and making it more practical and less costly, this paper aims to demonstrate the feasibility study of the biliary tree performing only two radiographs in CT.

METHOD

CT were performed in 39 patients undergoing cholecystectomy by laparotomy. All had signs and symptoms of gallstones, without clinical obstruction of main bile duct.

According to the performed technique, the cystic duct was dissected until the emergence of common bile duct and ligated approximately 0.8 cm from the common bile duct; between the common bile duct and the ligation point it was done a lateral opening of cystic duct with partial closure. The cystic duct was intubated with a 4 or 6 FG catheter. The patient was placed in inclined and right side, with about 20° angle, disassociating the spine from the image and improving the quality of the examination.

Technique

First X-ray or overpressure

Was injected 15 cm³ of iodine contrast diluted in 50% of saline solution, with manual high pressure above the residual pressure of biliary tree and immediately made the radiograph. This manouver studied the biliary tree both intra and extrahepatic. The duodenal papilla often reacts and closes with the pressed contrast, facilitating reflux into the liver. Images representing gallstones, tumors, strictures, extrinsic compressions are well seen in this radiograph. The duodenal papilla, spastic or damaged by tumors and inflammatory processes, also is shown in this X-ray.

Second X-ray or emptying

After three minutes of contrast injection, it was done the second radiograph. It would reveal no contrast, small amount, reasonable or almost total contrast. This is the dynamic state. In the same X-ray it could be seen the silhouette of residual biliary tree, and minor gallstones not identified in the overpressure (1st X-ray) and other abnormalities, difficult to be diagnosed when there was a lot of contrast.

For teaching purposes and accurate evaluation, was created by the authors radiographic classification in degrees (Figures 1 and 2), where the overpressure varies from 0 to 3 (Figures 3A and 4A) and the emptying of 1 to 3 (Figures 3B and 4B).

Overpressure	
Grade 0	Contrasted entire biliary tree
Grade 1	2 / 3 contrasted
Grade 2	1 / 2 contrasted
Grade 3	1 / 4 contrasted or complete emptying

FIGURA 1 – Radiographic classification in degrees of contrasted main bile duct

Emptying (after three minutes)	
Grade 1	1 / 3 complete emptying of contrast or
Grade 2	½ contrast
Grade 3	¾ or absence of contrast emptying

FIGURE 2 – Radiographic classification in degrees of the main bile duct in emptying phase

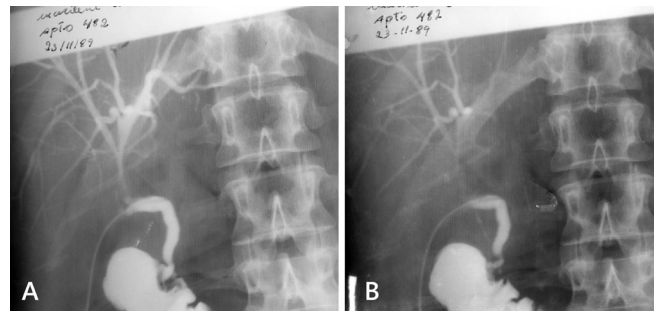


FIGURA 3 – A: Radiogram in overpressure showing the entire biliary tree contrasted - grade 0; B: Radiogram in emptying time with half the contrast in the biliary tree - grade 2

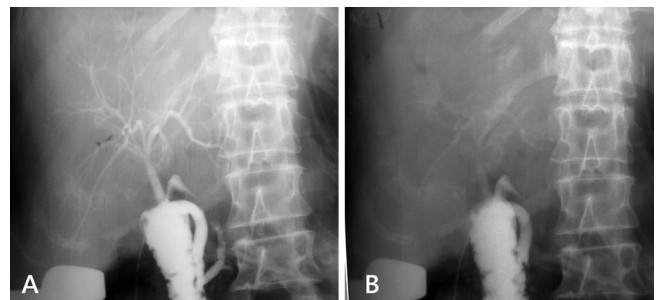


FIGURA 4 – A: X-ray phase in overpressure, with two thirds of the biliary tree contrasted - grade 1; B: Radiogram in draining stage, showing contrast in less than a third in biliary tree - grade 1

RESULTS

Of the 39 patients who underwent CT, 66.7% had complete or almost complete filling of the biliary tree intra and extra-hepatic phase of overpressure and 5.1% contrasted quarter or less (Table 1). Three minutes later, 59% of patients remained with 1/3 or less contrast in biliary tree. On the other hand, in eight patients remained three quarters or more of contrast in the biliary tree (Table 2). Of

these cases, two needed to take radiographs after seven additional minutes. In all these cases, representing 5% of the total, were completely empty after the third X-ray.

TABLE 1 – Frequencies in degrees of contrast of the biliary tract in 39 patients in the overpressure phase

Overpressure	
	N - %
Grade 0	26 – 66,7%
Grade 1	04 – 10,3%
Grade 2	07 – 17,9%
Grade 3	02 – 5,1%
Total	39 – 100%

TABLE 2 - Frequencies in degrees of contrast in biliary tract in 39 patients, emptying phase

Deflation	
	N - %
Grade 1	23 – 59%
Grade 2	08 – 20,5%
Grade 3	08 – 20,5%
Total	39 – 100%

Alterations observed were: one case of colecistoduodenal fistula, three kinking of the choledochus and one periampular cyst. There was no evidence of biliary gallstone in the main biliary duct.

The patients without postoperative complications.

DISCUSSION

The intraoperative cholangiography was first described more than 70 years ago and today the biliary tract can be studied preoperatively with certainty by ultrasound, computed tomography, magnetic resonance cholangiopancreatography and others. Even after so many years, CT is good technical resource in bile duct surgery investigation. Versatile, can be performed either by laparotomy in the operation, such as in laparoscopy. The mean duration of a CT was 20 minutes and images could be obtained with both simple X-ray machine or image intensifier^{2,11}.

Was found in the literature CT being performed with till eight radiographs, an average of 2,48². The lack of standardization in the performance of CT, found in several publications and daily activity, is worrisome suggesting that the systematization would bring advantages, such as: reduction of the false negatives and false positives, better learning for beginners, standard documentation, standardized didactic and scientific findings⁶.

With the advent of laparoscopy, concern about safety of anatomical dissection of the pedicle of the gallbladder, performed in this situation without the possibility of palpating the structures, encouraged

surgeons to perform CT more often¹¹.

According to the presented series, with two X-rays has found to recognize most of the changes. It is possible: 1) to evaluate the anatomy of the entire biliary tree; 2) to identify unsuspected gallstones in the biliary tract; 3) to recognize intraluminal content in large and small overpressure after emptying; 4) to do immediate identification of any injuries; 5) to recognize patency, shape, capacity and diseases of the duodenal papilla; 6) to document the biliary tract^{1,2,11}.

The advantages are: 1) allows repetition, like all other forms of intraoperative radiographic study; 2) saves a radiograph; 3) decreases the time of anesthesia and radiological work-up; 4) allows radiomanometric study; 5) decreases exposure to X-ray; 6) less access and less handling time by the technician, with less risk of infection.

While not within the scope of this paper, it is important to say that there is no consensus among surgeons whether CT should be performed routinely or selectively⁹. Leaving aside this argument, the fact is that CT is an important feature of the surgical armamentarium in the evaluation of the biliary tract.

CONCLUSION

The proposed technique proved feasible, simple, fast and effective.

REFERENCES

- Bastos ELS, Micheloni PRT, Silvado RAB. A colangiografia peroperatória. *Ver. Col. Bras. Cir.* 1998; 25(4): 251-3.
- Brenner S, Campos ACL, Souza FJ, Brenner AS. Colangiografia per-operatória: uso de rotina ou seletivo? *Rev. Col. Bras. Cir.* 1990; 17(6): 124-8.
- Brenner S, Campos ACL, Souza FJ, Brenner AS. Colangiografia per-operatória: uso de rotina ou seletivo? *Rev. Col. Bras. Cir.* 1990; 17(6): 124-8.
- Glenn F, Grafe WR. Historical events in biliary tract surgery. *Arch. Surg.* 1966; 93: 848-52.
- Grundy DJ, King PA, Lloyd G. Comparative evaluation of preoperative and operative radiology in biliary-tract disease. *Brit. J. Surg.* 1972; 59(3): 205-8.
- Isaacs J, Daves ML. Technique and evaluation of operative cholangiography. *Surg. Gynec. Obstet.* 1960; 111: 103-112.
- Le Quesne LP. Discussion on cholangiography. *Proc. R. Soc. Med.* 1960; 53: 852-5.
- Mirizzi PL. Operative cholangiography. Its contribution to the pathophysiology of the common bile-duct. *The Lancet.* 1938; 2: 366-69.
- Mirizzi PL. Operative cholangiography. *Surg. Gynec. Obstet.* 1937; 65: 702-10.
- Samuel E. Operative cholangiography. *Br. J. Radiol.* 1959; 32(382): 669-72.
- Soares CER. Colangiografia peroperatória, cinquenta anos depois: ainda dúvidas? *Rev. Col. Bras. Cir.* 1983; 10(2): 70-5.
- Yasojima EY, Lopes Filho GJ. Colangiografia peroperatória sistemática em colecistectomia videolaparoscópica. *Rev. Col. Bras. Cir.* 2002; 29(2): 92-8.