

# ABDOMINAL WALL ENDOMETRIOMA

## *Endometrioma de parede abdominal*

Italo **ACCETTA**, Pietro **ACCETTA**, André Figueiredo **ACCETTA**,  
Francisco José Santos MAIA, Ana Paula Félix de Andrade **OLIVEIRA**

From Faculdade de Medicina da Universidade Federal Fluminense, Hospital Estadual Azevedo Lima and Hospital Universitário Antônio Pedro, Niterói, RJ, Brasil.

**HEADINGS** – Endometriosis. Abdominal wall.

**Correspondência:**

Italo Accetta  
E-mail: italo@urbi.com.br

Conflict of interest: none  
Financial source: none

Submitted: 13/10/2010  
Accepted for publication: 21/12/2010

**DESCRITORES** - Endometriose. Parede abdominal.

**ABSTRACT – Background:** The exact incidence of endometriosis in the general population is unknown. Confirmation of this disease is only possible by histopathological analysis of a fragment obtained by some invasive procedure, because there is so far, no clinical secure marker. **Aim:** To report the experience with the clinical manifestations and surgical treatment in patients with abdominal wall endometrioma. **Methods:** Retrospective analysis of patients operated for abdominal wall endometrioma with emphasis on data relating to age, symptoms, previous cesarean, relation of symptoms with the menstrual cycle, physical examinations and additional surgical treatment, postoperative course and histopathological results of specimens. **Results:** Fourteen patients were operated during the study period, aged between 28 and 40 years. The presence of local mass and pain that worsened during menstruation were the main complaints. Ultrasound and CT examinations were important to precisely localize the disease. Surgical excision was a wide excision of the tumor and affected tissues. The patient progressed satisfactorily and histopathology confirmed the diagnosis of abdominal wall endometrioma in all cases. **Conclusion:** Exists a clear relationship between cesarean operation and abdominal wall endometrioma; ultrasound studies and CT scans help to plan the surgical resection allowing resection of tumor and all affected adjacent tissues.

**RESUMO – Racional:** A incidência exata da endometriose na população geral é desconhecida. A confirmação desta doença só é possível através da análise histopatológica de um fragmento obtido por algum procedimento invasivo, pois não existe até o momento, nenhum marcador clínico seguro. **Objetivo:** Relatar a experiência com as manifestações clínicas e o tratamento cirúrgico em pacientes com endometrioma de parede abdominal. **Método:** Análise retrospectiva das pacientes operadas por endometrioma de parede abdominal, dando ênfase aos dados relativos à idade, sintomas, cesariana prévia, relação dos sintomas com o ciclo menstrual, exames físicos e complementares, tratamento cirúrgico, evolução pós-operatória e resultado histopatológico dos espécimes. **Resultados:** Foram operadas 14 pacientes no período estudado, com idade entre 28 e 40 anos. A presença de massa e dor local que piorava durante a menstruação foram as queixas principais. Ultrassonografia e tomografia computadorizada foram exames importantes em localizar precisamente a doença. O tratamento cirúrgico foi exérese ampla da tumoração e dos tecidos comprometidos. As pacientes evoluíram satisfatoriamente e o histopatológico confirmou a suspeita de endometrioma de parede abdominal em todos os casos. **Conclusão:** Foi nítida a relação entre cesariana prévia e endometrioma de parede abdominal e estudos ultrassonográficos e tomográficos auxiliaram a planejar a abordagem cirúrgica permitindo a exérese da tumoração e de todos os tecidos adjacentes comprometidos.

## INTRODUCTION

**E**ndometriosis is defined as the presence of functional endometrial tissue (endometrial glands and stroma) in locations outside the endometrial cavity and uterine muscle that usually responds to hormonal stimulation.

Their exact incidence in the general population is unknown. Confirmation of this disease is only possible by histopathological analysis of a fragment obtained by an invasive procedure, because there is so far, no clinical safe marker. When endometriosis is confined to a mass, shall be called the

endometrioma, which is not often observed by the general surgeon, especially if they occur in extrapelvic location.

The aim of this study is to report experience in 14 cases of abdominal wall endometrioma, emphasizing the clinical presentation, the importance of computed tomography and surgical treatment employed.

## METHODS

It was conducted a retrospective study of patients treated for abdominal wall endometrioma in the Azevedo Lima State Hospital and the University Hospital in the period from January 2000 to December 2008, analyzing age, symptoms and time course, previous relation of symptoms with the menstrual cycle, clinical assessment, surgical treatment, postoperative course and histopathological results of the surgical specimens.

## RESULTS

Fourteen patients were operated (Table 1) during the study period, aged between 28 and 40 years (average 33.42). The time of the signs and symptoms ranged from six months to three years (average 2.63). Thirteen patients had a history of cesarean delivery, which occurred between four and twelve years (mean 6.9) before the appearance of the tumor.

TABLE 1 - Clinical data, diagnosis, treatment and postoperative

Case	Age	Previous cesareans (years)	Time of symptoms(years)	Location	Size (cm)	Imaging examinations	Treatment	Postoperative evolution
1	31	4	1,5	FID	6 x 4	US; TC	Wide excision + screen	Good
2	33	5	1	FIE	2,5 x 1,8	US; TC	Wide excision + screen	Good
3	29	6	2	FID	4 x 3	US; TC	Wide excision	Good
4	40	—	1	Cic. Umb.	1,5 x 1,6	—	Wide excision	Good
5	35	7	3	FID	4 x 4	US; TC	Wide excision	Good
6	28	7	3	FIE	2 x 2	US; TC	Wide excision	Good
7	35	10	1	FIE	2,3 x 2,4	US	Wide excision	Good
8	40	12	1	Cic. Umb.	1,5 x 1,6	US	Wide excision	Good
9	26	8	7	FID	3 x 3	US	Wide excision	Good
10	28	8	7	FIE	8 x 5	US	Wide excision + screen	Good
11	32	2	1,5	FIE	4 x 4	US; TC	Wide excision + screen	Good
12	39	9	3	FIE	3 x 3	US; TC	Wide excision	Good
13	40	7	7	FID	3x3	US; TC	Wide excision	Good
14	32	5	0,5	FIE	3x3	US; TC	Wide excision	Good

FID = right iliac fossa; FIE = left iliac fossa; FLE = left flank; Cic umb = umbilicus; U.S. =ultrasound, CT = computed tomography

The main complaint in all cases was a tumor in the abdominal wall, which increased in volume and became more painful in the presence of a period. The tumor was located in the iliac fossa in 11 patients (five right

and six left) and left flank in one. All were located near the surgical scar from cesarean section (Figure 1). In two cases, were in the umbilical region. One tumor showed exophytic, with cerebriform and external bleeding during menstruation. The size of lesions ranged from 1.6 x 6.0 x 1.5 cm and 4.0 cm. All had tenderness, blurred boundaries, soft consistency and increased sensitivity.

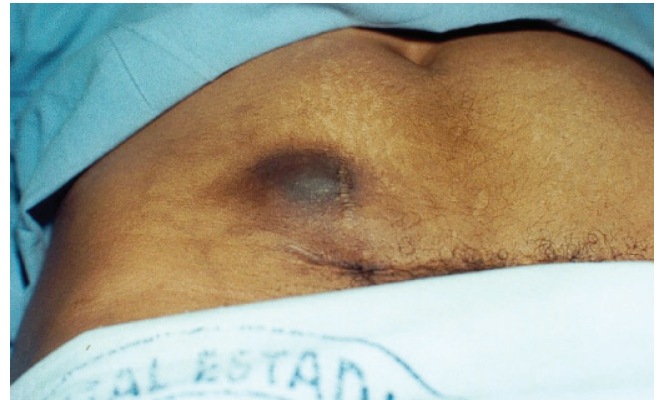

FIGURE 1 – Endometrioma near the scar of cesarean section, with emphasis on color

Ultrasonography was performed in 13 and abdominal CT scan in nine case. In three the CT scan showed contrast enhancement by tumor (only one was in menstruation period).

Surgical excision was used in large tumor and adjacent compromised tissues. On four occasions it was necessary to use a polypropylene mesh in abdominal wall reconstruction, associated with active suction drainage for 48 hours on two occasions.

The postoperative course of patients was satisfactory without any complications.

Histopathologic examination of specimens confirmed the preoperative diagnostic impression of endometrioma in all cases.

## DISCUSSION

Endometriosis is a clinical entity well known in the gynecological literature, but is not yet well understood among the general surgeons. Its extrapelvic location is much less common than the pelvis and has been observed in various organ systems (lungs, bronchi, pleura, gallbladder, kidney, bladder, small intestine, large intestine, appendix, omentum, lymph nodes, space sub-arachnoid)<sup>4,6,8</sup>.

No theory can fully explain the exact mechanism of formation of endometriosis is likely to result from a combination of events. The most accepted hypothesis is that reflux occur through tubes, particles of the endometrium into the abdominal cavity, blood and lymph vessels. Another possibility is the presence of primitive multipotent cells, that under certain

conditions produce endometriosis. Ectopic endometrial foci are almost always under the influence of ovarian hormones, with all the changes of the menstrual cycle, including bleeding.

According to Han, et al.<sup>5</sup> malignant transformation of endometriosis is rare, but can not be ruled out.

As seen in these cases the endometrioma usually affects women between the ages of reproduction, with peak incidence in the third and fourth decades<sup>15</sup>. When in the abdominal wall is preferably located near or in a surgical scar. Although in most cases occurring in patients with previous cesarean section<sup>13</sup>, the endometrioma has also been observed in the surgical incision after conventional or laparoscopic hysterectomy<sup>9,14</sup> appendectomy and inguinal hernia, as has been described in patients without any previous intervention<sup>12</sup>, a fact verified in one case in this series. For prophylaxis of endometriosis after cesarean section. Wasfie<sup>13</sup> recommends vigorous wound irrigation with saline before closure of the abdominal wall. The only patient in this study that reported no previous operation, had normal delivery 12 years before.

The time elapsed between the previous operation and the onset of symptoms resulting from the installation process can vary from six months to 20 years<sup>8,12</sup>. In these patients, this period was between four and 12 years.

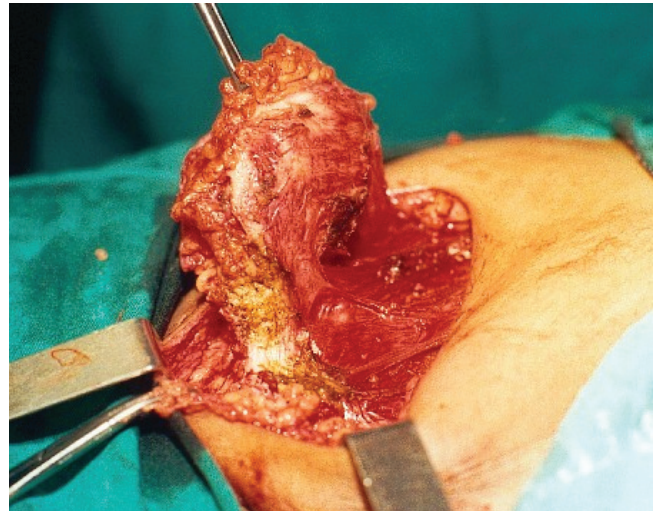
The classic symptoms of abdominal wall endometrioma in a tumor is very sensitive to palpation, pain intermittently, which increases in volume and sensitivity according to the phase of the menstrual cycle.

The presumptive diagnosis should always be considered when signs and symptoms clearly coincide with the phases of the menstrual period. However, this relationship is not always very clearly presented, making it difficult to establish the real cause of the problem. It is important to establish differential diagnosis with the following tumors: sarcomas, metastatic carcinoma, hernias, hematomas, and granulomas among others. In these cases the clear link between the signs and symptoms with menstruation favored the correct diagnostic impression of endometrioma.

Ultrasonography and computed tomography are important to define not only the size of the lesion but also the degree of involvement of the abdominal wall. A CT scan shows heterogeneous mass with no capsule, capable of capturing contrast, and perfectly locate the tumor, identifying structures of the abdominal wall that are compromised. This information is very important in the planning of surgical strategy. CT also allows study of the whole pelvic cavity that may also may be compromised by the disease.

Koger<sup>8</sup>, Patterson<sup>10</sup>, and Calabrese<sup>1</sup> still defend the puncture with fine needle aspiration biopsy, which in the opinion of this paper authors would be contraindicated by the possibility of spreading disease in healthy tissues in the path of the puncture.

The treatment of abdominal wall endometrioma is surgical resection and has as main goal the complete resection of the process, no remaining endometrial tissue in the affected area. Therefore, excision should be large<sup>2,3,7,8,11</sup>, to remove all the segments of skin, subcutaneous tissue, muscle, aponeurosis and peritoneum potentially involved (Figure 2). If possible, the defect created by excision borders must be corrected with his own abdominal muscles and aponeurosis. But when this leads to some tension in the suture lines, the most widely used option is the use of polypropylene mesh.



**FIGURE 2** - Excision of large endometrioma and tissues including skin, subcutaneous tissue and muscle part of the anterolateral abdominal

## CONCLUSION

It was clear the relationship between cesarean section and abdominal wall endometrioma in this study, and ultrasound and CT scans helped to plan the surgical resection of the tumor and adjacent all affected tissues.

## REFERENCES

1. Calabrese L, Delmonte O, Mari R. Endometriosis of the abdominal wall. Clinical case and review of literature. *Acta Biomed. Atheneo Parmense* 1997; 68: 35-43.
2. Celik M, Bulbuloglu, E, Buyukbese, MA, Cetinkaya AS. Abdominal wall endometrioma localizing in rectus abdominal sheath. *Turk. J. Med. Sci.* 2004; 34: 341-3
3. Chun JT, Nelson H.S, Maull K.J. Endometriosis of the abdominal wall. *South Med. J.* 1990; 83: 1491-2.
4. Gupta S, Shah S, Motashaw ND, Shah N, Darshana V, Daye V. Case report: Bladder wall endometrioma. *Ind. J. Radiol. Imag.* 2001; 11:23-24.

5. Han AC, Hovendensen S, Roseblum NG, Salazar H. Adenocarcinoma arising in extra gonadal endometriosis: an immunohistochemical study. *Cancer*, 1998; 83; 1163-9.
6. Healy JT, Wilkinson NW, Sawyer M. Abdominal wall endometrioma in a laparoscopic trocar tract. A case report. *Am. Surgeon*, 1995; 61: 962-3.
7. Kocakusak A, Arpinar E, Arikan S, Dermirbag N, Tarlaci A, Kabaca C. Abdominal wall endometriosis: a diagnostic dilemma for surgeons. *Med. Princ. Pract.* 2005; 14: 434-7.
8. Koger KE, Shatney CH, Hodge K, Mcclenathan JH. Surgical scar endometrioma. *Surg. Gynecol & Obstet.* 1993; 177; 242-6.
9. Nirula R, Greaney GC. Incisional endometriosis: an underappreciated diagnosis in general surgery. *J. Am. Coll. Surg.* 2000; 190:404-407.
10. Patterson GK, Winburn GB. Abdominal wall endometriomas; report of eight cases. *Am. Surgeon.* 1999; 65; 36-9.
11. Singh KK, Lessels AM, Adam DJ, Jordan C, Miles WFA, Macyntyre IMC. Presentation of endometriosis to general surgeons: a 10-year experience. *Br.J.Surg.* 1995, 82: 1349-51.
12. Thylan S. Letter to the editor. Re: Abominal wall endometrioma in a laparoscopic trocar tract. A case report *Am. Surgeon.* 1996; 62: 617.
13. Wasfie T, Gomez E, Seon S, Zado B. Abdominal wall endometrioma after cesarian section: A preventable complication. *Int. Surg.* 2002; 87:175-177.
14. Wilson H, Shaxted E. Implatation endometrioma at a port site after laparoscopic abdominal supracervical hysterectomy. *Gynaecological endoscopy* 1999; 8:245.
15. Wolf Y, Haddad R, Werbin N, Skornick Y, Kaplan O. Endometriosis in abdominal scars. *Am. Surgeon*, 1996; 62; 1042-4.