



CERVICAL ESOPHAGOGASTRIC ANASTOMOSIS FISTULA FOLLOWING ESOPHAGECTOMY: A PROBLEM WITH NO SOLUTION?

FÍSTULA DA ANASTOMOSE ESOFAGOGÁSTRICA CERVICAL APÓS ESOPHAGECTOMIA: UM PROBLEMA SEM SOLUÇÃO?

Flavio Roberto **TAKEDA**¹, Rubens Aissar **SALLUM**¹, Ivan **CECCONELLO**¹, Sérgio Carlos **NAHAS**¹

HEADINGS: Esophagectomy. Surgical Anastomosis. Fistula

The surgical treatment of esophageal cancer has evolved a lot in recent years. Forty years ago, the esophagectomy with lymphadenectomy technique in three dissection fields (cervical, thoracic and abdominal) proposed by Hiroshi Akiyama in 1981¹ showed an increased survival of patients with esophageal neoplasia associated with extensive lymphadenectomy, currently representing the primary type of esophagectomy performed in the East. However, the surgical procedure's morbidity rate was around 60%, with mortality of around 7%¹. The advent of minimally invasive surgery in the late 1990s led to declining rates of postoperative complications, especially those of respiratory complications⁶. The publication of a prospective study comparing the hybrid minimally invasive esophagectomy technique with the conventional esophagectomy technique (thoracotomy and laparotomy) evidenced that the minimally invasive technique could have fewer postoperative complications without interfering with overall survival⁴.

In 1977, Professor Henrique Walter Pinotti proposed the transhiatal, also called transdiaphragmatic esophagectomy⁵. This esophagectomy procedure without thoracotomy showed a 40% decline in surgery-related complications⁵. More recently, performing the same procedure with the minimally invasive technique also showed a decrease of around 20%⁷.

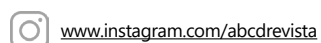
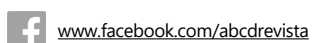Thus, in recent years, we observed an improvement in surgical results with acceptable rates of complications¹⁰. However, when evaluating the surgical results, transthoracic esophagectomy shows more extensive lymphadenectomy related to a more significant number of resected lymph nodes. In the past, this would translate into a direct increase in patient survival. Nowadays, with the advent of neoadjuvant therapies,

the need for extensive lymphadenectomy has become very debatable in the literature. Transthoracic access allows resection¹ of lymph nodes with a median of around 30, while conventional transhiatal access⁷ reaches 20 lymph nodes and laparoscopic transhiatal access 25 lymph nodes³.

However, despite the implementation of minimally invasive techniques, the rates of esophagogastric anastomosis fistula remain at around 10-15%³, regardless of the technique employed (manual, circular or linear stapling) and some surgical maneuvers (epiploplasty, pleural reconstruction, and use of surgical glue)².

Recently, we proposed a surgical standardization following esophagectomy for revascularization of the gastric tube transposed by the posterior mediastinum using neck vessels (external jugular vein and transverse cervical artery), observing a proven improvement in local tissue perfusion, which reduced the occurrence of 10.4% of fistulas (control group) to no fistula (the group with microanastomosis)⁸. It is worth mentioning the technical difficulty of assessing tissue perfusion⁹. After all, the methodology employed should be technically easy to apply, as sensitive as possible, and reproducible, which is still a challenge. Probably, esophagogastric fistulas are not only related to tissue perfusion but also local factors such as, for example, hypertension caused by persistent postoperative cough and immunogenic factors.

Finally, cervical vascular microanastomosis (Supercharged Anastomosis For Esophagectomy – SAFE procedure) is a new perspective of reducing esophagogastric fistulas following esophagectomy. The next step will be to identify who would really benefit from SAFE, proven through randomized clinical trials.



From the ¹Department of Gastroenterology, Digestive Surgery Division, Hospital das Clínicas, Faculty of Medicine, University of São Paulo, São Paulo, SP, Brazil

How to cite this article: Takeda FR, Sallum RA, Cecconello I, Nahas SC. Arq Bras Cir Dig. 2021(3):e1619. <https://doi.org/10.1590/0102-672020210002e1619>

Correspondence:
Flavio Roberto Takeda.
E-mail: flavio.takeda@hc.fm.usp.br

Financial support: none
Conflict of interest: none
Received: 28/07/2021
Accept: 02/09/2021

REFERENCES

1. Akiyama H, Tsurumaru M, Kawamura T, Ono Y. Principles of surgical treatment for carcinoma of the esophagus: analysis of lymph node involvement. *Ann Surg.* 1981;194(4):438-46. doi: 10.1097/0000658-198110000-00007.
2. Castro PM, Ribeiro FP, Rocha Ade F, Mazzurana M, Alvarez GA. Hand-sewn versus stapler esophagogastric anastomosis after esophageal resection: systematic review and meta-analysis. *Arq Bras Cir Dig.* 2014;27(3):216-21. doi: 10.1590/s0102-67202014000300014.
3. Chevallay M, Jung M, Chon SH, Takeda FR, Akiyama J, Mönig S. Esophageal cancer surgery: review of complications and their management. *Ann N Y Acad Sci.* 2020;1482(1):146-162. doi: 10.1111/nyas.14492
4. Mariette C, Markar SR, Dabakuyo-Yonli TS, Meunier B, Pezet D, Collet D, D'Journo XB, Brigand C, Perniceni T, Carrère N, Mabrut JY, Msika S, Peschaud F, Prudhomme M, Bonnetain F, Piessen G; Fédération de Recherche en Chirurgie (FRENCH) and French Esophago-Gastric Tumors (FREGAT) Working Group. Hybrid Minimally Invasive Esophagectomy for Esophageal Cancer. *N Engl J Med.* 2019;380(2):152-162. doi: 10.1056/NEJMoa1805101.
5. Pinotti HW, Pollara WM, Raia AA. Surgical treatment of advanced megaesophagus by sub-total esophagectomy by cervico-abdominal route without thoracotomy with incision of the diaphragm. *AMB Rev Assoc Med Bras.* 1980;26(10):339-42.
6. Swanstrom LL, Hansen P (1997) Laparoscopic total esophagectomy. *Arch Surg* 1997;132(9):943-7; discussion 947-9. doi: 10.1001/archsurg.1997.01430330009001.
7. Takeda FR, Sallum RAA, Ribeiro U Jr, Ceconello I. Laparoscopic transhiatal esophagectomy in esophageal cancer patients with high-risk post-operative complications. *Dis Esophagus.* 2021:doab022. doi: 10.1093/dote/doab022.
8. Takeda FR, Tutihashi R, Tustumi F, Sallum RAA, de Freitas Busnardo F, Ribeiro U Jr, Ceconello I. Supercharged cervical anastomosis for esophagectomy and gastric pull-up. *J Thorac Cardiovasc Surg.* 2021;162(3):688-697.e3. doi: 10.1016/j.jtcvs.2020.06.021.
9. Takeda FR Dr, Ceconello I. The complex assessment of anastomosis' perfusion following esophagectomy: Set in stone? *Eur J Surg Oncol.* 2021;47(6):1491-1492. doi: 10.1016/j.ejso.2020.11.010.
10. Vieira FM, Chedid MF, Gurski RR, Schirmer CC, Cavazzola LT, Schramm RV, Rosa ARP, Krueel CDP. Transhiatal esophagectomy in squamous cell carcinoma of the esophagus: what are the best indications? *Arq Bras Cir Dig.* 2021;33(4):e1567. doi: 10.1590/0102-672020200004e1567.